

Airbag pneumonitis: a report and discussion of a new clinical entity

Jaelyn M. Caudle, MD;* Robert Hawkes, MD;† Daniel W. Howes, MD;* Robert J. Brison, MD*

ABSTRACT

This report describes the occurrence of pneumonitis in a young male immediately after inhalation of aerosolized chemicals subsequent to motor vehicle airbag deployment. The clinical presentation was one of mild shortness of breath associated with bilateral alveolar infiltrates on chest radiology. Not previously described, this diagnosis should be considered in the differential of pulmonary infiltrates in motor vehicle crash patients.

Key words: airbag injuries, pneumonitis

RÉSUMÉ

Ce rapport décrit la survenue d'une pneumonite chez un jeune homme, immédiatement après l'inhalation de substances chimiques libérées dans l'air à la suite du déploiement du coussin gonflable lors d'un accident de la route. Le tableau clinique se caractérisait par une légère dyspnée associée à des infiltrats pulmonaires bilatéraux à la radiographie pulmonaire. Ce diagnostic, qui n'a jamais été décrit, devrait être pris en compte dans le diagnostic différentiel d'infiltrats pulmonaires chez les patients victimes d'un accident d'automobile.

Introduction

Airbags have been available in North American vehicles since the 1970s and have been mandatory in all new vehicles since 1998.¹ An estimated 20% reduction in mortality and morbidity in serious car crashes has been attributed to these safety devices.² Most injuries associated with airbags are minor and include contusions, abrasions and lacerations to the head, neck, extremities and thorax.^{3,4} Serious but rare pulmonary (i.e., pulmonary contusion, hemothorax and pneumothorax), ophthalmologic, neurologic or cardiovascular injuries have been reported for adults who were out of position relative to the airbag at the moment of deployment.⁴⁻⁶ Serious injuries and death have also been reported in children seated in the front passenger seat, including those in rear facing carriers.⁵ Airbag propellants have been implicated in reactive dermatitis, ocular burns

and reactive airway disease.^{4,7-9} The presentation of our case adds a new description of injury — a chemical pneumonitis — to the existing literature.

Case report

An 18-year-old male belted driver of a minivan was involved in a high-speed motor vehicle crash (MVC) rollover with airbag deployment. He was able to get out of the vehicle on his own and was found by paramedics sitting at the roadside. The vehicle had rolled 6 to 7 times, with the airbag deploying while he was in the inverted position. At the scene, his vital signs were O₂ saturation 88%, heart rate 102 beats/minute, blood pressure 128/72 mm Hg, respiratory rate 12 breaths/minute. He was transported to our trauma centre with full spinal precautions. On arrival in the emergency department (ED), the patient's vital signs were

From the Departments of *Emergency Medicine and †Radiology, Queen's University, Kingston, Ont.

Received: Feb. 21, 2007; revisions received: May 22, 2007; accepted: May 22, 2007

This article has been peer reviewed.

Can J Emerg Med 2007;9(6):470-3

heart rate 93 beats/minute, blood pressure 125/73 mm Hg, respiratory rate 12 breaths/minute, O₂ saturation 97% with O₂ delivered by a non-rebreather mask. His symptoms included dyspnea, sternal area pain and a cough with scant

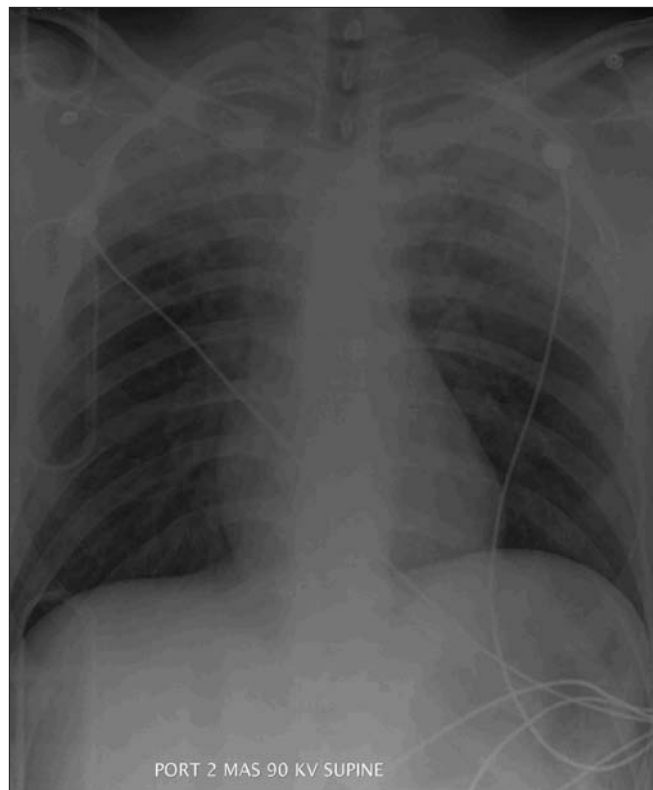


Fig. 1. Chest radiograph showing significant bilateral, symmetrical and apical airspace disease.

production of blood-tinged sputum. He had not vomited. Auscultation revealed normal air entry bilaterally, with no abnormal sounds. Other than minimal chest wall tenderness, there was no evidence of chest or maxillofacial injury, or oral or nasal bleeding. Neither aspiration of blood nor blunt trauma seemed probable as the cause of the patient's hypoxia or respiratory complaints. The patient was previously healthy, on no medications and was a non-smoker. The remaining primary and secondary survey examinations were normal.

The chest radiograph (Fig. 1) showed significant bilateral, symmetrical and apical airspace disease. The differential diagnoses considered included pulmonary contusion, aspiration of blood and pneumonitis. An unenhanced, high-resolution spiral CT scan of the chest showed symmetric, predominantly apical upper lobe and posterior lower lobe, diffuse airspace findings with ground glass opacities. There were no other injuries noted on the chest CT (Fig. 2). Although diagnostic consideration included pulmonary hemorrhage, the distribution of the radiographic changes was atypical, and radiological interpretation was most consistent with a diagnosis of chemical pneumonitis.

The patient was observed in the ED for 8 hours, during which time his room air O₂ saturation improved to 94%. He remained mildly tachypneic with a respiration rate of 22 breaths/minute. Repeat chest radiographs at 8 hours after injury showed mild, interval improvement in the upper lobe airspace disease and increased involvement of the mid and lower lung zones (Fig. 3). The patient declined admis-

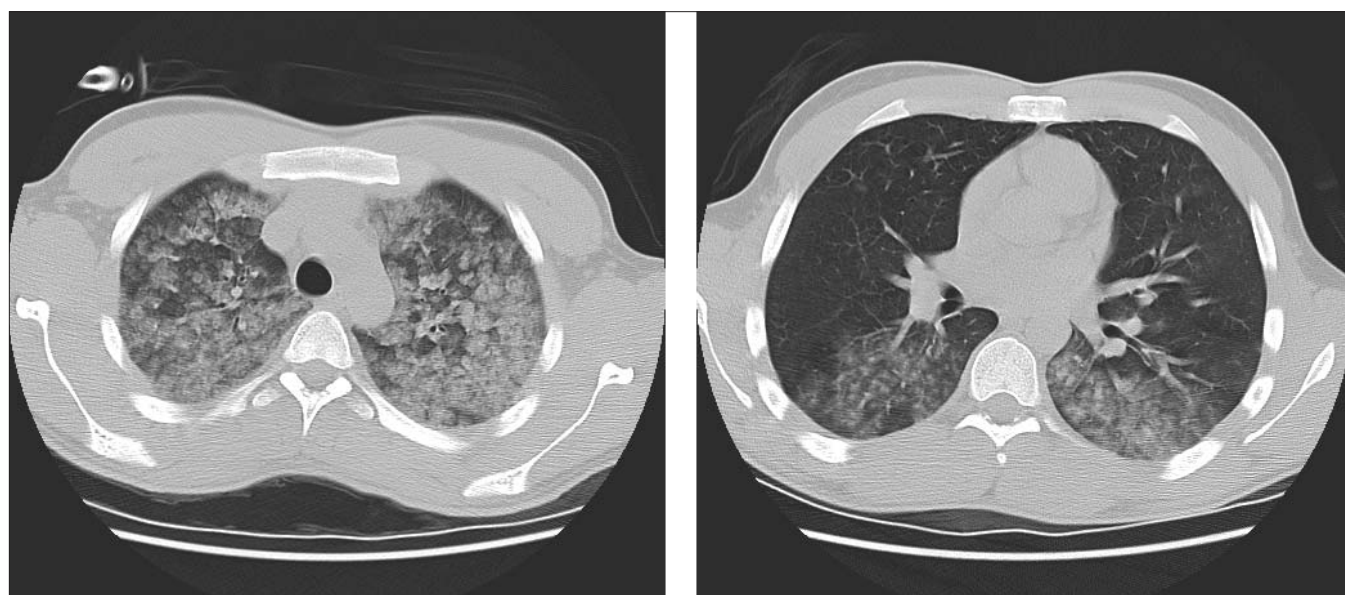


Fig. 2. An unenhanced, high-resolution spiral CT scan of the chest (left and right) showing symmetrical, predominantly apical upper lobe and posterior lower lobe, diffuse airspace findings with ground glass opacities.

sion and was discharged home with family physician and respiratory follow-up. A 10-day oral corticosteroid course was provided.

The patient experienced minimal hemoptysis of blood-tinged sputum for 3 days after discharge and exertional dyspnea with wheezing for 2 weeks. Repeat chest x-ray at 3 weeks and pulmonary function testing at 4 weeks were normal.

Discussion

Widespread implementation of automobile airbags in MVCs has resulted in a substantial reduction in mortality.¹ However, this increased use has also been associated with new patterns of injury caused by airbag deployment. These injuries, while minor compared with those associated with non-use, include fractures, chemical burns, blunt cardiovascular trauma, ophthalmologic injury and soft tissue injuries.⁴⁻⁶ A review of the literature (Medline 1966 to 2006 using the MESH terms airbag injuries, sodium azide, airbag and pneumonitis) identified few cases of inhalation injuries related to the release of toxic compounds during airbag deployment.⁷⁻¹² One case of subglottic injury was reported following airbag rupture causing a clinical presentation of bronchospasm in a patient with underlying lung disease.⁸ Gross and colleagues reported that 40% of asthmatics experienced significant bronchoconstriction after airbag deployment.⁷ Further studies suggested the primary irritant was the particulate matter and not the gaseous com-

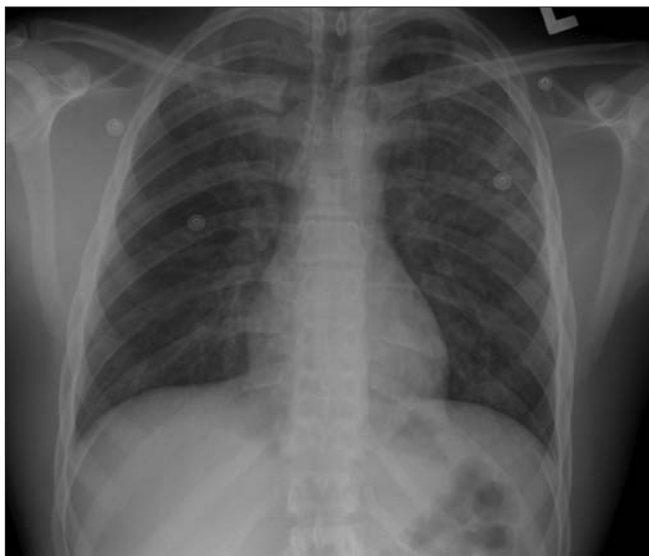

Fig. 3. Repeat chest radiographs taken 8 hours after injury showing mild, interval improvement in the upper lobe air-space disease and increased involvement of the mid and lower lung zones.

ponent of the effluent.^{10,11} Our case adds a new type of injury — a chemical pneumonitis — to the existing literature.

The major propellant in airbags is sodium azide, which is combined with an iron or copper catalyst to generate the heated nitrogen gas that rapidly fills the airbag.^{12,13} In normal deployment the azide is converted into sodium hydroxide and sodium carbonate. These compounds and trace gases (i.e., carbon dioxide, hydrogen and carbon monoxide) are vented into the passenger compartment through ports in the airbag following deployment. Talc, present on the surface of the airbag to ensure smooth, symmetric deployment, also contributes to visible particulate matter. Compounds that are highly water soluble can affect the upper airway because of direct contact with the mucosa and rapid absorption into the trachea and bronchi.¹⁴ Less soluble compounds travel farther into the airway, causing damage to alveoli and bronchiole epithelium. Principle contribution to airway penetration is particle size; smaller particles (0.5–3.0 μm) travel farther. Sodium azide and sodium hydroxide are very small hydrophilic compounds. They may have been responsible for the pneumonitis in this patient.

Symptomatology of inhalation injury is varied. Airbag-induced lung injury may result in bronchoconstriction, airway edema, hemoptysis, pulmonary infiltrates and emphysema. Inhaled sodium azide produced symptoms of respiratory distress, pulmonary edema and cardiopulmonary failure among manufacturing and transportation workers who were exposed to toxic levels of this compound.¹²

The differential diagnoses for the radiographic findings in our trauma patient included pulmonary contusion, pulmonary hemorrhage, acute respiratory distress syndrome (ARDS) and aspiration pneumonitis. The location of the abnormality does not match the history or mechanism of injury for pulmonary contusion or pulmonary hemorrhage. The time course and severity of injury exclude ARDS. There is no history to support aspiration of blood or vomit. Pulmonary hemorrhage and aspiration pneumonitis usually require 24 to 48 hours for radiographic resolution.¹⁵ The rapid onset of radiographic changes, the nature of the CT findings and the apical location of the injury all favour chemical pneumonitis by inhalation while the inverted patient was in close proximity to the deploying airbag.

Conclusion

Our case focuses on the pulmonary complications in an 18-year-old male involved in a high-speed MVC rollover

with airbag deployment. Pulmonary injury presented as significant bilateral upper lobe densities on chest radiograph and CT scan with clinical signs limited to modest compromise of respiratory function. This presentation is consistent with a diagnosis of bilateral upper lobe inhalation chemical pneumonitis. The potential for airbag pneumonitis should be included in the differential diagnosis of patients presenting with pulmonary densities on chest radiography following deployment of an airbag.

Competing interests: None declared.

References

1. Mikhail J, Huelke DF. Air bags: an update. *J Emerg Nurs* 1997; 23:439-45.
2. Zador P, Ciccone M. Automobile driver fatalities and frontal impacts: airbags compared with manual belts. *Am J Public Health* 1993;83:661-2.
3. Antosia RE, Partridge RA, Virk AS. Air bag safety. *Ann Emerg Med* 1995; 25:794-8.
4. Corazza M, Trincone S, Virgili A. Effects of airbag deployment: lesions, epidemiology and management. *Am J Clin Dermatol* 2004;5:295-300.
5. Wallis LA, Greaves I. Injuries associated with airbag deployment. *Emerg Med J* 2002;19:490-3.
6. Gault JA, Vichnin MC, Jaeger EA, et al. Ocular injuries associated with eyeglass wear and airbag inflation. *J Trauma* 1995;38: 494-7.
7. Gross KB, Haidar AH, Basha MA, et al. Acute pulmonary response of asthmatics to aerosols and gases generated by airbag deployment. *Am J Respir Crit Care Med* 1994;150:403-14.
8. Epperly NA, Still JT, Law E, et al. Supraglottic and subglottic airway injury due to deployment and rupture of an automobile airbag. *Am Surg* 1997;63:979-81.
9. Hambrook DW, Fink JN. Airbag asthma: a case report and review of the literature. *Ann Allergy Asthma Immunol* 2006;96: 369-72.
10. Gross KB, Koets MH, D'Arcy JB, et al. Mechanism of induction of asthmatic attacks initiated by the inhalation of particles generated by airbag system deployment. *J Trauma* 1995;38:521-7.
11. Weiss JS. Reactive airway dysfunction syndrome due to sodium azide inhalation. *Int Arch Occup Environ Health* 1996;68:469-71.
12. Chang S, Lamm SH. Human health effects of sodium azide exposure; a literature review and analysis. *Int J Toxicol* 2003;22: 175-86.
13. Schreck RM, Rouhana SW, Santrock J, et al. Physical and chemical characterization of airbag effluents. *J Trauma* 1995; 38:528-32.
14. Miller K, Chang A. Acute inhalation injury. *Emerg Med Clin North Am* 2003;21:533-57.
15. Barrett S, Johnson M. Shortness of breath. In: Rosen P, Doris P, Barkin R, et al, editors. *Diagnostic Radiology in Emergency Medicine*. St. Louis (MS): Mosby; 1992. pp. 273-313.

Correspondence to: Dr. Jaelyn Caudle, Department of Emergency Medicine, Queen's University, 79 Stuart St., Kingston ON K7L 2V7; 9jmc2@queensu.ca