

## Severe undernutrition in growing and adult animals

### 18.\* The effects of rehabilitation on the teeth and jaws of pigs

By R. A. McCANCE†

*Medical Research Council Department of Experimental  
Medicine, University of Cambridge*

AND P. D. A. OWENS

*The Queen's University of Belfast, Department of Anatomy,  
Belfast, Northern Ireland*

AND C. H. TONGE

*The University of Newcastle upon Tyne, Sutherland Dental School,  
Northumberland Road, Newcastle upon Tyne 1*

(Received 31 July 1967—Accepted 8 January 1968)

1. Pigs, held by undernutrition to a weight of about 5.5 kg till they were a year old, were then rehabilitated on an excellent growing ration, and killed when they were fully mature.
2. Undernutrition of this degree of severity delayed the growth and development of the teeth, but relatively less than that of the body or the jaws.
3. The teeth became abnormally sited and the shape of the mandible changed.
4. During rehabilitation, some of the crowns and most of the roots of the molar teeth failed to reach their proper size.
5. Some of the molar teeth remained permanently impacted and out of alignment.
6. The fine structure of the teeth, particularly of those parts formed during the period of undernutrition, was still abnormal when the animals were killed.

There is little experimental work on the dental effects of undernutrition, and the important papers were reviewed by Tonge & McCance (1965), who were studying the matter in pigs. The diet used was an excellent one, if given in satisfactory quantities, but the degree of undernutrition finally achieved was such that the animals weighed only some 5.5 kg when they were a year old, by which time their litter-mates weighed about 150 kg or more (McCance, 1960). In clinical terms these animals were about 3.5% of their expected weight, and they were suffering from an extreme degree of 'marasmus'. In other words, growth had been limited throughout by a deficiency of calories. Photographs of these animals have been published by McCance & Widdowson (1962), and special and general aspects of this work by various authors have appeared in previous papers in this journal.

It is now proposed to describe the effects of rehabilitation on the teeth, particularly the molar teeth, of similarly undernourished pigs, so that the present investigation opens with the mouth and teeth in the state described by Tonge & McCance (1965),

\* Paper no. 17: *Br. J. Nutr.* (1967), 21, 787.

† Present address: Medical Research Council Infantile Malnutrition Research Unit, Mulago Hospital, P.O. Box 7051, Kampala, Uganda.

and ends with them as they were found in fully rehabilitated animals reared from 1 year of age on the same diet as litter-mates which had never been undernourished at all. The molar teeth were studied in the first instance because the timing of their development and eruption indicated that they were likely to show considerable reaction to the experimental regime.

#### MATERIAL AND METHODS

Thirty-five pigs, bred and reared at the laboratory farm near Cambridge, have been used for the main investigation. This number was made up as follows: two pigs were killed after they had been undernourished till they were 1 year old to check some of the conclusions reached by Tonge & McCance (1965) about the jaws and teeth of such animals. Two pigs were killed after they had been rehabilitated for 4 months, 8 months and 12 months respectively, and nine animals after they had been rehabilitated for 2½–4 years. In each instance rehabilitation started when the pigs were 1 year old. As after 1 year of undernutrition, a double control was used for each stage of rehabilitation: (1) animals of the same age which had never been undernourished; (2) normal animals as old as the period for which the undernourished animal had been rehabilitated. Consequently, at least two normal pigs were killed at the ages of 4, 8, 12, 16 and 20 months. One normal animal was killed when it was 2 years old, one when it was 2½ years old, and six fully mature adult animals over 3 years old. Additional pigs have been used to check specific points from time to time.

The pigs were killed either at the slaughter-house or in the laboratory, and the heads were removed and the muscle and skin dissected out from them. The skull was then opened, the brain removed and the jaws were disarticulated. After some further cleaning the mandible, with the remainder of the skull, was placed in neutralized formal saline for about a month. The two parts were then removed, carefully cleaned up, photographed from the side and also perpendicularly from the 'inside' of the mouth. They were then sent to C.H.T. at Newcastle. Measurements and histological examinations were then made, as outlined by Tonge & McCance (1965); both jaws were dissected longitudinally, X-rayed, photographed, and sent to P.D.A.O. at Belfast for a detailed study of the permanent molar teeth.

The angles between the base of the mandible and the forward slope of the incisor teeth at their most anterior point were measured in one or more, sometimes all, of the following ways: (1) from the Cambridge photographs, which were specially taken to avoid distortion; (2) by measurements on the jaws themselves; (3) from X-ray photographs. The last method was probably the least reliable, but the results of the three methods usually agreed reasonably well within a range of 5 degrees or so and the mean of the available measurements was accepted as the best approximation.

The permanent molar teeth and the alveolar bone around them were removed from nineteen of the jaws with a dental drill. Four jaws were from animals 1 and 2 years old and six from animals 3 years old and over. The remaining five jaws came from animals at the younger and intermediate ages of 4, 8, 16 and 20 months. Each tooth was then dissected out and freed from bone by further use of the drill, dental chisels and blunt dissecting scalpels. Any roots fractured during this process were repaired with impact

adhesive (Evo-Stick); the weight of this was negligible. Two dimensions of the crowns of these teeth were then measured with a Vernier caliper gauge (Fig. 1): (i) the mesio-distal length of the crown (*AC*, *EG*), defined as the distance between the mid-points of the mesial and distal surfaces of the crowns; (ii) the bucco-lingual width of the crowns, strictly defined as the greatest measurement at right angles to the mesio-distal alignment (*A* or *C*; *E*, *F* or *G*). Because of the size of the teeth and the impression that different parts of them might vary in their response to the undernutrition and rehabilitation, three widths *A*, *B*, *C*, or *E*, *F*, *G*, were measured as shown in Fig 1, and the mean was obtained. Severe attrition of the occlusal surfaces complicated the measurements in the older animals. Each root or root mass was measured and recorded

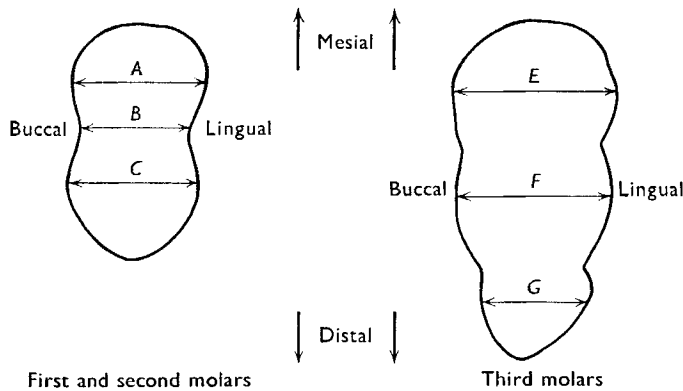


Fig. 1. Diagram of the occlusal views of the first and second molar teeth (left) and of the third molar (right) to show where the measurements of the crown widths were made.

separately. The length was taken along the long axis of the root from the apex to the junction of the enamel and cementum. Curvature of the roots was not taken into account, as this was usually negligible. Each tooth was weighed to the nearest 0.01 g. Attrition of the occlusal surfaces of the teeth and debris accumulating in the crevices between the cusps made it impossible to obtain their 'true' weights after they had reached maturity. An approximation of the weight of the molar segment consisting of the three molar teeth, for comparison with body-weight, was obtained by weighing the upper and lower molar segments on each side of the jaw at all stages of their development and calculating their mean at each stage. Specimens with missing teeth were not included in this aspect of the survey. Since the emphasis of this paper is on molar teeth as a unit on each side and in each jaw, the molar segment of three teeth, rather than all twelve molars, is compared with body-weight.

## RESULTS

### *Comparative growth of body and teeth*

Fig. 2 shows the somatic weight-time relationship of (a) normal animals reared on unlimited food and therefore to some extent overweight, (b) the experimental animals during their period of undernutrition and subsequent rehabilitation—also on

unlimited food. At the end of the period of undernutrition the experimental pigs weighed about 3.3% of the weight to be expected of them at that age. By the end of the period of rehabilitation they had recovered to nearly 80% of their expected weight, and they were clearly not going to improve on this. This confirms results previously obtained (McCance, 1966; McCance & Widdowson, 1966; Lister & McCance, 1967). Fig. 3 shows the same relationships for molar teeth, and for present purposes the falling weight due to attrition in later life may be disregarded. There were differences between the effects of undernutrition on the body as a whole and on the teeth, the most important being the delayed but continuous growth of the molar teeth during the period of undernutrition, so that, at the end of it, they were 29% of their expected weight. This had improved to a little over 70% by the end of rehabilitation, but the recovery was then at an end.

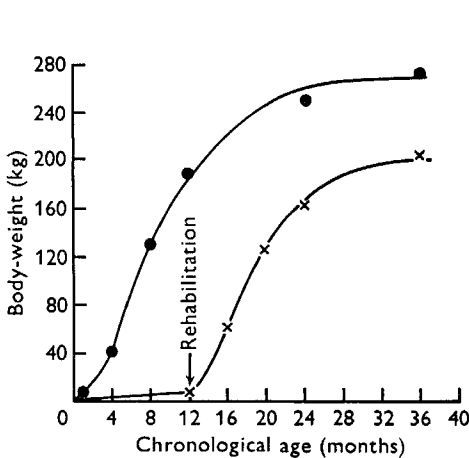


Fig. 2

Fig. 2. Effect of undernutrition followed by rehabilitation on somatic growth. The increase in weight of normal pigs is shown above, and of pigs undernourished for 1 year and then rehabilitated, below.

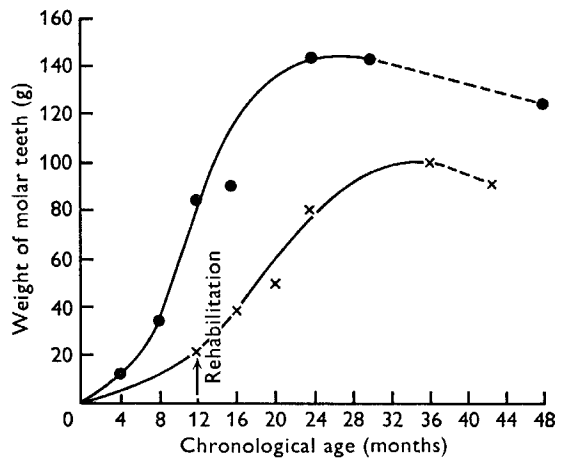


Fig. 3

Fig. 3. Effect of undernutrition followed by rehabilitation on the growth of the molar teeth. The increase in weight of the molar teeth of normal pigs is shown above, and of pigs undernourished for 1 year and then rehabilitated, below. ---, loss in weight due to attrition.

Another demonstration of the changing relationships between the weights of the somatic and dental tissues, during undernutrition and subsequent rehabilitation, is shown in Fig. 4. This shows the weights of molar teeth  $\times 100$  as a percentage of the weights of the body as they varied with the chronological age of the animals. At the end of undernutrition the molar teeth were 0.36% of the weight of the body, whereas the normal ones were only 0.04%. Four months later the two percentages were almost the same, and by the time the pigs were 2 years old the teeth of the experimental animals accounted for a smaller proportion of the body-weight than in the normal ones.

Aspects of the continuous if delayed development of the molars in jaws which had not grown large enough for them were demonstrated radiologically by McCance, Ford & Brown (1961) and Tonge & McCance (1965), and Pl. 1*a* illustrates a dissection of

the lower jaw of a pig after 1 year of undernutrition. It shows the delayed shedding of the milk teeth, and many indications of potential malocclusion and severe overcrowding in the jaw. The overcrowding seems less apparent than it really is, for in pigs there is normally ample free space, both in front of and behind their canines (Owens, 1968). A full description of the normal pig at 1 year, together with illustrations, is given by Tonge & McCance (1965).

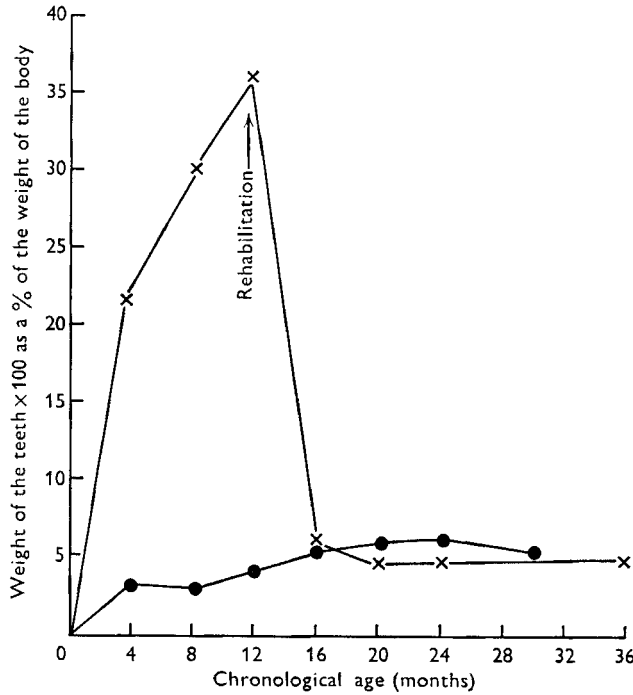


Fig. 4. Effect of undernutrition followed by rehabilitation on the weight of the molar teeth as a percentage of body-weight. x—x, experimental pigs; ●—●, normal pigs.

Table 1. Anterior angles (degrees) of the mandible of normal and experimental pigs of corresponding weight and age

Normal pigs			Experimental pigs				Significance of difference	
No.	Age (months)	Weight (kg)	No.	Under-nourished (year)	Rehabilitated (months)	Weight (kg)		Mean angle
6	1	5.52	8	1	0	5.55	18.8	$P < 0.001$
5	12	159	8					
3	16	192	2	1	4	50	27.0	—
3	20	125	2	1	8	122	32.0	—
7	36	274	10	1	24+	201	34.6	$P < 0.01$

A further aspect of this crowding is shown by the distortion in the shape of the mandible. Table 1 shows the mean anterior angles of the mandibles of normal and experimental animals at various ages and weights. The angles in the undernourished pigs were significantly smaller than those in their weight controls 1 month old, and in

their age controls. They remained smaller during rehabilitation, although the numbers were too few for statistical treatment, and after full rehabilitation the angles were still significantly smaller than those of normal adults. This distortion was recorded radiologically on isolated mandibles (McCance *et al.* 1961; Tonge & McCance, 1965). The measurements made of the anterior and angular breadths of the mandible, as described by Tonge & McCance (1965), were not sufficiently numerous to show statistically whether the mandibles of the undernourished animal were disproportionately long, and the detailed measurements of the jaws will be left for a later publication.

Previous workers (Widdowson & Kennedy, 1962) used velocity growth curves

$$\frac{\text{gain of weight} \times 100}{\text{unit of time} \times \text{weight at the beginning of the timed period}}$$

to study the effects of undernutrition, followed by rehabilitation, on the body-weight of rats. As a possibly more instructive alternative the gains in weight per unit of time

Table 2. *Gains in weight of the body and molar teeth of normal pigs and of pigs rehabilitated after 1 year of undernutrition; the initial starting values were the same in both groups of animals*

2-month periods of normal or of rehabilitating growth	Gain in body-weight (kg)		Gain in weight of the molar teeth (g)	
	Normal animals	Rehabilitating animals	Normal animals	Rehabilitating animals
1	19.0	17.0	14.0	8.0
2	40.0	37.0	16.0	8.0
3	47.0	35.0	20.0	10.0
4	33.0	30.0	19.0	10.0
5	23.0	20.0	18.0	10.0
6	24.0	19.0	14.0	10.0
7	15.0	9.0	10.0	8.0
8	11.0	6.0	6.0	6.0
9	10.0	9.0	4.0	6.0
10	11.0	5.0	—	3.0
11	9.0	} -5.0	—	1.0
12	4.0		—	—

during rehabilitation and during normal growth were calculated, and the results for the body and the teeth are shown in Table 2. The records were made from the time when both groups of animals and both sets of teeth were the same weight, and therefore compare their growth over the same weight range. This table, and Figs. 2 and 3, show that: (a) after the delayed growth in the 1st year of life, neither the animals nor their teeth ever increased in weight during their 2nd and 3rd years of life as rapidly as the bodies or the teeth of the normal animals growing over the same weight range had done when they were younger; and that (b) both the bodies and the teeth stopped growing at about the same chronological age from conception; and consequently that (c) neither the bodies nor the molar teeth of the rehabilitating pigs attained the correct, genetically determined size as regards either their bodies or their permanent molar teeth.

*Measurement of the permanent molars*

Table 3 shows the measurements of the three molar teeth in the lower jaw that were made at the end of undernutrition, and after full rehabilitation. Similar measurements were also made in the upper jaw. The detailed results, including values for the intermediate stages of rehabilitation, will be published elsewhere. The crowns and roots of the first molar teeth were fully formed by the time the normal animals were 1 year old. The crowns had already been laid down by the time undernutrition began, and were of the correct size. The development of the roots was greatly held up by the undernutrition, and was never made good, even by the end of rehabilitation, although growth throughout this period was taking place under the stimulus of full nutrition.

Table 3. *Mean measurements (cm) of the molar teeth in the lower jaw of normal, undernourished and rehabilitated pigs*

Type, age of pig	No. of molar	Crowns		Roots				
		Length	Width*	Mesio-buccal	Disto-buccal	Disto-lingual	Mesio-lingual	Distal
Normal, 1 year	1st	1.80	1.11	1.77	1.75	1.69	1.90	—
	2nd	2.25	1.47	1.62	1.66	1.56	1.60	—
	3rd	3.40	1.48	—	—	—	—	—
Undernourished, 1 year	1st	1.82	0.97	0.95	0.95	0.83	0.80	—
	2nd	2.03	1.10	—	—	—	—	—
	3rd	—	—	—	—	—	—	—
Normal adults	1st	1.52	1.19	1.70	1.60	1.68	1.70	—
	2nd	2.00	1.55	1.60	1.70	1.84	1.71	—
	3rd	3.82	1.68	1.70	1.70	1.60	1.80	0.95
Fully rehabilitated adults	1st	1.60	1.05	1.16	1.37	1.26	1.40	—
	2nd	2.05	1.34	1.65	1.55	1.50	1.53	—
	3rd	2.92	1.51	1.33	1.43	1.38	1.50	1.10

\* Means of measurements indicated in Fig. 1.

Similar events were taking place in the upper jaw. The crowns and roots of the second molars had also completed their development in the normal animals by the time they were 1 year old, with the possible exception of the disto-lingual root, and this was complete in the upper jaw. The formation of these teeth was running about 6 months late in the undernourished pigs, and at the end of the year the crowns had not yet reached the stage of development shown by the normal pigs at 8 months of age, and the roots had not yet begun to be calcified. Nevertheless, these molars made a relatively complete recovery, and all the roots, except possibly the two lingual ones, ultimately achieved approximately their correct length. The third molars behaved differently however. The crowns of these teeth should have begun to calcify at about the 6th month, i.e. during the period of undernutrition, but they had not yet erupted when the undernutrition came to an end. The whole of their visible development, therefore, took place during a time of full nutrition, yet the crowns finished up only some two-thirds their proper size (McCance *et al.* 1961) and the roots made an equally poor recovery (Owens, 1968). Only the distal root reached its proper length, and the photographs in Pl. 1 *b* show that all the molar roots suffered in width, as well as length.

*Displacement and loss of teeth*

Pl. 2 *a* shows the maxilla of a normal  $2\frac{1}{2}$ -year-old animal, and Pl. 2 *b* the malalignment of the molar teeth in the upper jaw of an undernourished and fully rehabilitated hog. This essentially illustrates an exceptionally good degree of restoration of regularity of tooth arrangement. Pl. 3 shows the mandible of another fully rehabilitated hog with malalignment of both third molars, one of which had rotated through about  $90^\circ$ . The first and second molar teeth were missing on the right side, and the third molar was missing from the left side of the maxilla of the same pig. Loss of molars from the upper jaw was observed in two of the fifteen rehabilitated pigs and from the lower jaw in three of these animals. Irregularities in tooth arrangement were more marked in the mandibles than in the maxillae.

Other mandibles have been illustrated by McCance (1964) and McCance & Widdowson (1966), and a preliminary report has been made about them by Owens, Tonge & McCance (1965). The state of the mouth at the end of the period of undernutrition was demonstrated by Tonge & McCance (1965).

The general picture is therefore reasonably complete. Permanent malocclusion remained, the third molars in both jaws were often grossly misplaced, and those in the mandible were frequently too small. Furthermore, molars were sometimes missing.

*Structure of the teeth*

Pigs' teeth are not so heavily calcified as those of man. Considering the structure and siting of the teeth after the year of undernutrition, their recovery was remarkably good, but they were rarely so well formed as those of the normal animals. Incremental lines and zones of interglobular dentine were far more numerous than in the normal animals and there were many more pockets of resorption on the outer sides of the roots that had been filled in with cementum.

Pl. 4 *a* and *b* are ground sections of mesial roots of the first mandibular molars of two pigs. Both animals had been rehabilitated for 8 months. The development of these roots had been held up by the period of undernutrition, and their growth during rehabilitation may have been handicapped by the migration of the teeth in the elongating mandible. Pl. 4 *a* shows (*A*) an area of dentine formed during undernutrition, (*B*) an irregular band of transitional dentine separating this from (*C*), the dentine formed during rehabilitation. The incremental lines are very conspicuous and so are the multiple dark patches of uncalcified 'interglobular' dentine. Pl. 4 *b* shows (*A*) an area of dentine with a very irregular edge which has been filled in with cementum (*B*, *B*).

The roots of the second molar teeth were formed entirely during rehabilitation, and Pl. 4 *c* shows part of the mesial root of one of these mandibular teeth 1 year after rehabilitation had begun. There has, for some reason, been gross interference with the normal growth pattern of the most recently formed dentine lying adjacent to the pulp cavity and this has resulted in what might be described as a very large abnormally calcified incremental line.

Pl. 5 *a* is a ground section through the distal root of the first permanent maxillary



molar from a pig that had been rehabilitated for 2 years. The dentine of the root (*A*) has been surrounded by an excessive amount of cementum (*B*) which, because of its deposition in the long axis of the tooth, has lengthened the root area and presented a greater area for periodontal ligament attachment, thus aiding retention during rehabilitation. Since the jaws are increasing rapidly in size at a time when, apart from cementum deposition, the tooth is complete, the cementum has a functional significance in relation to tooth retention at a time when the tooth is moving within the remodelling jaw.

Most of the crowns and the whole of the roots of the third molar teeth were formed during rehabilitation. Pl. 5*b* shows a ground section of a mesial root of one of these mandibular teeth after over 2½ years of rehabilitation. The most recently formed dentine (*B*) lying next to the pulp cavity (*C*) is most irregular and full of dark patches of uncalcified 'interglobular' material. Since the pulp cavity can go on forming secondary dentine throughout life this finding indicates that even after full rehabilitation this function may never become normal.

Pl. 5*c* is a ground section of one of the mesial roots of a second permanent upper molar taken from a normal animal 3 years old. This plate has been inserted to show that rudimentary incremental lines can sometimes be found in normal teeth and also, but rarely, pockets of dentine that has been resorbed for some reason and subsequently filled with cementum.

#### DISCUSSION

##### *Complete growth and the completion of development*

It is well known that each part of the body develops at its own characteristic rate and time. The brain develops early and its pattern of formation is mainly genetically determined, while the testes and ovaries are influenced by hormone production. The teeth, which develop from the 2nd month of gestation to adult life, have a definite chronological order in which they form, erupt, grow roots and become functional. This genetically determined sequence of events results in teeth developing at precisely the right moment to bring them into correct alignment and position in the jaw which has been following its development at a totally different rate, dictated partly by genetics and partly by the hormonal activity of the pituitary. Hammond (1932*a, b*, 1950) repeatedly emphasized a fact which had only been vaguely appreciated before, namely that the 'level' of nutrition profoundly influences these differential rates of development, because, although undernutrition delays all growth, it delays the growth of those parts least which are developing fast, and which have therefore what Hammond describes as 'priority of growth'. Today it might be put in another way by saying that the metabolic turnover of those tissues is directed so strongly towards anabolism that when there is not enough food to enable all the organs and tissues to grow at an optimum rate, the privileged ones continue growing, slowly it is true, but sometimes even at the expense of others, which might be regressing in size.

The work at Cambridge over the last 20 years on the effects of severe undernutrition has repeatedly confirmed Hammond's conceptions based on his study of the pig and sheep, but new points have been added. It would now appear that: (1) if the body is

prevented from growing to the full by a low plane of nutrition early in life, it may never be possible for it to attain its full genetic stature, however high the plane of nutrition may later become (Widdowson & McCance, 1960; Lister & McCance, 1965; McCance, 1962, 1966); (2) if a permanent molar tooth is likewise prevented by undernutrition from developing as it should early enough in its chronological life span, it also may never attain its potential genetically determined size. It will do better than the body during the period of undernutrition because during their time for development teeth have a greater priority of growth, or tendency towards anabolism, than bones. Nevertheless, it will fail unless each stage has been completed within a finite chronological age.

The reasons for this are not yet clear. However: (a) It cannot be due to a general defect of nutrition, for during rehabilitation, when most of the growth of the body, the roots and some of the crowns of the permanent molars are taking place, the state of nutrition of the animal is as perfect as it can be made. (b) It is probable from the work of Fábry & Hruza (1956) that the failure of the body to complete its development to the full is due to the effect of age on the production of, or the response of the epiphyses to, growth hormone. (c) Growth hormone need not be considered in the case of teeth, and it is possible to argue that the 'built-in' metabolic clock inside the molar tooth germs, which stimulates them to develop at a finite chronological age, ceases to provide this stimulation at an equally finite age, whether their development has been completed within this time or not. The small size of the molar and particularly of the third molar crowns may, however, be the result of the compression of the enamel organ during the critical period of its development, and the rapid movement of these molars in the jaw during rehabilitation may be partly responsible for the small size of the roots (Owens, 1968).

#### *The shape of the jaws and the siting of the teeth*

Trowell, Davies & Dean (1954) discussed what was then known about the teeth in infantile malnutrition. Evidence then was that their development was up to time, and this is what one would expect from the severity, duration and timing of the malnutrition usually encountered in man (Hellman, 1923; Boas, 1933; Stack, 1964).

Work on pigs has now demonstrated conclusively that if the undernutrition is sufficiently severe, it leads to considerable delay in the appearance and eruption of all the teeth, alters the structure and shape of the mandible, and produces malocclusion and displacement of the permanent molars. Furthermore, many of these changes are permanent, even if a state of full nutrition is restored, and ample time allowed for rehabilitation.

These findings are important for at least two reasons: (1) It has been a matter for debate among dental anatomists for many years whether the structure of the mouth and the siting of the teeth can or cannot be affected by the level of nutrition (Brash, McKeag & Scott, 1956; Garn, Lewis & Blizzard, 1965). It is now clear that they can, and to a much greater extent than previous work on animals has suggested (Wiener & Purser, 1957), but whether the severity of the undernutrition envisaged is enough to account for the whole of the lesions sometimes observed in man remains to be seen.

(2) Within the last few years a beautiful technique for determining the age of an elephant has been devised (Laws, 1966), which depends upon detailed study of its molar teeth. This technique is now being applied to three populations of elephants which are thought to have been living at three different planes of nutrition (K. G. McCullagh, personal communication). It has been assumed hitherto that the development of the teeth found in their mouths has been dictated solely by chronological age. This view may have to be modified, but present evidence suggests that the elephants' planes of nutrition are not sufficiently different to invalidate the use of the method.

#### *The fine structure of the teeth*

The paper of Tonge & McCance (1965) showed that undernutrition produced abnormalities, both in the crowns and roots. The present article shows that normal structure is seldom regained and that abnormal dentine may continue to be formed until the very end of full general rehabilitation. Hence all aspects of the dentition must be regarded as permanently impaired. The value of this work seems to lie in the fact that it has reproduced many of the features of faulty dentition so well recognized in man. The most notable are the delays in the times of eruption, irregular siting, multiple malocclusions and disturbed calcification. The environment, in short, has been proved to play an important part in these events, and it would have been impossible to prove this experimentally in man.

The authors are very grateful to Terry Cowen for taking such good care of the animals, and to Mr Peter John for doing so much of the technical work. C.H.T. wishes to acknowledge the personal assistance of Mr Donald Reid and Miss Elizabeth Shallcross.

#### REFERENCES

- Boas, F. (1933). *Hum. Biol.* **5**, 429.  
 Brash, J. C., McKeag, H. T. A. & Scott, J. H. (1956). *The Aetiology of Irregularity and Malocclusion of the Teeth*, 2nd ed. London: Dental Board of U.K.  
 Fábry, P. & Hruza, Z. (1956). *Physiologia bohemoslov.* **5**, Suppl. 10.  
 Garn, S. M., Lewis, A. B. & Blizzard, R. M. (1965). *J. dent. Res.* **44**, Suppl. to no. 1.  
 Hammond, J. (1932*a*). *Farm Animals: their Breeding, Growth and Inheritance*, 2nd ed. London: Arnold and Co.  
 Hammond, J. (1932*b*). *Growth and Development of Mutton Qualities in the Sheep*, p. 200. Edinburgh: Oliver and Boyd.  
 Hammond, J. (1950). *Proc. R. Soc. B* **137**, 452.  
 Hellman, M. (1923). *Dent. Cosmos* **65**, 34.  
 Laws, R. M. (1966). *E. Afr. Wildlife J.*, **4**, 1.  
 Lister, D. & McCance, R. A. (1965). *Br. J. Nutr.* **19**, 311.  
 Lister, D. & McCance, R. A. (1967). *Br. J. Nutr.* **21**, 787.  
 McCance, R. A. (1960). *Br. J. Nutr.* **14**, 59.  
 McCance, R. A. (1962). *Lancet* *ii*, 621.  
 McCance, R. A. (1964). *J. Pediat.* **65**, 1008.  
 McCance, R. A. (1966). *Tijdschr. soc. Geneesk.* **44**, 569.  
 McCance, R. A., Ford, E. H. R. & Brown, W. A. B. (1961). *Br. J. Nutr.* **15**, 213.  
 McCance, R. A. & Widdowson, E. M. (1962). *Proc. R. Soc. B* **156**, 326.  
 McCance, R. A. & Widdowson, E. M. (1966). *Wiss. Veröff. dt. Ges. Ernähr.* **15**, 74.  
 Owens, P. D. A. (1968). The effect of undernutrition and rehabilitation on the jaws and teeth in pigs. In *Calorie Deficiencies and Protein Deficiencies. Proceedings Glaxo Conference*. London: J. and A. Churchill.  
 Owens, P. D. A., Tonge, C. H. & McCance, R. A. (1965). *J. dent. Res.* **44**, 1159.

- Stack, M. V. (1964). *Biologia Neonat.* **6**, 197.  
 Tonge, C. H. & McCance, R. A. (1965). *Br. J. Nutr.* **19**, 361.  
 Trowell, H. C., Davies, J. N. P. & Dean, R. F. A. (1954). *Kwashiorkor*. London: Arnold Ltd.  
 Widdowson, E. M. & Kennedy, G. C. (1962). *Proc. R. Soc. B* **156**, 96.  
 Widdowson, E. M. & McCance, R. A. (1960). *Proc. R. Soc. B* **152**, 188.  
 Wiener, G. & Purser, A. F. (1957). *J. agric. Sci., Camb.* **49**, 51.

## EXPLANATION OF PLATES

## PLATE 1

- (a) A dissection of the lower jaw in a pig after 1 year of undernutrition. Notice (i) the thinness of the ramus and the lack of depth of the body of the mandible, (ii) the angulation of the incisors, (iii) the delayed shedding of the deciduous teeth and formation of the permanent teeth, (iv) the abnormal siting of the second permanent molar.
- (b) Photographs of the lower molar teeth at 3 years of age in fully rehabilitated pigs (above) and in normal pigs (below). Notice the relative proportions of the crowns and roots (see p. 363 for further details).

## PLATE 2

- (a) The maxilla of a normal pig 2.5 years old.
- (b) The maxilla of a fully rehabilitated hog showing moderate malocclusion and alignment. The second and third molars on the left are rotated and there is overcrowding in the premolar segments.

## PLATE 3

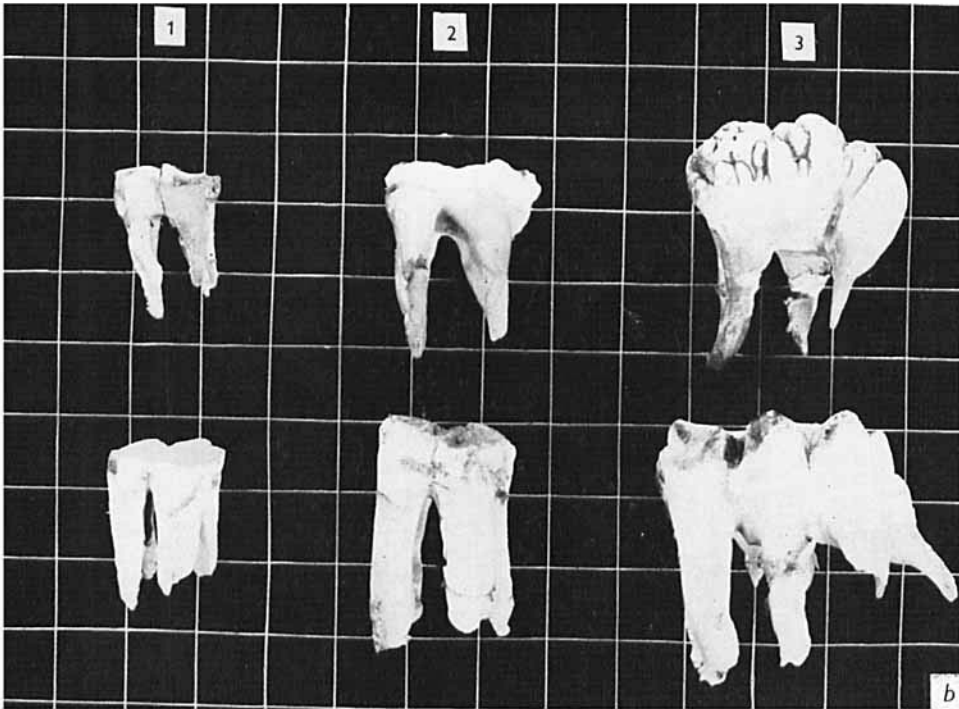
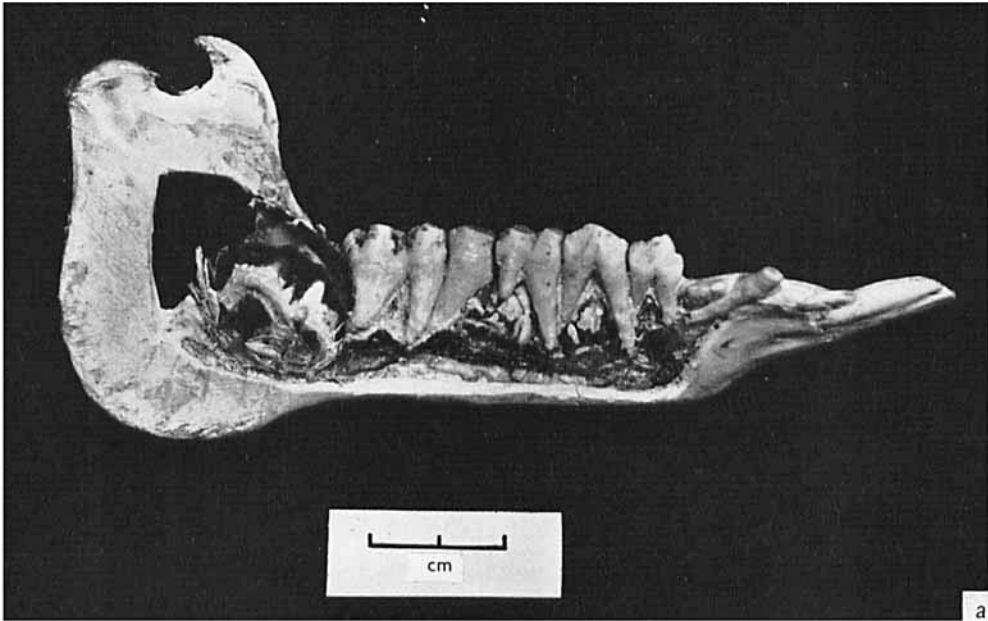
The mandible of a fully rehabilitated hog. The first and second molars are missing on the right-hand side and both third molars are rotated out of their normal alignment.

## PLATE 4

- (a) A ground section of a mesial root of the first permanent lower molar tooth of a pig undernourished for 1 year and rehabilitated for 8 months. *A*, dentine formed before rehabilitation; *B*, the junction between this and (*C*) dentine formed during rehabilitation. Note the irregularities and abnormalities in *B* and the incremental lines parallel to the junction tissue in *A* and more so in *C*.
- (b) A ground section of a mesial root of one of the first permanent lower molars of a pig undernourished for 1 year and rehabilitated for 8 months. Notice *A*, dentine with an irregular area in it which has been resorbed, probably as part of the migration of the tooth during rehabilitation. This area has been repaired and filled in by irregular and abnormally arranged cementum (*B, B*).
- (c) A ground section of a mesial root of a second permanent lower molar tooth from a pig undernourished for 1 year and rehabilitated for 1 year. The roots of this tooth were formed entirely during rehabilitation. *A*, normal external cementum; *B*, the dentine formed during the first stages of rehabilitation; *C*, the most recently formed dentine. There are notable incremental lines in *B*, parallel to the line of the cementum, but in *C* these have become very close together and most abnormal.

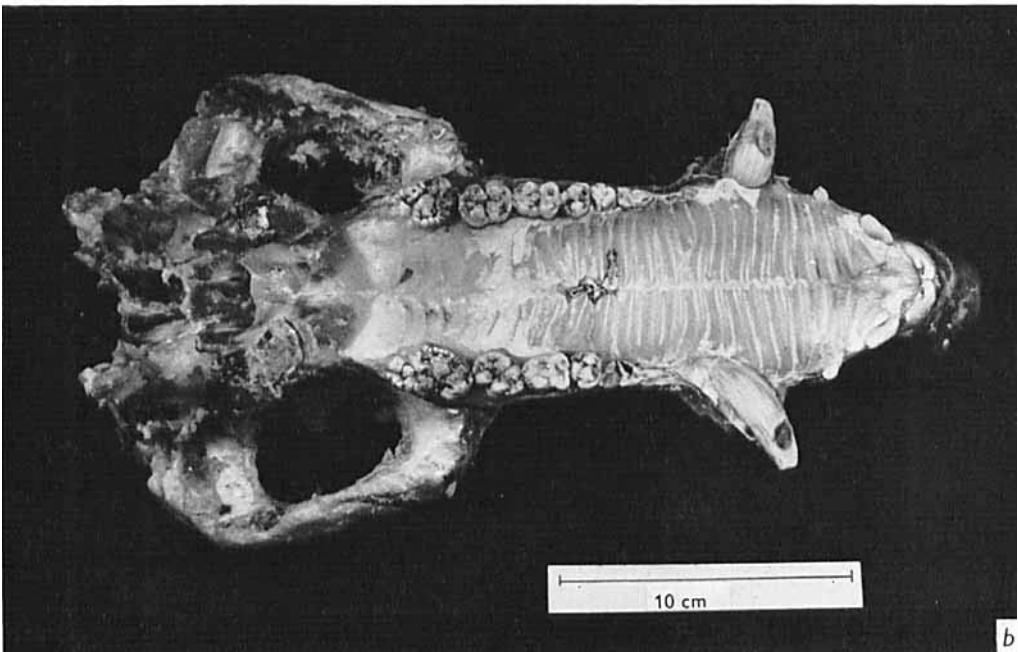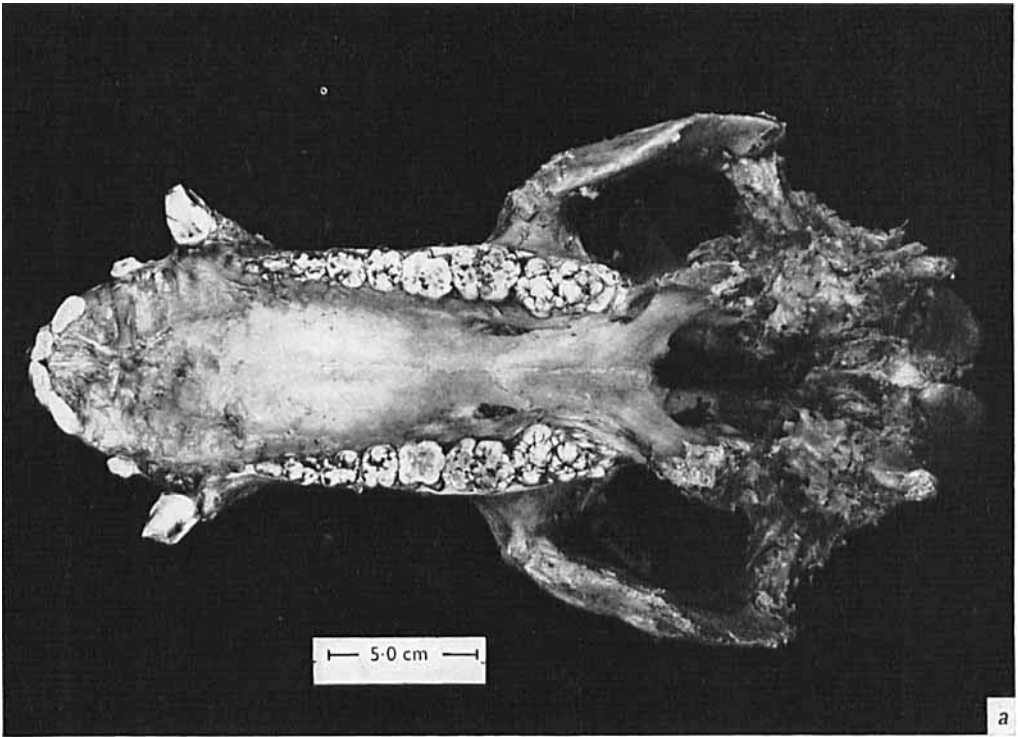
## PLATE 5

- (a) A ground section of a distal root of the first permanent upper molar tooth from a pig undernourished for 1 year and rehabilitated for 2 years. *A*, dentine of the root; *B*, extensive depositions of cementum surrounding the root, which probably assisted its retention in the jaw during the migration of the tooth; *C*, inter radicular area.
- (b) A ground section of a mesial root of the third permanent lower molar tooth of a pig undernourished for 1 year and rehabilitated for 2 years, 7 months. *A*, relatively normal dentine, whereas *B*, the most recently formed, is highly irregular with many incremental lines running parallel to the pulp cavity and multiple blobs of dark uncalcified interglobular material; *C*, is the pulp cavity.
- (c) A ground section of a mesial root of the second permanent upper molar tooth of a normal pig well-nourished from 3 years. *A*, dentine with; *B*, minor evidences of incremental lines; *C*, a pocket in the dentine which has been resorbed and filled with cementum. In the normal animals these are very rare.




R. A. McCANCE, P. D. A. OWENS AND C. H. TONGE


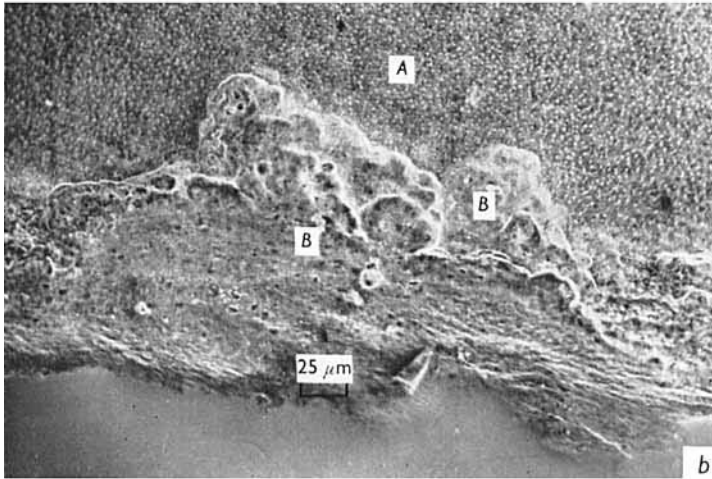

(Facing p. 368)





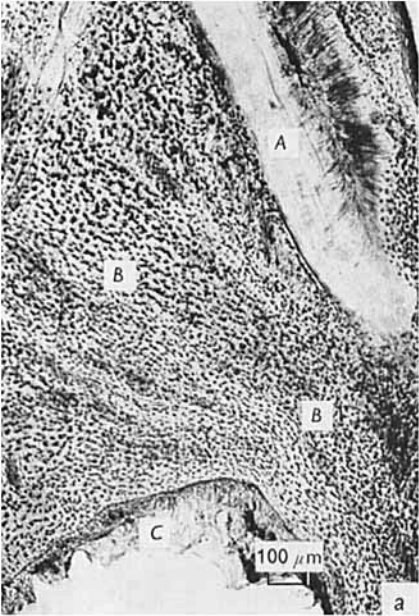
R. A. McCANCE, P. D. A. OWENS AND C. H. TONGE



R. A. McCANCE, P. D. A. OWENS AND C. H. TONGE







R. A. McCANCE, P. D. A. OWENS AND C. H. TONGE