

## O174

### Gray matter reduction in high-risk subjects, recently diagnosed and chronic patients with schizophrenia: A revised coordinate-based meta-analysis

C. Brasso<sup>1\*</sup>, D. Liloia<sup>2</sup>, F. Cauda<sup>2</sup>, L. Mancuso<sup>2</sup>, A. Nani<sup>2</sup>, J. Manuello<sup>2</sup>, T. Costa<sup>2</sup>, S. Duca<sup>3</sup> and P. Rocca<sup>1</sup>

<sup>1</sup>Department Of Neuroscience, University of Turin, Torino, Italy;

<sup>2</sup>Department Of Psychology, University of Turin, TORINO, Italy and

<sup>3</sup>Neuroradiology, Koelliker Hospital, Torino, Italy

\*Corresponding author.

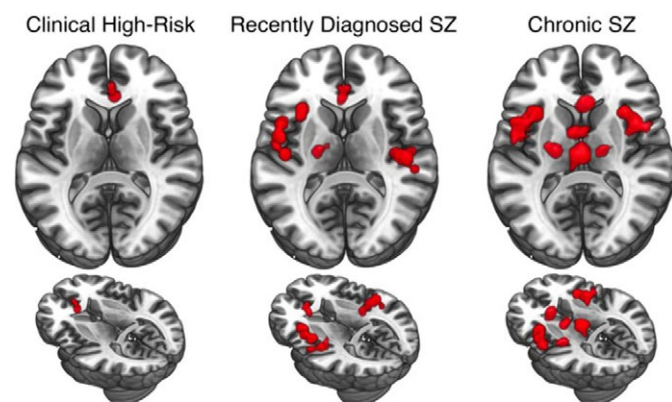
doi: 10.1192/j.eurpsy.2021.360

**Introduction:** Characterizing neuroanatomical markers of different stages of schizophrenia (SZ) to assess of how the disorder develops is extremely important for the clinical practice. It still remains uncertain how abnormalities are formed as SZ progresses.

**Objectives:** We reviewed and analyzed 113 voxel based morphometry studies on people at risk of or with schizophrenia to assess GM alterations at different stages of the disorder and to functionally characterize these GM variations.

**Methods:** We performed a meta-analysis of voxel-based morphometry studies of genetic and clinical high-risk subjects (g-/c-HR), recently diagnosed (RDSZ) and chronic SZ patients (ChSZ). We quantified gray matter (GM) changes associated with these four conditions and compared them with contrast and conjunctural data. We performed the behavioral analysis and networks decomposition of alterations to obtain their functional characterization.

**Results:** Compared to previous investigations, results reveal a robust cortical-subcortical, left-to-right homotopic progression of GM loss. The right anterior cingulate is the only altered region in all



a coordinate-based meta-analysis of different stages of schizophrenia highlights a clear progression of the grey matter damage

conditions. Contrast analyses show left-lateralized insular, amygdalar and parahippocampal GM reduction in RDSZ, which appears bilateral in ChSZ. An overlap between RDSZ and ChSZ is observed in the left insula, amygdala, precentral and inferior frontal gyri. Functional decomposition shows involvement of the salience network, with an enlargement of the sensorimotor network in RDSZ and the thalamus-basal nuclei network in ChSZ.

**Conclusions:** These results can help the research on diagnostic and neuroimaging biomarkers of SZ staging, as well as on the identification of new therapeutics neuroanatomic targets that could be addressed with focused magnetic or non-invasive electric stimulation.

**Disclosure:** No significant relationships.

**Keywords:** voxel-based morphometry; behavioral analysis; salience network; psychosis

## O173

### Chronotopic encoding of emotional dimensions in the human brain assessed by fMRI

G. Lettieri<sup>1\*</sup>, G. Handjaras<sup>1</sup>, E. Ricciardi<sup>2</sup>, P. Pietrini<sup>2</sup> and L. Cecchetti<sup>1</sup>

<sup>1</sup>Momilab - Sane Group, IMT School for Advanced Studies Lucca, Lucca, Italy and <sup>2</sup>Momilab, IMT School for Advanced Studies, Lucca, Italy

\*Corresponding author.

doi: 10.1192/j.eurpsy.2021.361

**Introduction:** Affective experiences vary as function of context, motivations and the unfolding of events. This temporal fundamental aspect of emotional processes is often disrupted in psychiatric conditions.

**Objectives:** To investigate how the brain represents the association between affect and time, we combined fMRI and behavioral ratings during movie watching.

**Methods:** Participants watched 'Forrest Gump' in the fMRI scanner (n=14, 6F). Data were preprocessed (see 10.1101/2020.06.06.137851v1) and average brain activity from 1000 regions was extracted. Independent subjects (n=12, 5F) provided continuous ratings of the intensity of their affective state while watching the same movie. Using PCA, we derived the first 3 affective dimensions (polarity, complexity, intensity; 10.1038/s41467-019-13599-z) and computed their time-varying correlation in windows from 5-1000tps. We identified the window size with the maximum between-subjects accordance and computed the inter-subject functional connectivity (10.1038/ncomms12141). For each region, we obtained connectivity strength and its association in time with changes in affective dimensions ( $p_{Bonf} < 0.05$ ).

**Results:** Fluctuations in connectivity strength of the right rMFG, precuneus, pSTS/TPJ, dmPFC, aINS and left pMTG were associated to polarity. Also, connectivity of the right IPS/SPL, SFG, dpreCS, IFGpOrb, OFC, precuneus, vpreCS and pSTS/TPJ followed the timecourse of perceived intensity of affect.

**Conclusions:** Connectivity strength of default mode represents the pleasantness of the experience, whereas attention and control networks encode its intensity. Emotional descriptions converge in right temporoparietal and fronto-polar cortex, where the stream of affect is encoded in a chronotopic manner. These results expand our understanding of the neural correlates of emotional processing, a function severely affected by mental disorders.

**Disclosure:** No significant relationships.

**Keywords:** affective timecourse; naturalistic stimulation; emotions; fMRI

## O174

### Multimodal magnetic resonance spectroscopy and surface-based morphometry study of individuals at ultra-high-risk for psychosis

A. Tomyshev<sup>1\*</sup>, P. Menshchikov<sup>2</sup>, M. Omelchenko<sup>3</sup>, V. Kaleda<sup>4</sup>, D. Kupriyanov<sup>2,5</sup> and I. Lebedeva<sup>1</sup>

<sup>1</sup>Laboratory Of neuroimaging And Multimodal Analysis, FSBSI Mental Health Research Center, Moscow, Russian Federation; <sup>2</sup>Clinical Science, LLC Philips Healthcare Russia, Moscow, Russian Federation; <sup>3</sup>Department Of Youth Psychiatry, FSBSI Mental Health Research Center, Moscow, Russian Federation; <sup>4</sup>Department Of Endogenous Mental Disorders, FSBSI Mental Health Research Center, Moscow, Russian Federation and <sup>5</sup>Neurocognitive Research Department, National Research Center "Kurchatov Institute", Moscow, Russian Federation

\*Corresponding author.

doi: 10.1192/j.eurpsy.2021.362

**Introduction:** Studies examining gamma-aminobutyric acid (GABA) or glutamate in ultra-high risk for psychosis (UHR) have shown conflicting results, and a number of multimodal studies examining associations between metabolite and structural characteristics is very limited.

**Objectives:** We aimed to investigate potential associations between GABA and glutamate levels and cortical thickness in the frontal lobe in UHR individuals and healthy controls (HC).

**Methods:** 20 male UHR individuals and 19 healthy controls (HC) underwent structural MRI and MR spectroscopy at 3T Philips scanner. T1-weighted images were processed via FreeSurfer 6.0 to quantify cortical thickness for selected frontal regions labeled according to Desikan atlas. MEGA-PRESS acquisitions were analyzed with jMRUI (ver. 5.1 Alpha), levels of GABA and glutamate were calculated as ratios to creatine + phosphocreatine.

**Results:** The study revealed: 1) GABA/Cr ratios reduction in the left frontal lobe ( $p=0.001$ ) which was not attributable to antipsychotic medication; 2) cortical thickness reductions in the left pars orbitalis ( $p=0.005$ ) (the anterior part of the inferior frontal gyrus) in the UHR individuals compared to HC. No significant correlations between GABA/Cr ratios and cortical thickness were identified in both groups.

**Conclusions:** The findings indicate that the UHR state is associated with altered GABA levels and cortical thickness reductions in the prefrontal cortex. The results also show that GABA levels are not directly related to cortical abnormalities, suggesting that altered metabolite levels may be associated with a complex system of structural and functional impairments, rather than directly correlating with structural changes in separate cortical regions. The work was supported by RFBR grant 19-29-10040.

**Disclosure:** No significant relationships.

**Keywords:** Magnetic resonance spectroscopy; GABA; Cortical thickness; Ultra-high risk of psychosis

## O175

### Cortical thickness abnormalities in long-term remitted cushing's disease

S. Bauduin<sup>1\*</sup>, Z. Van Der Pal<sup>1</sup>, A. Pereira<sup>2</sup>, O. Meijer<sup>2</sup>, E. Giltay<sup>1</sup>, N. Van Der Wee<sup>1</sup> and S. Van Der Werff<sup>1</sup>

<sup>1</sup>Department Of Psychiatry, Leiden University Medical Center, Leiden, Netherlands and <sup>2</sup>Department Of Endocrinology, Leiden University Medical Center, Leiden, Netherlands

\*Corresponding author.

doi: 10.1192/j.eurpsy.2021.363

**Introduction:** Remitted Cushing's disease (RCD)-patients commonly continue to present persistent psychological and cognitive deficits, and alterations in brain function and structure. Assessing cortical thickness and surface area of RCD-patients may offer further insight into the neuroanatomical substrates of Cushing's disease.

**Objectives:** To assess cortical thickness and surface area in RCD-patients in comparison to healthy controls (HCs).

**Methods:** Structural 3T MRI's were obtained from 25 long-term RCD-patients, and 25 age-, gender-, and education-matched HCs. T1-weighted images were segmented to extract mean cortical thickness and surface area values of 68 cortical gray matter regions. Paired sample t-tests explored differences between the anterior cingulate cortex (ACC; region of interest), and the whole brain. Validated scales assessed psychiatric symptomatology, self-reported cognitive functioning, and disease severity.

**Results:** After correction for multiple comparisons, ROI analyses indicated that RCD-patients showed reduced cortical thickness of the left caudal ACC and the right rostral ACC compared to HCs. Whole-brain analyses indicated thinner cortices of the left caudal ACC, left cuneus, left posterior cingulate cortex, right rostral ACC, and bilateral precuneus compared to HCs. No cortical surface area differences were identified. Cortical thickness of the left caudal ACC was inversely associated with anxiety symptoms and disease duration.

**Conclusions:** In six of 68 regions examined, RCD patients had reduced cortical thickness in comparison to HCs. Cortical thickness of the left caudal ACC was inversely associated with disease duration, suggesting that prolonged and excessive exposure to glucocorticoids may be related to cortical thinning of brain structures involved in emotional and cognitive processing.

**Disclosure:** No significant relationships.

**Keywords:** Neuroimaging; Cushing's Disease; endocrinology; Psychiatric symptomatology

## Neuroscience in psychiatry

## O178

### Association between abnormal fetal head growth and autism spectrum disorder

O. Regev<sup>1</sup>, G. Cohen<sup>1</sup>, A. Hadar<sup>2</sup>, G. Meiri<sup>3</sup>, H. Flusser<sup>4</sup>, A. Michaelovskii<sup>4</sup>, I. Dinstein<sup>5</sup>, R. HersHKovitz<sup>6</sup> and I. Menashe<sup>1\*</sup>

<sup>1</sup>Department Of Public Health, Ben-Gurion University of the Negev, Beer Sheva, Israel; <sup>2</sup>Department Of Obstetrics And Gynecology, Clalit Health Services, Beer Sheva, Israel; <sup>3</sup>Child Psychiatry, Soroka University Medical Center, Beer Sheva, Israel; <sup>4</sup>Child Development Center, Soroka University Medical Center, Beer Sheva, Israel; <sup>5</sup>Department Of Psychology, Ben-Gurion University of the Negev, Beer Sheva, Israel and <sup>6</sup>Department Of Obstetrics And Gynecology, Soroka University Medical Center, Beer Sheva, Israel

\*Corresponding author.

doi: 10.1192/j.eurpsy.2021.364