

## Letter to the Editor: New Observation

# Subarachnoid Hemorrhage as a Delayed Manifestation of Reperfusion Injury Seven Weeks Following Carotid Endarterectomy

Jesmeen K. Deo<sup>1</sup> , Donatella Tampieri<sup>2</sup>  and Bryce A. Durafourt<sup>1</sup> 

<sup>1</sup>Division of Neurology, Department of Medicine, Queen's University and Kingston Health Sciences Centre, Kingston, ON, Canada and <sup>2</sup>Department of Radiology, Queen's University and Kingston Health Sciences Centre, Kingston, ON, Canada

**Keywords:** Carotid endarterectomy; stroke; cerebral hyperperfusion syndrome; reperfusion injury; subarachnoid hemorrhage

Cerebral hyperperfusion syndrome (CHS) is an uncommon complication following carotid artery revascularization. The syndrome is characterized by headache, neurological deficits, and seizures in the absence of another etiology such as new infarct, artery re-occlusion, or pharmacological cause.<sup>1</sup> Post-operative hypertension is a main contributor. When increased blood flow is uncontrolled, intracranial hemorrhage in the previously hypoperfused area is associated with significant morbidity (30% disabled, 50% mortality).<sup>2</sup> Subarachnoid hemorrhage (SAH) as a presentation of CHS is rare, with only ten cases reported in the literature ranging from mild SAH with complete recovery to more extensive SAH causing death.<sup>3</sup>

The risk of CHS is cited from 1%–7% following a carotid procedure.<sup>4</sup> Time to onset is varied but typically within a few days, with a peak incidence at 12 hours after carotid artery stenting (CAS) and 6 days after carotid endarterectomy (CEA).<sup>5</sup> It has been accepted that CHS can occur up to 1-month post-revascularization. Only two cases have been described with very delayed CHS, here defined as 3 weeks or longer following revascularization (Table 1). Here, we describe a case of CHS presenting with SAH more than 7 weeks following CEA.

A 65-year-old male with a history significant for smoking (100 pack-year), alcohol use, dyslipidemia, hypertension, and remote right-sided occipital epidermoid cyst removal initially presented with transient symptoms of left-sided paresthesias ongoing for several months. A non-contrast CT scan of the head revealed a chronic infarct in the right precentral gyrus, as well as in the right superior and inferior parietal lobule (Fig. 1a). He was started on clopidogrel. Twenty-four days after the initial CT scan, he presented to the emergency department (ED) with similar transient symptoms, at which point CT angiography (CTA) revealed 85% stenosis at the origin of the right internal carotid artery (ICA) (Fig. 1b). He was subsequently referred to Vascular Surgery and underwent a right carotid endarterectomy three weeks later. There were no immediate complications, his blood pressure was well controlled, and he was discharged home the next day on dual antiplatelet therapy. In follow-up, he continued to be asymptomatic; therefore, he was switched to ASA only on post-operative day 13.

Fifty-two days following his CEA, the patient re-presented to the ED with recurrence of paresthesias of the left arm, leg, and lower jaw which were similar to his original presentation prior to the CEA. Initial blood pressure at the time of presentation was 154/85 mmHg. A CT/CTA of the head demonstrated a small volume SAH in the central sulcus at the location of his previous infarct (Fig. 1c) and no residual ICA stenosis (Fig. 1d). An MRI of the brain was performed to explore other potential causes of SAH, such as hemorrhagic transformation of an acute stroke, reversible cerebral vasoconstriction syndrome, posterior reversible encephalopathy syndrome (PRES), cerebral amyloid angiopathy (CAA), or vascular abnormalities. However, no other etiology for the hemorrhage was clearly identified (Fig. 1e–g).

The patient's symptoms abated upon arrival, but he continued to have transient episodes of the same symptoms over the course of his admission. Repeat CT scan on day 2 of admission did not show any adverse interval change. Electroencephalogram (EEG) did not demonstrate any epileptiform activity. Blood pressure was controlled at SBP < 140 mmHg for the duration of his admission and his ASA was held.

A broad differential was explored to investigate this patient's clinical and radiological findings. Imaging was not suggestive of new infarct, PRES, CAA, or vascular abnormality. Focal seizures remained a diagnostic possibility despite the normal EEG. There was no perfusion imaging performed at the time of presentation to confirm increased cerebral perfusion; however, given the location of the hemorrhage in the territory of previous infarct with no evidence of superimposed acute infarct, reperfusion injury was felt to be the most likely etiology. The acute onset of recurrence of the paresthesias, while similar to the initial symptoms the patient experienced prior to the CEA, makes it less likely for the hemorrhage to represent an incidental finding.

The patient was discharged home without clinic deficit. At outpatient follow-up twenty-three days later, he reported ongoing intermittent mild transient symptoms, and no repeat imaging was available to confirm resolution of the initial associated vasogenic edema.

**Corresponding author:** B. A. Durafourt; Email: [bryce.durafourt@kingstonsc.ca](mailto:bryce.durafourt@kingstonsc.ca)

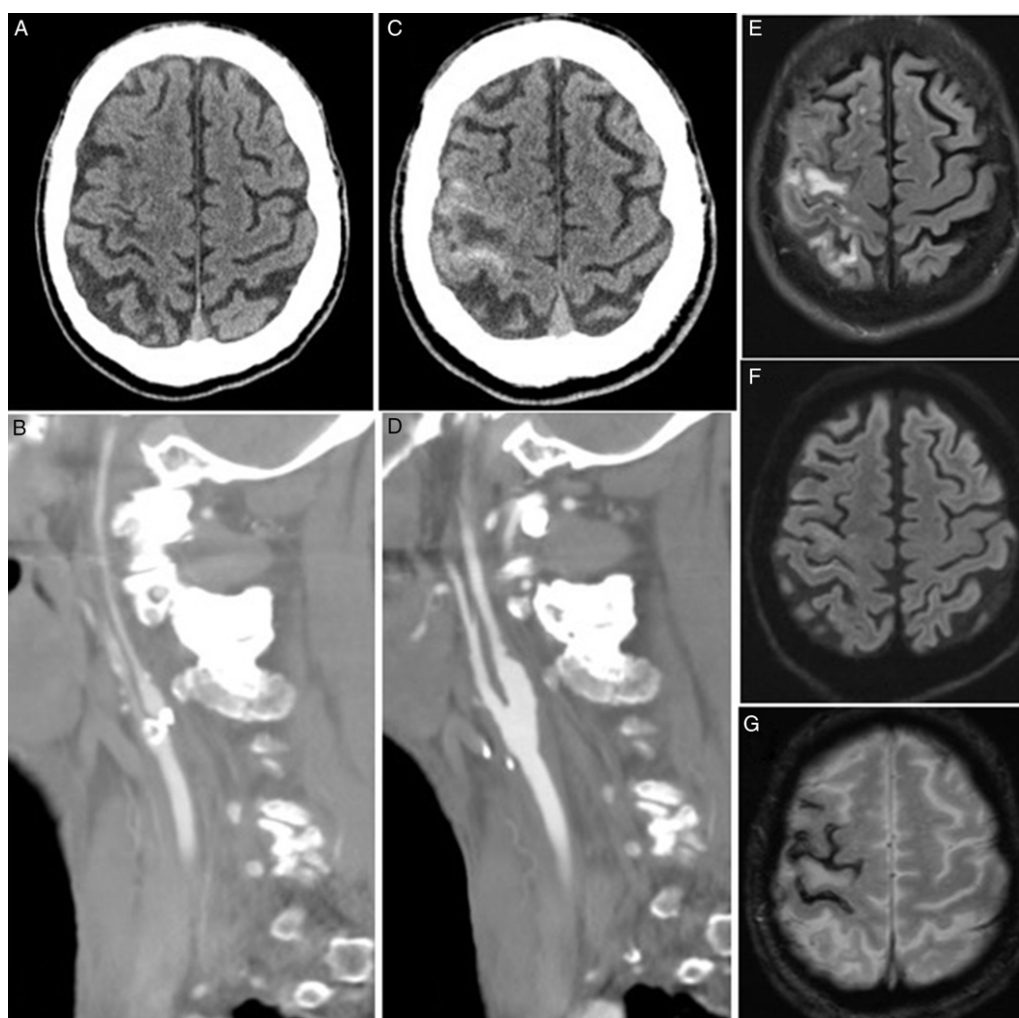
**Cite this article:** Deo JK, Tampieri D, and Durafourt BA. Subarachnoid Hemorrhage as a Delayed Manifestation of Reperfusion Injury Seven Weeks Following Carotid Endarterectomy. *The Canadian Journal of Neurological Sciences*, <https://doi.org/10.1017/cjn.2023.294>

© The Author(s), 2023. Published by Cambridge University Press on behalf of Canadian Neurological Sciences Federation. This is an Open Access article, distributed under the terms of the Creative Commons Attribution licence (<http://creativecommons.org/licenses/by/4.0/>), which permits unrestricted re-use, distribution and reproduction, provided the original article is properly cited.

**Table 1:** Reported cases of delayed CHS which occurred 3 weeks or longer following revascularization

| Reference   | Age/Sex | Patient profile  | CEA or CAS   | Time After procedure | Presentation   | Imaging findings   | Outcome after treatment                                       |
|---|---------|--|--------------|----------------------|--|--|---|
| Ogasawara et al., Neurosurgery (2004) 54(5):1258–1262               | 66 M    | HTN, 95% stenosis R ICA  | CEA of R ICA | 29 days              | L motor seizures with secondary generation (SBP 152) | SPECT imaging performed Day 30 after CEA demonstrated reappearance of hyperperfusion, worsened as compared to Day 28 when SBP had been under close monitoring. T2 MRI sequence: hyperintense lesions in right cerebral hemisphere. | Imaging findings resolved. Discharged home, back to baseline. |
| Oh et al., Journal of Korean Neurological Society (2014) 56(5):441. | 67 F    | HTN, T2DM. 73% stenosis L ICA, total occlusion R proximal ICA, 70% stenosis both vertebral artery orifices | CAS of L ICA | 21 days              | Status epilepticus (SBP 190)                         | FLAIR MRI sequence: hyperintense lesions in left cerebral hemisphere. CT perfusion – increased flow at the time of CHS presentation, improved but still hyperperfused at 24 days.  | Imaging findings resolved. Discharged home, back to baseline. |

HTN = hypertension; SBP = systolic blood pressure; T2DM = type 2 diabetes mellitus.



**Figure 1:** *a.* Initial CT scan of the head without contrast, demonstrating the chronic ischemic lesion in the right precentral gyrus; *b.* Initial CTA demonstrating the heavily calcified atherosclerotic plaque at the right internal carotid artery origin resulting in near total occlusion; *c.* Follow-up CT without contrast showing new right CEA linear leptomeningeal hemorrhage in the right precentral and central sulcus; *d.* Follow-up CTA demonstrating excellent result of the right CEA without residual stenosis; MRI sequences FLAIR (*e.*), DWI (*f.*), GRE (*g.*), demonstrating lack of diffusion restriction and diffuse leptomeningeal siderosis. The hypodensity in the precentral gyrus in the follow-up CT (*c.*) and MRI (*E, F, G*) is in keeping with focal vasogenic edema due to the lack of restriction in DWI and focal swelling of the gyrus.

The pathophysiology of CHS is not well understood. One proposed mechanism is that of impaired autoregulation developing due to longstanding hypoperfusion in ischemic cortex.<sup>6</sup> When revascularized, chronically dilated vessels are then exposed to sudden uncontrolled high flow. Another possible mechanism is that reperfusion appears to cause an increase in nitric oxide and free radicals.<sup>5</sup> This process is thought to be further exacerbated by chronic hypertension, which leads to damage of the blood-brain barrier and predisposes to edema.<sup>2,5</sup> The most significant risk factor identified is post-operative systolic blood pressure above 150 mmHg; close control of blood pressure is of particular importance in high-risk groups.<sup>1</sup> Despite this, there is no standard duration for monitoring blood pressure after the procedure.

This case of CHS more than seven weeks post-carotid revascularization suggests that the risk of reperfusion injury may persist beyond the traditionally accepted time frame. The risk factors for delayed susceptibility remain unclear, and therefore while it is rare, patients presenting with new or recurrent symptoms in the revascularized hemisphere should be evaluated for CHS.

**Author contribution.** All authors have seen and approved the content of the submission, and all have contributed significantly to the work. J.D. and B.D. were involved in the clinical care of the patient, prepared the written case report, and performed the initial literature review. D.T. reviewed and prepared the

images for the case, performed additional literature review, and reviewed and edited the manuscript.

**Funding.** None.

**Competing interests.** None.

## References

1. Bouri S, Thapar A, Shalhoub J, et al. Hypertension and the post-carotid endarterectomy cerebral hyperperfusion syndrome. *Eur J Vasc Endovasc Surg.* 2011;41:229–37. DOI: [10.1016/j.ejvs.2010.10.016](https://doi.org/10.1016/j.ejvs.2010.10.016).
2. Farooq MU, Goshgarian C, Min J, Gorelick PB. Pathophysiology and management of reperfusion injury and hyperperfusion syndrome after carotid endarterectomy and carotid artery stenting. *Exp Transl Stroke Med.* 2016;8:7. DOI: [10.1186/s13231-016-0021-2](https://doi.org/10.1186/s13231-016-0021-2).
3. Leclerc A, Goia A, Gilard V, Derrey S, Cury S. Massive non-aneurysmal subarachnoid hemorrhage after cervical carotid angioplasty and stenting: a case report and review of the literature. *Neurochirurgie.* 2022;68:342–6. DOI: [10.1016/j.NEUCHI.2021.04.003](https://doi.org/10.1016/j.NEUCHI.2021.04.003).
4. Lieb M, Shah U, Hines GL. Cerebral hyperperfusion syndrome after carotid intervention. *Cardiol Rev.* 2012;20:84–9. DOI: [10.1097/CRD.0b013e318237eef8](https://doi.org/10.1097/CRD.0b013e318237eef8).
5. Lin Y-H, Liu H-M. Update on cerebral hyperperfusion syndrome. *J Neurointerv Surg.* 2020;12:788–93. DOI: [10.1136/neurintsurg-2019-015621](https://doi.org/10.1136/neurintsurg-2019-015621).
6. Waltz AG. Effect of blood pressure on blood flow in ischemic and in nonischemic cerebral cortex. *Neurology.* 1968;18:613. DOI: [10.1212/WNL.18.7.613](https://doi.org/10.1212/WNL.18.7.613).