



Letter to the Editor: New Observation

Virtual Reality Visualization of an Epidermoid Cyst Causing Intracranial Hypertension

Azza S. Reda^{1,2} , Rafael Glikstein^{1,2}, Vered Tsehmaster-Abitbul^{1,2}, Teresa Flaxman³, Dan J. La Russa⁴ and Eduardo Portela de Oliveira^{1,2} 

¹Department of Radiology, Radiation Oncology and Medical Physics, University of Ottawa, Ottawa, ON, Canada, ²Neuroradiology Section, Department of Medical Imaging, The Ottawa Hospital, The Ottawa Hospital Research Institute, Ottawa, ON, Canada, ³Department of Radiology, Radiation Oncology and Medical Physics, The Ottawa Hospital Research Institute, Clinical Epidemiology Program, University of Ottawa, Ottawa, ON, Canada and ⁴Department of Medical Imaging, Radiation Oncology and Medical Physics, Radiation Medicine Program, University of Ottawa, Ottawa, ON, Canada

Keywords: Neuroradiology; brain tumors; virtual reality

Intradiploic epidermoid cysts are rare tumors that may occur anywhere in the skull bones. Epidermoid cysts are composed of remnant ectodermal cells and have been reported to account for less than 1% of all primary bone tumors.¹ They are slow-growing, painless lesions but can be symptomatic based on location and size. Occipital intradiploic epidermoid cysts have been described as a cause of intracranial hypertension due to mass effect and compression of the dural venous sinuses.² Complete surgical resection is the treatment of choice to relieve the symptoms.³

While conventional neuroimaging techniques, such as computed tomography (CT) and magnetic resonance images (MRI), remain the workhorse for diagnosing epidermoid cysts. Recent advances in imaging techniques, such as virtual reality (VR), have opened new avenues for assessing these lesions.^{3–5} Here we report on a case of a 24-year-old male presenting with long-standing

headache and peripheral vision loss lasting for < 1hr with exertion, spontaneously resolving upon rest. He was otherwise healthy and taking no medications. Clinical examination showed bilateral papilledema.

Magnetic resonance imaging of the brain (Fig. 1) demonstrated a well-defined occipital intradiploic lesion, slightly hyperintense signal to the cerebral spinal fluid on T1-W, high signal on T2-W and FLAIR, and peripheral areas of T1 hypersignal. The lesion shows restricted diffusion on DWI and no enhancement, helping to differentiate it from other benign lesions like dermoid, hemangioma, and aneurysmal bone cysts. The cyst causes mass effect on the occipital lobe and right cerebellum with mild right tonsillar herniation. There is also a mass effect on the dural venous sinuses at the level of the torcula with compression of the superior sagittal and transverse sinuses, also seen additionally with the VR

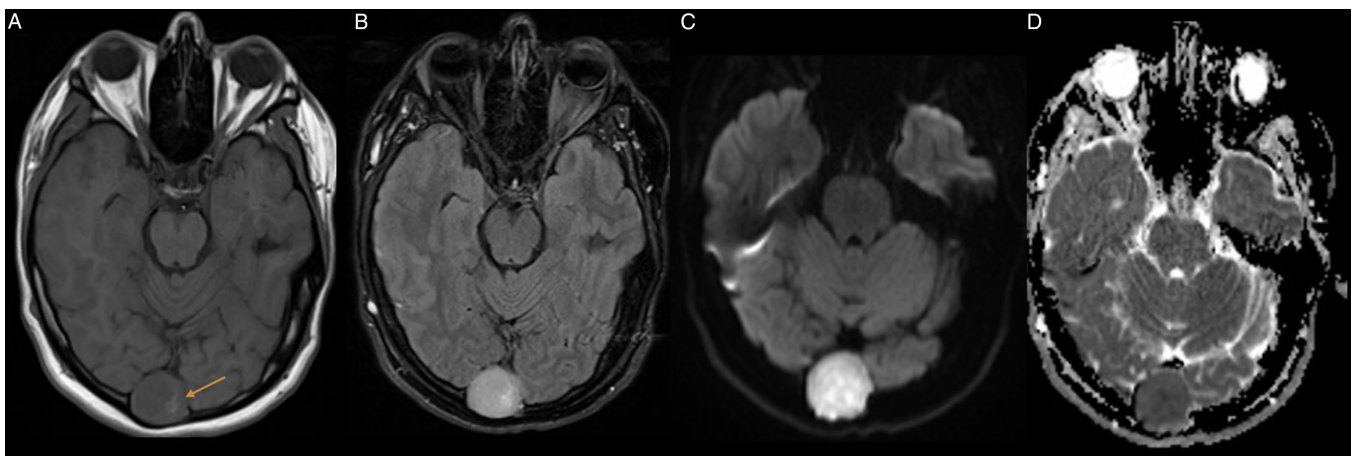


Figure 1: MRI of the brain. **a)** Axial T1 pre contrast shows intradiploic occipital mass with low signal intensity and peripheral linear high signal could be blood, calcification, or proteinaceous material (Arrow). **b)** Axial FLAIR lesion shows high signal intensity. **c)** and **d)** Axial DWI and ADC show restricted diffusion.

Corresponding author: E. Portela de Oliveira; Email: eporteladeoliveira@toh.ca

Cite this article: Reda AS, Glikstein R, Tsehmaster-Abitbul V, Flaxman T, La Russa DJ, and Portela de Oliveira E. (2024) Virtual Reality Visualization of an Epidermoid Cyst Causing Intracranial Hypertension. *The Canadian Journal of Neurological Sciences* 51: 886–887, <https://doi.org/10.1017/cjn.2023.305>

© The Author(s), 2023. Published by Cambridge University Press on behalf of Canadian Neurological Sciences Federation. This is an Open Access article, distributed under the terms of the Creative Commons Attribution licence (<http://creativecommons.org/licenses/by/4.0/>), which permits unrestricted re-use, distribution and reproduction, provided the original article is properly cited.

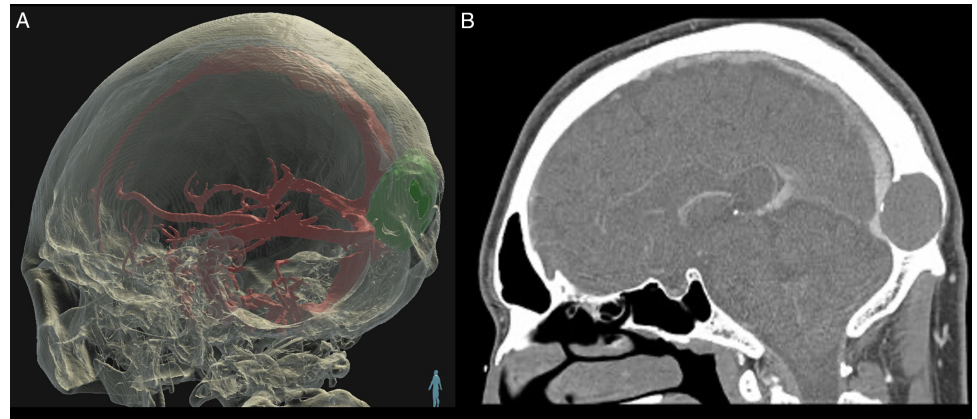


Figure 2: Virtual reality image (Elucis, Realize Medical Inc, Ottawa, Canada) showing a three-dimensional model of the occipital intradiploic epidermoid compressing the posterior one-third of the superior sagittal sinus and the torcula (a). These 3D anatomical models were generated from the accompanying sagittal CT venogram (b).

visualization and enhanced CT brain (Fig. 2). A diagnosis of an intradiploic epidermoid cyst was made based on these imaging features. The patient underwent surgical resection of the lesion with occipital craniectomy for treatment of patient's symptoms. Pathology results confirmed the diagnosis of an intradiploic epidermoid cyst. The patient had complete resolution of papilledema after surgery.

The 3D VR model offered unparalleled insights into the cyst's features, supporting precise localization and mapping of surrounding neurovascular structures. The 3D anatomical models shown in the VR software (Elucis, Realize Medical Inc., Ottawa, Canada) were segmented from the sagittal CT venogram (Fig. 2) and axial T1 MRI directly within the VR environment by a member of the 3D advanced visualization lab at The Ottawa Hospital. These two images were also positionally registered in the VR software using a built-in rigid image registration process prior to modeling. In addition to 3D visualization in VR, members of the radiology and surgery team have the ability to conduct measurements of the lesion and adjacent critical structures.

Supplementary material. The supplementary material for this article can be found at <https://doi.org/10.1017/cjn.2023.305>.

Competing interests. None.

References

1. Moreira-Holguin JC, Medélez-Borbonio R, Quintero-Lopez E, García-González U, Gómez-Amador JL. Intradiploic epidermoid cyst with intracranial hypertension syndrome: report of two cases and literature review. *Int J Surg Case Rep.* 2015;16:81–6.
2. Park BH, Lee HS, Lee JS. Occipital intradiploic epidermoid cyst with intracranial hypertension. *J Korean Neurosurg Soc.* 2006;40:377–80.
3. Kumaran SP, Gupta K, Priyadarshini H, Ghosal N. Giant intradiploic epidermoid cyst of occipital bone: a case report and literature review. *Neuroradiol J.* 2010;23:707–10.
4. Alaraj A, Luciano CJ, Bailey DP, et al. Virtual reality cerebral aneurysm clipping simulation with real-time haptic feedback. *Neurosurgery.* 2015; 11:52–8.
5. Bernardo A. Virtual reality and simulation in neurosurgical training. *World Neurosurg.* 2017;106:1015–29.