

Familial Spastic Ataxia Associated With Ehlers-Danlos Syndrome With Platelet Dysfunction

C. Chouza, J.L. Caamaño, O. De Medina, J. Bogacz, C. Oehninger, R. Vignale, G. De Anda, E. Novoa, R. De Bellis, H. Cardozo, B. Crispino, S. Romero, H. Correa, S. Feres

ABSTRACT: Four members of a family with consanguineous relationships, the proband and his three children (2 sons and 1 daughter) are affected with Familial Spastic Ataxia and with Ehlers-Danlos' Syndrome with platelet aggregation dysfunction. In the four cases, this exceptional association appears remarkably homogeneous both in clinical and laboratory studies. The two syndromes are of dominant-autosomal transmission and probably originated in a new mutation which presumably maintained a genetic linkage. Spastic ataxia is characterized by a precocious onset and a slow evolution. The first-born son shows a dominant pyramidal syndrome with mild ataxia suggesting that it is a transitional form of familial spastic paraplegia. The Ehlers-Danlos syndrome pertains to form II or "mitis" with moderate skin hyperelasticity and joint hypermobility. The abnormal platelet aggregation curves have the same profile in all the patients. The first-born son also presents a mitral valve prolapsus as we may find either in Ehlers-Danlos syndrome or in spastic ataxia.

The neurophysiological, tomographical, histological, ultrastructural and biochemical studies attempt to accomplish a better definition of these associated nosological entities.

RÉSUMÉ: Dans une famille avec des rapports de consanguinité, quatre de ses membres, le "proband" et ses trois enfants (deux hommes et une femme) sont atteints d'une ataxie spastique et du syndrome d'Ehlers-Danlos avec déficit d'agrégation des plaquettes. Cette extraordinaire association montre des aspects cliniques et de laboratoire très homogènes dans les quatre cas. Les deux syndromes se transmettent d'une manière autosomale dominante et originent probablement dans une nouvelle mutation qui maintient peut-être un lien génétique. L'ataxie spastique se caractérise par un début très précoce et une lente évolution. L'aîné montre un syndrome pyramidal dominant avec une légère ataxie, ce qui suggère une forme transitionnelle avec la paraplégie spastique familiale. Le syndrome d'Ehlers-Danlos correspond à la forme II ou "mitis" avec une hyperélasticité modérée de la peau et une hypermobilité articulaire. Les courbes anormales d'agrégation des plaquettes ont le même profil chez tous les patients. L'aîné montre un prolapsus de la valve mitrale tel que nous pouvons le trouver dans le syndrome d'Ehlers-Danlos ainsi que dans l'ataxie spastique. Les études neurophysiologiques, tomographiques, histologiques, ultrastructurelles et biochimiques essaient de définir le mieux possible cette association d'entités nosologiques.

Can. J. Neurol. Sci. 1984; 11:541-549

The Ehlers-Danlos' Syndrome (Ehlers, 1901; Danlos, 1908) or hyperelastic cutis is a disorder of the connective tissue produced by a biochemical disturbance of collagen, of hereditary nature and usually of dominant autosomic transmission. The clinical expression comprises thin, soft, hyperelastic and frail skin with defective cicatrization associated to articular hypermobility and the risk of luxation. Arachnodactyly, muscular hypotonia, Kypho-scoliosis and cutaneous molluscum pseudotumours are frequent components of the syndrome. Some of the complications we may observe are multiple arterial aneurysms and dissecting aortic ectasis. Various congenital malformations may appear such a hypertelorism, epicanthus, syndactylism

and cardiac defects. Some forms of the syndrome are accompanied by hemostatic disturbances. With a significant incidence of 10 to 20% (Aita, 1972), Ehlers-Danlos' syndrome is associated with various neurological syndromes such as mental deficiency, marked hypotonia, epilepsy, multiple neurofibromatosis (Goodman et al., 1962), acute multiple brachial neuropathy (Kayed and Kass, 1979) and, exceptionally, to spino-cerebellar degeneration (Aita, 1972).

We present a family with a consanguineous relationship whose proband and three children suffer from spastic ataxia of precocious onset associated to Ehlers-Danlos syndrome with platelet aggregation dysfunction. To our knowledge this is the first

report of this kind of association. This unusual nosologic presentation is transmitted in dominant autosomic form and its clinical and laboratory data are of remarkable homogeneity in the four patients.

CLINICAL STUDY

The family lives in the city of San Carlos some 140 kilometers' distance from Montevideo, Uruguay's main city.

We can see in the family pedigree (Fig. 1) a consanguineous relationship between the proband's parents and also between the proband and her first husband. The proband (Case 1) and her three children (Cases 2, 3 and 4) are affected. There are no previous known cases of these diseases in the family. The neurological examination was completed with the Ataxias' Scale of Pourcher and Barbeau (1980), rating the Total Score (maximum of 138) and the Functional Staging (0-5) in each case.

AUTOSOMAL DOMINANT SPASTIC ATAXIA

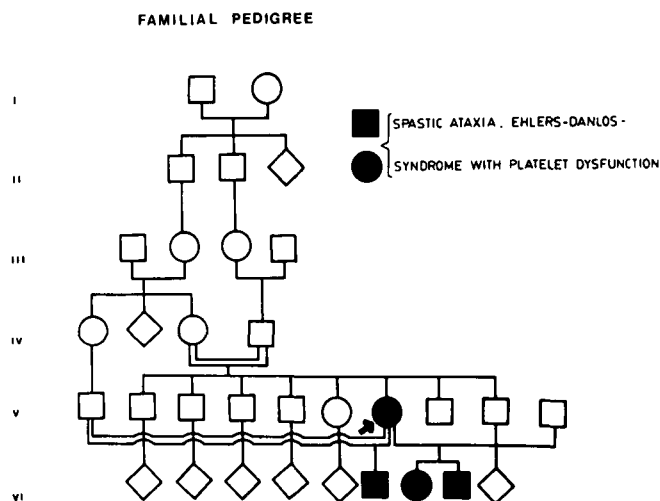


Figure 1

CASE REPORTS

Case 1: The proband (Fig. 2) N.P. 38 years old. Female. Caucasian. Left-handed. When she was 3 years old her left foot progressively became deformed in varus; the same symptom appeared in her right foot 3 years later accompanied by weakness of both feet, unsteadiness of gait and repeated falls. At the age of 7 she noticed incoordination of movement and tremor, and at age 13 she had dysarthria and progressive ataxia of gait; two years later she needed help for walking. These symptoms had a slow progression and, at present, the patient uses a wheel-chair although sometimes she may walk some steps with the aid of a special walking cane.

Past history: BK pleuritis when 15 years old. Physical examination: Tall and thin with long arms and fingers. Epicanthus. Skin: Thin, soft, hyperelastic, folding easily (Fig. 3). The translucency of the skin permits visualization of the superficial vascular system. Multiple molluscum. Large "cafe au lait" spot on cervical left side. Torpid post-traumatic lesions in lower limbs. Joints: Hyperextensibility most marked in distal joints. Mild dorso-lumbar scoliosis.

Neurological examination: Normal intellect. Mild dysarthria. Severe myopia, higher on the right eye. Fundus: severe myopic signs with

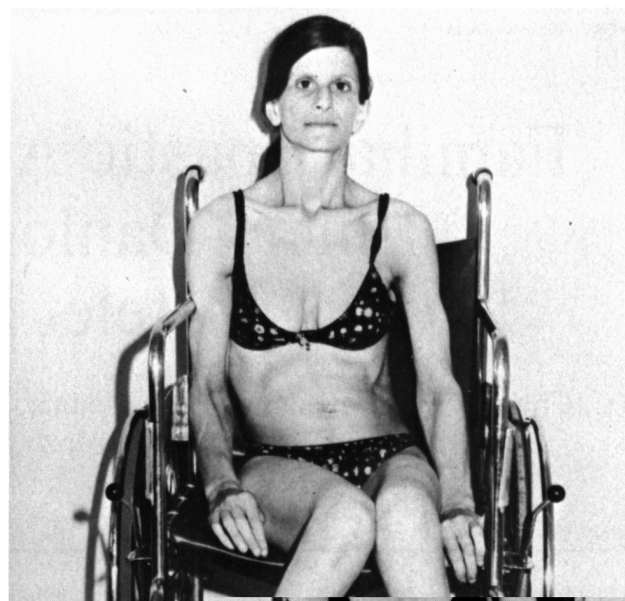


Figure 2

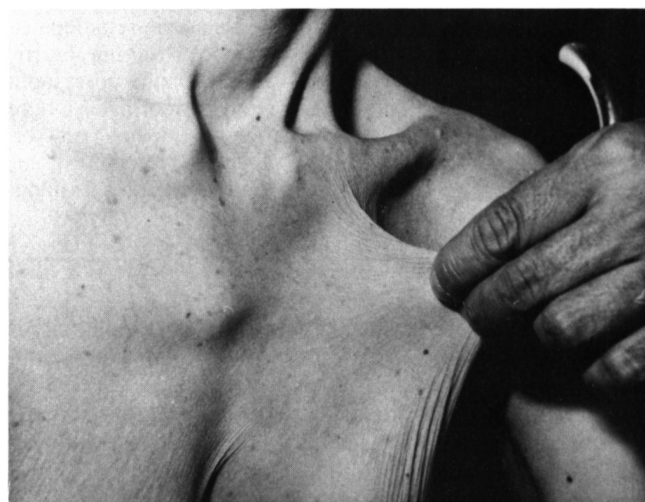

Figure 3

diffuse choroiditis. Visual field with colours: normal. Bilateral rotatory nystagmus in primary position. Transient convergent strabismus. Irregular conjugate pursuit ocular movements in lateral gazes. Enhanced mandibular reflex. Upper limbs: hyperextensibility and muscle hypotonia. Normal muscle strength and tendinous reflexes. Cerebellar incoordination of moderate degree. Normal sensitivity. Lower limbs: extension and internal rotation with pes equinus-varus. Severe spasticity with marked tendinous hyperreflexia and intense Babinski. Weakness and coordination are

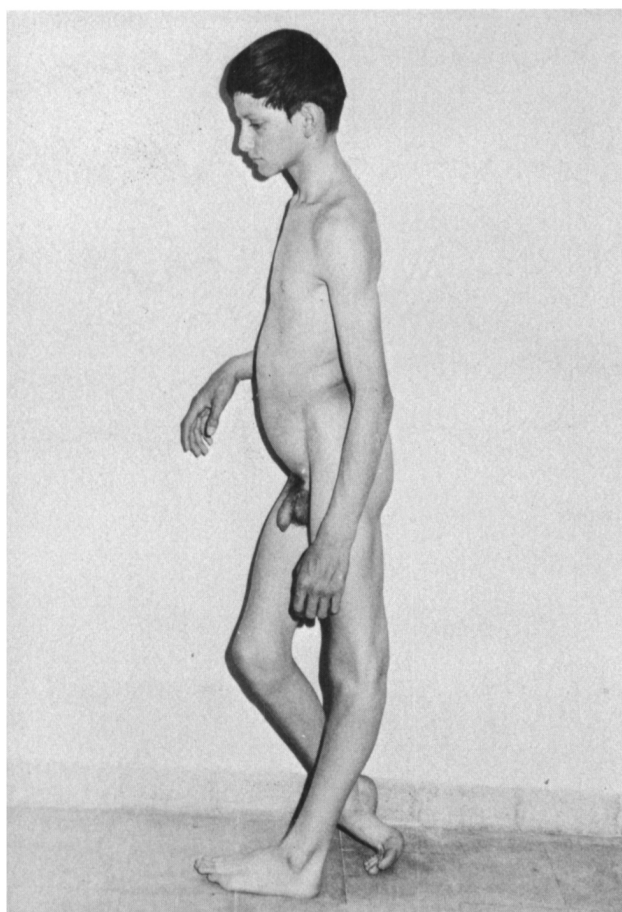


Figure 4

difficult to evaluate because of the spasticity. Vibratory sensation within the limits of normality. Very difficult gait with help. Total score (Pourcher-Barbeau Scale): 75. Functional stage: IV.

Case 2: (Fig. 4) L.C. 15 years old. Male. Caucasian. Left-handed. Delay in attainment of motor behaviour. When 3 years old he started left varus pes and at the age of 6 varus also appeared on his right foot, thus determining slowly progressive disturbances of gait. Two years ago dysarthria and moderate loss of strength in the lower limbs. The patient walks without help.

Physical examination: Tall and thin. Hypertelorism. Defective dental implantation. Skin: Translucent with visible blood vessels. Hyperextensible with easy and elastic folding. Pigmented and papulous nevus on lumbo-sacral sector. Joints: Marked hypermobility.

Neurological examination: Normal intellect. Mild dysarthria and hypophonia. Severe myopia and bilateral astigmatism. Fundus: severe myopic signs with myopic degeneration of the retina. Vertical oscillatory nystagmus of moderate degree. Transient convergent strabismus. Enhanced mandibular reflex. Upper limbs: Hyperextensibility and hypotonia. Mild bilateral incoordination. Normal strength, reflexes, and sensitivity. Lower limbs: Bilateral pes equinus-varus-cavus. Marked internal rotation of lower limbs. Pronounced hyperextensibility. Moderate spasticity. Intense bilateral Babinski. Mild incoordination. Vibratory sensation within the limits of normality. Scissor-gait with knee hyperextension. Total score: (Pourcher-Barbeau Scale): 47. Functional stage: III.

Case 3: R.P. 11 years old. Female. Caucasian. Right-handed. At 18 months started showing varus attitude on left foot and when 3 years old right varus pes appeared, with progressive accentuation. Dysarthria at age 5 and upper limbs incoordination when 7 years old which some months later associated with lower limbs weakness and unsteadiness of gait. Low school learning.

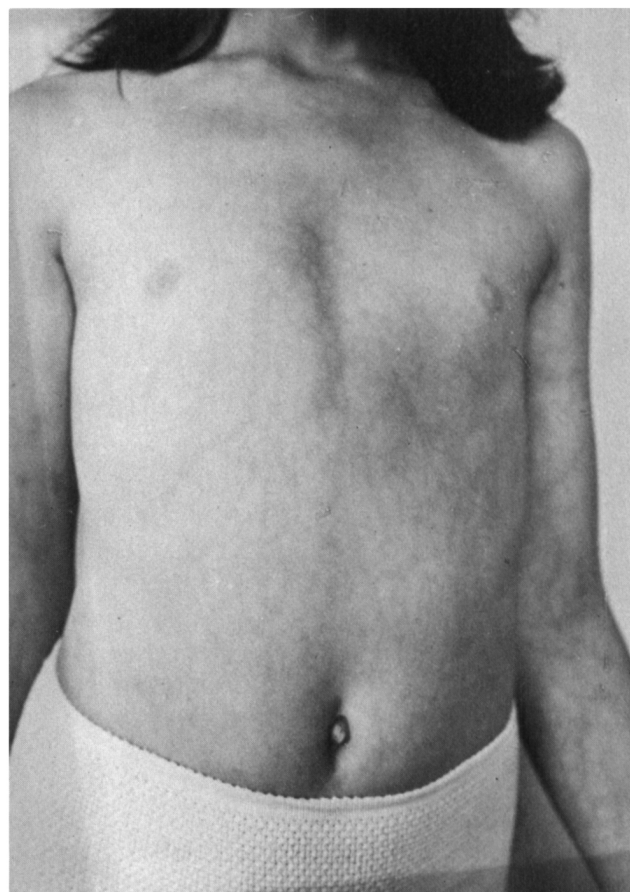


Figure 5

Physical examination: Long and thin upper limbs. Skin: Hyperextensible with easy and elastic folding. Visible cutaneous blood vessels on trunk and limbs (Fig. 5 & 6). Pigmented flat nevus on back and right upper limb. Joints: Hypermobile.

Neurological examination: Marginal intellect (WISC = 73). Moderate dysarthria and hypophonia. Fundus: normal. Enhanced mandibular reflex. Upper limbs: Hyperextensibility and hypotonia. Mild hyporeflexia. Mild-moderate cerebellar incoordination. Lower limbs: Bilateral pes cavus. Hyperextensibility. Mild spasticity and hyperreflexia. Bilateral Babinski. Mild weakness. Mild cerebellar incoordination. When the patient stands up, we observe: hyperlordosis. "Tendinous dance" of feet, mild ataxia and paretic-spastic gait. Total score (Pourcher-Barbeau Scale): 40. Functional stage: II.

Case 4: J.P. 8 years old. Male. Caucasian. Right-handed. Since 2 months ago varus attitude is noticed in his left foot.

Physical examination: Normal biological type. Skin: Hyperelastic. A few nevi on back. Joints: Hypermobility, specially in hands (Fig. 7). **Neurologic examination:** Normal intellect and speech articulation. Fundus: Normal. Normal cranial nerves. Upper limbs: Pronounced hyperextensibility and hypotonia. Lower limbs: Left pes cavus. Marked hyperextensibility and hypotonia. Patellar hyporeflexia and Achillean areflexia. No Babinski. Mild trunk ataxia. Sporadic "tendinous dance" of feet. Normal gait. Total score (Pourcher-Barbeau Scale): 27. Functional stage: I.

PARACLINICAL

Electrophysiological Studies

Case 1: Electroencephalogram (EEG): Normal. EVOKED POTENTIALS: (Fig. 8)

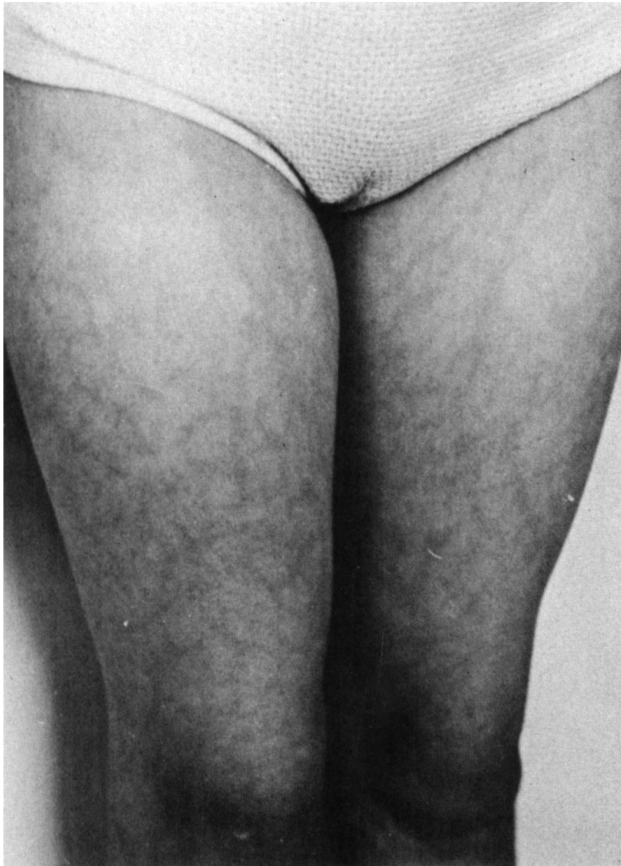

Figure 6



Figure 7

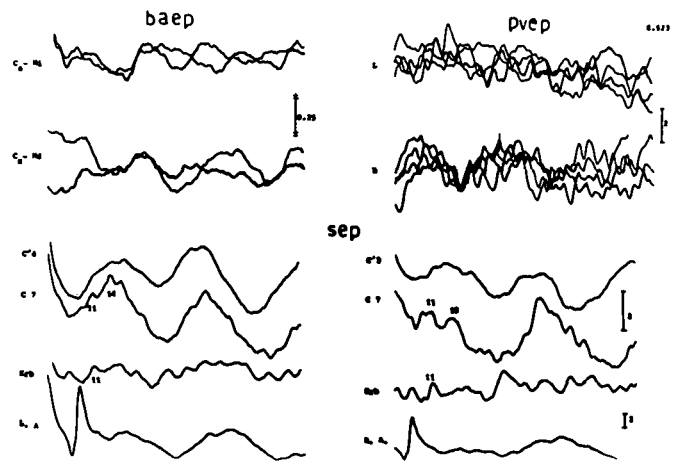


Figure 8

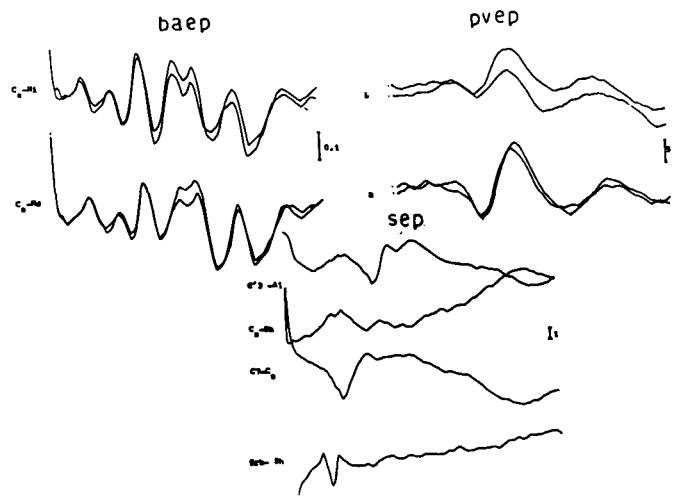


Figure 9

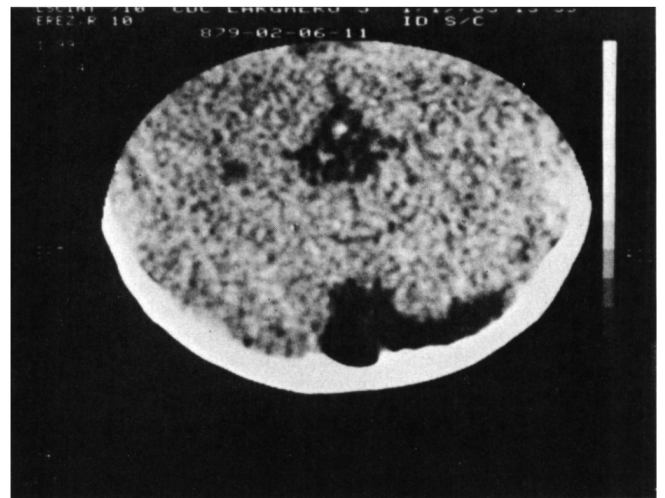


Figure 10

Brain-stem auditory evoked potentials (BAEP) Disorganized pattern after monoaural stimulation with clicks. It was possible to identify wave I (Fig. 8).

Pattern of visual evoked potentials (PVEP) (Inverted checkerboard) After several trials, no reliable response could be recorded.

Electro-retino-gram (ERG) (average-skin electrodes). On scotopic conditions we registered a very reduced *b* wave and an abnormal response to the flicker stimuli. (20/sec.)

Somato-sensory evoked potentials (SEP) (cephalic: F_z and non-cephalic reference: dorsum of the hand) Spinal potentials P11 and P13 (median nerve stimulation) are not registered.

Sensory-conduction velocity (SCV) median nerve: 55.50 m/sec. sural nerve: 43.75 m/sec. - 34.73 m/sec.

Case 2: EEG: Normal.

EVOKED POTENTIALS:

BAEP: Disorganized responses. Absence of waves II and V in C_z - Mi (stimulation of the left ear) and of wave V in C_z - Md (stimulation of the right ear). On C_z - Mi we found a very reduced wave III.

PVEP: Superposition of the EMG could not be avoided. An extended P100 was found.

ERG: Normal.

SEP: The P9, P11, P13 and N20 potentials were not registered on lead C3 - hand and on Cv 7 - hand.

SCV: Median nerve: 53.57 m/sec. Sural nerve: 43.75 m/sec.

Case 3: EEG: Normal.

EVOKED POTENTIALS:

BAEP: Disorganized pattern. On C_z - Mi (stimulation of left ear) and on C_z - Md (stimulation of right ear) the I and II waves were registered with normal latencies and amplitudes. Wave III outlines on C_z - Mi and is absent on C_z - Md.

PVEP: A very extended P100 with similar values to those of Case 2.

ERG: Normal.

SEP: P11, P13 and N20 were not recorded.

SCV: Median nerve: 62.5 m/sec. Sural nerve: 58.33 m/sec.

Case 4: EEG: Positive spikes' syndrome.

EVOKED POTENTIALS: (Fig. 9)

BAEP: Organized patterns appear in C_z - Mi and in C_z - Md. Normal interpeak latency. Amplitude coefficient (V/I) above 1. (Fig. 9)

PVEP: P100 in the normal latency and amplitude range.

ERG: In the right eye, the *a* wave with the red filter and the flicker response is not well defined.

SEP: P10, P12, P14 were recorded in the leads C_z - shoulder and N22 in the lead C'3 - A1.

SCV: Median nerve: 60.71 m/sec. Sural nerve: 51.47 m/sec.

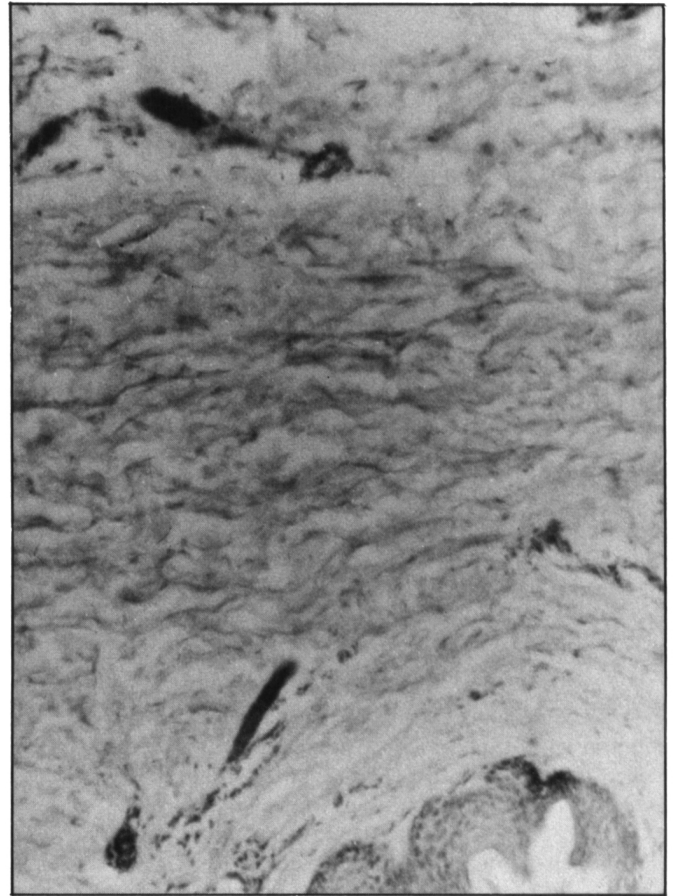


Figure 11

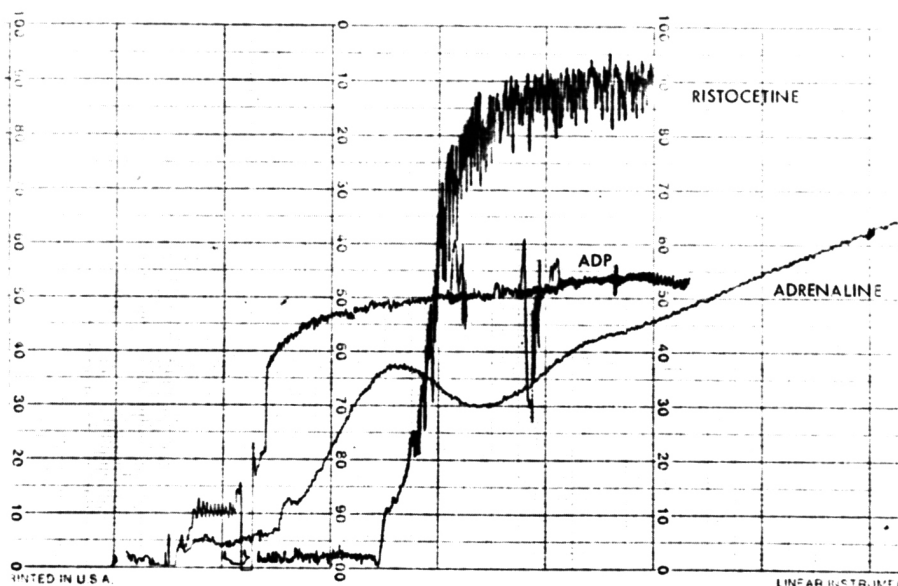


Figure 12

Tomographical Studies (CAT. Elscint 710)

Case 1: Mild atrophy of upper surface of cerebellar vermis.

Case 2: Normal.

Case 3: Localized atrophy on posterior lobe of right cerebellar hemisphere (Fig. 10).

Cardiovascular Evaluation

The 4 patients presented normal studies, ECG and echocardiograms with the exception of Case 2 whose bi-dimensional echocardiogram revealed a holosystolic mitral prolapsus.

Skin Biopsy

It was done by punch using routine techniques (hematoxylin-eosin) and Weigert's coloration (Fig. 11) for dyeing of elastic fibres. Similar characteristics were obtained in the four cases. No alterations were verified in the epidermis. The decreased dermis showed a dense, compact pattern made up of collagen and elastic fibres, which were increased in number. No elastorrexis was present. In brief, non-specific alterations compatible with hyperelastic skin or Ehlers-Danlos syndrome. The proband also underwent biopsy of cutaneous tumour with nevus' characteristics, on the chin. Its histological study reported an intradermal nevus of neural form.

Hematological Results

Technics employed:

— Bleeding Time by Duke and Ivy techniques; — Platelet count in Ultra-Logic-800 analyzer; — Platelet adhesitivity by Hellem II technic in columns of glass beads; — Platelet aggregation by Born and O'Brian Chrono-Log-320 Aggregometer with register; — Quick's Time with human cerebral thromboplastin by Poller and Thompson's technique; — Cephalin-caolin Time; — Platelet electron microscopy: Siemens-Elmiskop-1 equipment, (Biological Investigation Institute "Clemente Estable").

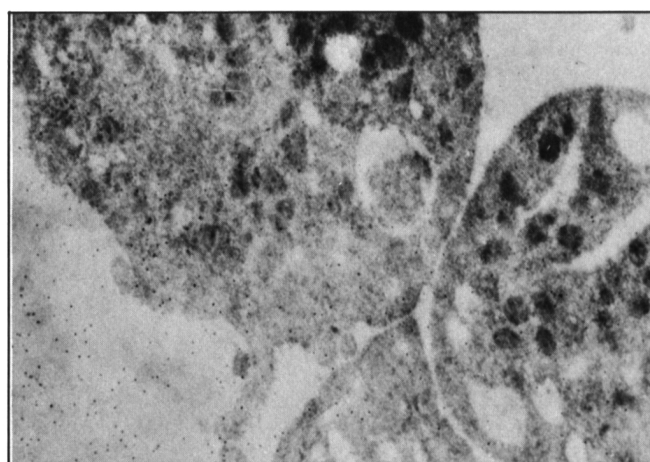


Figure 13

RESULTS

Normal bleeding time, platelet count, platelet adhesitivity, Quick's and cephalin-caolin times. Platelet aggregation: normal before epinephrine (1×10^{-4} M.C.f.), before ristocetine (1.5 mg/ml - C.f.) or before collagen (1.5 mg/ml. C.f.). Abnormal before A.D.P. (1.3×10^{-5} M.C.f.) with absence of second wave (Fig. 12). Platelet electron microscopy: platelets larger than usual with decrease in number of dense granules and decrease in number of mitochondria (Fig. 13).

Biochemical Study

Cerebro-spinal fluid (Table 1)

The four cases showed low level of total proteins with values near the lower limit of normality. There was a relative increase

Table 1: C.S.F. Gel-Polyacrylamid Electrophoresis

NORMAL VALUES	Pre Ab 5 ± 1.5%	Ab 51.5 ± 7%	α 1 6.5 ± 1.5%	α 2 8.5 ± 2%	β 1 13.5 ± 3%	β 2 5 ± 1.5%	10 ± 3%	PROTEINS gr o/oo
CASE 1 Proband	7.8	49	7	9	14	7.2	6	0.20
CASE 2	8	55	6	6	10	8.4	6.6	0.25
CASE 3	7.5	48	6.9	8.8	15	7.3	6.5	0.21
CASE 4	8.5	54	5	7.5	10.5	9.5	5	0.30

Table 2: Lipo-Proteic Metabolism and L.A.D. in Plasma

NORMAL VALUES	TG up to 190 mg/dl	Cholest. 160-260 mg/dl	NEFA 0.06-0.9 meq/l	α 28-40%	preβ 12-21%	β 40-56%	HDL 21.5-79.5 mg/dl	LDL 39-117 mg/dl	VLDL 3.5-45.5 mg/dl	LAD 1.84 ± 0.12 mol/min. mg.prot. x10 ⁻⁴
CASE 1 (proband)	180	200	0.75	28	14	50	22	70	33	1.47
CASE 2	155	260	0.75	30	19	47	30	49	49	1.25
CASE 3	170	210	0.65	28	19	44	23	60	45	1.44
CASE 4	150	240	0.09	31	18	45	25	50	50	1.20

Table 3: Gas-Chromatography of N.E.F.A. in Plasma

	Controls	Case 1	Case 3	Case 4	Case 2
20:4 Arachidonic Acid	4 ± 1	3.2	4	4	3.9
18:3 Linolenic Acid	0.80 ± 0.60	0.12	0.10	0.09	0.08
18:2 Linoleic Acid	21.40 ± 2	15	16.5	17.5	16
18:1 Oleic Acid	32 ± 2.2	33	34.2	33.2	33.6
18:0 Stearic Acid	6 ± 1.5	6.2	6.5	7	6.9
16:1 Palmitoleic Acid	5 ± 2	5.6	7	6	6.2
16:0 Palmatic Acid	25.80 ± 1.5	26	25.8	26	24.8
14 Miristic Acid	1.44 ± 0.30	1.75	1.80	1.50	1.60

The statistic analysis using the t test for independent samples showed: significant low levels of linolenic acid ($p < 0.0001$) and linoleic acid ($p < 0.00005$) in the patients compared to the standard control.

of typical proteins of the CSF such as pre-albumin and β_2 globulin (or τ component) which allows us to suppose a degenerative profile as present in many degenerative diseases of the central nervous system (Ben Hamida et al., 1980).

The severe decrease of immunoglobulins does not favour intrathecal immune activation or autoimmunity responses and may suggest a depression of the immunocompetent system in these disorders. These results were obtained with native CSF (not concentrated) but with an electrophoretic technic of high sensibility (modified polyacrylamide gel).

Plasma

Lipoprotein exploration (Table 2)

Total cholesterol and triglycerides showed normal values but they were near the higher limit of normality, a fact observed in Friedreich's disease (Huang et al., 1978).

Electrophoresis in cellulose-acetate showed normal pre- β and β lipoproteins whilst α lipoproteins were near the lower limit of normality. These findings are in accordance with normal values of HDL, LDL and VLDL but the afore-mentioned were in the lower limit of normality coinciding with observation by Huang et al. (1978) in Friedreich's disease. These facts suggest a defect of the protein fraction of α lipoproteins or the HDL, and specifically of the apoprotein constituents (Apo A_I activator of the acyl-cholesterol-lecithin-transferase, Apo A_{II} transporter, Apo E, Apo C_{II} and Apo C_{III} activator and inhibitor of the lipoprotein-lipase). Verification would require quantitative exploration of each one of them.

The non-esterified plasma fatty acids (NEFA) studied were normal from the quantitative point of view (Table 3). The qualitative classification of these in comparison with control series showed a significant decrease of linolenic acid (18:3) ($p < 0.0001$) and mainly of linoleic acid (18:2) ($p < 0.00005$). Considering that they are essential fatty acids, their deficiency suggests that the transporting lipoprotein complexes present a defective incorporation to phospholipids.

The decrease in activity of plasma lipo-amide-dehydrogenase (LAD), also verified in the 4 cases in relation with normal controls, suggests an inhibition of this enzyme which is situated at a key intersect in cellular energetic metabolism.

Pyruvicemia is within normal limits but in upper normal values. This indicates an alteration of carbohydrate metabolism, which may be secondary to a decrease in pyruvate-dehydrogenase activity.

The remarkable homogeneousness of the biochemical results in the 4 cases confirm the fact that genetic determinants have a linear expression.

COMMENTS

From the analysis of the familial pedigree, some considerations emerge about the mechanism involved in the transmission of these disorders. Other reports postulated an autosomal-dominant, autosomal-recessive or x-linked type of inheritance. In this family we can exclude the x-linked transmission due to the presence of affected individuals of both sexes in the siblings. The autosomal-recessive inheritance may be considered as a possible transmission mechanism but in this circumstance it is not probable. Taking into account the available information, we propose an autosomal-dominant type of inheritance as the most probable mechanism of transmission in this family.

Although no information has been previously reported, the concomitant presence of Ehlers-Danlos' disease (Type II) in all the affected individuals (also transmitted as an autosomal-dominant trait) would suggest the possibility that both genes could be linked. The absence of previous cases of these diseases in the family suggests but does not prove a probable mutation in one of the proband's parents.

Analysis of the neurological signs shows that the proband is affected by a severe ataxo-spastic syndrome of long evolution (35 years) suggesting a benign course of this disease and indicating a probable similar prognosis for the children. Although there is an important functional impairment, we have not observed the frequent complications of advanced stages of these disorders, such as neurogenic sphincterian disturbances and their secondary urinary infections. Schut (1950) observed a positive correlation between the age of onset of illness and its duration in dominant ataxia, pointing out that the earlier the age of onset, the shorter duration of the disease (which is not the case in our patient). Case 2 is characterized by a clear predominance of spastic pyramidal signs over the mild cerebellar incoordination, similar to spasmodic paraplegia; we believe it is probably a transitional form between both. The spastic ataxias occupy a central position in the spinal-cerebellar degenerations' spectrum, very close to familial spastic paraplegia (Barbeau, 1976). In the classification of spinal cerebellar degenerations' proposed by Greenfield (1954), we find the spinal, spinal-cerebellar, and cerebellar forms. Within the first group he includes hereditary spastic-ataxia and establishes its possible association with hereditary spastic-paraplegia. Landau and Gitt (1951) presented a family with varied phenotypic expressions, including patients with spastic-ataxia and spastic-paraplegia. The main difference between the two entities is the presence or absence of ataxic signs. However, even in the "pure" Strumpell's form, existence of mild signs of ataxia in any of the affected members is admitted (Sutherland,

1975). In this event the familial disease is spastic-ataxia, and Case 2 may represent the linking or "trait d'union" between both entities, indicating the "continuum" of these degenerative disorders.

Case 3 represents a clear but not completely developed form of spastic-ataxia, since pyramidal and cerebellar signs are of moderate and similar intensity.

Case 4, has presented cavus pes and varus deformation of the left foot as well as other neurological stigmata in the past months, sufficient to diagnose incipient spinal-cerebellar degenerative disease. The latter probably corresponds to spastic-ataxia considering the similarities of the initial symptom, the affected side and the association to Ehlers-Danlos' syndrome. In the 4 cases, it is worth mentioning the outstanding early onset of the disease, which varied between 18 months and eight years.

Generally, spastic-ataxias are of dominant inheritance transmission and begin in the third or fourth decade; the cases of early onset and particularly those which start at childhood correspond to the recessive forms (Bell & Carmichael, 1939; Hogan & Bowman, 1977).

Consequently, this family which presents dominant forms and onset in early childhood may be considered an exceptional case, with rare references of similar cases in the literature (Bergstedt et al., 1962).

Another fact worth mentioning is that the disease in the 4 patients had the same presenting symptom, varus pes, on the same side, on the left, and at very similar ages; this indicates the homogeneity of presentation of this entity and the importance of the genetic determinant as to the form and time of onset of the disease. Cases 1, 2 and 3 with developed neurological disease showed very well defined abnormalities of the evoked potentials in the three patterns, specially in the BAEP and the PVEP. Case 1 of longer duration, shows severe disorders: absence of visual response with ERG' disorders, absence of intraxial components of the BAEP, absence of the SEP short latencies. These facts were present in lesser degree in cases 2 and 3; on the contrary, case 4 had normal responses with exception of a possible disorder of the cones' system suggested by the computed ERG.

We point out the pronounced disturbances in the visual and auditory pathways through the brain-stem. The intensity, inconstancy and unilateral fashion of the ERG abnormalities allow us to say that the intense disturbances of the visual pathway are mostly due to its disturbance rather than disorders of the retina, which did not show manifest clinical disturbances. Similarly on the BAEP, the maintenance of wave I with normal latencies and absence of other components — specially segment II-V, indicate the central involvement of the auditory pathway. The normal ortodromic conduction velocities of limbs allows us to state that the absence of P11, P13 and N20 potentials manifest affection of the somatosensory pathway in its supraspinal central sector. A longitudinal study of Case 4 will allow us to establish at an early stage whether we are faced with the same clinical entity.

These abnormalities of evoked potentials in this family with spastic-ataxia, are more severe than those observed in another familial group with Friedreich's ataxia (Bogacz et al., 1984).

Computerized axial tomography helps us to define the cerebellar lesions that may appear in spastic ataxias. In Case 1 of longer evolution there is only a mild atrophy of the cerebellar vermis

thereby indirectly indicating the severity of the spinal lesions to which this entity corresponds. Case 3 reveals focal cerebellar atrophy which has been previously described.

The diagnosis of Ehlers-Danlos' syndrome is easily accomplished in our patients because they show the characteristic, although moderate, signs of the disease. In addition we have the physical conformation with long and thin upper limbs and fingers that evoke arachnodactyly as well as the neuro-ectodermic dysplasia such as the various nevi and cutaneous tumours.

The clinical forms of presentation of the syndrome are heterogeneous, with degrees varying from minimal forms to those which convey a risk of death. The different clinical presentations gave rise to classifications such as Beighton's (1970), later modified by McKusick (1972), which then included 7 types. With the addition of new forms the classification totalized 10 types in 1982 (Hammerschmidt et al., 1982). When placing the syndrome in this classification one must bear in mind the type of genetic transmission, the intensity and characteristics of clinical signs and the knowledge or ignorance of the collagen's biochemical defect. In view of their dominant-autosomal character, the moderate intensity of the clinical signs (skin's hyperelasticity and articular hypermobility) and the absence of greater complications, we believe our cases correspond to type II or "mitis" with unknown biochemical defect. The cardiovascular abnormalities observed in Ehlers-Danlos' syndrome are due to congenital disturbances or are secondary to a connective tissue disease.

Mitral valve's prolapsus, observed in 5% of the general population (Darsee et al., 1979), is a relatively frequent manifestation of various disorders of the connective tissue such as systemic lupus erythematosus, Marfan's syndrome and Ehlers-Danlos syndrome. In the latter it constitutes the most frequent cardiovascular disturbance according to Leier et al. (1980). The discovery of collagen disorders in the mitral valve of these patients would indicate that the connective tissue disturbance is of pathogenic importance.

In Case 2 the mitral valve prolapsus, revealed in the echocardiogram, probably is a further expression of the biochemical defect of collagen. However we also state the possibility that such a valve prolapsus may be a manifestation of the corresponding spastic-ataxia. In Spastic Ataxia of Charlevoix-Saguenay, the echocardiogram reveals high incidence of mitral valve prolapsus (8 out of 12 patients) (Bouchard et al., 1978). On the contrary, in Friedreich's disease the distinctive feature is the hypertrophic cardiomyopathy while valvular prolapsus is not frequent (1 out of 21 patients).

Disturbances in the hemostatic mechanism have been described in some forms of Ehlers-Danlos' syndrome, particularly in those of recessive transmission (Goodman et al., 1962; Lisker et al., 1960). In some cases such disorders produce bleeding with risk of death; therefore, we deduce that it is important to explore the hemostatic conditions in this syndrome. The hemostatic defect has been attributed to structural failure of vessels, due to alteration of the support caused by the defective collagen, or to disturbances of the coagulation mechanism — particularly failure of platelet aggregation. Arneson et al. (1980) propose that the defective fibronectin would explain the platelet dysfunction, the hyperelastic skin and the articular hypermobility. Fibronectin is an important adhesive glyco-protein of the connective tissue that is present in the platelet membrane and works as collagen receiver (Bensusan et al., 1978); when the

endothelium is damaged, this platelet-collagen interaction constitutes an important hemostatic stage. The fibronectin pool that exists on the α granules of the platelets is important for platelet aggregation and an abnormality of same may determine abnormal platelet aggregation; for example, before ADP, as happens in the aforementioned cases. The alteration in platelet aggregation found in the 4 cases studied, does not express itself by hemorrhagic manifestations nor does it modify the bleeding time. It has value as a biological index since, in this family, its presence is associated with Ehlers-Danlos syndrome.

The defective platelet aggregation is related to the clear-cut ultra-structural alterations found in the platelets, the larger size and the decrease in number of intraplatelet granules; this was already mentioned by Kashiwagi et al. (1965).

This variety of the Ehlers-Danlos' syndrome with platelet dysfunction is usually seen in recessive forms of the disease; therefore its presence in these patients, whose disease is of dominant transmission, constitutes an exception.

In the case of this family, special precautions must be taken when considering surgery, as e.g. an orthopedic operation. We should then think about the disorder in platelet aggregation which may lead to defective hemostasis.

In view of the hereditary characteristics, genetic counselling should also be taken into account.

REFERENCES

- Aita J (1972) Miscellaneous neurocutaneous diseases. The Phakomatoses. Ed. PJ Vinken and GW Bruyn. North-Holland Pub Comp Amsterdam 14: 772-806.
- Arneson MA, Hammerschmidt DE, Furcht LT and King RA (1980) A New Form of Ehlers-Danlos Syndrome. *JAMA* 244: 144-147.
- Barbeau A (1976) Quebec Cooperative Study of Friedreich's Ataxia. Design of the Investigation. *Can J Neurol Sci* 3: 271-274.
- Beighton P (1970) The Ehlers-Danlos Syndrome. London. William Heinemann Medical Books Ltd.
- Bell JM and Carmichael EA (1939) On hereditary ataxia and spastic paraplegia. *Treasury of Human Inheritance*. London, Cambridge University Press. 4: 141-281.
- Ben Hamida M, El Younsi C and Isautier CH (1980) Electrophorèse du liquide céphalo-rachidien au cours des hérédo-dégénérescences spino-cérébelleuses. *Revue Neurol* 136: 25-32.
- Bensusan HB, Koh TL, Henry KG, Murray BA and Culp LIA (1978) Evidence that fibronectin is the collagen receptor on platelet membranes. *Proc Natl Acad Sci U.S.A.* 75: 5864-5868.
- Bergstedt M, Johansson S and Muller R (1962) Hereditary spastic ataxia with central retinal degeneration and vestibular involvement. A clinical report on a family. *Neurology* 12: 124-132.
- Bogacz J, Chouza C, Romero S, Bogacz A, Correa H and Barbeau A (1984) Visual Evoked Potentials and Brain Stem Auditory Potentials in Friedreich's Ataxia. A longitudinal study. *Can J Neurol Sci* (this issue).
- Bouchard JP, Barbeau A, Bouchard R and Bouchard RW (1978) Autosomal Recessive Spastic Ataxia of Charlevoix-Saguenay. *Can J Neurol Sci* 5: 61-69.
- Danlos M (1908) Un cas de cutis laxa avec tumeurs par contusion chronique des coudes et des genoux. *Bull Soc Frac Derm Syph* 19: 70-73.
- Darsee JR, Mikolich JR, Nicoloff NB and Lesser LE (1979) Prevalence of mitral valve prolapse in presumably healthy young men. *Circulation*. 59: 619-622.
- Ehlers E (1901) Cutis laxa Neigung zu Haemorrhagien in der Haut, Lockerung meherer Artkulationen. *Dermatol Zschr* 8: 172-179.
- Gattiker HF, Davignon A, Bozio A, Batlle-Diaz J, Geoffroy G, Lemieux B, Barbeau A (1976) Echocardiographic Findings in Friedreich's Ataxia. *Can J Neurol Sci* 3: 329-332.
- Goodman R, Levitsky J and Friedman I (1962) The Ehlers-Danlos Syndrome and Multiple Neurofibromatosis in a kindred of mixed derivation, with special emphasis on hemostasis in the Ehlers-Danlos Syndrome. *Am J of Medicine* 32: 976-983.
- Greenfield JG (1954) The spino-cerebellar degenerations. Blackwell Scientific Publications. Oxford. England.
- Hammerschmidt DE, Arneson MA, Larson SL, Van Tassel RA and McKenna JL (1982) Maternal Ehlers-Danlos Syndrome type X. Successful management of pregnancy and parturition. *JAMA* 248: 2487-2488.
- Hogan G and Bauman M (1977) Familial spastic ataxia: occurrence in childhood. *Neurology* 27: 520-526.
- Huang YS, Nestruck AC, Barbeau A, Bouchard JP, Davignon J (1978) Plasma Lipids and Lipoproteins in Friedreich's Ataxia and Familial Spastic Ataxia-Evidence for an Abnormal Composition of High Density Lipoproteins. *Can J Neurol Sci* 5: 149-156.
- Kashiwagi H, Riddle J, Abraham J and Frame B (1965) Functional and Ultrastructural Abnormalities of Platelets in Ehlers-Danlos Syndrome. *Ann Int Medicine*. 63: 249-254.
- Kayed K and Kass B (1979) Acute multiple brachial neuropathy and Ehlers-Danlos Syndrome. *Neurology*. 29: 1620-1621.
- Landau W and Gitt J (1951) Hereditary spastic paraplegia and hereditary ataxia. A family demonstrating a variety of phenotypic manifestations. *Archives of Neurology and Psychiatry*. 66: 346-354.
- Leier C, Call T, Fulkerson Ph and Wooley Ch (1980) The spectrum of cardiac defects in the Ehlers-Danlos Syndrome, Types I and III. *Annals of Internal Medicine*. 92: 171-178.
- Lisker R, Noguero A and Sanchez-Medal L (1960) Plasma thromboplastin component deficiency in the Ehlers-Danlos Syndrome. *Ann Int Med* 53: 388-392.
- McKusick VA (1972) Heritable Disorders of Connective Tissue. Edition 4. St. Louis C.V. Mosby Co.
- Pourcher E and Barbeau A (1980) Field Testing of an Ataxia Scoring and Staging System. *Can J of Neurol Sciences* 7: 339-344.
- Schut JW (1950) Hereditary ataxia. *Arch Neurol Psychiatry* 63: 535-568.
- Schut JW, Haymaker W (1951) Hereditary ataxia. *J Neurophathol Clin Neurol* 1: 183-213.
- Sutherland J (1975) Familial spastic paraplegia. *System Disorders and Atrophies*. Ed. PJ Vinken and GW Bruyn. North Holland Publish Comp Amsterdam 22: 421-431.