

Transcatheter tricuspid valve-in-valve implantation in a paediatric patient: a case report

Brief Report

Cite this article: Öztürk M, Aykan HH, and Karagöz T (2025). Transcatheter tricuspid valve-in-valve implantation in a paediatric patient: a case report. *Cardiology in the Young*, page 1 of 3. doi: [10.1017/S1047951125000186](https://doi.org/10.1017/S1047951125000186)

Received: 5 September 2024

Revised: 29 October 2024




Accepted: 29 December 2024

Keywords:

Transcatheter implantation; valve-in-valve; tricuspid valve; case report

Corresponding author:

Musa Öztürk; Email: mozturk91@gmail.com

Musa Öztürk , Hayrettin Hakan Aykan  and Tevfik Karagöz 

Department of Pediatric Cardiology, Hacettepe University Hospital, Ankara, Turkey

Abstract

Percutaneous interventions have become significant in the management of congenital heart diseases, with transcatheter procedures being increasingly used for valve dysfunction, particularly for cases requiring repetitive surgeries. This abstract presents a successful transcatheter valve-in-valve implantation in a 16-year-old patient with severe tricuspid regurgitation following a bioprosthetic tricuspid valve replacement. The procedure involved transcatheter tricuspid valve implantation using the Mammoth 25x40 mm balloon catheter and the 26 mm Myval transcatheter heart valve system (Meril Life Sciences Pvt. Ltd, Vapi, Gujarat, India), resulting in immediate improvement in right atrial pressure and regurgitation. The patient underwent an electrophysiological assessment as part of the follow-up and was discharged with a normal sinus rhythm. Tricuspid valve interventions, although less common, are essential in congenital heart diseases, which necessitate prosthetic heart valve implantation due to long-term complications. The valve-in-valve procedure offers a safe alternative, especially in paediatric patients, for reducing risks caused by repetitive surgeries, providing a valuable treatment option in experienced centres.

Introduction

Percutaneous interventions can be of critical importance in the treatment and follow-up of congenital heart diseases. Nowadays, transcatheter intervention is increasingly used for valve dysfunction in patients requiring recurrent surgery. Percutaneous replacement was first applied to a prosthetic pulmonary conduit with valve dysfunction in the early 2000s.¹ Transcatheter pulmonary valve implantation is frequently performed in paediatric patients, especially in the follow-up of congenital heart disease presenting with right ventricular outflow tract dysfunction, such as tetralogy of Fallot.² Although dysfunctional pulmonary conduit and aortic valve intervention is performed, percutaneous valve implantation in the mitral and tricuspid positions are performed less frequently in selected cases.^{3,4}

The early results of valve-in-valve and valve-in-ring transcatheter tricuspid valve implantation, whose frequency of application increased in the second decade of the 2000s, are satisfactory.⁵ In the mid-term follow-up of the procedure, valve dysfunction, endocarditis, and leaflet thrombus were rarely observed.⁶ Considering the increased risk of repeat surgery, percutaneous tricuspid valve-in-valve implantation appears to be an important option.

It is aimed to present the successful transcatheter valve-in-valve implantation procedure in a 16-year-old patient with severe tricuspid regurgitation who underwent Medtronic No. 29 Hancock II bioprosthetic tricuspid valve replacement.

Case presentation

The patient, who was born at term with normal birth weight, was referred to paediatric cardiology when a loud murmur was heard during routine check-ups when he was 6 months old. The echocardiographic evaluation revealed tricuspid hypoplasia and severe pulmonary stenosis. Tricuspid valvulotomy and pulmonary artery reconstruction were performed on the patient, for whom the decision for surgery was made, at the age of 7 months.

The patient, who was followed up with moderate tricuspid and pulmonary insufficiency until the age of 14, was placed in the pulmonary position with a Medtronic no. 25 Mosaic bioprosthetic mitral valve; Medtronic no 29 Hancock II bioprosthetic T510 valve was implanted in the tricuspid position. The patient with right atrial dilatation underwent a right atrial maze procedure in the same session.

The patient's outpatient follow-up continued after the valve replacements. A decrease in exercise capacity was noted in the clinic over time. In the 17th month after the operation (15.5 years old, 43 kg), the patient's complaints of intermittent palpitations, chest pain, and signs of peripheral oedema are noteworthy. Severe tricuspid regurgitation and a severely enlarged

© The Author(s), 2025. Published by Cambridge University Press. This is an Open Access article, distributed under the terms of the Creative Commons Attribution licence (<https://creativecommons.org/licenses/by/4.0/>), which permits unrestricted re-use, distribution and reproduction, provided the original article is properly cited.

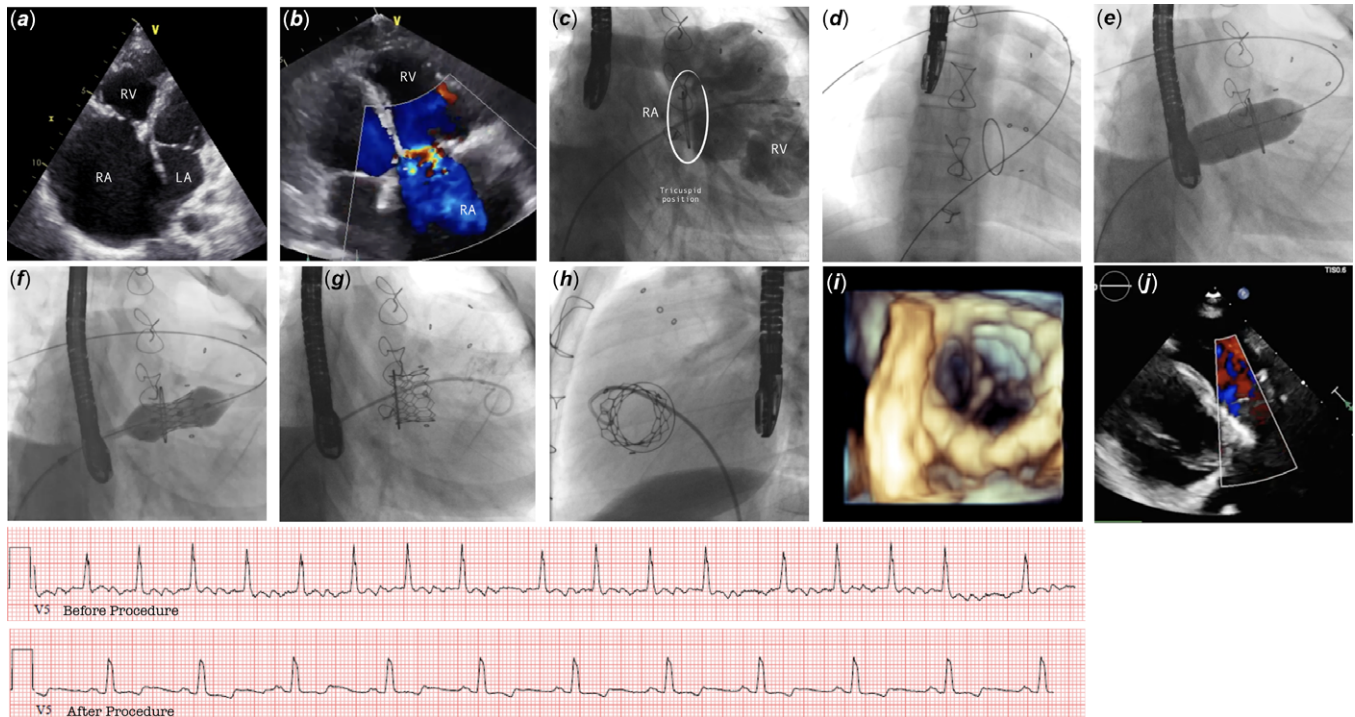


Figure 1. RA: Right atrium, RV: Right ventricle, LA: Left atrium.

right atrium were detected. The electrocardiography revealed atrial flutter with low ventricular rate.

Procedure details

The patient, who had severe tricuspid regurgitation, signs of decompensated right heart failure, and atrial flutter, was hospitalised. The anticoagulant and antiplatelet doses he was taking were adjusted. Transesophageal echocardiography confirmed that tricuspid regurgitation was severe and there was no intracardiac thrombus. There was no valve insufficiency at the paravalvular level.

The patient was processed in the catheterisation unit under general anaesthesia. Right femoral vein access was provided and the guide wire was advanced to the distal right pulmonary artery. Contrast injections revealed severe tricuspid regurgitation, mild pulmonary regurgitation, and dilated right atrium. The average right atrium pressure was measured as 12–13 mmHg. It was gradually dilated and the 14F long sheath was advanced until near the tricuspid annulus. The Mammoth 25x40 mm balloon catheter (Meril Life Sciences Pvt. Ltd, Vapi, Gujarat, India) was inflated at the level of the tricuspid valve and balloon stabilisation and sizing were tested. After balloon stabilisation was achieved, the 26 mm Myval transcatheter heart valve system (Meril Life Sciences Pvt. Ltd, Vapi, Gujarat, India) was subjected to a preliminary preparation and crimping process. The valve was loaded into the delivery system and implanted in the tricuspid position by merging the distal end of both the bioprosthetic valve and the Myval valve. Footage of the process details is shown in Figure 1. Immediately after the procedure, it was observed that the right atrial pressure decreased to 8–9 mmHg, and there was no tricuspid regurgitation during the contrast injection into the right ventricle. Transesophageal echocardiography showed that valve movements

were normal in 3D and there was a trace amount of regurgitation. Simultaneous cardioversion was not applied to the patient, who was haemodynamically stable and had atrial flutter rhythm with 2:1 ventricular crossover, to guarantee valve stabilisation. The femoral venous access was closed with a figure of 8 stitches, haemostasis was achieved, and the procedure was terminated.

A transesophageal electrophysiological study was performed on the patient with oro-pharyngeal local anaesthesia on the 5th day after transcatheter tricuspid valve implantation. Intraatrial reentrant tachycardia was observed with an atrial cycle length of 300 msec. After atrial capture was achieved, tachycardia was terminated with short-term overdrive pacing. The patient was discharged in sinus rhythm after clinical follow-up was completed.

Discussion

Tricuspid valve intervention is required, although less frequently, in congenital heart diseases. This procedure is usually performed surgically. Due to complications in long-term follow-up, the use of bioprosthetic tricuspid valves instead of mechanical valves is common. The rapid degeneration of these valves necessitated off-label transcatheter valve-in-valve tricuspid implantation.^{7,8}

Early valve degenerations, especially in paediatric patients, seriously affect long-term mortality and morbidity. Scar areas and fibrous adhesions formed after repeated operations make surgical intervention difficult in patients with long life expectancy. Satisfactory long-term results have been obtained in large series in adult patients.⁹ In paediatric patients, such off-label usage is conducted in certain and suitable situations.¹⁰ For these reasons, the valve-in-valve procedure in the tricuspid position is safely performed in experienced centres on selected paediatric patients after risk assessment.

Conclusion

Valve-in-valve procedure for degenerated tricuspid valve in congenital heart diseases requiring recurrent surgery can be used in paediatric patients in experienced centres as avoiding surgical risk, palliative time saving, and curative treatment option.

Author contribution. Musa Öztürk: Writing—original draft preparation, data curation

Hayrettin Hakan Aykan: Resources, writing—review and editing

Tevfik Karagöz: Conceptualisation, methodology, resources

Financial support. The authors declare that the study received no funding.

Competing interests. The authors declare that there is no conflict of interest to disclose.

Ethical standard. Informed consent was obtained from patient and his family to share patient clinical information and imaging photographs anonymously for the scientific purposes.

References

- Bonhoeffer P, et al. Percutaneous replacement of pulmonary valve in a right-ventricle to pulmonary-artery prosthetic conduit with valve dysfunction. *Lancet* 2000; 356 (9239): 1403–1405. DOI: [10.1016/S0140-6736\(00\)02844-0](https://doi.org/10.1016/S0140-6736(00)02844-0).
- Alkashkari W, Alsubei A, Hijazi ZM. Transcatheter pulmonary valve replacement: Current state of art. *Curr Cardiol Rep* 2018; 20 (4): 27. DOI: [10.1007/s11886-018-0966-y](https://doi.org/10.1007/s11886-018-0966-y).
- Gurvitch R, et al. Transcatheter valve-in-valve implantation for failed surgical bioprosthetic valves. *J Am Coll Cardiol* 2011; 58 (21): 2196–2209. DOI: [10.1016/J.JACC.2011.09.009](https://doi.org/10.1016/J.JACC.2011.09.009).
- Dvir D, Barbanti M, Tan J, Webb JG. Transcatheter aortic valve-in-valve implantation for patients with degenerative surgical bioprosthetic valves. *Curr Probl Cardiol* 2014; 39 (1): 7–27. DOI: [10.1016/j.cpcardiol.2013.10.001](https://doi.org/10.1016/j.cpcardiol.2013.10.001).
- Viotto G, et al. Early outcomes of transcatheter tricuspid valve-in-valve implantation: a case series. *Interact Cardiovasc Thorac Surg* 2019; 29 (1): 59–63. DOI: [10.1093/ICVTS/IVY362](https://doi.org/10.1093/ICVTS/IVY362).
- McElhinney DB, et al. Mid-term valve-related outcomes after transcatheter tricuspid valve-in-valve or valve-in-ring replacement. *J Am Coll Cardiol* 2019; 73 (2): 148–157. DOI: [10.1016/J.JACC.2018.10.051](https://doi.org/10.1016/J.JACC.2018.10.051).
- McElhinney DB, et al. Transcatheter tricuspid valve-in-valve implantation for the treatment of dysfunctional surgical bioprosthetic valves: an international, multicenter registry study. *Circulation* 2016; 133 (16): 1582–1593. DOI: [10.1161/CIRCULATIONAHA.115.019353](https://doi.org/10.1161/CIRCULATIONAHA.115.019353).
- Karaduman BDuran, Ayhan H, Keleş T, Bozkurt E. Transcatheter tricuspid valve-in-valve implantation with a novel balloon expandable Myval THV. *Ann Thorac Surg* 2021; 112 (6): e435–e437. DOI: [10.1016/j.athoracsur.2021.03.014](https://doi.org/10.1016/j.athoracsur.2021.03.014).
- Scarsini R, et al. Long-term follow-up after trans-catheter tricuspid valve-in-valve replacement with balloon-expandable aortic valves. *Int J Cardiol* 2017; 235: 141–146. DOI: [10.1016/J.IJCARD.2017.02.076](https://doi.org/10.1016/J.IJCARD.2017.02.076).
- Ayhan H, Karaduman BDuran, Keleş T, Bozkurt E. Transcatheter treatment tricuspid regurgitation by valve-in-ring implantation with a novel balloon-expandable Myval® THV. *Kardiol Pol* 2022; 80 (3): 363–364. DOI: [10.33963/KP.a2022.0013](https://doi.org/10.33963/KP.a2022.0013).