

# MORPHOLOGICAL AND CYTOGENETIC STUDIES ON CONJOINED TWINS

BL. KONSTANTINOVA

Central Laboratory of Teratology, Medical Academy, Sofia, Bulgaria

---

*Two cases of monoamniotic conjoined male twins, born at term after normal pregnancies, are reported. The first case, a bicephalus, shows hypoplastic and malformed left-side organs, absence of the left umbilical artery, and two communicating hearts, the left one with three cameras. The second case, a pygothoracopagus, consists in a twin "parasite", with no head but with two upper and two lower limbs, slightly less developed than those of the formed twin. The left eye of the formed twin is double than the right one and contains two eye apples — one well-formed and the other rudimentary. There is a rudiment of a second mouth on the left cheek. The umbilical cord contains five blood vessels — one umbilical vein and four umbilical arteries. The cytogenetic study of the pygothoracopagus reveals aneuploidy, more pronounced in the "parasite" than in the formed twin.*

---

During many years of practice I could observe six cases of conjoined twins, a rare teratological event that more frequently appears in monoamniotic male twins. Two such cases are described in the following.

*The first case is a bicephalus born to a primigravida aged 18 and suffering from epilepsy. (According to Speider and Meadow, 1972, epileptic women have an increased tendency to conceive abnormal children, as well as to conceive female children, with respect to normal women).*

*During the last months of pregnancy the mother had slightly formed edema without raised RR and with no albumin in the urine. In the first two months she suffered from a severe form of grippe with high temperature (39 °C). She was admitted at the Maternity Hospital with a normal course of childbirth and with good tones of the infant that become worse during delivery. There are twins in the father's family.*

*The bicephalus has two heads, the right one bigger, four normally formed extremities, the right ones thicker, one anus through which the atresive ampulla recti filled with meconium extends (Fig. 1a, b). The scrotum is empty (there are no testes) and the penis is well-formed. The umbilical cord is irregularly formed, with only two blood vessels, v. umbilicalis and one a. umbilicalis, but no left umbilical artery (Fig. 2).*

*The X-ray pictures show two completely formed spinal columns and a common pelvis. The left clavicle of the right side (corresponding to the right head) and the right clavicle of the left side (corresponding to the left head) are not completely formed and, instead of a horizontal disposition, they have almost a vertical one (Fig. 3a, b). The bicephalus has one abdominal and one thoracic cavity for both parts, but two hearts which communicate by means of a channel of the heart muscle in the region of the left atrium of the right heart and the right atrium of the left heart. The left heart has an irregular form and is several times bigger than the right one; the atrium membrane fails (cor trilobulare) (Fig. 4). The right part of the single atrium cavity communicates with the posterior part of the left atrium of the right heart, which has a normal shape and a regular inner architecture. A common dilated thoracic and an abdominal aorta comes from the left heart. A small aorta comes from the right heart which, at the level of the bifurcation of the trachea, runs into the big aorta coming from the left heart. The common abdominal aorta passes before the liver, rather than behind it, whereby the second liver lies upon it. The larger part of this second liver is in the mediastinum. It presses upon two of the four lungs, the latter not being completely formed and having a thickness of 2 mm. A single gall-bladder is found in the big liver. The right lungs are well-formed, whereas the left ones are very hypoplastic. Four adrenal glands and two pancreases are present.*

*The urinary and sex organs are double in number: four kidneys, four ureters, four testes, two bladders, one spleen (increased in size) are found in the left part of the common abdominal cavity; in the right abdominal cavity two round formations are found, having the size of maize grains and presenting some spleen tissue (the embryo of a second spleen). One of them has been histologically found to be seminiferous. The digestive system consists of two oesophagi (the middle part of the left one lacks), two stomachs, two duodeni which open into a common jejunum, dilated and full of meconium (Fig. 5). The left brain is smaller than the right one and shows a slight hydrocephaly of the lateral ventriculi. Both spinal columns have a normal structure.*

CASE 1

Fig. 1a, b. Double-headed monster (two heads and two spinal columns).

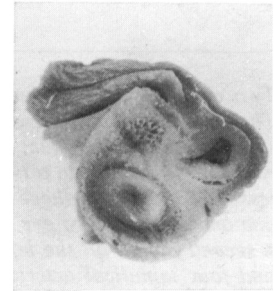
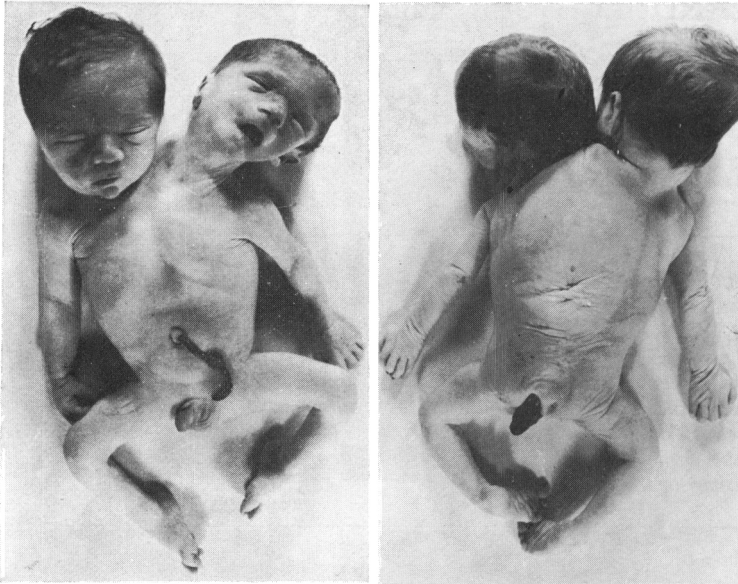


Fig. 2. Umbilical cord containing only two blood vessels (there is no left umbilical artery).

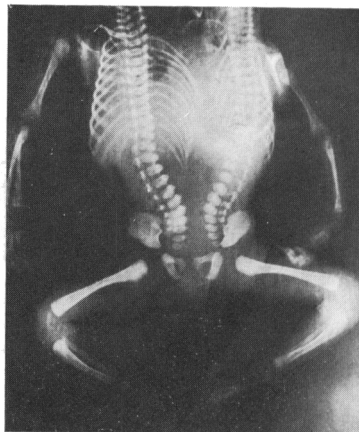
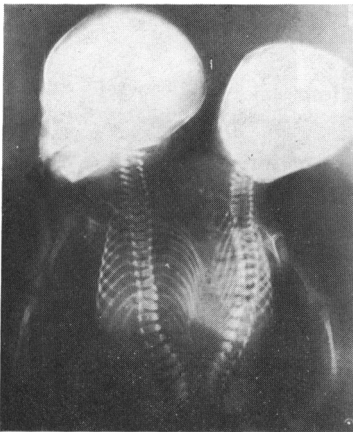


Fig. 3a, b. One pelvis (two upper and two lower extremities).

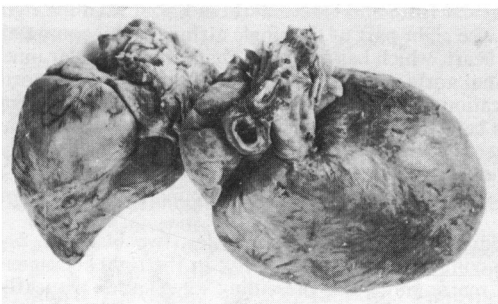


Fig. 4. Both hearts communicate (the left atrium of the right small heart communicates with the right part of the single atrium cavity of the left big heart).

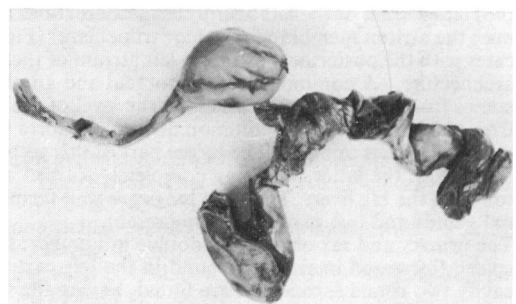


Fig. 5. The central part of the left oesophagus lacks. Two stomachs are present and two duodenums which open into a common jejunum.

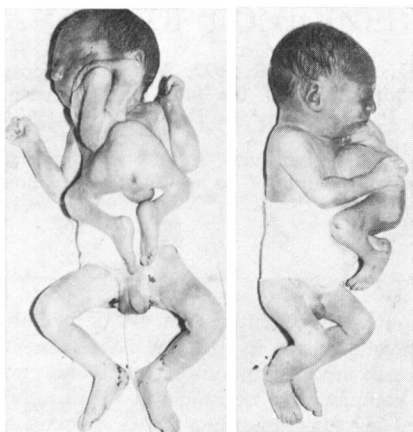

Fig. 6a, b. The twin "parasite" lies upon the thoracic and abdominal parts of the formed twin.

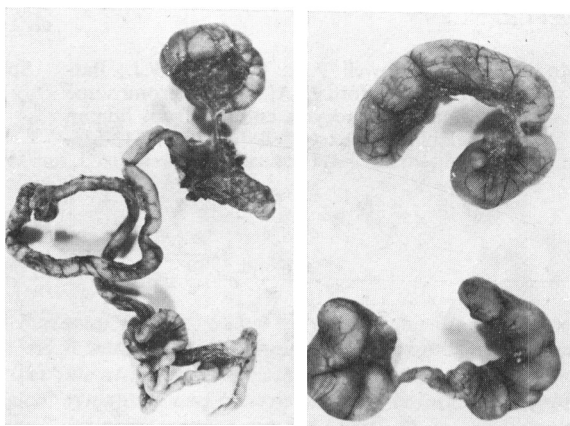


Fig. 7a, b. Colon begins and ends blindly. Kidney with the shape of a horseshoe.

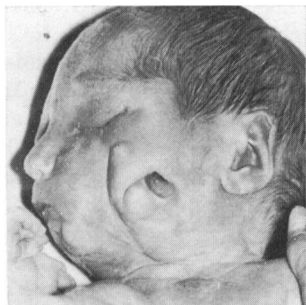

Fig. 8. The rudiment of a second mouth may be seen on the left cheek.

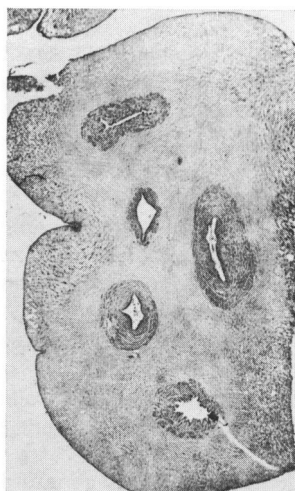


Fig. 9. Umbilical cord containing five blood vessels (one umbilical vein and four umbilical arteries).

#### CASE 2

The second case is a pygothoracopagus who lived four days after being born to a gravida-3, aged 23. One of the twins is well-formed and the other one has no head — a twin "parasite" who has grown with the abdominal and thoracic walls of the formed twin (Fig. 6a, b). The twin "parasite" consists of a body and of two upper and two lower extremities less developed than those of the formed twin. The abdominal cavity of the "parasite" presents one part of the abdominal cavity of the formed twin and contains a big kidney with the shape of a horseshoe, two ureters, two rudimentary testes, one bladder and colon, the beginning and endings of which are blind (their narrow lumen contains a scarce quantity of whitish dryish structureless matter) (Fig. 7a, b). The left eye of the formed twin is double than the right one and contains one rudimentary and one formed eye apples. On the same facial side (the left one) the rudiment of a second mouth may be seen, exuding some slobbery matter (Fig. 8). The umbilical cord has five blood vessels — four umbilical arteries and one umbilical vein (Fig. 9).

Two cytogenetic studies could be performed in the last case. The first study was performed by means of leukocyte cultures of peripheral venous blood, on the mother and on the two twins while still alive, according to the method of Moorhead et al. (1960). The study was performed post mortem with lymph tissue and bone marrow cultures. Both studies indicated a pronounced aneuploidy (hypodiploidy affecting different chromosomes), much more remarkable in the "parasite" than in the formed twin.

## REFERENCES

- Moorhead P.S., Nowell P.C., Mellman W.J., Bat-tips D.M., Hungerford D.A. 1960. Chromosome preparations of leukocytes cultured from human peripheral blood. *Exp. Cell Res.*, 20: 613-616.
- Speider B.D., Meadow S.R. 1972. Maternal epilepsy and abnormalities of the fetus and newborn. *Lancet*, 2: 839.

Prof. Bl. P. Konstantinova, Central Laboratory of Teratology, Belo More St. 8, Sofia 27, Bulgaria.