



Brief Report

Cite this article: Anghel F, Badiu CC, and Poncetlet AJ (2024). Bicuspidisation of unicuspid stenotic pulmonary valve in a nine-year-old male. *Cardiology in the Young*, page 1 of 3. doi: [10.1017/S104795112400043X](https://doi.org/10.1017/S104795112400043X)

Received: 3 February 2024

Revised: 26 February 2024

Accepted: 26 February 2024

Keywords:

Pulmonary valve stenosis; bicuspidisation; pulmonary valve repair; CHD; unicuspid pulmonary valve

Corresponding author:

F. Anghel; Email: florin.anghel@rez.umfcd.ro

¹Department of Cardiovascular Surgery, University Emergency Hospital Bucharest, Bucharest, Romania; ²Carol Davila University of Medicine and Pharmacy, Bucharest, Romania; ³Institut de Recherche Expérimentale et Clinique (IREC), Cliniques Universitaires Saint-Luc, Université catholique de Louvain, Brussels, Belgium and ⁴Department of Cardiovascular and Thoracic Surgery, Université catholique de Louvain, Brussels, Belgium

Abstract

We report the case of a 9-year-old male with severe congenital pulmonary valve stenosis referred to our centre for percutaneous valvotomy. On admission, trans-thoracic echocardiogram confirmed a unicuspid pulmonary valve with a peak/mean pulmonary valve gradient of 91/53 mmHg and a pulmonary annulus of 13.8 mm (−0.8 Z Score). It also showed an enlarged RV (RV/LV ratio 0.9). During cardiac catheterisation, an additional atrial septal defect (secundum) with significant left to right shunt ($Q_p/Q_s > 2$) was diagnosed, which was not amenable to percutaneous closure. The patient was referred for surgical repair.

The atrial septal defect was closed by a direct running suture. The repair of the unicuspid valve consisted in bicuspidisation by a large commissurotomy to the left anterior wall of the pulmonary artery. The neo-commissure was created with two separate patches of autologous pericardium secured to the wall of the pulmonary root. The adjustment of the effective height of the pulmonary valve leaflets was done by trimming the patches and a triangular plication of the newly created posterior leaflet. Perioperative echocardiogram showed a peak gradient of 15 mm Hg and trivial pulmonary regurgitation. The total cross-clamp time was 92 min and the bypass time 123 min with a favourable evolution after the surgery.

The particularity of the case is represented by the complexity of the bicuspidisation procedure. Using this technique, a tailored approach is needed for every patient.

Congenital pulmonary valve stenosis is a relatively common congenital heart malformation that accounts between 7.5 and 9% of all congenital heart malformations. The first-line treatment widely accepted is percutaneous balloon valvotomy.¹

Case presentation

We report a case of a 9-year-old male known with a history of genetical disorder (translocation [4;21] [q27;q22]), who was referred to our centre for severe congenital pulmonary valve stenosis. On admission, the trans-thoracic echocardiogram confirmed the pulmonary valve stenosis with a peak/mean pulmonary valve gradient of 91/53 mmHg and a pulmonary annulus of 13.8 mm (−0.8 ZScore) and also showed dilated right chambers with a RV/LV ratio of 0.9. He underwent cardiac catheterisation for a planned pulmonary valve balloon dilation. During the procedure, the additional presence of a secundum atrial septal defect was acknowledged. The anatomic features of the atrial septal defect would not allow an endovascular device placement. As there was a surgical indication for atrial septal defect closure ($Q_p/Q_s > 2$), the pulmonary valve dilation procedure was not performed. The patient was scheduled for surgery. Preoperative transesophageal echocardiogram confirmed severe pulmonary valve stenosis. The presence of a dysplastic bicuspid pulmonary valve was described (Fig. 1a–c).

After going on cardiopulmonary bypass, the atrial septal defect was directly by a running suture. Through a transverse pulmonary arteriotomy, exploration of the pulmonary valve revealed a typical unicuspid valve. Only the right commissure was well developed while the height of the left raphe was reduced (Fig. 2, black circle, asterisk). The pulmonary valve repair consisted in a bicuspidisation (orientation: 180 degrees) by a large commissurotomy to the anterior wall of the pulmonary artery, extending slightly into the annular plane (Fig. 3a). Partial disinsertion of the leaflet along the annular plane of the two newly created leaflets allowed to adjust the effective height of the native leaflets. The neo-commissure was created with two separate patches of autologous pericardium secured to the wall of the pulmonary root. The patches were trimmed to fit the leaflet defects secondary to the disinsertion of part of the native valve from the annulus (Fig. 3b,c). Final adjustment of the effective height of the newly created leaflets was done by triangular plication of the posterior leaflet (Fig. 3d). The final result was a newly created bicuspid valve with a butterfly patch (Fig. 3e, white circular shape). The total cross-clamp and bypass time were 92 and 123 min, respectively. Perioperative echocardiogram

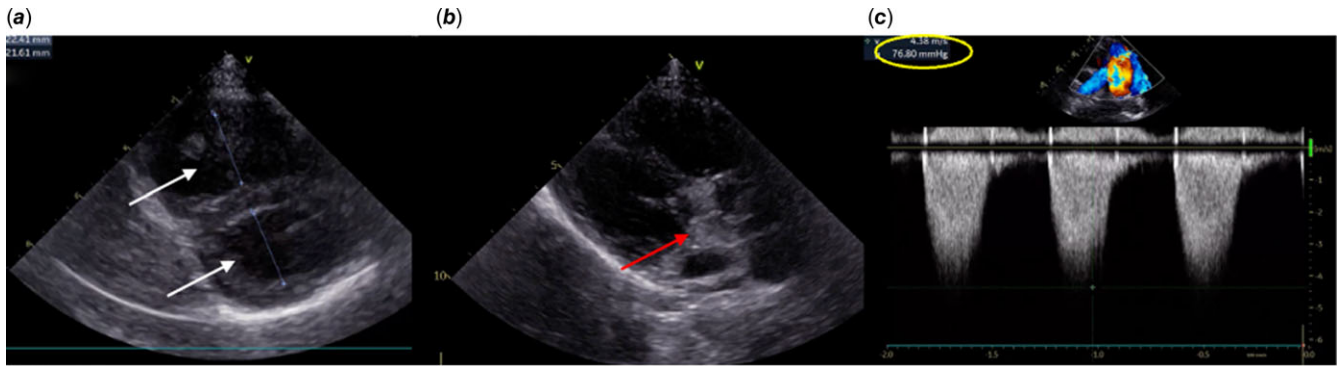


Figure 1. **a:** Parasternal short-axis papillary muscle view: dilated right chambers with a RV/ LV ratio = 0,9; **b:** Parasternal long-axis view: dysplastic, stenotic, bicuspid pulmonary valve; **c:** peak transpulmonary gradient of 76 mmHg.

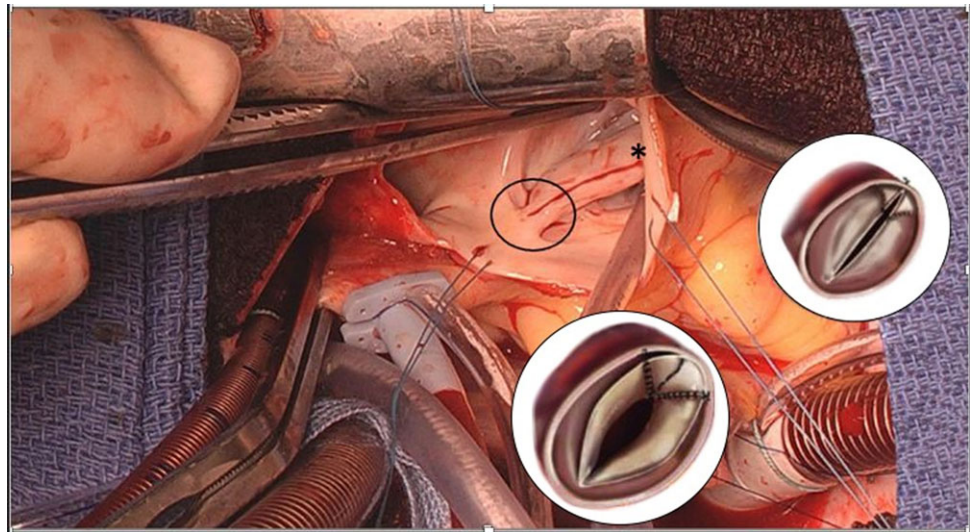


Figure 2. View from the surgeon's side of the pulmonary valve. Black circle: the unique commissure; white circular shape: final result of the butterfly patch in open and nearly closed positions. Asterisk: pseudo-commissural fusion of the left raphe.

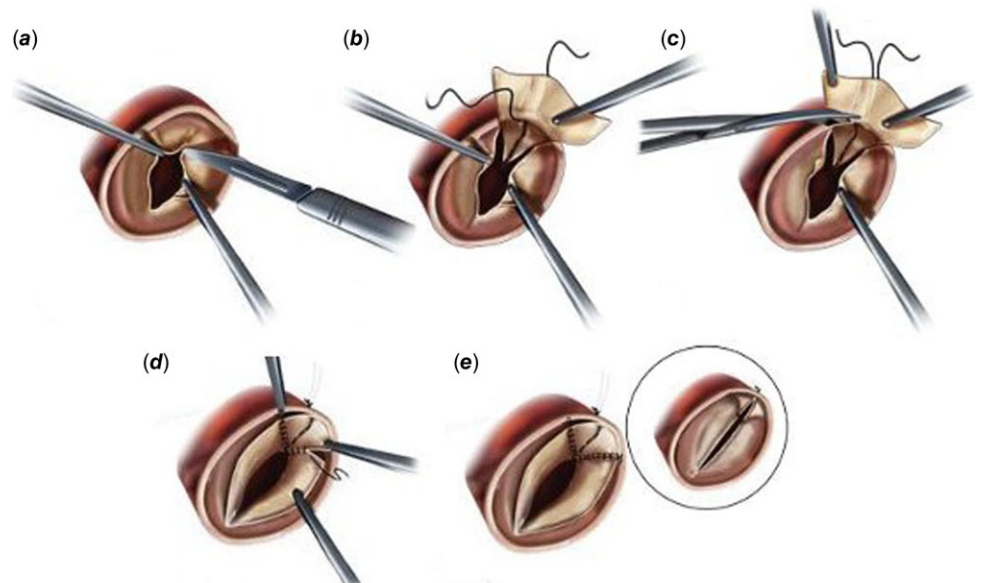


Figure 3. Key steps in the surgical therapy—how to transform a unicuspid autograft into a symmetric bicuspid valve. **a:** Division of the raphe, to create a new commissure. **b:** Anchoring of an autologous pericardial patch to the pulmonary root wall. **c:** Trimming of the patch. **d:** Suturing of the patch to the 2 leaflets' edges. **e:** Final result of the butterfly patch in open and nearly closed position.

Courtesy of Veronica Lorenz, M.D. [8]

showed a peak gradient of 15 mm Hg and trivial pulmonary regurgitation (Video 1). The patient made an uneventful recovery and was discharged on day 8.

Discussion

Unicuspid pulmonary valves are extremely rare, in the absence of complex CHD.² There is evidence for relief of pulmonary valve obstruction immediately after balloon pulmonary valvotomy and at follow-up.³ In our case, the percutaneous treatment was not the ideal option as the unexpected associated diagnosis of multi-fenestrated secundum atrial septal defect could not be treated percutaneously. The experience in bicuspidisation of unicuspid stenotic pulmonary valves is scarce, and as far as we know, there are no published case reports delineating a surgical approach for the repair of such pulmonary valve. The bicuspidisation technique was primarily developed for the unicommisural unicuspid aortic valves, also a very rare congenital malformation^[4,5]. Though the fresh autologous pericardium usually demonstrated thickening with retraction,⁶ there is evidence in the literature that in pulmonary position, it remains supple, non-calcified and is able to reduce the pulmonary regurgitation and maintain normal function of right ventricle at long term.⁷ Furthermore, it has also presented the capability to increase in length and consequently, the neo pulmonary valve can grow to meet the demand of the growing child. This was the rationale for using fresh pericardium patch for leaflet augmentation in our case. The main goals of our surgical approach were (a) to obtain a reduction of peak systolic pressure gradients across the pulmonary valve, below 25 ± 19 mmHg (15 mmHg)³ and (b) a better coaptation surface, which could theoretically lead to improved long-term results compared to interventional balloon valvotomy. Indeed, the percutaneous treatment presents a high percentage of pulmonary regurgitation and right ventricle dilation at long-term follow-up.⁸

Conclusion

The evidence for bicuspidisation of unicuspid stenotic pulmonary valves in the literature is scarce. Based on the experience with unicuspid aortic valve repair which is growing, the surgical steps to

bicuspidise a unicuspid pulmonary valve can be adapted, while requiring a broad surgical expertise in valve repairs. Detailed preoperative planning and a tailored approach for every patient are mandatory in order to achieve a good repair result.

Supplementary material. The supplementary material for this article can be found at <https://doi.org/10.1017/S104795112400043X>.

Financial support. None.

Competing interests. None.

References

1. Balushi AAL, Shuaili HAL, Khabori MAL, Maskri SAL. Pulmonary valve regurgitation following balloon valvuloplasty for pulmonary valve stenosis: single center experience. *Ann Pediatr Card* 2013; 6: 141. DOI: [10.4103/0974-2069.115258](https://doi.org/10.4103/0974-2069.115258).
2. Burrage MK, Baker C, Nikolaidou C, Myerson S, Ferreira VM. Rare unicuspid pulmonary valve and pulmonary artery aneurysm in an elderly asymptomatic patient. *Eur Heart J Cardiovasc Imaging* 2020; 21: 708–708. DOI: [10.1093/ehjci/jeaa008](https://doi.org/10.1093/ehjci/jeaa008).
3. Rao PS. Balloon pulmonary valvuloplasty: a systematic review. *Indian Heart J* 2023; 75: S0019483223004765. DOI: [10.1016/j.ihj.2023.12.007](https://doi.org/10.1016/j.ihj.2023.12.007).
4. Schäfers H-J, Aicher D, Riodynycheva S, et al. Bicuspidization of the unicuspid aortic valve: a new reconstructive approach. *Ann Thorac Surg* 2008; 85: 2012–2018. DOI: [10.1016/j.athoracsur.2008.02.081](https://doi.org/10.1016/j.athoracsur.2008.02.081).
5. Gofus Ján, Karalko M, Fila P, et al. Comparison of bicuspidization and Ross procedure in the treatment of unicuspid aortic valve disease in adults – insight from the AVIATOR registry. *Front Cardiovasc Med* 2022; 9: 900426. DOI: [10.3389/fcvm.2022.900426](https://doi.org/10.3389/fcvm.2022.900426).
6. Schwartzman WE, Jimenez M, Yates AR, et al. Patch materials for pulmonary artery arterioplasty and right ventricular outflow tract augmentation: a review. *Pediatr Cardiol* 2023; 44: 973–995. DOI: [10.1007/s00246-023-03152-7](https://doi.org/10.1007/s00246-023-03152-7).
7. Pande S, Arya A, Agarwal SK, et al. Long-term performance of untreated fresh autologous pericardium as a valve substitute in pulmonary position. *Ann Card Anaesth* 2022; 25: 164. DOI: [10.4103/aca.aca.22.21](https://doi.org/10.4103/aca.aca.22.21).
8. Merino-Ingelmo R, Soto JS, Coserria-Sánchez F, Descalzo-Señoran A, Valverde-Pérez I. Long-term results of percutaneous balloon valvuloplasty in pulmonary valve stenosis in the pediatric population. *Rev Esp Cardiol (Engl Ed)* 2014; 67: 374–379. DOI: [10.1016/j.rec.2013.08.020](https://doi.org/10.1016/j.rec.2013.08.020).