
Neuroimaging Highlight

Editor: David Pelz

Concomitant Viral and Bacterial Encephalitis after Temozolomide for Glioblastoma

Submitted by: Jenny P. Tsai, Nicolae Petrescu, Warren P. Mason, Leanne K. Casaubon

Can J Neurol Sci. 2014; 41: 84-85

Following resection of a left temporal lobe glioblastoma, a 59-year-old man received radiation therapy with concurrent and adjuvant temozolomide (TMZ). During this time, he was maintained on dexamethasone 4mg daily. His disease remained stable clinically and radiographically on this therapy. (Figure 1) Four months after radiation therapy, he presented with a one-week history of confusion, hallucinations and fever. A brain computed tomogram scan showed a resection site abscess for which he underwent surgical drainage. Samples obtained at surgery for bacterial culture demonstrated gram positive cocci. A complete blood count revealed mild lymphopenia with a serum lymphocyte count between 600 and 1,000 x 10⁶/L, and mildly elevated absolute neutrophil count between 7 and 15 x 10⁹/L. Broad-spectrum antibiotic therapy was therefore initiated early for suspected bacterial infection in an immunocompromised patient. However, the patient did not improve clinically and remained stuporous with a best post-operative Glasgow Coma Scale (GCS) never exceeding 7. An electroencephalogram performed three days after surgery showed bilateral anterior temporal periodic lateralizing epileptiform discharges (PLEDs). At that time a brain magnetic resonance imaging (MRI) demonstrated new bilateral temporal, orbito-frontal, and thalamic hyperintensities on T2-weighted sequences (Figure 2).

These findings were suspicious for acute Herpes Simplex virus (HSV) encephalitis, and thus acyclovir was added to his antibiotic regimen. Cerebrospinal fluid (CSF) analysis was positive for herpes simplex virus type 1 by polymerase chain reaction (PCR). Given a high pre-test probability and the known high sensitivity and specificity of CSF PCR analysis for viral meningoencephalitis, the result was concluded as confirmative for HSV-1 encephalitis.¹

Despite early broad-spectrum anti-bacterial therapy and immediate initiation of acyclovir following the brain MRI that was suspicious for herpes encephalitis, the patient failed to improve clinically. Follow-up MRI performed three weeks later demonstrated hemorrhagic necrosis of the right anterior temporal lobe and progressive and extensive edema involving adjacent cortex. (Figure 3) Although the patient survived, his

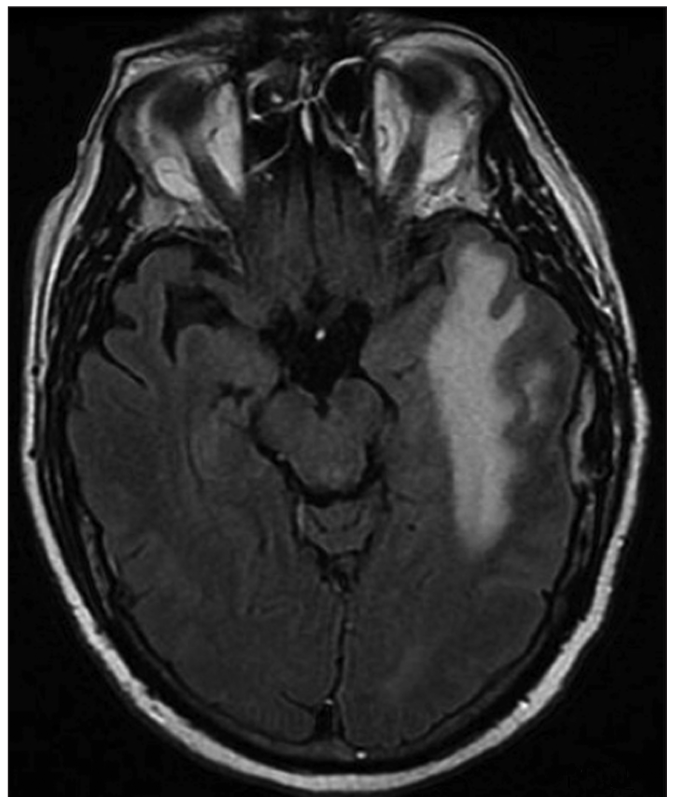


Figure 1: The patient's brain MRI one month prior to the onset of the acute infectious illness showing long-standing localized T2 hyperintensity in the area of the glioblastoma.

functional status was significantly impaired, and no further anticancer therapy was administered. The patient was transferred to palliative care.

Temozolomide is myelosuppressive and causes lymphopenia, with selective CD4+ T-lymphocyte suppression in addition to diminished peripheral CD8+ T-cell and B-cell populations.²

From the Division of Neurology, Department of Medicine, University Health Network-Princess Margaret Hospital, University of Toronto, Toronto, Ontario, Canada.

RECEIVED FEBRUARY 25, 2013. FINAL REVISIONS SUBMITTED AUGUST 30, 2013.

Correspondence to: Jenny P. Tsai, Toronto Western Hospital, University Health Network, West wing, 5th Floor, 399 Bathurst St., Toronto, Ontario, M5T 2S8, Canada.

Email: jennyp.tsai@utoronto.ca.

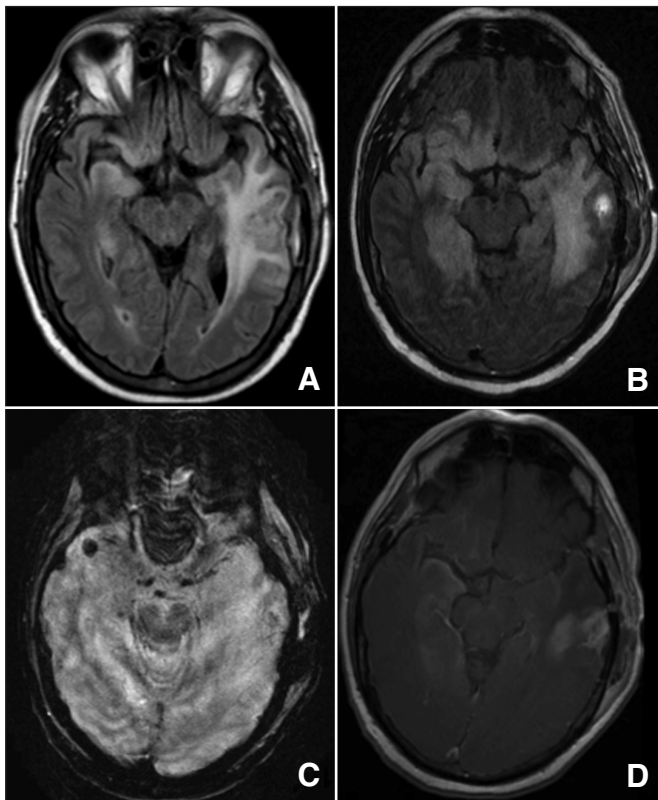


Figure 2: At presentation, brain MRI demonstrates bilateral mesial temporal and orbitofrontal T2 hyperintensities (A, FLAIR). After abscess drainage, further extension of hyperintense T2 signal is noted (B, FLAIR), with features of microhemorrhages (C, Gradient Echo, GRE) and bilateral meningeal enhancement (D, T1-weighted imaging with gadolinium).

Although infectious complications attributed to TMZ alone are rare and carry limited clinical sequelae, caution is warranted in glioma patients who receive this agent. Moreover, many patients with glioblastoma have chronic corticosteroid exposure, which can aggravate the immunosuppressive effects of TMZ by promoting susceptibility to bacterial, viral, fungal and parasitic infections.³ This predisposition increases with continuous-dosing TMZ regimens, cumulative TMZ dose delivered and duration of treatment.^{2,4} Cases of disseminated herpes zoster, *Pneumocystis jirovecii*, *Cryptococcus*, *Strongyloidis*, and herpes simplex infections, have been reported in patients with gliomas treated with TMZ.^{4,7} Similarly, lymphocytopenia secondary to TMZ may lead to reactivation of cytomegalovirus, resulting in pulmonary, gastrointestinal, and neurological complications, occurring as early as one month after initiation of TMZ therapy.^{2,4,6-8} Furthermore, presentation of viral encephalitis may be indolent or mimicking bacterial infection, with a mortality of 20-30% in untreated patients, hence underlining the importance of high clinical caution.⁹

Patients with glioblastoma receiving standard therapy that includes cranial irradiation, temozolomide chemotherapy and chronic exposure to corticosteroids are an immunosuppressed population. Awareness of their susceptibility to a variety of

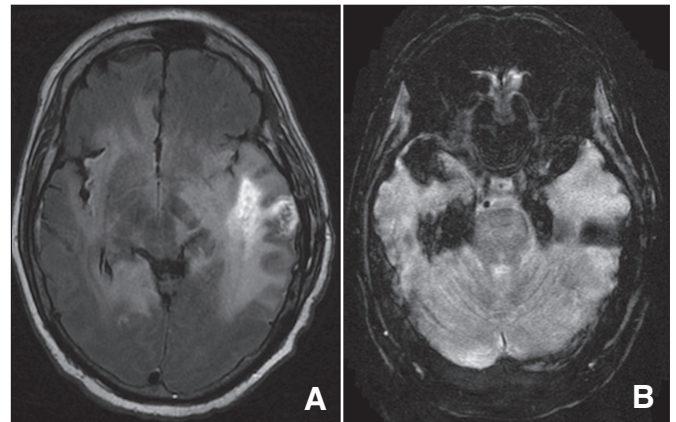


Figure 3: Despite early broad-spectrum antibiotic and anti-viral therapy initiated immediately after the first post-operative MRI, radiographic progression continued (A, FLAIR), with marked exacerbation in hemorrhagic necrosis on susceptibility sequence imaging (B, GRE).

bacterial and viral infections is key to timely diagnosis and initiation of appropriate antimicrobial therapies.

REFERENCES

- DeBiasi RL, Kleinschmidt-DeMasters BK, Weinberg A, Tyler KL. Use of PCR for the diagnosis of herpesvirus infections of the central nervous system. *J Clin Virol.* 2002 Jul;25 Suppl 1:S5-11.
- Su YB. Selective CD4+ Lymphopenia in melanoma patients treated with temozolomide: a toxicity with therapeutic implications. *J Clin Oncol.* 2004 Feb 15;22(4):610-16.
- Gaviani P, Silvani A, Lamperti E, et al. Infections in neuro-oncology. *Neurol Sci.* 2011 Oct 15;32(S2):233-6.
- Schwarzberg AB, Stover EH, Sengupta T, et al. Selective lymphopenia and opportunistic infections in neuroendocrine tumor patients receiving temozolomide. *Cancer Invest.* 2007 Jan;25(4):249-55.
- Aregawi D, Lopez D, Wick M, Scheld WM, Schiff D. Disseminated strongyloidiasis complicating glioblastoma therapy: a case report. *J Neurooncol.* 2009 Mar 31;94(3):439-43.
- Meije Y, Lizasoain M, García Reyne A, et al. Emergence of cytomegalovirus disease in patients receiving temozolomide: report of two cases and literature review. *Clin Infect Dis.* 2010 Jun 15;50(12):e73-6.
- Okita Y, Narita Y, Miyakita Y, Ohno M, Nagai S, Shibui S. Management of Cytomegalovirus infection in a patient with malignant glioma treated with temozolomide and steroids. *Intern Med.* 2012;51(20):2967-71.
- Stupp R, Mason WP, van den Bent MJ, et al. Radiotherapy plus concomitant and adjuvant temozolomide for glioblastoma. *N Engl J Med.* 2005 Mar 10;352(10):987-96.
- Sundén B, Larsson M, Falkeborn T, et al. Real-time PCR detection of human herpesvirus 1-5 in patients lacking clinical signs of a viral CNS infection. *BMC Infectious Diseases.* 2011 Aug 17;11(1):220.