

NORMAL AND ABERRANT PALMAR CREASES IN TWINS AND SIBLINGS

C. C. PLATO (1), W. WERTELECKI (2), J. T. SCHWARTZ (3)

- (1) National Institute on Aging, Gerontology Research Center, National Institutes of Health, Baltimore, Maryland, USA
- (2) Department of Medical Genetics, University of South Alabama, College of Medicine, Mobile, Alabama, USA
- (3) Office of Biometry and Epidemiology, National Eye Institute, National Institutes of Health, Bethesda, Maryland, USA

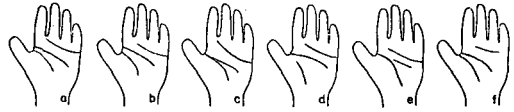
The present study involving MZ and DZ twin pairs, as well as paired normal sibs, was undertaken to investigate further the genetic involvement in the formation of normal palmar crease patterns, as well as simian and Sydney patterns. Two variations of normal creases were investigated: the thenar type R and the distal type I. Both types cluster in families. The R is more frequent in the females. For both types, MZ twins are more concordant than DZ twins or sibs. Sib studies suggest strong genetic involvement in the development of both the R and I crease types. Parents with simian and/or Sydney creases have more children with these traits than offspring of parents without these traits; however, concordance rate comparisons of MZ or DZ twins and sibs do not suggest strong genetic involvement as in the case of the R and I crease types.

Normal palms usually have three primary flexion creases: the distal, the proximal and the thenar. These creases, even though they do not meet the strict definition of dermatoglyphics, are very often studied and reported along with the other dermatoglyphic features. The three main palmar creases have fairly well defined positions and directions. Several examples are given in Fig. 1.

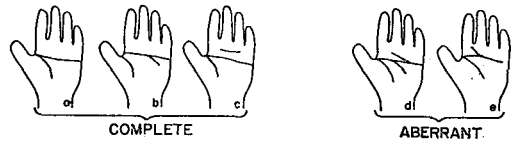
The proximal and distal palmar creases have been investigated extensively, mainly due to their occasional "fusion" to form a single transverse palmar crease, simian crease (Fig. 1:II). The frequency of the simian crease varies from population to population, and it is unusually high among patients with certain congenital anomalies; the best known of these is, of course, Down's syndrome. Recently a special form of proximal flexion crease was recognized by Menser and Purvis-Smith (1969), which they called Sydney crease. By definition, a Sydney crease is a proximal crease which extends to the ulnar margin of the palm (Fig. 1:III). High frequencies of Sydney creases were found among patients with leukemia (Menser and Purvis-Smith 1969, Purvis-Smith and Menser 1973, Wertelecki et al. 1973). Detailed discussion of the various forms and frequencies of the simian and Sydney creases in normal population and in different congenital anomalies were reviewed and presented elsewhere (Wertelecki and Plato 1974b). The thenar palmar crease is rarely investigated. In a recent report (Wertelecki and Plato 1974a) a form of the thenar crease, thenar R, was studied, which originates at the radial border of the palm, separately from the proximal crease (Fig. 2). The same Figure also shows the type of distal crease, distal I, which originates from the II interdigital area of the palm. Both the thenar R and the distal I type creases were found to occur more frequently in children of whom either one or both parents had these traits (Wertelecki and Plato 1974a).

The present study dealt with the expression of the palmar creases in MZ and DZ twin pairs and sib

I NORMAL



II SIMIAN



III SYDNEY

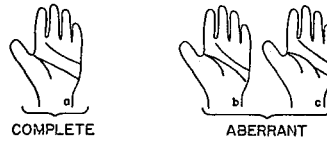


Fig. 1. Example of normal, simian, and Sydney creases.

Table. Concordance for the palmar crease types in twins and sibs (% values)

Pair composition	Thenar R	Distal I
MZ twins	72.0	74.0
DZ twins (same sex)	65.0	38.0
Sibs (same sex)	23.0	28.0
Sibs (unlike sex)	15.0	12.0

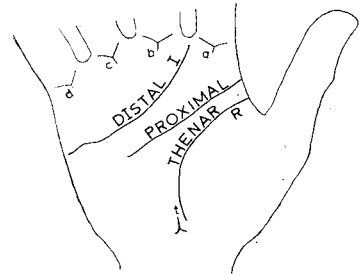

Fig. 2. The three main palmar creases with specific examples of the distal I and thenar R types.

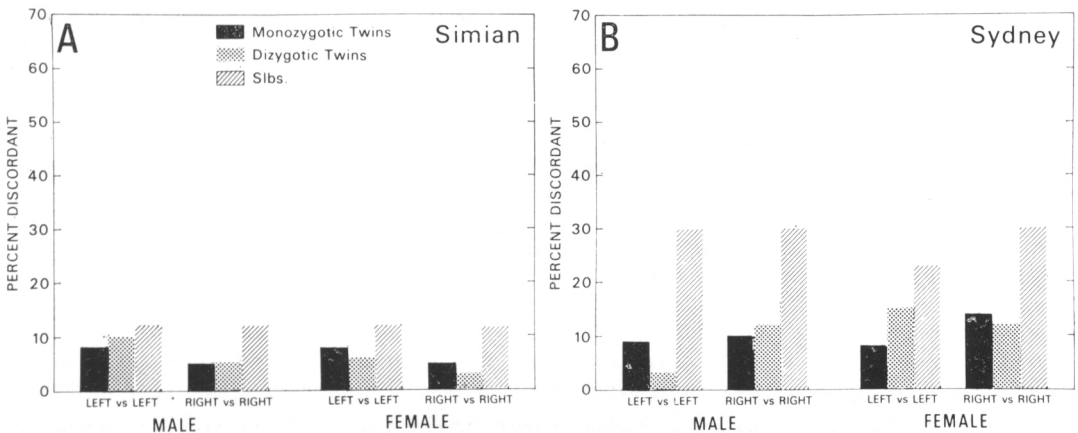


Fig. 3. Homolateral discordance in twin and sib pairs for the simian and Sydney palmar creases.

pairs. Fig. 3 presents the percentage of homolateral discordance for the various paired comparisons of the simian and Sydney creases. In the simian creases (Fig. 3A), although the sibs tend to demonstrate higher percentage of homolateral discordance than the twin pairs, all chi-square values were nonsignificant. The Sydney crease histograms (Fig. 3B) also indicate a higher percentage of homolateral discordance. In this case, however, the male sibs were significantly more discordant than either type of twins, while the female sibs differed significantly only from the MZ twins. These results suggest that even though there are familial tendencies (Wertelecki and Plato 1974c) in the occurrence of both the simian and the Sydney creases, hereditary factors are of lesser importance, if any, in their etiology. Table 1 cites the frequencies in which both pair members have bilateral thenar R or distal I creases. These preliminary results suggest a higher degree of genetic involvement in the formation of distal I crease and strong intrauterine influence in the thenar R development. Investigations are presently under way to evaluate further the extent of the genetic and intrauterine effects in the etiology of the thenar R, distal I and the simian and Sydney creases.

REFERENCES

- Menser M. A., Purvis-Smith S.G. 1969. Dermatoglyphic defects in children with leukemia. *Lancet*, 1: 1076.
- Plato C.C., Cereghino J.J., Steinberg F.S. 1973. Palmar dermatoglyphics of Down's syndrome: revisited. *Pediatr. Res.*, 7: 111-118.
- Purvis-Smith S.G., Menser M.A. 1973. Dermatoglyphics in leukemia. *Br. Med. J.*, 4: 646-648.
- Wertelecki W., Plato C.C., Fraumeni J.F., Niswander J.D. 1973. Dermatoglyphics in leukemia. *Pediatr. Res.*, 7: 620-626.
- Wertelecki W., Plato C.C. 1974a. Subclassification of normal palmar creases--A tool to assess prenatal development. *Proc. 14th Congr. Pediatrics, Buenos Aires, Peditria*, 14: 108-111.
- Wertelecki W., Plato C.C. 1974b. The simian and Sydney crease--A Survey. *Proc. L.S. Penrose Memorial Colloquium on Dermatoglyphics, W. Berlin* 1973.
- Wertelecki W., Plato C.C. 1974c. Palmar flexion creases in birth defects and leukemia: a survey of 5000 individuals stressing normal ethnic, sex and familial differences. *Proc. 14th Int. Congr. Pediatrics, Buenos Aires, Peditria*, 14: 111-113.