




Neuroimaging Highlight

Basal Ganglia Involvement in Susac Syndrome During Pregnancy

Erin Nuro¹ , Cathy Meng Fei Li¹, Andrew Leung² , Lillian Barra^{3,4}, Anita Dayal-Harbour^{1,5} and Jennifer Mandzia¹ 

¹Department of Clinical Neurological Sciences, London Health Sciences Centre, Western University, London, ON, Canada, ²Department Of Medical Imaging, London Health Sciences Centre, Western University, London, ON, Canada, ³Department of Medicine, Division of Rheumatology, and Department of Epidemiology and Biostatistics, the University of Western Ontario, London, ON, Canada, ⁴Lawson Health Research Institute, London, ON, Canada and ⁵Thompson Medical Centre, London, ON, Canada

Keywords: Autoimmune disease; basal ganglia; corpus callosum; Susac

(Received 7 March 2024; final revisions submitted 27 May 2024; date of acceptance 10 July 2024)

A 33-year-old woman at 32 weeks gestational age presented with a 4-week history of encephalopathy and hearing loss. Her past medical history was unremarkable, and she was only taking prenatal vitamins. The neurological examination was remarkable for cognitive slowing, apathy and difficulty hearing bilaterally. Brain MRI revealed bilateral caudate nuclei, lentiform nuclei, external capsules and corpus callosum FLAIR hyperintensities (Figure 1a). Audiological testing confirmed bilateral sensorineural hearing loss. Ophthalmological examination showed visual acuity of 20/20 bilaterally. Humphrey visual field analyzer testing was normal. Fundus fluorescein angiography to assess for branch retinal artery occlusion (BRAO) was not performed because of its relative contraindication in pregnancy.¹ A lumbar puncture did not show evidence of any infectious, inflammatory or autoimmune process.

The patient was acutely treated with IVIG 2 g/kg over 5 days and high-dose steroids of 1 g methylprednisolone IV once daily for 3 days. This was followed by monthly IVIG and 50 mg prednisone maintenance therapy with a slow taper over a few months. At a 4-month follow-up, she endorsed improvement in cognition and hearing loss. Repeat audiological testing revealed near resolution of sensorineural hearing loss in the right ear, but ongoing profound hearing loss in the left ear. In addition, she had a successful at-term delivery without any fetal or neonate complications and has continued to show disease stability at one year.

Repeat MRI 4 months after initial imaging showed resolution of basal ganglia FLAIR hyperintensities and near resolution of other brain lesions including the corpus callosum (Figure 1b).

Susac syndrome is a rare autoimmune vasculo-occlusive disease in which circulating antibodies attack the vascular endothelium, resulting in arterial microinfarcts affecting the inner ear, retina and CNS.^{2,3} Diagnosis is based on clinical presentation, brain MRI, audiometry and retinal fluorescein angiography. Although the classic triad of Susac syndrome includes encephalopathy, hearing loss and BRAO,^{4,5} only 13% of patients exhibit all three at disease onset.² Other potential diagnoses include MS, ADEM, CNS vasculitis, hypoxic ischemic encephalopathy and cerebrovascular disease.

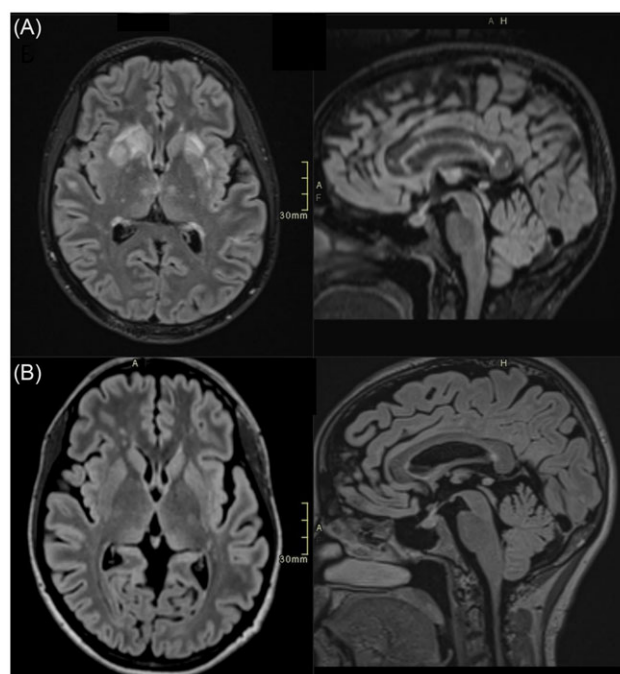


Figure 1. Brain MRI depicting basal ganglia and corpus callosum involvement in Susac syndrome. (A) Axial and sagittal brain MRI with T2 FLAIR depicting hyperintense signal in the bilateral basal ganglia and corpus callosum. (B) Axial and sagittal brain MRI with T2 FLAIR showing improvement in signal abnormality in the basal ganglia and corpus callosum four months post-treatment initiation.

MRI findings include multiple hyperintense foci on T2-weighted imaging involving both the white and gray matter, corpus callosum, leptomeninges, thalamus and cerebellum.⁶ Involvement of the corpus callosum with characteristic “snowball” lesions is a pathognomonic finding on MRI.⁶ Epidemiologically, the disease mainly affects young women with a female/male ratio of 3:1.³

Corresponding author: Jennifer Mandzia; Email: jennifer.mandzia@lhsc.on.ca

Cite this article: Nuro E, Li CMF, Leung A, Barra L, Dayal-Harbour A, and Mandzia J. Basal Ganglia Involvement in Susac Syndrome During Pregnancy. *The Canadian Journal of Neurological Sciences*, <https://doi.org/10.1017/cjn.2024.306>

Several case reports indicate that pregnancy or the postpartum period may exacerbate Susac syndrome, suggesting that immune modulation during pregnancy affects this auto-immune condition.⁷ To date, there are 33 cases of Susac's in pregnancy, the majority of which describe several corpus callosum lesions, with 4 cases showing additional basal ganglia involvement. Of these four cases, two patients presented in the antenatal period with either persistent or partial remission of symptoms despite therapies.⁸

To our knowledge, this is the first report of Susac syndrome in the antenatal period with predominant basal ganglia involvement, showing near-complete imaging resolution posttreatment, successful term delivery and improved cognitive symptoms and hearing. Furthermore, our case emphasizes the benefits of timely diagnosis and early aggressive therapy in Susac syndrome.

Author contributions. EN contributed substantially to the study concept and design, data acquisition and analysis and drafting of the manuscript and figures.

CMFL contributed substantially to data acquisition and analysis and reviewed the manuscript for important intellectual content.

AD contributed substantially to the study concept and design, data acquisition and analysis and drafting of the manuscript and figures.

AL contributed substantially to data acquisition and analysis and reviewed the manuscript for important intellectual content.

LB contributed substantially to data acquisition and analysis and reviewed the manuscript for important intellectual content.

JM contributed substantially to the study concept and design, data acquisition and analysis and drafting of the manuscript and figures.

Funding statement. None.

Competing interests. None.

References

1. Kornblau IS, El-Annan JF. Adverse reactions to fluorescein angiography: a comprehensive review of the literature. *Surv Ophthalmol.* 2019;64:679–93. DOI: [10.1016/j.survophthal.2019.02.004](https://doi.org/10.1016/j.survophthal.2019.02.004).
2. Dorr J, Krautwald S, Wildemann B, et al. Characteristics of Susac syndrome: a review of all reported cases. *Nat Rev Neurol.* 2013;9:307–16. DOI: [10.1038/nrneurol.2013.82](https://doi.org/10.1038/nrneurol.2013.82).
3. Pereira S, Vieira B, Maio T, Moreira J, Sampaio F. Susac's syndrome: an updated review. *Neuroophthalmology.* 2020;44:355–60. DOI: [10.1080/01658107.2020.1748062](https://doi.org/10.1080/01658107.2020.1748062).
4. Kleffner I, Duning T, Lohmann H, et al. A brief review of Susac syndrome. *J Neurol Sci.* 2012;322:35–40. DOI: [10.1016/j.jns.2012.05.021](https://doi.org/10.1016/j.jns.2012.05.021).
5. Kleffner I, Dörr J, Ringelstein M, et al. Diagnostic criteria for Susac syndrome. *J Neurol Neurosurg Psychiatry.* 2016;87:1287–95. DOI: [10.1136/jnnp-2016-314295](https://doi.org/10.1136/jnnp-2016-314295).
6. Susac JO, Murtagh FR, Egan RA, et al. MRI findings in Susac's syndrome. *Neurology.* 2003;61:1783–7. DOI: [10.1212/01.WNL.0000103880.29693.48](https://doi.org/10.1212/01.WNL.0000103880.29693.48).
7. Ioannides ZA, Airey C, Fagermo N, Blum S, McCombe PA, Henderson RD. Susac syndrome and multifocal motor neuropathy first manifesting in pregnancy. *Aust N Z J Obstet Gynaecol.* 2013;53:314–7. DOI: [10.1111/ajo.12069](https://doi.org/10.1111/ajo.12069).
8. Willekens B, Kleffner I. Susac syndrome and pregnancy: a review of published cases and considerations for patient management. *Ther Adv Neurol Disord.* 2021;14:1756286420981352. DOI: [10.1177/1756286420981352](https://doi.org/10.1177/1756286420981352).