

Cerebral Hemodynamics in Migraine

V. C. HACHINSKI, J. OLESEN, J. W. NORRIS,
B. LARSEN, E. ENEVOLDSEN, AND N. A. LASSEN

SUMMARY: *Clinical and angiographic findings in migraine are briefly reviewed in relation to cerebral hemodynamic changes shown by regional cerebral blood flow (rCBF) studies. Three cases of migraine studied by the intracarotid xenon 133 method during attacks are reported.*

In classic migraine, with typical prodromal symptoms, a decrease in cerebral blood flow has been demonstrated during the aura. Occasionally, this flow decrease persists during the headache phase. In common migraine, where such prodromata are not seen, a flow decrease has not been demonstrated.

RÉSUMÉ: *Les résultats des examens cliniques et angiographiques dans la migraine sont revus en relation avec les modifications hémodynamiques démontrées par les études du flot cérébral régional (rCBF). L'auteur rapporte 3 cas de migraine étudiés, pendant l'attaque, avec la méthode au xenon 133 intracarotidien.*

Dans la migraine classique avec symptômes prodromaux classiques on note une diminution du flot cérébral durant l'aura. Parfois cette diminution persiste pendant la phase de céphalée. Par contre dans la migraine commune, où ces prodromes ne sont pas connus, on ne note pas de diminution du flot.

During the headache phase of both types of migraine, rCBF has usually been found to be normal or in the high range of normal values. The high values may represent postischemic hyperemia, but are probably more frequently secondary to arousal caused by pain.

Thus, during the headache phase rCBF may be subnormal, normal or high. These findings do not exclude the possibility of distension of the larger intracranial arteries during migraine headache, but the angiographic evidence, however limited, does not support this speculation.

Au cours de la phase de céphalées, dans les deux types de migraine, le rCBF est généralement normal ou même élevé. Ces valeurs élevées représentent peut-être une hyperémie postischémique, mais sont probablement plus souvent causées par la stimulation secondaire à la douleur.

Donc, pendant la phase de céphalée migraineuse, le rCBF peut être bas, normal ou élevé. Ceci n'exclut pas la possibilité d'une distension des plus grosses artères pendant la céphalée migraineuse, mais l'évidence angiographique, même limitée, n'appui pas cette spéculation.

The prevailing view of the pathogenesis of classical migraine postulates that the aura is due to vasoconstriction of cerebral vessels and the headache is due to dilatation of extracranial arteries. This view is based on clinical, experimental and angiographic observations, and on direct measurement of the cerebral blood flow (CBF) during migraine.

Clinical Observations

Clinical observations on the possible vascular etiology of migraine date from at least the time of Sir Thomas Willis (McNaughton, 1976). Subsequent reports have added detail but not substance to Willis' evidence. Analysis of the visual symptoms of migraine suggests not only a vascular pathogenesis, but that the maximum disturbance is within the supply of individual intracranial arteries (Hachinski et al., 1973). Marcussen and Wolff (1950) found that the physiological vasodilator CO₂ abolished the prodromal scotomata in patients with migraine. The physician-migraneur Cahan recorded his visual field defect before and after he inhaled the vasodilator amyl nitrate and found that inhalation reduced the extent of his visual deficit (Wolff, 1972). The elimination or limitation of visual symptoms by such vasodilators implies underlying vasoconstriction, although the effects could be produced by other mechanisms. At times, a permanent neurological deficit occurs during the course of a migraine attack, which on rare occasions may prove fatal (Guest and Wolff, 1964). Computerized tomography of the brain confirms that such deficits are secondary to cerebral infarction (Mathew et al., 1976; Hungerford et

From the MachLachlan Stroke Unit, Sunnybrook Medical Centre, Toronto, Canada (V. C. Hachinski and J. W. Norris); the Department of Neurology, Rigshospitalet, Copenhagen, Denmark (J. Olesen); the Department of Clinical Physiology, Bispebjerg Hospital, Copenhagen, Denmark (B. Larsen and N. A. Lassen); the Department of Neurology, Arhus Kommunehospital, Arhus, Denmark (E. Enevoldsen).

Reprint requests to: Dr. V. C. Hachinski, Sunnybrook Medical Centre, 2075 Bayview Avenue, Toronto, Ontario, Canada M4N 3M5.

al., 1976; Cala and Mastaglia, 1976) presumably due to severe vasoconstriction.

Angiographic Observations

Dukes and Veith (1964) reported a case in which angiography during an attack of classic migraine showed vasoconstriction during the prodromal phase. Unfortunately, the PaCO₂ was not measured and thus the changing caliber of the vessels may have been due simply to the hyperventilation that is common in patients in distress. They also noted reflux of the contrast material into the basilar artery following an internal carotid injection. Other authors have made similar observations (Skinhøj, 1973; Norris et al., 1975). This finding is not pathological, but it is unusual, even when the contrast material is administered via an intracarotid catheter. It implies that the pressure in the carotid system is greater than in the vertebro-basilar system. This could be produced either by increased pressure in the carotid distribution (as in arteriolar vasoconstriction) or by decreased resistance in the vertebro-basilar distribution. The occurrence of this phenomenon may be enhanced by hyperventilation (Hachinski et al., 1977).

Cerebral Blood Flow Studies

The clinical and angiographic evidence for the vascular hypothesis in migraine is indirect. Direct measurements of CBF by O'Brien (1971) in 18 patients showed a 23% decrease in CBF during the aura phase and an 8% increase during the headache phase. The CBF studies were performed by the xenon 133 (¹³³Xe) inhalation technique. This method has a potential for error in migraine because it cannot distinguish reliably between cerebral and extracranial blood flow. In migraine, the cerebral perfusion may be decreasing while simultaneously the extracranial blood flow may be increasing. Skinhøj and Paulson (1969) and later Skinhøj (1973) using the intracarotid ¹³³Xe method (which avoids the problem of extracranial contamination) also observed a decrease in global and sometimes re-

gional CBF (rCBF) during the aura and an increased CBF during the headache phase. In one of the cases, headache began while the aura persisted and showed a mixed pattern of regional increases and decreases of cerebral blood flow. Mathew et al. (1976) made similar observations in cases of classic and complicated migraine. In addition, they observed that there was an increased CBF during headache in common migraine. All these observations were made during different phases of migraine on different patients. Norris et al. (1975) reported a case of classic migraine in whom CBF determinations were made during the aura and headache phase on the same patient during the same attack. There was a considerable decrease of CBF during the aura, which rose during the headache phase. The following reports illustrate various changes in CBF during attacks of classic and common migraine.

METHODS

Informed consent was obtained from the patient in all cases. Regional cerebral blood flow was measured by the intra-arterial ¹³³Xe injection method (Lassen and Ingvar, 1961). This involves percutaneous insertion of a thin polyethylene catheter into the internal carotid artery (Seldinger technique) and the intra-arterial injection of a bolus of ¹³³Xe in saline. The washout of isotope is then followed by external collimated scintillation detectors, each measuring a small area of the hemisphere. Case 2 was studied with a 32 detector CBF machine. The 254 channel equipment (Sveinsdottir et al., 1977) used to study cases 1 and 3 has a spatial resolution of approximately 1 cm. (Hougaard et al., 1976). The rCBF values are calculated by the initial slope method (CBF init) as described by Olesen et al. (1971). In normal man the rCBF thus measured averages about 50 ml/100 gms per minute with the higher values anteriorly. The normal range is from about 40 to 70 ml/100 grams per minute and ischemia can be considered to be present when rCBF values of 20 ml/100 grams per minute or below are recorded. These values

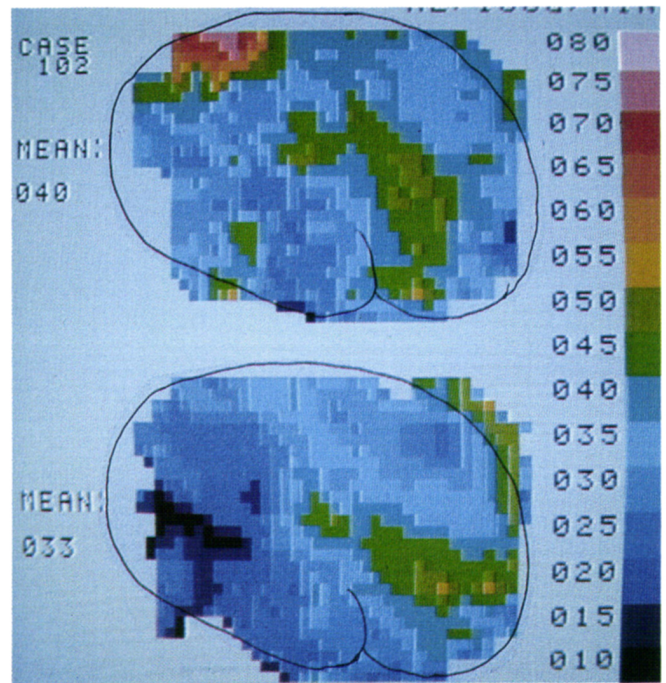
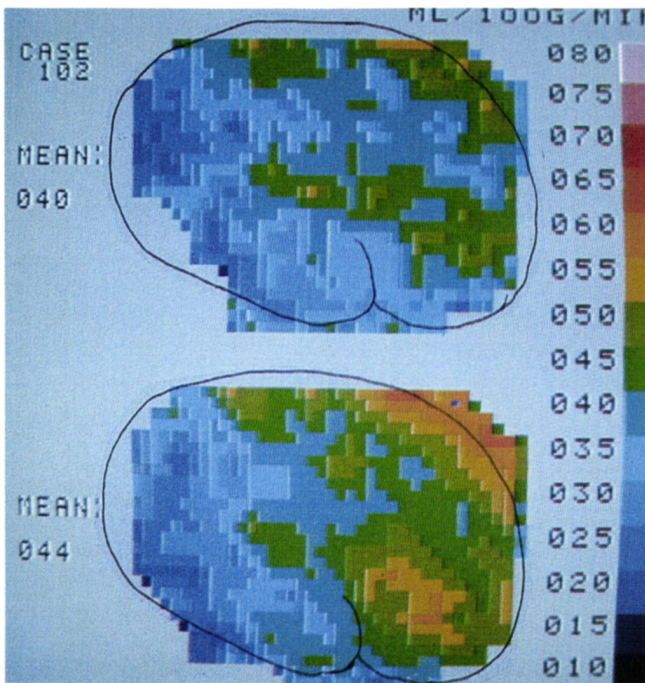
are displayed in coded colors so that the rCBF of each region can be appreciated visually by comparison with a color scale. All values are corrected for remaining radioactivity from preceding measurements, and arterial PaCO₂ was measured during each flow determination. Intra-arterial blood pressure was measured by a transducer.

Case 1

A 45-year-old man had weekly attacks since childhood, consisting of right-sided throbbing headaches, sometimes preceded by visual blurring in the right eye. On admission to hospital following a migraine attack, he was drowsy and restless and showed left leg weakness and left hemianesthesia. Lumbar puncture revealed normal cerebro-spinal fluid (CSF) and the electroencephalogram (EEG) was normal. CBF was evaluated on the fifth hospital day. Low values were found (Fig. 1) both in the resting state and while listening to simple words. Shortly afterwards, he developed a severe right frontal headache with nausea and photophobia, and then became obtunded and confused. Two further CBF studies were performed at 5 minutes and 25 minutes after this attack (Fig. 2 and Table 1). CBF was now decreased even further with values below the ischemic threshold of 20 ml/100 grams per minute in

TABLE 1
Cerebral Blood Flow During Migraine

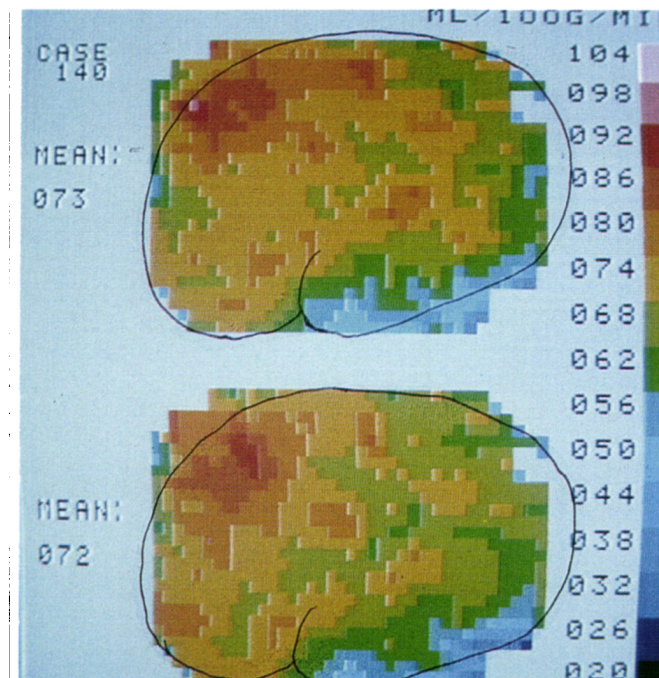
	MABP (mmHg)	PaCO ₂ (mmHg)	CBF init (ml/100 g/min)
CASE 1			
rCBF 1	85	42	40
- 2	80	42	44
- 3	90	40	40
- 4	94	46	33
CASE 2			
rCBF 1	78	35	34
- 2	81	38	38
- 3	77	36	38
- 4	73	33	25
CASE 3			
rCBF 1	105	41	73
- 2	100	41	72



REGIONAL CEREBRAL BLOOD FLOW (rCBF) IN CLASSIC MIGRAINE

Figure 1—Case 1. Right lateral view. Each square represents the rCBF in a discrete area of the brain in ml/100 gm/min according to the color scale on the right of the figure. The rCBF values are low both during rest (upper figure) and while listening to simple words (lower figure).

Figure 2—Case 1. The code is as in Fig. 1. rCBF 5 minutes (upper figure) and 25 minutes (lower figure) after the onset of a migraine attack. At 5 minutes there is an area of high flow but the CBF is otherwise decreased. At 25 minutes the rCBF is even lower, with values below the ischemic threshold of 20 ml/100 gm/min in the posterior part of the hemisphere (lower figure).



rCBF IN COMMON MIGRAINE

Figure 3—Case 3. The code is similar to that in Fig. 1. rCBF while the headache was mild (upper figure) and severe (lower figure). There is no significant difference between the mean or the regional CBF.

large areas of the posterior half of the right hemisphere.

This case demonstrates an extremely low cerebral blood flow during a combined headache and aura (obtundation) phase of an attack of classic migraine.

Case 2

This 26-year-old male had no family history of migraine and, except for an episode of concussion 8 years before admission, his previous health had been good. He was admitted following two attacks of blurring of the right visual field followed by parasthesia in the tongue and the hand accompanied by aphasia. About one hour later, bilateral throbbing headache developed, more severe on the right side. Neurological examination was normal, and the EEG showed some bitemporal 4-7 Hz activity with sharp-waves.

Regional cerebral blood flow was measured in the resting state, and following the injection of somatostatin (37.5 micrograms) (growth hormone release inhibiting hormone) into the carotid artery. A third CBF study was performed in the resting state and finally, shortly after an injection of 200 micrograms of somatostatin into the carotid artery. The purpose of somatostatin injection was to study its effects on cerebral blood flow in general as part of a larger series, and not to study its effects on migraine. Immediately before the last measurement, the patient developed one of his usual classic migraine attacks. At the end of the study he had a right homonymous hemianopia, with a marked receptive and expressive aphasia and later developed a throbbing, bilateral headache with nausea. Carotid angiogram performed during the aura phase of the migraine attack showed prolonged transit time and pronounced filling of the basilar artery.

This case demonstrates marked CBF reduction during the aura of classical migraine with values approaching the level critical for metabolism (Table 1). Somatostatin may have triggered this migraine attack or the occurrence of the headache may have been purely coinci-

dental, but probably the latter, since injection of somatostatin intravenously has not caused migraine in a series of patients (Hansen and Lundbaek, 1977).

Case 3

A 31-year-old female, with no family history of migraine, was well up to 2½ years prior to admission. She then developed recurrent episodes of left-sided throbbing hemicrania, with nausea, vomiting, photophobia and phonophobia. There were no prodromal symptoms. Neurological examination revealed no abnormalities. Because of the strict unilaterality of symptoms, an asymmetry on the EEG on the left side and the disabling symptoms, a carotid angiogram was performed in conjunction with which rCBF was measured. Both the angiogram and a computerized tomogram of the brain were normal.

The patient had been headache free until the time of the CBF measurement. After placement of the carotid catheter she developed a mild left-sided headache. After the first CBF measurement the headache rapidly grew worse, and during the second CBF measurement the headache became severe. There was, however, no significant change in the mean CBF value or the regional distribution of the cerebral blood flow (Table 1 and Fig. 3).

This case of common migraine demonstrates almost no change in CBF during the development of an attack of headache.

DISCUSSION

The data presented here correspond with previous clinical, angiographic and cerebral blood flow evidence of a decreased cerebral blood flow in the aura phase of classical migraine (Skinhøj and Paulson, 1969; O'Brien, 1971; Skinhøj, 1973; Norris et al., 1975; Mathew et al., 1976). The decrease may be severe and sometimes reach values low enough to be critical for brain tissue oxygenation (Trojaborg and Boysen, 1973; Sharbrough et al., 1973; Branstetter et al., 1975; Heiss et al., 1975). Lactacidosis noted in the CSF dur-

ing attacks of classic migraine give further support to this idea (Skinhøj, 1973).

One may only speculate as to the cause of this ischemia. Is it vasospasm caused by circulating vasoactive substances or does it represent the effect of products liberated from brain tissue? The angiographic evidence is scarce, but the few publications describing angiographic appearances during migraine attacks, with the exception of Dukes and Veith (1964), demonstrate a normal caliber of larger cerebral arteries. This suggests increased cerebrovascular resistance at the arteriolar level. Cerebral blood flow regulation in this phase may be abnormal. Simard and Paulson (1973) found that the normal increase in CBF occurring during inhalation of CO₂ was completely abolished, and similar though less striking findings were noted by Hachinski et al. (1977). Cerebral blood flow at different blood pressure levels has not been studied during a migraine aura. It is therefore not known whether the regulation of cerebrovascular resistance (autoregulation) is impaired in this situation.

In some cases the decrease in cerebral blood flow noted during the migraine aura may continue into the headache phase (Skinhøj, 1973). We present in this communication a case with no definite aura, but where the associated symptoms (mainly a depressed level of consciousness occurring simultaneously with the headache) were associated with a distinctly decreased brain perfusion.

During the headache phase of classic migraine normal or increased cerebral blood flow has been reported (Skinhøj and Paulson, 1969; O'Brien, 1971; Skinhøj, 1973; Norris et al., 1975; Mathew et al., 1976). Where marked cerebral ischemia occurs during the prodromal phase, the flow increase is most likely due to reactive hyperemia. On the other hand, pain of any sort is known to activate brain function and increase cerebral blood flow (Ingvar et al., 1975). The observed hyperemia could be simply secondary to pain. This mechanism was suggested to explain the increased CBF noted in a

case of cluster headache (Norris et al., 1976).

Common migraine occurs much more frequently than classical migraine. In this disorder prodromal symptoms are lacking, and during the attack no symptoms indicate cerebral dysfunction. Several CBF studies have demonstrated normal or moderately increased values during an attack of common migraine (Skinhøj, 1973; Mathew et al., 1976). We present here another case where no change in CBF occurred before or during a spontaneous attack of headache.

Skinhøj (1973) found CSF lactacidosis during migraine attacks in classic and common migraine. The increased CSF levels of lactic acid in the patients with common migraine alone was not statistically significant. Even if it is substantiated in a larger series that lactacidosis occurs in common migraine, it may be secondary to hyperventilation and respiratory alkalosis, which may accompany attacks of common migraine.

Case 3 of this series was studied at the moment a slight headache appeared and a normal CBF was found. During the next CBF evaluation the headache was severe and the CBF did not change significantly. This case therefore does not confirm the hypothesis that common migraine is caused by an asymptomatic CBF reduction. The CBF increases that can occur during common migraine are probably secondary to pain arousal.

Dr. Hachinski is a Senior Research Fellow of the Ontario Heart Foundation.

REFERENCES

BRANSTON, N. M., SYMON, L., CROCKARD, H. A. and JUHASZ, J. (1975). Dependence of the cortical evoked response of the local tissue blood flow in baboons and its sensitivity to arterial pO₂. In: *Blood Flow and Metabolism in the*

- Brain (Harper, A. M., Jennett, W. B., Miller, J. D. and Rowan, J. O. (Eds.). Churchill Livingstone, Edinburgh, pp. 14.22-14.26.
- CALA, L. A. and MASTAGLIA, F. L. (1976). Computerized axial tomography findings in patients with migrainous headaches. *Bri. Med. J.* 2, 149-150.
- DUKES, H. T. and VIETH, R. G. (1964). Cerebral arteriography during migraine prodrome and headache. *Neurology*, 14, 636-639.
- GUEST, I. A. and WOLFF, A. L. (1964). Focal infarction of brain in migraine. *Brit. Med. J.* 1, 225-226.
- HACHINSKI, V. C., PORCHAWKA, J. and STEELE, J. C. (1973). Visual symptoms in the migraine syndrome. *Neurology*, 23, 570-579.
- HACHINSKI, V. C., NORRIS, J. W., COOPER, P. W. and EDMEADS, J. G. (1977). Cerebral circulatory disturbances in classic and complicated migraine. (Unpublished.)
- HANSEN, A. P. and LUNDBAEK, K. (1977). Personal communication.
- HEISS, W. D., WALTZ, A. G. and HAYAKAWA, T. (1975). Neuronal function and local blood flow during experimental cerebral ischemia. In: *Blood Flow and Metabolism in the Brain*. (Harper, A. M., Jennett, W. B., Miller, J. D. and Rowan, J. O. (Eds.). Churchill Livingstone, Edinburgh, pp. 14.27-14.28.
- HOUGAARD, K., OIKAWA, T., SVEINSDOTTIR, E., SKINHØJ, E., INGVAR, D. H. and LASSEN, N. A. (1976). Regional cerebral blood flow in focal cortical epilepsy. *Arch. Neurol.* 33, 527-535.
- HUNGERFORD, G. D., du BOULAY, G. H. and ZILKHA, K. J. (1976). Computerized axial tomography in patients with migraine: a preliminary report. *J. Neurol. Neurosurg. Psychiat.* 39, 990-994.
- INGVAR, D. H., ROSEN, I. and ELMQVIST, D. (1975). Effects of somatosensory stimulation upon rCBF. In: *Blood Flow and Metabolism in the Brain*. (Harper, A. M., Jennett, W. B., Miller, J. D. and Rowan, J. O. (Eds.). Churchill Livingstone, Edinburgh, pp. 14.29-14.32.
- LASSEN, N. A. and INGVAR, D. H. (1961). The blood flow of the cerebral cortex determined by Krypton⁸⁵. *Experientia*, 17, 42-43.
- McNAUGHTON, F. L. (1976). Thomas Willis and headache. Invited lecture to the 11th Canadian Congress of Neurological Sciences, Winnipeg, Oct. 13-16. (Unpublished.)
- MARCUSSEN, R. M. and WOLFF, H. G. (1950). Studies on headache; I Effects of carbon dioxide-oxygen mixtures given during preheadache phase of migraine attack; II Further analysis of the pain mechanism of headache. *Arch. Neurol. Psychiat.* 63, 42-51.
- MATHEW, N. T., MEYER, J. S., WELCH, K. M. A. and NEBLETT, C. R. (1976). Abnormal CT scans in migraine. *Neurology*, 26, 380.
- MATHEW, N. T., HRASTNIK, F. and MEYER, J. S. (1976). Regional cerebral blood flow in the diagnosis of vascular headache. *Headache*, 15, 252-260.
- NORRIS, J. S., HACHINSKI, V. C. and COOPER, P. W. (1975). Changes in cerebral blood flow during a migraine attack. *Brit. Med. J.* 3, 676-677.
- NORRIS, J. W., HACHINSKI, V. C. and COOPER, P. W. (1976). Cerebral blood flow changes in cluster headache. *Acta neurol. Scand.* 54, 371-374.
- O'BRIEN, M. D. (1971). Cerebral blood changes in migraine. *Headache*, 10, 139-143.
- OLESEN, J., PAULSON, O. B. and LASSEN, N. A. (1971). Regional cerebral blood flow in man determined by the initial slope of the intra-arterially injected 133 Xe. *Stroke*, 2, 519-540.
- SHARBROUGH, F. W., MESSICK, J. M. and SUNDT, T. J. Jr. (1973). Correlation of continuous electroencephalograms with cerebral blood flow measurements during carotid enarterectomy. *Stroke*, 4, 674-683.
- SIMARD, D. and PAULSON, O. B. (1973). Cerebral vasomotor paralysis during migraine attack. *Arch. Neurol.* 29, 207-209.
- SKINHØJ, E. (1973). Hemodynamic studies within the brain during migraine. *Arch. Neurol.* 29, 95-98.
- SKINHØJ, E. and PAULSON, O. B. (1969). Regional blood flow in internal carotid distribution during migraine attack. *Bri. Med. J.* 3, 569-570.
- SVEINSDOTTIR, E., LARSEN, B., ROMMER, P. and LASSEN, N. A. (1977). A multidetector scintillation camera with 254 channels. *J. Nucl. Med.* 18, 168-174.
- TROJABORG, W. and BOYSEN, G. (1973). Relation between EEG, regional cerebral blood flow and internal carotid artery pressure during carotid enarterectomy. *Electroenceph. Clin. Neurophysiol.* 34, 61-69.
- WOLFF, H. G. (1972). *Headache and Other Head Pain*. Third Edition (Revised by Dalessio, D. J.). Oxford University Press, New York, pp. 231-234.