

## Co-existence of cerebral cysticercosis with Japanese encephalitis: a prognostic modulator

A. DESAI<sup>1</sup>, S. K. SHANKAR<sup>2</sup>, P. N. JAYAKUMAR<sup>3</sup>, A. CHANDRAMUKI<sup>1</sup>,  
M. GOURIE-DEVI<sup>4</sup>, B. V. RAVIKUMAR<sup>5†</sup> AND V. RAVI<sup>1\*</sup>

Departments of Neurovirology<sup>1</sup>, Neuropathology<sup>2</sup>, Neuroradiology<sup>3</sup> and Neurology<sup>4</sup>, National Institute of Mental Health & Neuro Sciences, Bangalore 560029

<sup>5</sup> Astra Research Centre India, Bangalore 560003

(Accepted 12 October 1996)

### SUMMARY

In this study, we investigated the frequency of co-existence of cerebral cysticercosis (CC) in Japanese encephalitis (JE) cases with special emphasis on its role in predicting the final clinical outcome. Amongst the 163 confirmed cases of JE, 37.42% (61/163) had co-existent CC. This was confirmed by antibody detection in the CSF of 45 cases, CT scan of the brain in 6 cases and at autopsy in 3 cases. In 2 cases confirmation was possible by CT scan as well as at autopsy, in 4, CSF antibody levels and CT scan were suggestive of CC while in 1, CSF antibodies and autopsy were suggestive of CC. The co-occurrence of *Cysticercus cellulosae* in the brain emerged as a prognosticator of poor outcome in JE cases ( $P < 0.03$ ).

### INTRODUCTION

The southern districts of Karnataka State, South India, have been experiencing periodic outbreaks of JE since 1979 and the population at risk in these areas is children under the age of 15 years, especially those belonging to the lower socio-economic group [1]. Pigs act as efficient amplifiers of JEV in the natural cycle of the virus and pig-rearing is a common occupation in these endemic areas [2]. Pigs also act as intermediate hosts in the life-cycle of the tape worm *Taenia solium* as they harbour the larval forms, namely *Cysticercus cellulosae*. The involvement of pigs in the natural cycle of these two organisms increases the chances of their co-existence in man. In fact, a high prevalence of intestinal parasitic infections has been recorded in areas endemic for viral encephalitis [3–5]. Further, malnutrition and inadequate living conditions are

known to lower the immune status which in turn may contribute to infection by the neurotropic viruses [6]. These observations seem to suggest that parasitic infestations enhance the probability of viral invasion through modulation of the host defence mechanisms.

The objective of this study was to determine the probable frequency of cerebral cysticercosis in patients with JE, especially those who survive, as well as determine its role in influencing the clinical outcome.

### MATERIALS AND METHODS

#### Patients

The study was carried out between October and December of two consecutive years, 1990 and 1991, at the National Institute of Mental Health and Neuro Sciences Hospital, Bangalore, South India. One hundred and sixty-three patients with a clinical diagnosis of acute viral encephalitis formed the study group. The majority of the patients presented with

\* Correspondence and reprint requests: Dr V. Ravi, Associate Professor, Department of Neurovirology, NIMHANS, Bangalore 560029, India.

† Present address: X-Cyton Diagnostics Pvt Ltd, Bangalore 560094.

Table 1. Evidence of co-existent neurocysticercosis in confirmed cases of Japanese encephalitis

Parameter used	No. positive/ no. tested	Percentage
Anticysticercal anti-bodies in the CSF	50*/161	31.05
CT findings	12/31	38.70
Autopsy findings	6†/13	46.15

\* In four of these patients CT scan evidence was also available.

† In two of these patients CT evidence was available while in one patient anti-cysticercal antibodies were detected in the CSF.

fever, headache, vomiting, altered sensorium and convulsions. Both CSF and serum samples were collected from all these patients immediately upon admission into the hospital. A definitive diagnosis of JE was established in all these patients using one or more of the following laboratory criteria: presence of JEV specific IgM/neutralizing antibodies in the CSF and/or JEV antigen in the CSF.

#### Computerized Axial Tomogram (CT scan) examination

Base line and enhanced CT scans were done in a standard protocol. Axial contiguous 10 mm slices were taken from the OM line to the vertex. The slices were imaged on a polyester-based film. All the sections of a patient were viewed together for evidence of focal cystic lesions, calcifications and diffuse cerebral oedema in the form of decreased attenuation of the brain parenchyma and compressed ventricles and cisterns.

#### JEV specific IgM antibody detection

An IgM capture ELISA as described by Burke and colleagues [7] with minor modifications [8] was used for this purpose. The results were expressed in ELISA units and patients with > 100 units in the CSF were considered positive by this test [7].

#### JEV neutralizing antibodies

These antibodies were estimated by a micro-neutralization test described earlier and a titre of > 5 in the CSF was considered diagnostic of JE [9].

#### JEV antigen detection

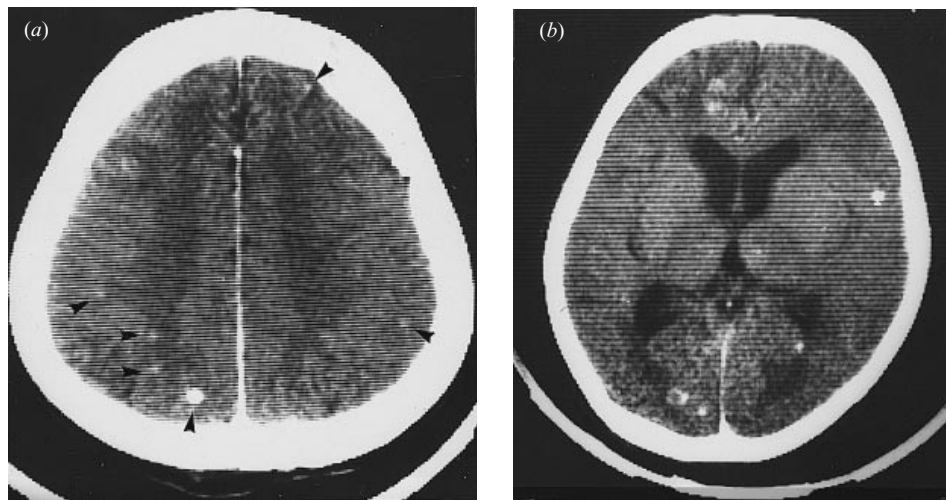
Two different procedures were used for this purpose – (i) a reverse passive haemagglutination test (RPHA) described by Ravi and colleagues [8] was used to detect soluble JEV antigen in the CSF; and (ii) an immunofluorescent assay (IFA) was used to detect the cell-associated antigen in the cytospin smears of the CSF [10]. Both these assays use monoclonal antibodies to detect viral antigen.

#### Detection of antibodies to *Cysticercus cellulosae*

An indirect ELISA was used to detect the presence of anticysticercal antibodies in the CSF. The procedure adopted was essentially that described earlier [11]. Briefly, purified excretory/secretory antigens of *Cysticercus cellulosae* obtained from *in vitro* maintained cysts were immobilized on ELISA plates and reacted with 100  $\mu$ l of CSF (1:25 dilution). The bound antibody was detected using anti-human IgG peroxidase as the tracer. After washing the plates thrice with PBS, 100  $\mu$ l of the substrate solution ( $H_2O_2$  and tetramethylbenzidine) was added and the colour reaction was developed for 20 min at room temperature. Sulphuric acid (1 N, 100  $\mu$ l/well) was added to the wells to stop the reaction and the plates were then read in a Dynatech ELISA reader at 450 nm. A sample with an optical density (OD) value of > 0.2 absorbance units over the mean OD value of triplicate negative control wells was considered positive for cysticercus antibody. This test is not recommended for testing anti-cysticercal antibodies in the serum samples. The details pertaining to sensitivity and specificity of this test have been published elsewhere [11].

#### Autopsy studies

In 13 out of 39 fatal cases of JE a partial autopsy could be done. The brain was collected and fixed in formalin. After fixation, approximately 5 mm coronal slices of the brain were cut and examined for the presence of cysts. Paraffin embedded brain tissue sections from hippocampus, temporal cortex, thalamus, midbrain, medulla oblongata and cerebellum were stained with haematoxylin and eosin and examined for the distribution and density of the pathological lesions. The sections were examined under 10  $\times$  magnification and the density of microglial



**Fig. 1.** CT scan of the brain in Japanese encephalitis and cerebral cysticercosis. Note multiple cysts (arrow) in both the hemispheres and diffuse cerebral oedema (*a*). Axial slice showing focal areas of hypoattenuation in the left frontal, left temporal and both occipital regions. Multiple cysts are seen in both the hemispheres (*b*).

nodules and pale, circumscribed necrolytic lesions were assessed in various areas semiquantitatively; + = sparse (one microglial nodule or necrolytic lesion in 3–4 microscopic fields); ++ = mild (one microglial nodule and/or necrolytic lesion in one microscopic field); +++ = moderate (2–4 microglial nodules and/or necrolytic lesions in one microscopic field); ++++ = severe (more than four microglial nodules and/or necrolytic lesions in one microscopic field). The distribution of these lesions in relation to the proximity and side of the brain having the cysticercal cysts were also noted.

#### Statistical analysis

A chi-squared test was used to ascertain the differences in the clinical and immunological parameters of two groups of JE patients, i.e. those with and those without co-existent cerebral cysticercosis.

#### RESULTS

Amongst the 163 confirmed cases of JE, 102 were males and 61 were females. The age of these patients ranged from 5 months to 57 years (mean = 8.9 years) and 79.75% (130/163) were children below the age of 15 years. All these patients were from JEV endemic areas. Antibodies to JEV were detected in the CSF of 78 (47.85%) while JEV antigen could be detected in the CSF of 24 (14.72%) cases. In the remaining 61 (37.42%) patients, both anti-JEV antibody and antigen were detected.

The co-existence of cerebral cysticercosis (CC) was

assessed in 163 patients using one or more of the three modes of investigation; anti-cysticercal antibodies could be tested in the CSF of 161 patients, CT scan of the brain in 31 patients and autopsy was possible in 13 patients. Amongst them, 61 patients (37.42%) had evidence of co-existent CC by one or more investigations (Table 1); anti-cysticercal antibodies were detected in the CSF of 45, CT scan findings highly suggestive of CC could be noted in 6 patients, while in 3 patients cysts were detected at autopsy. In 4 patients anti-cysticercal antibodies in the CSF as well as CT evidence could be obtained, in 2 other patients CT and autopsy findings confirmed the presence of CC while in 1 patient antibodies in CSF and autopsy studies confirmed the presence of CC. Amongst the 12 patients who had CT evidence of CC, single cysts were seen in 8 and multiple in 4. Frontal and parietal lobes showed diffuse cerebral oedema (Fig. 1). Although anti-cysticercal antibodies were present in the CSF of two patients (Sl. Nos. 2 and 5, Table 2), at autopsy cysticercal cysts were missed probably because we could not examine thinner slices of the brain. In the brain JE related pathological changes were frequent in the thalamus, in the absence of cysticercal cyst. With the co-existence of CC the numerical density and the topographic distribution of the pathological lesions increased (Table 2). Interestingly, the necrolytic lesions were found to be more and florid on the ipsilateral side bearing the parasitic cyst (Fig. 2).

Amongst the 163 confirmed cases of JE, the final clinical outcome was available in 118 cases. Of these, 41 recovered, 38 had residual neurological deficits at

Table 2. Distribution of JEV induced pathological lesions in the brain in relation to co-existent cerebral cysticercosis

Case*	Age and sex	Duration of illness (days)	Antibodies		Histopathology findings in brain†					
			JEV	NCC	H	TC	TH	MB	MED	CRBL
1.	12, M	8	+	–	–	–	++	+	–	–
2.	29, M	NK	–	+	–	–	–	–	–	–
3.	5, M	8	+	–	+	–	++	++	–	+
4.	6, M	4	+	–	–	–	+	–	–	–
5.	57, M	6	+	+	–	–	–	–	–	–
6.	35, M	11	–	–	–	–	–	–	–	–
7.	6, M	6	+	–	–	+++	++	–	–	–
8.	4, F	6	–	ND	–	–	++	–	–	–
9.	10, M	6	+	–	–	–	++	ND	ND	ND
10.	14, M	60	+	+	–	–	+	ND	–	–
11.	7, F	5	+	–	+	+	+++	++	–	–
12.	8, M	19	+	–	–	+++	++	–	–	+
13.	26, M	12	+	ND	+	+++	++++	++	–	–

\* Case Nos. 1–7 did not have evidence of cysticercal cysts in the brain, while Case Nos. 8–13 had cysts grossly evident at autopsy.

† H, hippocampus; TC, temporal cortex; TH, thalamus; MB, mid brain; MED, medulla oblongata; CRBL, cerebellum; NK, not known; ND, not done.

+, one microglial nodule and/or necrolytic lesions in 3–4 fields; ++, one microglial nodule and/or necrolytic lesions in one field; +++, 2–4 microglial nodules and/or necrolytic lesions in one field; +++, > 4 microglial nodules and/or necrolytic lesions in one field.

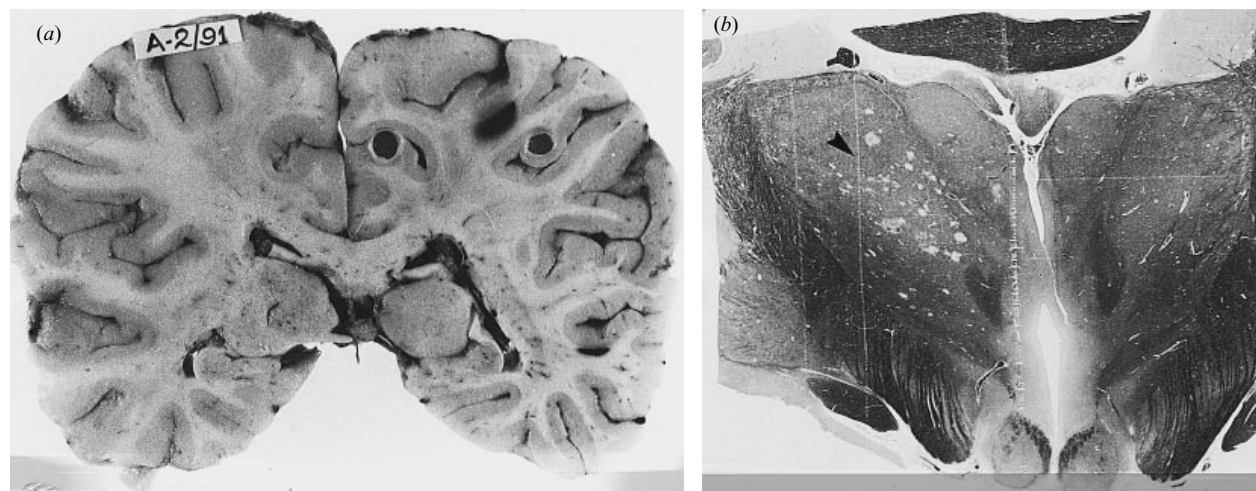


Fig. 2. Coronal slice of the brain in a case of JE showing two cysticercal cysts with host reaction and white matter congestion (a). The whole mount preparation of a section from the same case at the level of mamillary bodies showing necrolytic lesions in thalamic nuclei on the side which had cysticercal cysts in diencephalon anteriorly (b).

the time of discharge while 39 succumbed to the infection. The presence of co-existent CC was noted in 24.39% (10/41) of the cases that recovered, 39.47% (15/38) of the cases that recovered but had neurological deficits and 53.84% (21/39) amongst those who succumbed to the infection. To ascertain the modulating role of the parasite in relation to clinical course, progression and outcome of the viral en-

cephalitic process an analysis of the various clinical and immunological parameters was carried out in JE patients with and without cerebral cysticercosis. The results presented in Table 3 revealed that co-existent CC emerged as a poor prognosticator and significantly correlated to mortality as well as morbidity. None of the other parameters evaluated was significantly different between the two groups.



Table 3. Correlation of clinical and immunological parameters with co-existent cerebral cysticercosis in JE cases

Parameters evaluated	No. of patients		P value
	With CC	Without CC	
Age ( <i>n</i> = 116)			
< 15 Years	35	62	0.128
> 15 Years	11	8	
Sex ( <i>n</i> = 118)			
Male	35	47	0.298
Female	11	25	
CSF cells ( <i>n</i> = 100)			
< 10	10	21	0.401
> 11	30	39	
Fever ( <i>n</i> = 118)			
Present	46	69	0.421
Absent	0	3	
Convulsions ( <i>n</i> = 118)			
Present	37	47	0.117
Absent	9	25	
Altered sensorium ( <i>n</i> = 118)			
Present	36	54	0.853
Absent	0	3	
CSF-JEV IgM ( <i>n</i> = 118)			
> 500 Units	24	28	0.219
< 500 Units	22	44	
CSF-Nt Ab ( <i>n</i> = 118)			
> 80	24	24	0.065
< 80	22	48	
CSF-JEV Ag ( <i>n</i> = 118)			
Present	22	39	0.855
Absent	24	33	
Outcome ( <i>n</i> = 118)			
Expired	21	18	0.033 (SIG)
Survived	25	54	

CC, cerebral cysticercosis; CSF-JEV IgM, IgM antibodies to JEV in the CSF; CSF-JEV Nt Ab, titres of neutralizing antibodies to JEV in the CSF; CSF-JEV Ag, JEV antigen in the CSF; SIG, significant.

Figures in parentheses indicate the number of patients evaluated for each parameter tested.

\* A chi-squared test was used for determining the statistical significance for all the parameters except Fever for which the Fischer's exact probability test was used.

## DISCUSSION

Hsu (1940) was the first to report a case of cerebral cysticercosis [12] with diffuse inflammation of the central nervous system suggesting the possibility of co-occurrence of JE. Subsequently, elegant experimental models describing the synergistic role of *Toxocara canis* in the evolution of JEV infection in mouse were reported [13, 14]. Very few reports are available describing the co-existence of cerebral

cysticercosis in human JE cases. Liu and colleagues [3] were the first to describe a significant association of intestinal helminthic infections with JE in humans. Shankar and colleagues [15] at our centre observed that nearly one third of the brains of JE cases (11/34) examined at autopsy showed evidence of cerebral cysticercosis during an epidemic in 1979 in Karnataka state, South India. Although these two post-mortem studies provided valuable information on the phenomenon of co-existence, the frequency with which cerebral cysticercosis is associated with JE patients who survive is not known. Moreover, they were not designed to investigate the modulating role of the parasite on the progression, course and outcome of the viral encephalitic process. To the best of our knowledge this is the first prospective study to ascertain the frequency of co-existent CC in JE patients who survived the infection.

From post-mortem studies carried out on patients who died of neuropsychiatric ailments at our centre the overall prevalence of CC has been estimated to be 4% (unpublished observations). This is similar to the prevalence rates observed in general populations living in endemic areas of other parts of the world such as Mexico. In contrast, the prevalence of CC amongst JE patients in this study is significantly higher, 37.42% (61/163). It is tempting to postulate that this high prevalence observed is due to false positive reactions obtained with the ELISA used in this study. However, it must be emphasized that the ELISA test described here has been evaluated earlier and found to be specific and sensitive for the diagnosis of CC provided CSF is used as the specimen [11]. Its performance with serum samples, however, was not satisfactory, probably due to the presence of cross-reacting antibodies to other intestinal helminths. On the other hand, the frequency of co-occurrence of CC amongst the JE patients who were autopsied in this study (5/13; 38.4%) as well as from an earlier study (32.4%) at our centre [15], suggests that the prevalence is indeed higher in JE patients. Moreover, we have not observed such a high prevalence of CC at autopsy in other commonly encountered CNS infections at our centre such as tuberculous, pyogenic or fungal meningitis. The precise reasons for this relative increase of CC in JE patients is at present unclear. Pig rearing, the relatively higher incidence of intestinal parasitic infestation, poor socio-economic and hygienic conditions as well as malnutrition are some of the complex sociodemographic and ecological factors common to these two diseases. It is in this context that

experimental studies are relevant to dual infections in humans. It is evident from experimental studies that many helminths exhibit larval migration and/or have a predilection for the nervous tissue similar to neurotropic viruses [16, 17]. Further, the deleterious effect produced by the parasite on the host immune system in dual infections has recently been found to be due to metabolic products secreted by the larvae as well as the immune response to irrelevant or non-functional host-like antigens normally present on the surface of the larvae [16, 18]. Lastly, parasitic infections are known to induce generalized immunosuppressions, particularly cell-mediated immunosuppression, which in turn may predispose the host to a fulminant JEV infection [17].

The co-existence of CC emerged as a significant factor contributing to the fatal outcome of JE cases ( $P = 0.03$ ) in the present study. Experimental studies conducted in mice on dual infections with JEV and *Toxocara canis* have indicated that viral encephalitis might have been caused by the larvae destroying the blood-brain barrier or by creating malacic forms [14]. This probably facilitates the entry of the virus or its localization and replication in the brain, leading to a fulminant infection [14]. Indeed, some of the histopathological findings of this study seem to support such a 'hypothesis'. For instance, the distribution of necrolytic lesions was not only greater in number, but they were more widespread and pronounced in the brains of JE patients with co-existent CC as compared to those without (Table 2). Yet another feature noted was the direct relationship between the presence of a well-preserved cysticercal cyst and the marked degree of pathological lesions (Fig. 2), suggesting a modulating role of the cyst facilitating viral invasion. It is, therefore, possible that cerebral cysticercosis enhances JEV infection of the brain by breaching the blood-brain barrier as suggested earlier by others [13, 14, 18]. Irrespective of the mechanism, it appears that the association of cerebral cysticercosis in JE patients is more than a chance coincidence.

#### ACKNOWLEDGEMENTS

The authors wish to thank Dr Kimura-Kuroda, Tokyo Metropolitan Institute of Neurosciences, Japan, and the Director, National Institute of Virology, Pune, India for the monoclonal antibodies used in this study. The authors also wish to thank Ms Mary Kasi and Mr Ramkumar for their technical

assistance. The excellent support received from the directors of NIMHANS and Astra Research Centre India is also gratefully acknowledged.

#### REFERENCES

- Gourie-Devi M. Clinical aspects and experience in the management of Japanese encephalitis patients. In: Proceedings of the National Conference on Japanese encephalitis. Indian Council of Medical Research. New Delhi, 1984: 25–9.
- Rodrigues FM. Epidemiology of Japanese encephalitis in India: a brief overview. In: Proceedings of the National Conference on Japanese encephalitis. Indian Council of Medical Research. New Delhi, 1984: 1–9.
- Liu YF, Teng CI, Liu K. Cerebral cysticercosis as a factor aggravating Japanese B encephalitis. *Chinese Med J* 1957; **75**: 101–7.
- Sen Gupta J, Bhattacharya K. Distribution of parasitic infestation among hospital patients in Bankura, 1962–1969. *Ind J Publ Hlth* 1975; **19**: 69–72.
- Omer AHS, McLaren ML, Johnson BK, *et al.* Sero-epidemiology survey in the Gezera, Sudan with special reference to Arboviruses. *J Trop Med Hyg* 1981; **84**: 63–7.
- Grasenkov NI. Japanese encephalitis in the USSR. *Bull WHO* 1963; **30**: 161–72.
- Burke DS, Nisalak A, Ussery MA, Laorakpongse T, Chantavibul S. Kinetics of IgM and IgG response to Japanese encephalitis virus in human serum and cerebrospinal fluid. *J Infect Dis* 1985; **151**: 1093–9.
- Ravi V, Premkumar S, Chandramuki A, Kimura-Kuroda J. A reverse passive haemagglutination test for the detection of Japanese encephalitis virus antigens in the cerebrospinal fluid. *J Virol Methods* 1989; **23**: 291–8.
- Desai A, Ravi V, Chandramuki A, Gourie-Devi M. Detection of neutralizing antibodies to Japanese encephalitis virus in the cerebrospinal fluid using a rapid microneutralization test. *Serodiagn Immunother Infect Dis* 1994; **6**: 130–4.
- Desai A, Chandramuki M, Gourie-Devi M, Ravi V. Detection of Japanese encephalitis virus antigens in the CSF using monoclonal antibodies. *Clin Diag Virol* 1994; **2**: 191–9.
- Ravikumar BV, Suryanarayana V, Ravi V, Chandramuki A. Excretory/secretory antigens of tapeworm (*Cysticercus cellulosae*) for use in immunodiagnosis and vaccine preparation. Patient Corporation Treaty. World Intellectual Property Organisation, Geneva, 1990; Publication 90/08958.
- Hsu YK. Cerebral cysticercosis and acute poliomyeloencephalitis. *Chinese Med J* 1940; **57**: 318–9.
- Mochizuki H, Tomimura T, Oka T. Cerebrospinal nematodiasis as a provoking factor in Japanese encephalitis – an experimental approach. *J Infect Dis* 1954; **95**: 260–6.
- Pavri KM, Ghalsasi GR, Dastur DK, Goverdhan MK,

- Lalitha VS. Dual infections in mice: visceral larva migrans and sublethal infection with Japanese encephalitis. *Trans R Soc Trop med Hyg* 1975; **69**: 99–110.
15. Shankar SK, Vasudev Rao T, Mruthyunjayanna BP, Gourie-Devi M, Deshpande DS. Autopsy study of brains during an epidemic of Japanese encephalitis in Karnataka. *Indian J Med Res* 1983; **78**: 431–40.
  16. Gupta AK, Ayachit VL, Lad VJ, Rodrigues JJ. Isohaemagglutinins to human blood group A cells in mice with experimental canine toxocariasis. *Indian J Parasitol* 1989; **13**: 359–62.
  17. Gupta AK, Pavri KM. Alteration in the immune response of mice with dual infection of *Toxocara canis* and Japanese encephalitis virus. *Trans R Soc Trop Med Hyg* 1987; **81**: 835–40.
  18. Shankar SK, Suryanarayana V, Vasantha S, Ravi V, Ravikumar BV. Biology of neurocysticercosis – parasite related factors modulating host response. *Med J Armed Forces of India* 1994; **50**: 79–88.