

Quebec Cooperative Study
of Friedrich's Ataxia

Study of a Family with Progressive Ataxia, Tremor and Severe Distal Amyotrophy

J. BOUCHARD, P. BEDARD and R. BOUCHARD

SUMMARY: *We have studied a large family of which seven members suffer from a progressive disease with onset in the first decade. The first symptoms were gait ataxia and clumsiness in all cases, followed by progressive development of severe distal amyotrophy reminiscent of Charcot-Marie-Tooth disease. In four patients a postural tremor which was relieved by pharmacological agents was also evident in the limbs or head.*

Cerebellar atrophy was confirmed on CT scan. Motor nerve conduction velocities

were in the low normal range, while sensory nerve conduction was markedly decreased. All patients had impaired proprioception and vibration sense. The laboratory investigation revealed a normal CSF protein level and elevated serum bilirubin.

The patients reported in this study apparently suffer from an original recessive form of spinal and olivocerebellar degeneration associated with a neuronal form of Charcot-Marie-Tooth disease.

RÉSUMÉ: *Nous avons étudié une famille comprenant sept membres atteints d'une maladie progressive ayant débuté par une ataxie à la marche dans l'enfance. Plus tard s'installe une amyotrophie distale de plus en plus sévère, ressemblant en tout point chez les patients plus âgés à une maladie de Charcot-Marie-Tooth. Enfin, quatre patients présentent un tremblement dont nous décrivons les caractéristiques et le traitement.*

L'investigation a montré une atrophie cérébelleuse des plus marquées. Les vitesses de conduction motrice se chiffrent

aux limites inférieures de la normale alors que la conduction sensitive est très anormale. D'ailleurs tous les patients présentent des troubles des sensibilités profondes. On note aussi une hyperbilirubinémie et un taux normal de protéines dans le liquide céphalorachidien.

Nous croyons qu'il s'agit là d'une forme originale de dégénérescence spinale et olivocérébelleuse associée à une forme neuronale de la maladie de Charcot-Marie-Tooth, le tout transmis de façon autosomale récessive.

INTRODUCTION

In the course of the Québec cooperative study on Friedrich's ataxia we attempted to distinguish "classical" and "atypical" forms of spinocerebellar degeneration (SCD) to better understand the pathophysiological mechanisms underlying their common or diverging clinical manifestations.

In addition to classical and well characterized forms of spinocerebellar degeneration, several families presenting strong intrafamilial similarities have been encountered in clinical practice or described in the literature.

At present, there is no treatment to arrest the abiotrophic process, however some of the associated symptoms and signs can be relieved to allow a better functional prognosis. The purpose of this paper is to report a remarkably large family with a number of cases of progressive ataxia, and features such as severe distal amyotrophy similar to Charcot-Marie-Tooth disease (CMTD), and dentatorubral tremor. We will also report the results of pharmacological therapy on the tremor in these patients.

THE FAMILY

Both parents are alive and well. Born in the province of New Brunswick, Canada, they were married in 1928 and have always lived in the same village. They are not related and are unaware of any consanguinous marriage in their ancestors. The lineage came from acadian Port Royal on the father's side, and from the Québec City area, on the mother's side. Both lineages originated from France in the XVIIth Century. Several of the father's cousins are said to be ataxic.

The mother has had twenty seven pregnancies. Twenty children, ten males and ten females survived and are

From the Département des sciences neurologiques, et Centre de Recherche en neurobiologie, Hôpital de l'Enfant-Jésus, 1401, 18 ième Rue, Québec G1J 1Z4.

Reprint requests for the complete supplement on Friedrich's Ataxia (Phase Three) to: Dr. André Barbeau, Clinical Research Institute of Montreal, 110 Pine Ave. West, Montreal, Quebec, Canada H2W 1R7.

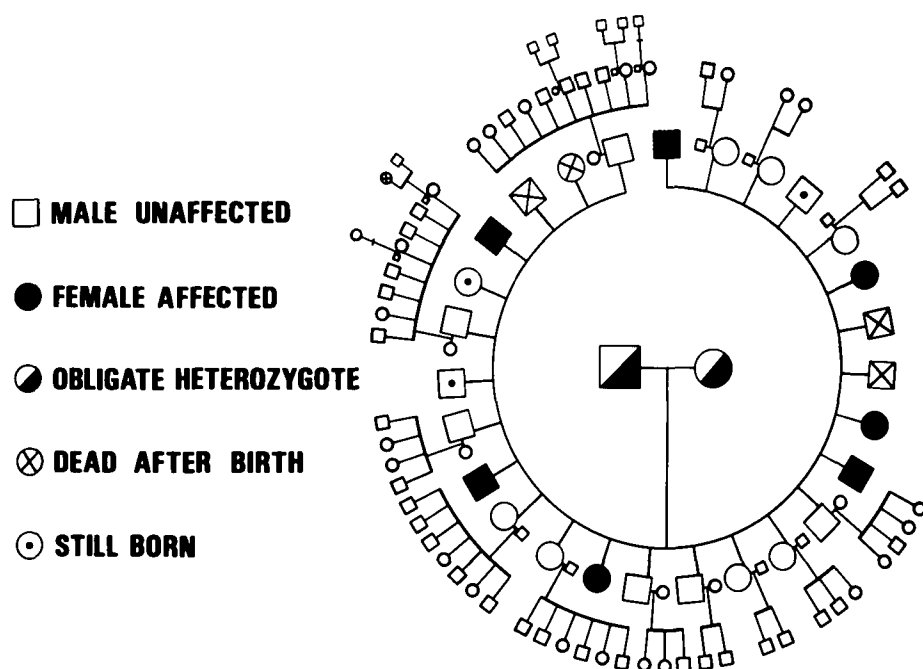


Figure 1 — Diagram giving the distribution of the seven ataxic patients in the reported family. Offspring of unaffected family members are said to be normal.

now adults. Seven are ataxic, with ages ranging from 48 to 21 years. The evolution of the disease was remarkably similar in all affected members. There is no other disease in the family and the thirteen normal children are married and their offspring are unaffected. Many of the descendants are living in the northeastern United States. The distribution of ataxic patients in the family is shown in Figure 1.

THE DISEASE

In this family the disease was transmitted as an autosomal recessive disorder to five males and two females. The onset of some clumsiness in walking and performing fine tasks with the hands was noted by the parents or the school teachers between 8 and 12 years of age. The first signs were so insidious and subtle that none of the patients noticed them personally. The male patients are now 48, 43, 40, 33 and 21 and the females 32 and 29 years old. They are referred to in the text by their first initial, followed by their sex and age. Only one patient, Rm 43, was admitted to hospital for investigation.

The first four boys worked on the family farm until the age of 25 and were confined to wheelchairs at about 30 except in one case where there was a five year postponement of this milestone. The girls found it convenient to

use the wheelchair in their early twenties but were still able to walk without assistance. The youngest patient walks with a staggering gait, but rarely falls. All are fully independent for their daily activities and appear mentally normal.

Cerebellar dysfunction were exemplified by:

- saccadic horizontal pursuit of the eyes, often with discrete end point nystagmus;

- dysarthria (slurred rather than explosive speech);

- marked dysmetria in the two older patients, only minimal in the upper limbs in the others, but severe to moderate in the lower limbs in all seven patients;

- fine and coarse alternating movements only slightly to moderately slow in the hands despite the severe amyotrophy in the older patients;

- gait ataxia in the three younger patients. There was no truncal ataxia, nor scoliosis.

There was no evidence of spasticity. Plantar responses were indifferent in all, even those with remaining voluntary extension of the toes. Tendon reflexes were lost except in the youngest girl in whom they were present but depressed at the elbows and knees, and absent at the ankles.

Posterior column signs in the lower limbs were constant and progressive. Older patients had no vibration or

position sense at the ankle while the youngest had only a slightly reduced vibration sense at the toe level. Rm 43 exhibited cystometric evidence of decreased proprioceptive sensations in the bladder. There was no clinically detectable qualitative change in cutaneous sensations, however the perception of pain, touch and temperature appeared delayed in the two older patients.

The most striking feature was the severe distal muscle atrophy such as seen in Charcot-Marie-Tooth disease with thinning of the whole leg and the inferior third of the thigh, as well as of the hands and the distal half of the forearm. This amyotrophy was accompanied by corresponding weakness in the involved segments. Again, weakness and atrophy were age related. The younger girls had only moderate weakness in foot extensors and evertors and slight atrophy of their hands while the youngest boy had only discrete amyotrophy of the small muscles of his hands. The older patients demonstrated flail feet and "simian" hands. There was no proximal weakness or atrophy.

One of the patients, Rm 43 had a coarse postural tremor which started in the right lower limb and progressed to the left and then the right upper limb and the head over a period of two years. This involuntary movement was ample, slow (about two to three per second), rhythmic, symmetrical in the lower limbs and exaggerated by emotion and movement. It consisted mainly of gross adduction-abduction movements of the thighs in the lower limbs. In the upper limbs there was an almost continuous flexion-extension movement of the forearm and with the arm extended, a pronation-supination movement of the wrist more evident in the right arm than the left. The tremor could be relieved sometimes by relaxing in bed but rarely disappeared except during sleep. This patient was admitted to hospital, submitted to the protocol of the Québec Cooperative Study and to drug trials aimed at the control of the tremor. The tremor of the upper limbs was almost completely suppressed by a combination of Sinemet R 250 mg, 1/2 tab. t.i.d. and Kemadrin R 5 mg, b.i.d. The lower limb tremor was greatly improved.

A sister, Lf 33, was later treated for tremor especially marked of the head and present for almost ten years, in the last year. The tremor was finer than in the previous patients, arrhythmic and sometimes appeared in brief repeated saccades of a few seconds each. It also responded well to the same combination of Sinemet and Kemadrin.

Two other patients exhibited a similar but less conspicuous tremor of the head only. The two younger males had a dystonic posture of the neck with permanent lateral flexion to the left, without pain, spasm or hypertrophy of neck muscles. This was not a compensatory deviation initiated by scoliosis. The same two patients were the only ones to present clinical reducible pes cavus.

There was no dysphagia and the lateral alternating movements of the tongue were normal in range and velocity.

A frequent complaint was occasional blurring of vision, and some of the patients wore glasses. There was no optic atrophy and complete ophthalmological examination which included color testing, was normal for one patient (Rm 43).

In short, the seven patients presented an evolving clinical cerebellar and proprioceptive deficit without signs of spasticity and the usual skeletal deformities seen in Friedreich's ataxia. In this family a progressive, time related distal muscle atrophy was seen in all affected members. Involuntary movements were also present in four. These patients did not have diabetes mellitus, cardiac problems or sphincter disturbances.

RADIOLOGICAL EVALUATION

The 43-year-old patient admitted to hospital did not show radiological evidence of scoliosis, pes cavus or enlargement of the heart, as is often seen in Friedreich's ataxia. No abnormality was seen on skull, total spine, chest, feet and upper gastro-intestinal tract.

A computerized tomography (CT) of the head in three patients demonstrated a comparable degree of severe atrophy of the cerebellum with normal cerebral hemispheres. Figure 2 gives the picture of the posterior fossa of Lf 32 (the same findings were present in

Rm 43 and Rm 21). Large superior cerebellar sulci, increased size of the vallecula, a normal cisterna magna and an enlarged fourth ventricle with no evidence of atrophy of the pons was seen. The confluence of the dorsal communicating cisterns (Galen, quadrigeminal and supra vermician cisterns) was clearly enlarged. The most striking feature was the abundance of foliae seen in the cerebellum indicating a diffuse and severe atrophy.

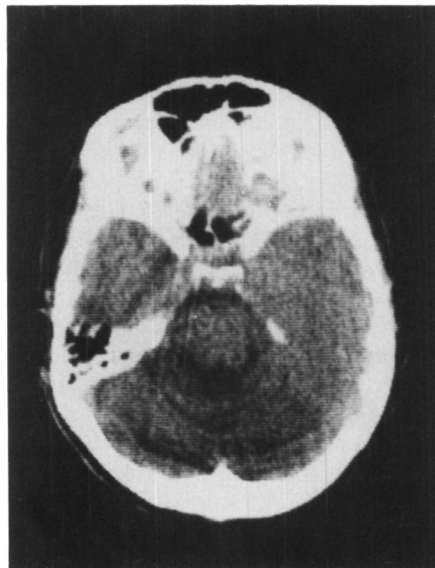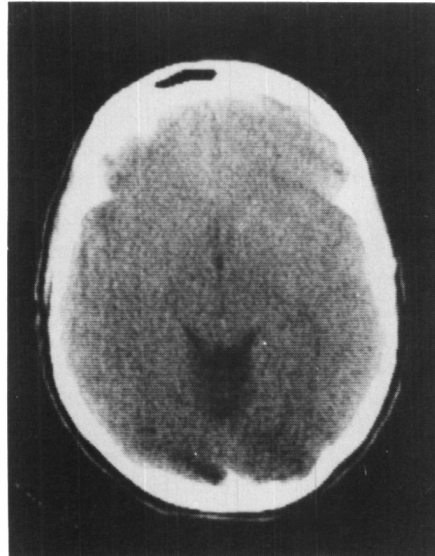


Figure 2 — CT scan demonstrating enlarged posterior communicating cisterns and superior sulci in A (upper). Increased IVth ventricle, and severe cerebellar atrophy with foliae seen in entire cerebellar field in B (lower).

The cerebellar atrophy as seen by computed tomography in the three cases is not specific. It is reminiscent of the atrophy seen in autosomal recessive spastic ataxia of Charlevoix-Saguenay (Langelier et al, 1979) although in the present family the atrophy is much more evident. However, it differs from the subtle and variable signs sometimes seen in Friedreich's ataxia.

ELECTROPHYSIOLOGICAL STUDIES

Electroencephalographic (EEG) tracings were normal in two affected males.

Electronystagmographic tracings in one patient showed bilateral horizontal gaze nystagmus, marked impairment of smooth ocular pursuit and optokinetic nystagmus, and defective fixation suppression of caloric nystagmus. These findings were similar to those described in Friedreich's ataxia (Kirkham et al, 1979) and in the Charlevoix-Saguenay syndrome (Dionne et al, 1979).

Needle electromyographic studies (EMG) were conducted in three affected patients, Rm 43, Gf 29 and Rm 21. The EMG recordings in the deltoid muscles were normal but there was little or no EMG activity on maximal voluntary contraction in distal muscles of hands, feet and legs. Only in the older patient (Rm 43) could fibrillations and positive waves be recorded distally. When present, motor unit potentials were polyphasic and of low or normal amplitude (no giant potential were observed).

Motor nerve conduction velocities (MNCV) were normal or in the lowest normal range for the younger patients in median (49.0 and 44.2 m/sec) and ulnar (46.9 and 54.4 m/sec) nerves. In RM 43, a motor response could not be elicited in the abductor pollicis brevis. With stimulation at the axilla and recording in the flexor communis, the median nerve conduction velocity was 55.0 m/sec. The amplitude of the evoked muscular responses was reduced for all the nerves, but particularly in the ulnar nerve of Rm 43 (25 μ V). In this nerve the latency was increased at the wrist (4.7 msec) and the velocity decreased to 22 m/sec. In the youngest patient, Rm 21 the MNCV was normal in the peroneal nerve (43.7 m/sec) with

a low amplitude of 1500 μ V with stimulation at the ankle and 300 μ V at the head of the fibula.

Evoked sensory nerve potentials were all abnormal. They were totally absent in median, ulnar and sural nerves in Rm 43 and Gf 29. In Rm 21, although orthodromic conduction could not be elicited from the index finger in the median nerve, antidromic stimulation produced a small (less than 1 μ V) peak after 3.8 msec ($N < 3.2$ msec). In the same patient, antidromic stimulation of the sural nerve at 11 cm from the point of recording produced a train of potentials after 4, 6, 7 and 8 msec with amplitudes of 2, 6, 10 and 6 μ V respectively. This effect was even more pronounced when stimulation was done at 21 cm, resulting in 5 peaks after 4, 4.8, 6, 7.2 and 8.4 msec and lower amplitudes of 2, 2, 3, 4, and 3 μ V respectively.

The EMG and MNCV were similar to findings previously reported in Friedreich's ataxia (Peyronnard et al, 1976; Bouchard et al, 1979). However, more signs of chronic denervation in distal muscles, without concomitant signs of active denervation or re-innervation were observed in the present study. Impairment of sensory conduction was also noted.

NERVE BIOPSY

In the nerve biopsy obtained from the sural nerve of Rm 43 an almost complete disappearance of myelinated fibers was seen, with no onion bulb formation under light microscope (cf Fig. 3). Electron microscopic examination revealed large areas of collagen alternating with other areas sparsely populated by axons. Myelin sheaths were usually absent and little evidence of active degeneration was observed in axons. Myelin debris was not observed under light or electron microscope.

CLINICAL LABORATORY FINDINGS

Although not extensive, the clinical biochemical investigation of one patient (Rm 43) produced some results of interest. Total serum bilirubin was slightly increased to 1.2 mg% on two occasions (N: 0.3 to 1.1) and 1.3 mg% after a 24 hours fast. Serum cholesterol was 176 mg% (N: 150-250) and triglycerides 63 mg% (N: 27-195).

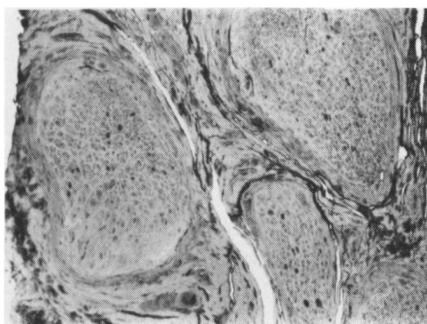


Figure 3 — Cross section of sural nerve taken from ankle in case Rm 43. Only a few shrunken small myelinated fibers are seen (paraphenylenediamine X 40).

The cerebrospinal fluid had normal protein content of 22 mg% with a relative increase in albumin.

DISCUSSION

The clinical picture reported here does not fit perfectly with any of the classical descriptions of SCD. We have a syndrome with its "lettres de créance" related to other spinocerebellar degenerations in the time of onset of the first symptoms, and the slow evolution of cerebellar and posterior column signs. It differs from Friedreich's ataxia in the absence of pyramidal tract and cardiac involvement, of skeletal deformity, and the presence of severe progressive distal amyotrophy.

Several authors have already discussed the relationship between Friedreich's ataxia and Charcot-Marie-Tooth disease, sometimes in a same kinship (Roth, 1948; Tyrer and Sutherland, 1961; De Recondo, 1975). The best attempt to classify these associations was probably the work of Greenfield (1954) where he stated that it "... is not surprising in view of the similarity in the pathology of the two diseases. The number of recorded cases however, remains quite small".

An effort has been made in the last decade (De Recondo and Godlewski, 1972; Tyrer, 1975; Geoffroy et al, 1976; Bouchard et al, 1978; Barbeau, 1978) to better delineate the main syndromes of SCD according to:

- the type of genetic transmission;
- the essential neurological signs;
- the associated defects (endocrine, cardiac, skeletal);
- the evolution;
- the electrophysiological findings.

By these criteria the patients reported here differ from the Charcot-Marie-Tooth disease, the Roussy-Levy syndrome (Roussy and Levy, 1926; Yudell, 1965), or any of the neural muscle atrophies such as classified by Dawidenkow (reported by Dyck 1975) or Dyck (1975) in his chapter on "inherited neuronal degeneration and atrophy affecting peripheral motor, sensory and autonomic neurons (HMSN)".

Muscle atrophy of some kind is not uncommon in a number of degenerative diseases, but the combination of severe localised atrophy in hands and legs is typical of the three types of Charcot-Marie-Tooth disease, hypertrophic neuropathy, neuronal or spinal type, such as outlined by Dyck and Lambert (1968). The muscle atrophy seen in F.A. is usually milder, sometimes limited either to the hands or the lower extremities, sometimes generalized, and clearly time related (Bell and Carmichael, 1939).

Silver (1966) described severe and disabling amyotrophy of the hands as the chief disability in two unrelated families presenting with spastic paraplegia. We also reported such an early severe amyotrophy of the hands in all affected members of two families with Charlevoix-Saguenay syndrome (Bouchard et al, 1978).

In the family reported in the present study, the older patients had the severe distal muscle atrophy characteristic of CMTD. However they lacked pes cavus and in addition, there was severe atrophy of the cerebellum evident on C.T. scan, and electrophysiological findings similar to those described in Friedreich's ataxia (Peyronnard et al, 1976; Bouchard et al, 1979).

The tremor present in four patients was consistent with the cerebellar degeneration and probably indicated more precisely a lesion in the rubro-olivo-dentatorubral loop. A similar tremor can be produced in monkeys by lesions at different levels of this loop. (Larochelle et al, 1971). None of the patients demonstrated palatal myoclonus which is sometimes associated with dentatorubral degeneration accompanied by hypertrophy of the inferior olivary nucleus.

This tremor although more of the rubral type than Parkinsonian,

responded to drugs used in Parkinson's disease, indicating that similar mechanisms may be implicated in part in the latter disease. Although involvement of the extrapyramidal system appeared slight, the head tilt present in two patients may indicate some degree of a lesion of this system.

Salisachs and Lapresle (1973) reported a case of "peroneal muscular atrophy due to hypertrophic neuritis associated with (familial) tremor of great amplitude causing dyskinesia". Antiparkinsonian drugs and stereotaxic surgery were not effective in relieving the tremor. Well documented cases resembling ours were studied by Delwaide and Schoenen (1976) and presented as "non hypertrophic familial neuropathy associated with intention tremor". This tremor was improved by propranolol.

In summary, if one considers the slow evolution, the abnormal movements, the marked atrophy of the cerebellum and the severe distal amyotrophy, this family present a combination of spinal and olivocerebellar degeneration with a neuronal type of autosomal recessive peroneal muscular atrophy.

ACKNOWLEDGEMENTS

This study was supported by a grant from l'Association Canadienne de l'Ataxie de Friedreich. We wish to thank Dr. C. Richards for her advice and Mrs. A. LaBrecque for typing the manuscript. Dr. F. Gagné did the neuropathological examination of the nerve biopsy.

REFERENCES

- BARBEAU, A., BRETON, G., LEMIEUX, B. and BUTTERWORTH, R.F. (1976). Bilirubin metabolism in Friedreich's ataxia. *Can. J. Neurol. Sci.*, 3: 365-372.
- BARBEAU, A. (1978). Friedreich's ataxia 1978 — an overview. *Can. J. Neurol. Sci.*, 5: 161-165.
- BELL, J.M. and CARMICHAEL, E.A. (1939). On hereditary ataxia and spastic paraplegia. In: *Treasury of Human Inheritance*. Vol. 4, Cambridge Press, London, pp 141-284.
- BOUCHARD, J.P., BARBEAU, A., BOUCHARD, R. and BOUCHARD, R.W. (1978). Autosomal recessive spastic ataxia of Charlevoix-Saguenay. *Can. J. Neurol. Sci.*, 5: 61-70.
- BOUCHARD, J.P., BARBEAU, A., BOUCHARD, R. and BOUCHARD, R.W. (1979). Electromyography and nerve conduction studies in Friedreich's ataxia and autosomal recessive spastic ataxia of Charlevoix-Saguenay (ARSACS). *Can. J. Neurol. Sci.*, 6: 185-190.
- BOUCHARD, R.W., BOUCHARD, J.P., BOUCHARD, R. and BARBEAU, A. (1979). Electroencephalographic findings in Friedreich's ataxia and autosomal recessive spastic ataxia of Charlevoix-Saguenay (ARSACS). *Can. J. Neurol. Sci.*, 6: 191-194.
- DELWAIDE, P.J. and SCHOENEN, J. (1976). Non-hypertrophic familial neuropathy associated with intention tremor. *J. Neurol. Sci.*, 27: 59-69.
- DE RECONDO, J. Hereditary neurogenic muscular atrophies (1975). In: *Handbook of clinical neurology*, P.J. Winken and G.W. Bruyn, editors. North Holland Publ. Co. Amsterdam, Vol. 21, pp 271-317.
- DIONNE, J., WRIGHT, G., BARBER, H., BOUCHARD, R. and BOUCHARD, J.P. (1979). Oculomotor and vestibular findings in autosomal recessive spastic ataxia of Charlevoix-Saguenay. *Can. J. Neurol. Sci.*, 6: 177-184.
- DYCK, P.J. (1975). Inherited neuronal degeneration and atrophy affecting peripheral motor, sensory, and autonomic neurons. In: *Peripheral Neuropathy*, Edited by Dyck, Thomas, Lambert, W.B. Saunders and Co. (Phil.) pp 825-867.
- DYCK, P.J. and LAMBERT, E.H. (1968). Lower motor and primary sensory neuron diseases with peroneal muscular atrophy. I. Neurologic, genetic and electrophysiologic findings in hereditary polyneuropathies. II. Neurologic, genetic and electrophysiologic findings in various neuronal degenerations. *Arch. Neurol.* 18: 603-625.
- GREENFIELD, J.G. (1954). *The spinocerebellar degenerations*. Blackwell Scient. Publ., Oxford.
- KIRKHAM, T.H., GUITON, D., KATSARKAS, A., KLINE, L.B. and ANDERMANN, E. (1979). Oculomotor abnormalities in Friedreich's ataxia. *Can. J. Neurol. Sci.*, 6: 167-172.
- LANGELIER, R., BOUCHARD, J.P. and BOUCHARD, R. (1979). Computed tomography of posterior fossa in hereditary ataxias. *Can. J. Neurol. Sci.*, 6: 195-198.
- LAROCHELLE, L., BEDARD, P., POIRIER, L.J. and SOURKES, T.L. (1971). Correlative neuro-anatomical and neuropharmacological study of tremor and catatonias in the monkey. *Neuropharmacol.*, 10: 273-288.
- PEYRONNARD, J.M., BOUCHARD, J.P., LAPOINTE, L., LAMONTAGNE, A., LEMIEUX, B. and BARBEAU, A. (1976). Nerve conduction studies and electromyography in Friedreich's ataxia. *Can. J. Neurol. Sci.*, 3: 313-318.
- ROTH, M. (1948). On a possible relationship between hereditary ataxia and peroneal muscle atrophy: with a critical review of the problems of "intermediate forms" in the degenerative disorders of the central nervous system. *Brain*, 71: 416-433.
- ROUSSY, G. and LEVY, G. (1926). Sept cas d'une maladie familiale particulière: troubles de la marche, pieds bots, et aréflexie tendineuse généralisée avec, accessoirement, légère maladresse des mains. *Rev. Neurol.* 1: 427-450.
- SALISACHS, P. and LAPRESLE, J. (1973). Névrite hypertrophique avec atrophie péronière associée à une dyskinésie volitionnelle d'attitude. *Rev. Neurol.* 129: 133-139.
- SILVER, J.R. (1966). Familial spastic paraplegia with amyotrophy of the hands. *J. Neurol. Neurosurg. Psychiat.*, 29: 135-144.
- TYRER, J.H. and SUTHERLAND, J.M. (1961). The primary spino-cerebellar atrophies and their associated defects, with a study of the foot deformity. *Brain*, 84: 289-300.
- TYRER, J.H. (1975). Friedreich's ataxia: In: *Handbook of clinical neurology*. P.J. Winken and G.W. Bruyn, editors. North Holland Publ. Co., Amsterdam. Vol. 21, pp 319-364.
- YUDELL, A., DYCK, P.J. and LAMBERT, E.H. (1965). A kinship with the Roussy-Levy syndrome: a clinical and electrophysiologic study. *Arch. Neurol.* 13: 432-440.