





## Letter to the Editor: New Observation

# Utility of Repeat Endpoint Quaking-Induced Conversion Testing in Creutzfeldt–Jakob Disease

Benjamin K. Dawson<sup>1</sup> , Andrew Gibson<sup>1</sup>, J. David Knox<sup>2</sup>, Keng Yeow Tay<sup>3</sup>, Andrew Leung<sup>3</sup> , Robert Hammond<sup>4</sup>  and Adrian Budhram<sup>1,4</sup> 

<sup>1</sup>Department of Clinical Neurological Sciences, London Health Sciences Centre and Western University, London, Ontario, Canada, <sup>2</sup>National Microbiology Laboratory, Public Health Agency of Canada, Winnipeg, Manitoba, Canada, <sup>3</sup>Department of Medical Imaging, London Health Sciences Centre and Western University, London, Ontario, Canada and <sup>4</sup>Department of Pathology and Laboratory Medicine, London Health Sciences Centre and Western University, London, Ontario, Canada

**Keywords:** Dementia; Prion; Creutzfeldt–Jakob disease

A 66-year-old woman was admitted to hospital with an 8-month history of progressive expressive language difficulties accompanied by more global functional decline. Over this time period, she had also developed memory difficulties and reported recently forgetting having put food in the oven until her smoke detectors were triggered. She additionally endorsed fragmented sleep, rapid involuntary contractions in the upper extremities that caused her to drop objects, and weight loss of 20–30 pounds. She had enlisted a food delivery service, as well as a personal care worker who now assisted her with activities of daily living. Her past medical history was notable for infectious encephalitis as a child as well as severe scoliosis without previous surgical intervention, resulting in predominantly wheelchair use for mobility.

On neurologic examination she scored 11/30 on the Montreal Cognitive Assessment (MoCA), compatible with dementia. She had evidence of expressive aphasia, ideomotor apraxia as well as stimulus-sensitive myoclonus. Despite appearing cachectic, she had full power. Spasticity was elicited in bilateral lower extremities, and Babinski sign was present bilaterally, potentially related to previous history of infectious encephalitis or severe scoliosis. There was no definite loss of sensation to pinprick or vibration, nor was there incoordination.

Magnetic resonance imaging (MRI) of the brain revealed bilateral signal abnormality of the cerebral cortices with peri-rolandic sparing, which was most evident on diffusion-weighted imaging (Figure 1). No signal abnormality of the basal ganglia or thalami was observed. Initial electroencephalogram (EEG) showed left temporal sharply contoured slowing, without definite spikes. Routine bloodwork for toxic, metabolic, and infectious causes of her symptoms was unremarkable. Based on her clinico-radiographic presentation, there was a high index of suspicion for Creutzfeldt–Jakob disease (CJD). For this reason, cerebrospinal fluid (CSF) was submitted to the National Microbiology Laboratory (NML) for prion disease testing including endpoint

quaking-induced conversion (EP-QuIC), which returned negative. Testing for 14-3-3 and total tau was also within normal limits.

Over the next 4 weeks, repeated brain MRIs showed no significant change in signal abnormalities. Repeat EEG showed abundant left temporal spikes, although no seizures were captured. No lateralized periodic discharges were observed. Given the negative CSF testing for prion disease and abundant temporal lobe spikes, expanded investigations including neural antibody testing for possible autoimmune encephalitis were performed. This was unremarkable outside of isolated weak positivity for anti-leucine-rich glioma-inactivated 1 by cell-based assay, without corroborative staining on tissue indirect immunofluorescence that raised the possibility of a false-positive/clinically irrelevant result. The patient had no clinical improvement after an empiric 5-day trial of methylprednisone 1 g intravenous daily, further reducing the likelihood of an antibody-mediated encephalitis. Given the high index of suspicion for CJD, CSF was re-collected and again submitted to the NML 4 weeks after initial CSF submission; while testing for 14-3-3 and total tau was again within normal limits, repeat EP-QuIC was positive. Genetic testing for CJD performed at the NML revealed no *PRNP* mutations, with the heterozygous methionine/valine (MV) genotype at codon 129. The patient was informed that her CSF testing was compatible with CJD. No further testing for alternative diagnoses was performed, and the patient was transferred to hospice care. She died 2 months later, and neuropathologic examination revealed vacuolar changes and scrapie-associated prion protein (PrP<sup>Sc</sup>) deposition that was confirmatory of sporadic CJD (Figure 2).

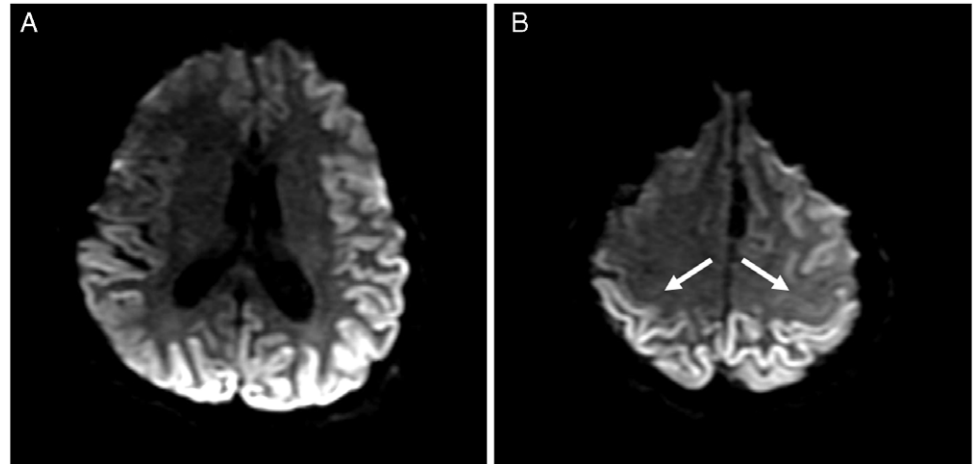
Sporadic CJD is a fatal neurologic disease that is characterized by the misfolding of normal prion protein. The diagnostic gold standard is detection of PrP<sup>Sc</sup> by neuropathologic examination, which is required for a diagnosis of definite sporadic CJD by Centers for Disease Control and Prevention (CDC) diagnostic criteria.<sup>1</sup> However, real-time quaking-induced conversion (RT-

**Corresponding author:** Adrian Budhram, Department of Clinical Neurological Sciences, London Health Sciences Centre, Western University, 339 Windermere Road, London, Ontario, Canada N6A 5A5. Email: [Adrian.budhram@lhsc.on.ca](mailto:Adrian.budhram@lhsc.on.ca)

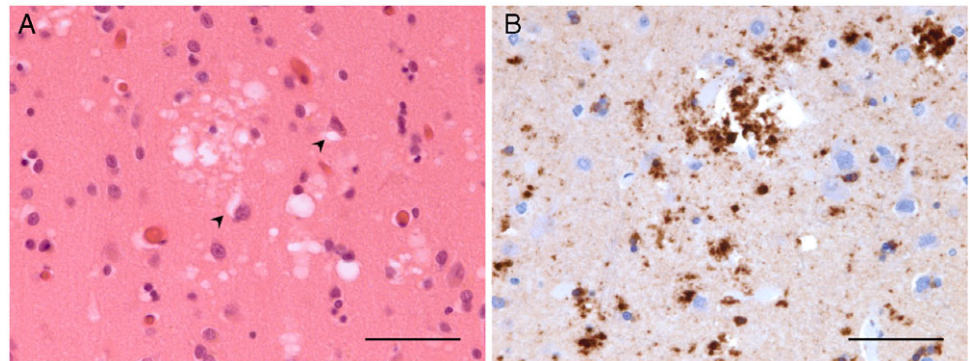
**Cite this article:** Dawson BK, Gibson A, Knox JD, Tay KY, Leung A, Hammond R, and Budhram A. (2023) Utility of Repeat Endpoint Quaking-Induced Conversion Testing in Creutzfeldt–Jakob Disease. *The Canadian Journal of Neurological Sciences* 50: 929–931, <https://doi.org/10.1017/cjn.2022.306>

© The Author(s), 2022. Published by Cambridge University Press on behalf of Canadian Neurological Sciences Federation. This is an Open Access article, distributed under the terms of the Creative Commons Attribution licence (<http://creativecommons.org/licenses/by/4.0/>), which permits unrestricted re-use, distribution and reproduction, provided the original article is properly cited.

**Figure 1:** Cortical diffusion restriction with peri-rolandic sparing typical of Creutzfeldt–Jakob disease. Axial diffusion-weighted imaging reveals bilateral cortical hyperintensities (A, B) with peri-rolandic sparing (B, arrows), typical of CJD. Corresponding hypointensities on apparent diffusion coefficient map confirmed true diffusion restriction (not shown).



**Figure 2:** Neuropathologic findings typical of Creutzfeldt–Jakob disease. Samples from the left temporal neocortex reveal patchy spongiform change with select vacuoles abutting cortical neurons (A, arrowheads) (hematoxylin and eosin, scale bar = 50 µm). Immunoperoxidase preparations confirm the presence of fine punctate and larger granular collections of abnormal prion proteins (B) (anti-PrP<sup>Sc</sup>, ECM Biosciences, Versailles, Kentucky, scale bar = 50 µm).



QuIC) is a recently developed prion-specific assay that can be performed antemortem using CSF and has high clinical sensitivity and specificity for CJD.<sup>2</sup> Its diagnostic value is reflected in the CDC diagnostic criteria, which permit a diagnosis of probable sporadic CJD to be made if a patient has any neuropsychiatric disorder plus a positive RT-QuIC result in CSF. The EP-QuIC assay in use in Canada is similar to that of RT-QuIC, with a comparably high reported clinical sensitivity and specificity of 96% and 99%, respectively, for CJD in a study of prospectively acquired CSF samples.<sup>3</sup> Of particular relevance to our case is the high clinical sensitivity (i.e., low false-negative rate) of EP-QuIC. In the aforementioned study, only three false-negatives under current assay conditions were identified out of 623 submitted samples.<sup>3</sup> While false-negative EP-QuIC results are rare, they can have profound implications on patient care; they may result in excessive additional tests, incorrect alternative diagnoses, and inaccurate prognostication resulting in undue stress to patients and caregivers.

Given the substantial impact a negative EP-QuIC result can have on patient diagnosis and management, placing this test result in the context of the clinical presentation is of particular importance. Our patient had rapidly progressive dementia along with diffuse cortical restricted diffusion that exhibited peri-rolandic sparing, which is highly suggestive of CJD.<sup>4,5</sup> Her initial negative EP-QuIC, alongside the absence of typical EEG findings<sup>6</sup> and an equivocal neural antibody result of unclear clinical relevance,<sup>7</sup> reduced the level of certainty in the diagnosis of CJD, although it remained a leading consideration. We hypothesized that repeat CSF testing after 4 weeks could increase the likelihood of a positive EP-QuIC result if the diagnosis was CJD, due to the expected

progression of prion burden over time. While the value of repeat RT-QuIC testing in the diagnosis of CJD after an inconclusive result has previously been described,<sup>8</sup> to our knowledge there are no previous reports demonstrating the value of repeat EP-QuIC testing in patients with an initial negative result. The findings of our case suggest that repeat EP-QuIC testing should be considered in patients with an initial negative result if there remains a high index of suspicion for CJD, and may help to ensure accurate patient diagnosis.

**Disclosures.** Dr. Dawson has nothing to disclose.

Dr. Gibson has nothing to disclose.

Dr. Knox has nothing to disclose.

Dr. Tay has nothing to disclose.

Dr. Leung has nothing to disclose.

Dr. Hammond has nothing to disclose.

Dr. Budhram reports that he holds the London Health Sciences Centre and London Health Sciences Foundation Chair in Neural Antibody Testing for Neuro-Inflammatory Diseases and receives support from the Opportunities Fund of the Academic Health Sciences Centre Alternative Funding Plan of the Academic Medical Organization of Southwestern Ontario (AMOSO).

Statistical analysis was not required for preparation of this manuscript.

No funding was received for this manuscript.

The authors have not published, posted, or submitted any related manuscripts from the same study.

**Statement of Authorship.** BKD: design and conceptualization, literature review, data analysis/interpretation, and drafting of the manuscript.

AG: data analysis/interpretation and critical revision of the manuscript for intellectual content.

JDK: data analysis/interpretation and critical revision of the manuscript for intellectual content.

KYT: data analysis/interpretation and critical revision of the manuscript for intellectual content.

AL: data analysis/interpretation and critical revision of the manuscript for intellectual content.

RH: data analysis/interpretation and critical revision of the manuscript for intellectual content.

AB: design and conceptualization, literature review, data analysis/interpretation, drafting of the manuscript, and project supervision.

## References

1. CDC's Diagnostic Criteria for Creutzfeldt-Jakob Disease (CJD). Centers for Disease Control and Prevention; 2018. Available at: <https://www.cdc.gov/prions/cjd/diagnostic-criteria.html>
2. McGuire LI, Peden AH, Orrú CD, et al. Real time quaking-induced conversion analysis of cerebrospinal fluid in sporadic Creutzfeldt-Jakob disease. *Ann Neurol*. 2012;72:278–85.
3. Simon SLR, Peterson A, Phillipson C, et al. Prospective study demonstrates utility of EP-QuIC in Creutzfeldt-Jakob disease diagnoses. *Can J Neurol Sci*. 2021;48:127–9.
4. Vitali P, Maccagnano E, Caverzasi E, et al. Diffusion-weighted MRI hyperintensity patterns differentiate CJD from other rapid dementias. *Neurology*. 2011;76:1711–9.
5. Young GS, Geschwind MD, Fischbein NJ, et al. Diffusion-weighted and fluid-attenuated inversion recovery imaging in Creutzfeldt-Jakob disease: high sensitivity and specificity for diagnosis. *AJNR Am J Neuroradiol*. 2005;26:1551–62.
6. Wieser HG, Schindler K, Zumsteg D. EEG in Creutzfeldt-Jakob disease. *Clin Neurophysiol*. 2006;117:935–51.
7. Budhram A, Yang L, Bhayana V, Mills JR, Dubey D. Clinical sensitivity, specificity, and predictive value of neural antibody testing for autoimmune encephalitis. *J Appl Lab Med*. 2022;7:350–6.
8. Barbosa BJAP, Castrillo BB, Alvim RP, et al. Second-generation RT-QuIC assay for the diagnosis of Creutzfeldt-Jakob disease patients in Brazil. *Front Bioeng Biotechnol*. 2020;8:929.