

The Journal of Laryngology and Otology

(Founded in 1887 by MORELL MACKENZIE and NORRIS WOLFENDEN)

October 1938

OBSERVATIONS ON THE PATHOLOGY OF MÉNIÈRE'S SYNDROME

By C. S. HALLPIKE and H. CAIRNS (London)

(from the Ferens Institute of Otology, Middlesex Hospital, and the
Department of Neurosurgery, London Hospital)

It is the purpose of this paper to describe—it is believed, for the first time—the pathological changes in the temporal bones of two cases of Ménière's syndrome. In both death occurred shortly after operation for section of the VIIIth nerve. For the purposes of the present paper, the surgical factors concerned in the operative failure of these cases will be dealt with only in so far as they are related to the interpretation of the histological changes which are now to be described. Their detailed consideration will be reserved for a further publication.

Introduction

The close anatomical association of the sense organs of hearing and equilibrium within the internal ear has always supported the more general view that impairment of function of these organs, often paroxysmal in type, would be likely to result from a wide variety of pathogenic agents acting upon the sensory elements, on their blood supply, or upon the labyrinth fluids. This general formula is accepted by Watkyn-Thomas¹ who states in a recent text-book that "we are justified in assuming that there is no one primary cause of Ménière's syndrome".

C. S. Hallpike and H. Cairns

In spite of the advantages of such a general outlook, the possibility must be welcomed of a closer differentiation by clinical methods of the pathological factors concerned in these cases: that is to say, by the establishment of the fact that in a significantly large group of cases, the signs and symptoms of acoustic and equilibrial disturbance present certain recognizable peculiarities in their mode of onset, in their type and degree, and in the course which they run over a period of years. This point of view has been ably put in two recent papers by Wright² and Crowe,³ who agree very closely, both in their clinical identification of a frequently encountered type of case and in postulating therein the action upon the labyrinthine end-organs of a single type of pathogenic agent. Wright believes the condition to be due to bacterial intoxication of the labyrinth, and describes it as a focal labyrinthitis. Crowe is less specific in his view of the type of pathogenic agent, but ascribes the condition to a disorder of the normal conditions of pressure and chemical constitution of the endolymph. One further possibility is represented by the view of Dandy⁴, who believes the site of the lesion to be in the trunk of the VIIIth nerve and not in the labyrinth.

Earlier reports upon the changes in the temporal bones in cases of so-called Ménière's syndrome are to our knowledge available in only two instances. In one of these, described by Witmaack⁵, a neurofibroma was revealed in the basal coil of the cochlea. In the other, described by Videbeck⁶, a generalized encephalitis was discovered, apparently of traumatic origin. Within the cochlea there was found a degeneration of Corti's organ with collapse of Reissner's membrane.

The point of view which we ourselves are inclined to favour is the one supported by the papers of Wright and Crowe, namely that a considerable proportion of patients exhibiting this syndrome are recognizable upon clinical grounds as being the victims of a common type of labyrinthine disorder. Clinical observation, possibly over a period of years, alone justifies the exclusion from this group of cases of traumatic encephalitis and of acoustic neuroma, and for this reason the reports of Witmaack and Videbeck are not considered relevant to the present paper. On the other hand, the clinical features of the present cases warrant their inclusion in the clinical group defined by Wright and Crowe, and the description of the anatomical changes in the temporal bones is, it is believed,

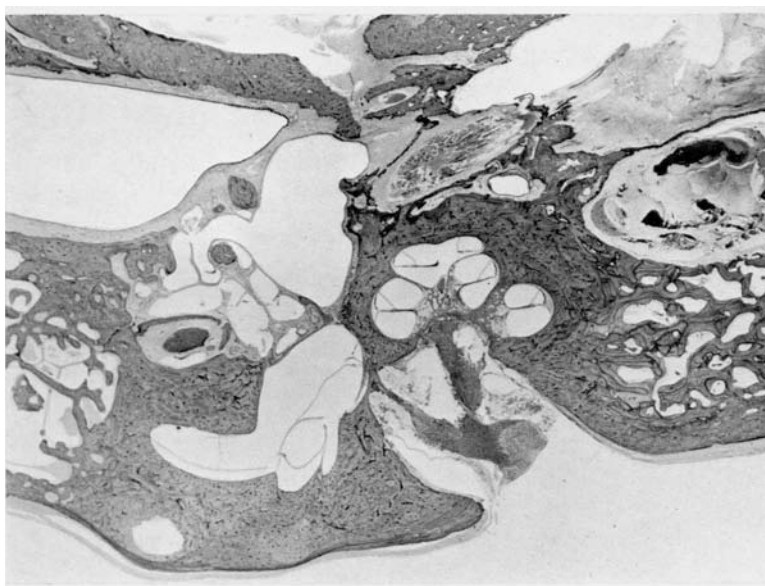


FIG. 1.

Case I. Right temporal bone. Low power view showing chronic inflammatory changes in the tympanum. The cochlea and vestibule are normal.

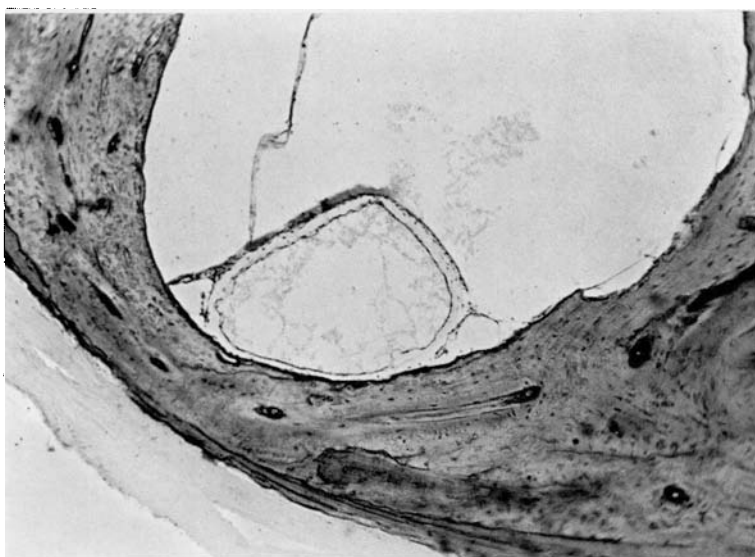


FIG. 2.

Case I. Right temporal bone. Anterior vertical canal. The membranous canal contains a moderate amount of albuminoid coagulum. There is also a mild degree of sub-epithelial vesiculation. The changes are of doubtful pathological significance.

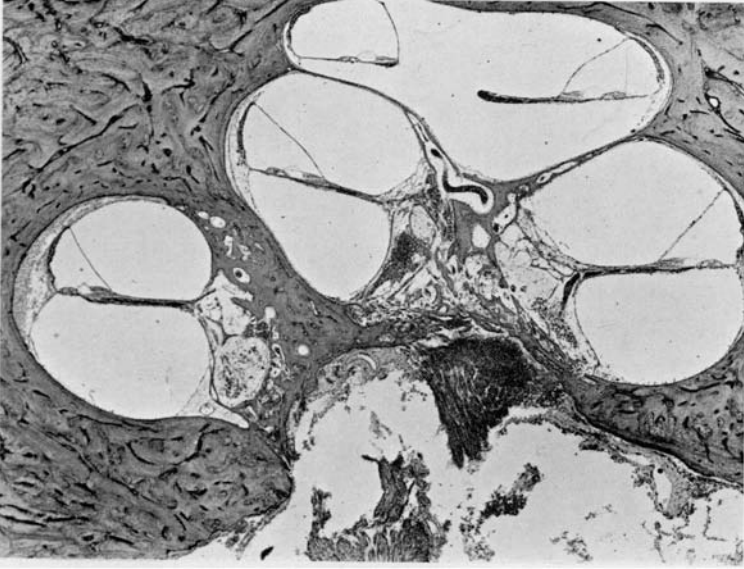


FIG. 3.

Case 1. Right temporal bone. The cochlea. No abnormality is present.

Pathology of Ménière's Syndrome

the first of its kind to be recorded. The clinical history of the first case now follows.

CASE I

Clinical History.—J.B., a dock labourer, aged 63, was referred to the department of Neurosurgery at the London Hospital by Mr. Maurice Sorsby in December, 1934, on account of attacks of vertigo. Apart from anthrax of the thumb when a young man, and occasional winter bronchitis, he had enjoyed good health until three years before admission when he began to have mild attacks of vertigo, followed six months later by attacks of greater severity, at times associated with falling. Owing to attacks in the docks he was put off work for four months during 1932 and for five months in 1933; during each of these periods he was treated by Eustachian catheterization and sedative drugs with slight relief. In 1934, five months before admission to Hospital, owing to further attacks at work he was discharged from his employment. His attacks became worse and for two months before admission he did not venture into the street alone for fear of falling in the traffic.

The mild attacks began with a momentary sensation of hot flushing in the head, followed by a slight loss of balance. He could still walk during these attacks, with a tendency to go to the left in zig-zag fashion, and with no certainty that when he put his foot down he would find a secure foothold; but after a dozen paces he would be all right again. In attacks of longer duration he would kneel to save himself from falling.

In the more severe attacks everything seemed to go black and he had to sit or lie down. There was then no sensation of rotation or of movement of the ground, but instead a feeling that he was staggering about; this lasted for a half-hour and was followed by unusually prompt recovery. On three occasions he fell without warning, twice in a backward direction with momentary loss of consciousness; once he nearly fell out of a chair. After each of these attacks he was able to get up immediately and to walk steadily. On a few occasions he was awakened by an attack. There was no vomiting or diplopia with the attacks.

One year before the attacks began he noticed that he was becoming deaf in the left ear. This deafness was progressive, and always worse in the winter time. He had never had aural discharge, but much dry wax came from his ears, and during the times when this was profuse he noticed that he was deaf also

C. S. Hallpike and H. Cairns

in his right ear. From the time of the onset of the deafness he was usually conscious of a drumming noise in the left ear ; this varied in intensity with his deafness but was not worse during the attacks.

Examination.—He was a well built, rather plethoric type of man. Blood pressure, 138/92. Smell was slightly defective at both nostrils and there was fine nystagmus to the right, but neurological examination, apart from auditory and vestibular investigations, showed no abnormality. His gait was normal. *Examination of Hearing:* Mr. Maurice Sorsby, to whom we are indebted for his records, had noted in the latter part of 1934 that both tympanic membranes were retracted, the left being worse than the right. The Eustachian tubes were patent. He noted also considerable loss of hearing, the lower tone limit being raised and the upper tone limit lowered. Bone conduction was shortened and Rinne's test positive. In the London Hospital it was found that he could hear whispers 2 feet from the right ear and the ordinary speaking voice only 3 inches from the left ear. Cold caloric test, with the patient lying down, gave no response on the left side after three minutes irrigation, on the right side nystagmus to the left after twenty seconds, but no vertigo.

Operation (December 18th, 1934).—Under avertin and intratracheal gas and oxygen anæsthesia the left vestibular nerve and part of the left cochlear nerve were divided. The operation was unusually difficult because of the excessive thickness and hardness of all parts of the posterior fossa (2 cm. in thickness over the lateral sinus). In consequence of this the bony opening was smaller than usual. However, division of the nerve was effected without any untoward incident, except that throughout the operation and in spite of avertin, the blood pressure was at an unusually high level. The highest level, 200/100, was recorded while the nerve was being divided.

Post-operative Course.—He responded well after operation, but the same evening he became restless, and during the night unconscious, with rising pulse rate and temperature, stertorous and bubbly breathing, small fixed pupils, absent corneal reflexes, flaccid limbs, diminished or absent tendon and plantar reflexes, and raised blood pressure (170/90). The bladder became distended and the urine contained a trace of sugar and albumin. The wound was re-opened twelve hours after the first operation, and there was tremendous tension and swelling

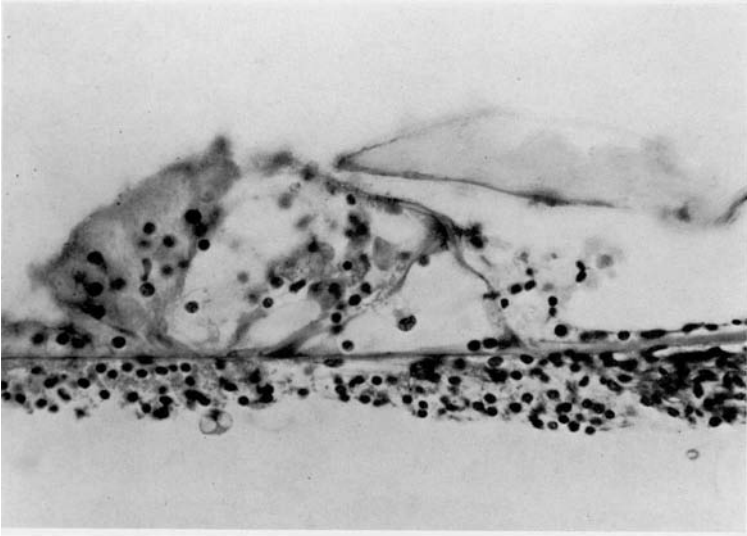


FIG. 4.

Human organ of Corti, showing the appearance typical of a fairly advanced degree of post-mortem degeneration.

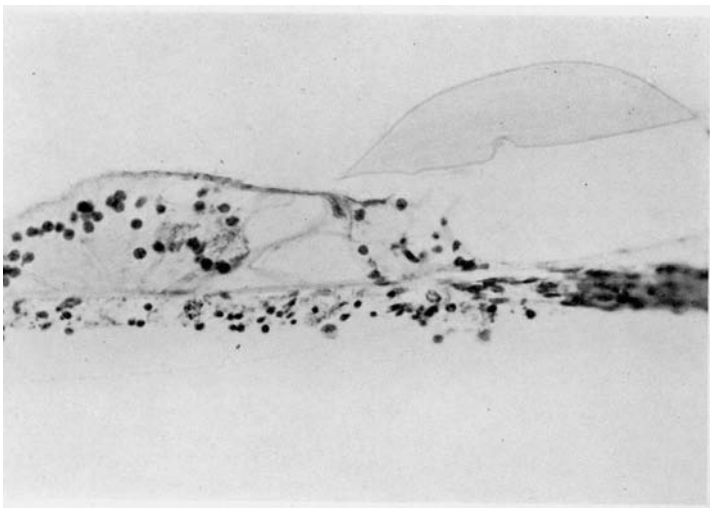


FIG. 5.

Case I. Right temporal bone. Corti's organ, showing a moderate degree of post-mortem degeneration. No pathological change is recognizable.

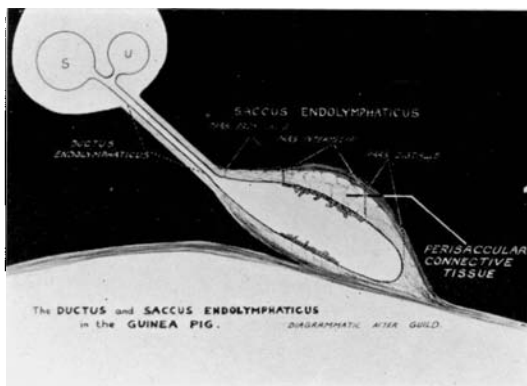


FIG. 6.

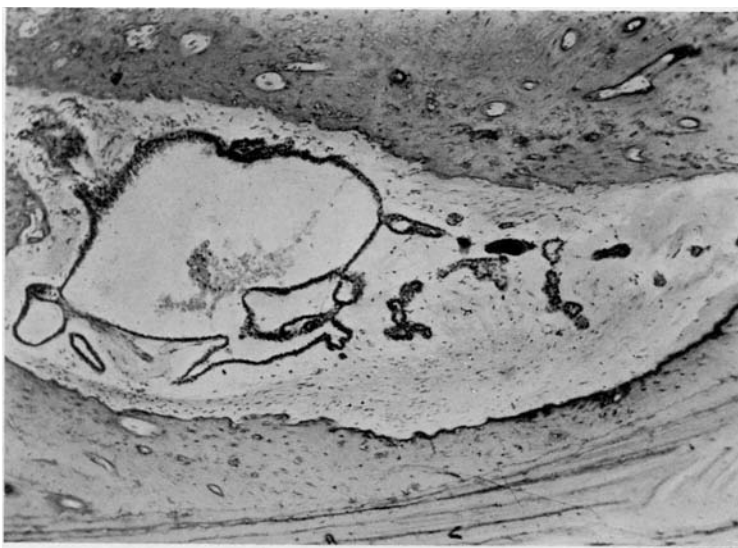


FIG. 7.

The human saccus endolymphaticus, showing the "normal" area of soft connective tissue surrounding the saccus.

Pathology of Ménière's Syndrome

of the presenting left lateral cerebellar lobe, associated with herniation of the tonsils, through the foramen magnum, which could only be relieved by decompressing the foramen magnum and allowing fluid to escape from the cisterna magna. Part of the posterior surface of the left cerebellar lobe was also removed. There was no evidence of post-operative bleeding. After operation his condition improved, but he did not fully regain consciousness and his chest condition became steadily worse with much purulent material in the trachea, and moist sounds and diminished breath sounds all over the chest. This was treated by posture and intermittent tracheal suction, but the patient died on December 21st.

Autopsy six hours after death showed an area of cavitation and hæmorrhage measuring 5.8×3.0 cm. in the white matter of the left cerebellar lobe and extending into the vermis and across the middle line. Both lungs showed congestion and œdema, and in the right lung there were a few nodules of broncho-pneumonia.

Comment.—Various technical points in connection with the operation of intracranial division of the VIIIth nerve will be considered in a later paper, but in passing it may be noted that this patient showed during the operation a tendency to arterial hypertension which may have contributed to the onset of cerebellar œdema and hæmorrhage, as did the smallness of the bony opening in the posterior fossa.

PATHOLOGICAL REPORT.

The temporal bones were received at the Ferens Institute on April 22, 1936, in a 4 per cent. solution of formaldehyde in which they had been preserved since the post-mortem examination, which was carried out on December 22nd, 1934, six hours after death. They were fully decalcified in 1 per cent. nitric acid in distilled water under control by X-rays and were embedded in celloidin. Serial sections were made in the horizontal plane at 25μ . Every tenth section was stained with Ehrlich's hæmatoxylin and counterstained with a mixture of Biebrich scarlet and eosin.

Histological Findings

RIGHT TEMPORAL BONE.

Pneumatization.—No air spaces are to be observed anterior to the cochlea. The area is occupied by cancellous bone with

C. S. Hallpike and H. Cairns

delicate bony trabeculae separating wide spaces containing fatty marrow. In the region surrounding the antrum the air spaces are poorly developed and their lining shows a moderate degree of chronic inflammatory change. There is thickening and fibrosis of the mucosa with scattered collections of leucocytes, chiefly small lymphocytes. In places the air cells contain masses of mucus and desquamated epithelium in varying stages of degeneration.

Labyrinth capsule.—This shows no abnormality. The fissula ante fenestram is present and well developed. No fissula post fenestram is present.

External auditory meatus.—Normal.

Tympanum.—The tympanic membrane is grossly thickened. At a point immediately anterior to the inferior extremity of the handle of the malleus its thickness was found by measurement to be 340μ . The average thickness of the membrane measured in this way in six normal specimens was found to vary between 80μ and 112μ with an average value of 94μ . Extensive chronic inflammatory changes are present in the tympanic mucosa; the epithelium is generally preserved; the sub-mucosa is greatly increased in thickness and contains numerous inflammatory cells, chiefly small lymphocytes. Laidlaw's silver stain shows numerous fine collagen fibrils.

Vestibule.—The disposition and size of the endolymph spaces in the vestibule show no abnormality. The perilymph cistern in the region of the stapes footplate is of normal size.

The state of development of the pneumatic and marrow spaces, the inflammatory changes in the tympanum, and the relations of endo- and perilymph spaces in the vestibule are depicted in Fig. 1.

The vestibular sense organs and the semi-circular canals.
Normal anatomy. The macular epithelium of the utricle, saccule, and cristae of the semi-circular canals consists normally of a layer of cells of very even thickness, lying between a well-defined basement membrane and a superficial reticulated membrane through which project the hairs of the sensory cells. The sensory cells are relatively few, and their nuclei are more or less centrally placed. The nuclei of the more numerous supporting cells lie scattered at all levels between the membranes and resemble the nuclei of the sensory cells in their size and structure, particularly under the conditions of fixation and staining which were employed in the present case. Under

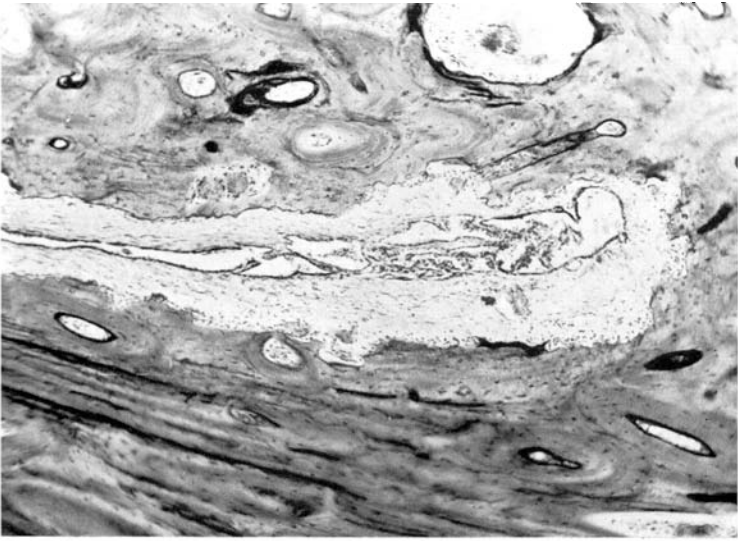


FIG. 8.

The saccus endolymphaticus from a patient without a known history of deafness. There is an atypical absence of the area of soft connective tissue around the saccus.

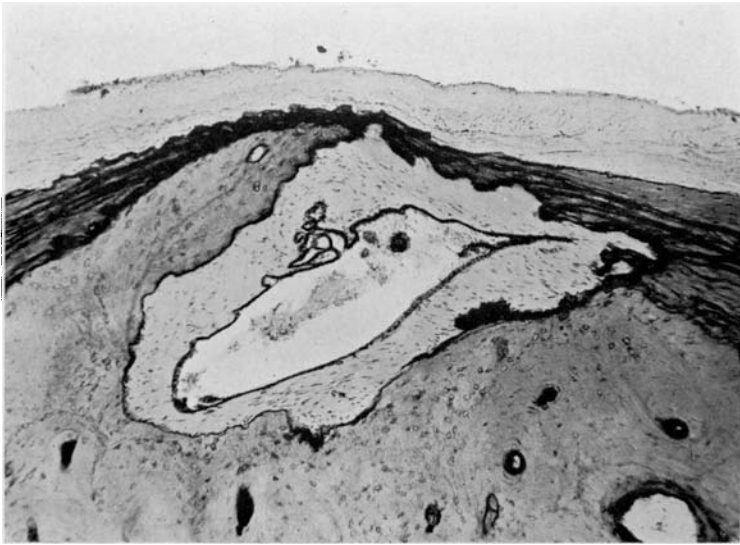


FIG. 9.

Case I. Right temporal bone, showing the absence of the "normal" perisaccular connective tissue.

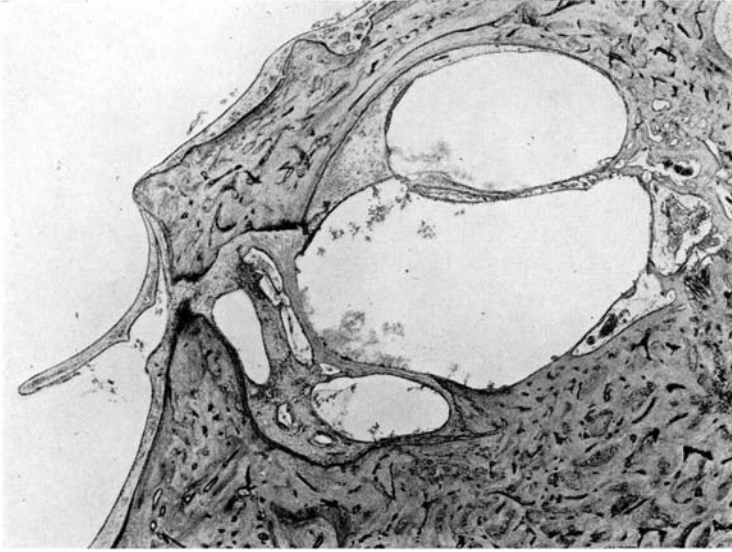

FIG. 10a.

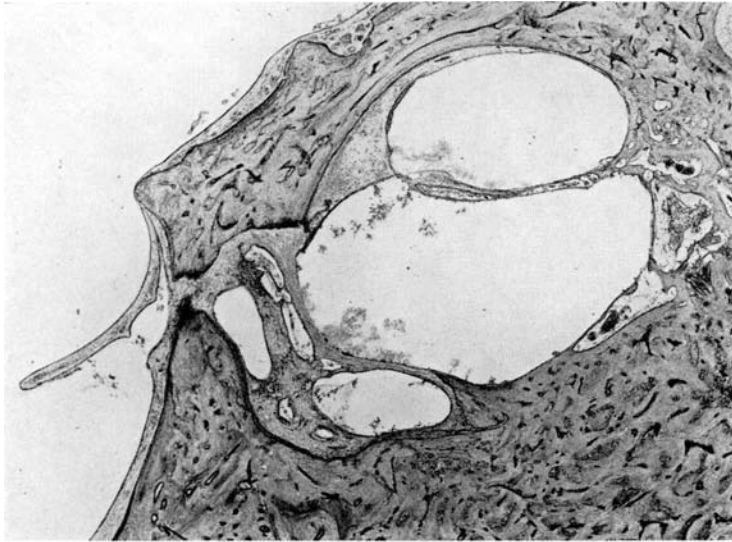

FIG. 10c.

Case I. *a* and *c* show the left stapes footplate and round window membrane. *b* and *d* show the same structures on the right side. Much chronic inflammatory granulation tissue is present in all four of the areas shown with thickening of the round window membrane.

Pathology of Ménière's Syndrome

these conditions also the cytoplasm is poorly preserved and its shrinkage exposes the keratin filaments of the supporting cells. The nuclei however stain well with hæmatoxylin and show numerous well differentiated chromatin granules.

1. *The vestibular sense organs.*—The condition of the maculae of the saccule and utricle in the present case is in close accordance with that described above as normal. There is no displacement of the otolith membranes and the density of the innervation is normal.

2. *The semi-circular canals.*—The epithelium and innervation of the cristae show no abnormality. In the internal limb of the anterior vertical canal and in the lateral canal certain changes are present in the lining epithelium which are reproduced in Fig. 2. The epithelium has been raised in localized excrescences, apparently by the formation of sub-epithelial fluid collections. A similar condition of comparable degree is present in these areas in seven out of ten normal cases between the ages of 40 and 60 years. Its pathological significance must therefore be regarded as doubtful.

The cochlea.—This shows no abnormality, either in the disposition of Reissner's membrane or the density of the spiral ganglion. The stria vascularis is normal. Fig. 3.

Corti's organ.—The interpretation of anatomical changes in Corti's organ is notoriously difficult on account of the rapid progress of post-mortem disintegration, a difficulty which is particularly marked in the human subject. The histological features of this type of degeneration have been well established by the investigations of Eckert Möbius⁷, and others, and may be described briefly as follows :

The cytoplasm shows a slight loss of density although the cell outlines are generally well preserved. The nuclei become pyknotic. More striking are the changes in form of Corti's organ as a whole, the cells of which show a marked tendency to break off and float away from the main mass. The tectorial membrane may undergo dissolution. Fig. 4 shows the condition typical of fairly advanced post-mortem degeneration of the human organ of Corti.

Fig. 5 shows the organ of Corti of the right temporal bone in the present case. It shows a moderate degree of post-mortem degeneration. No pathological change is recognizable.

VIIIth nerve and internal auditory meatus.—The VIIIth nerve has been cut across at a point about 1 cm. central to the

C. S. Hallpike and H. Cairns

neuroglial-neurilemmal junction. The neuroglial portion of the nerve shows a very well marked band of corpora amylacea, though these are not in excess of the amount normally present in this area at the age of the present subject. The nerve fibres and Scarpa's ganglion are normal. In the fundus of the meatus and between the diverging nerve bundles there is a considerable amount of structureless coagulum and inflammatory cells, chiefly polymorphonuclear leucocytes. This appears indicative of a moderate degree of meningeal reaction associated with the post-operative condition.

The aqueduct of the cochlea.—Scattered polymorphonuclear leucocytes are present throughout the length of the aqueduct, apparently derived from the sub-arachnoid space. Similar cells have been described in the fundus of the internal auditory meatus. In addition, there is a small collection of polymorphonuclear leucocytes adjoining the basilar membrane opposite the opening into the scala tympani of the cochlear aqueduct.

The saccus endolymphaticus.—The saccus and its surroundings display certain deviations from the condition defined as normal by Guild⁸, and later by Anson and Nesselrod⁹. Fig. 6 shows a diagrammatic representation of the mammalian ductus and saccus endolymphaticus according to Guild. The narrow tube lined by flattened epithelium is the ductus and all of the wider distal part is the saccus, which Guild divides into three parts, proximal, intermediate, and distal. The proximal and distal parts are lined by flattened epithelium and the intermediate part by a low columnar epithelium with recesses and papillary ingrowths. Surrounding this "pars intermedia" is a very loose vascular connective tissue.

In the course of another investigation Guild¹⁰ was able to show by means of the Prussian blue granule technique that the endolymph was absorbed through the wall of the pars intermedia into the loose perisaccular connective tissue.

A substantial confirmation of Guild's description has been provided by the examination of the temporal bones of thirteen normal subjects between the ages of 30 and 60 years. In eleven of these there was a well marked development of the perisaccular connective tissue as Guild describes. The condition is shown in Fig. 7. Considerable deviation from this condition does however appear to lie within the limits of normal variation. In two of the temporal bones of normal subjects

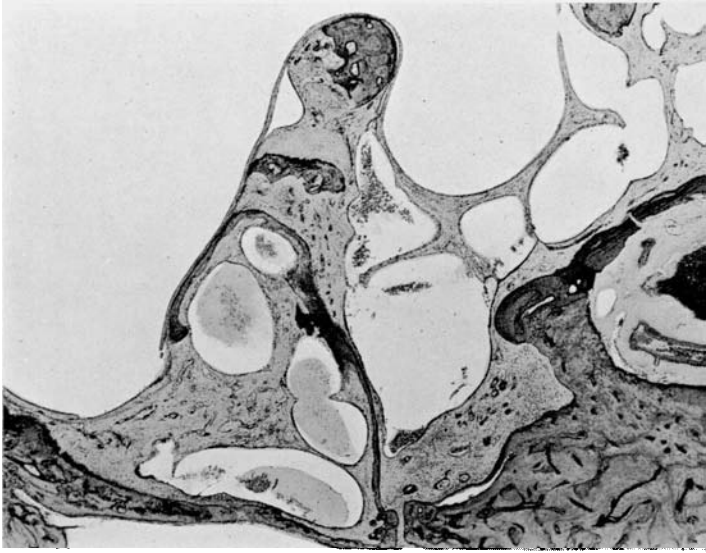


FIG. 10b.

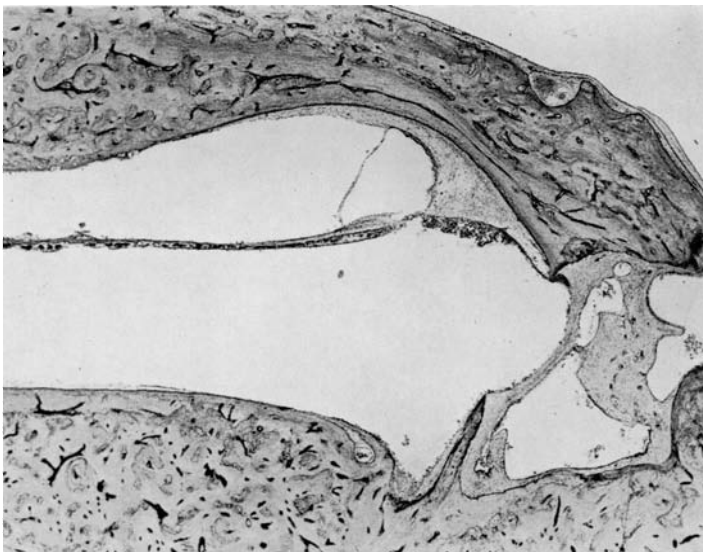


FIG. 10d.

Case I. *a* and *c* show the left stapes footplate and round window membrane. *b* and *d* show the same structures on the right side. Much chronic inflammatory granulation tissue is present in all four of the areas shown with thickening of the round window membrane.

Pathology of Ménière's Syndrome

so examined the perisaccular connective tissue was very poorly developed, and in these the epithelium was brought into practically direct relationship with the dense material of the surrounding dura mater. This condition is shown in Fig. 8.

The right saccus endolymphaticus of the present subject is shown in Fig. 9. It is of interest in its close reproduction of the condition shown in Fig. 8. That is to say, it belongs to the smaller anatomical group in which the "normal" area of perisaccular connective tissue is poorly developed.

LEFT TEMPORAL BONE.

Pneumatization.—There are no apical air spaces. The area anterior to the cochlea is occupied by wide-meshed cancellous bone containing fatty marrow. The air cells around the antrum are poorly developed and exhibit chronic inflammatory changes in their lining mucosa which are comparable in degree and extent to those described in the right temporal bone.

Labyrinth capsule.—This shows no abnormality. The fissula ante fenestram is present and well developed. No fissula post fenestram is present.

External auditory meatus.—Normal.

Tympanum.—Thickening of the tympanic membrane and chronic inflammatory changes in the tympanic mucosa are present and correspond closely in degree and distribution to those found in the right ear. The chronic inflammatory changes around the stapes footplates and round window membranes in the two ears are shown in Fig. 10, which emphasizes their symmetrical distribution.

In addition there is a marked thickening of the posterior end of the stapes footplate. The thickening is maximal at the posterior extremity of the footplate and tapers rapidly towards the anterior extremity, which is of normal thickness. The adjacent annular ligament is not involved. The bone constituting the thickening shows a degree of hæmatoxylin retention usual in mature lamellar bone. It is composed of small irregular lamellar systems with a very few ill-marked cement lines. The marrow spaces are moderately vascular, contain no inflammatory cells, and communicate in places by wide channels with the deep layers of the overlying mucosa.

The constitution of the bony mass favours its inflammatory origin without being incompatible with the view that it

C. S. Hallpike and H. Cairns

represents a late stage of otosclerosis. Localization of an otosclerotic lesion to the posterior extremity of the stapes footplate would however be unique, and this latter possibility must therefore be regarded as inadmissible.

The vestibule.—The disposition of the membranous walls of the utricle and saccule shows a marked abnormality. There is moderate dilatation of the utricle, particularly towards its upper part in the roof of the vestibule. At this point the small perilymph space lateral to the macula and on either side (anterior and posterior) of the point of entry of the utricular nerve has been obliterated. Lower, though still above the level of the oval window, this space persists although reduced in depth.

At the level of the stapes footplate the outstanding feature is an enormous dilation of the saccule which occupies the whole of the vestibule with the exception of a small area occupied by the lower part of the utricle and the opening of the inner end of the lateral semi-circular canal. The perilymph cistern which normally bounds the deep aspect of the stapes footplate has been obliterated. At a slightly lower level there can be seen a protrusion of the saccule into the perilymph space of the inner extremity of the lateral semi-circular canal. In general, the greatly attenuated wall of the saccule can be traced in continuity. At the point described however a rupture of this wall into the perilymph space appears to have occurred. No interference can be demonstrated with the patency of the communicating pathways between the utricle, saccule, and ductus endolymphaticus, and the utricular fold (the possible valve-like action of which has been emphasized by Bast¹¹) is seen in its normal position. The state of development of the pneumatic and marrow spaces, the inflammatory changes in the tympanum, and the dilatation of the saccular cavity are shown in Fig. 11. Fig. 12 shows the changes in the stapes footplate at a higher magnification.

The vestibular sense organs.—In both saccule and utricle the tissues deep to the macular epithelium are infiltrated with well preserved red cells. These are continuous with the larger masses of red cells which occupy the fundus of the internal auditory meatus. The macular epithelium shows no abnormality apart from a moderate degree of post-mortem change. There is a slight degree of elevation of the otolith membrane from the utricular macula which is within the limits of artefact.

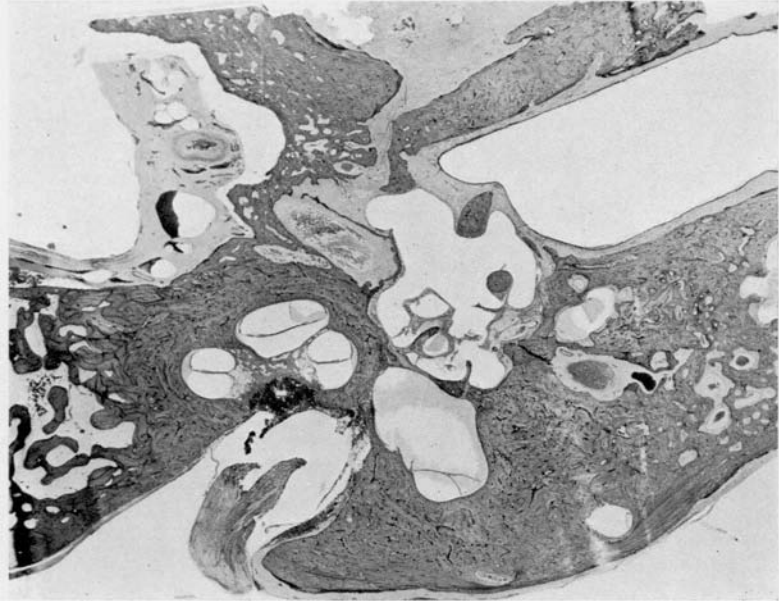

FIG. 11.

Case I. Left temporal bone. Low power view showing chronic inflammatory changes within the tympanum, and gross dilatation of the endolymph spaces of the vestibule and the cochlea.

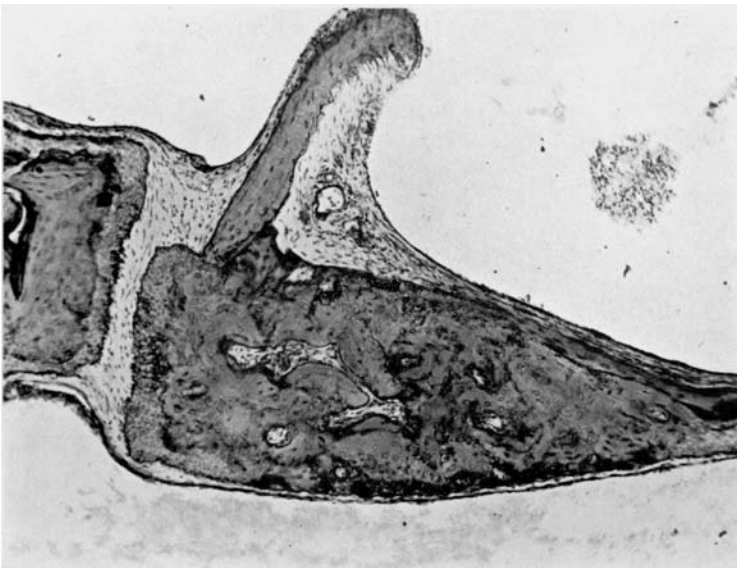


FIG. 12.

Case I. Left temporal bone. Bony thickening, probably of inflammatory origin, of the posterior extremity of the stapes footplate.

[face p. 634

Pathology of Ménière's Syndrome

The semi-circular canals.—No pathological changes can be recognized in the epithelium or innervation of the cristae. The canal walls show a moderate degree of sub-epithelial vesiculation as described in the opposite ear. Its pathological significance appears doubtful.

The cochlea.—A low power view of the cochlea is provided in Fig. 13. At this magnification there is to be seen a striking abnormality in the disposition of Reissner's membrane. In places this seems to have disappeared. In fact, this appearance is brought about by a gross dilatation of the scala media with displacement of Reissner's membrane on to the wall of the scala vestibuli, with obliteration of its perilymph space. In places the displacement of the membrane is not complete, and here can be seen organizing connective tissue elements apparently anchoring the membrane in its new position.

Fig. 14 shows a high power view of Reissner's membrane flattened against the roof of the scala vestibuli. The typical double row of epithelial and endothelial nuclei described by Retzius can be distinguished. Fig. 15 shows organizing connective tissue elements in the remaining niche of the scala vestibuli, anchoring Reissner's membrane in its new position. Laidlaw's stain shows a number of small but thick collagen fibrils.

The dilatation of the scala media is particularly marked at the helicotrema, and Reissner's membrane has here been displaced through the helicotrema into the apical portion of the scala tympani. This condition is shown in Fig. 16.

The spiral ganglion is of normal density, and its cells show no pathological changes.

Corti's organ.—Pathological changes have occurred in Corti's organ in all the whorls of a mid-modiolar section. The tendency towards disintegration of the cell mass with detachment of its members typical of post-mortem degeneration is not marked. As judged by the relative positions of the cell nuclei, a considerable compression or shrinkage of the cell mass has occurred. In addition, a reddish staining structureless coagulum is to be seen around the inner hair cells and filling Corti's tunnel. The staining reaction with hæmatoxylin shows a slight loss of differentiation on decolourization. As a result, Corti's organ appears rather more homogenous than normal. The appearance found is shown in Fig. 17. It does not

C. S. Hallpike and H. Cairns

correspond to any fixation artefact obtainable with formaldehyde or to any known stage of post-mortem degeneration. It must therefore be regarded as definite evidence of some ante-mortem degeneration.

The Stria vascularis.—Apart from a somewhat similar type of staining reaction with hæmatoxylin, the stria vascularis shows no recognizable abnormality.

The internal auditory meatus and VIIIth nerve.—The VIIIth nerve has been divided at the neuroglial-neurilemmal junction and has also been torn away at the fundus of the internal auditory meatus. It occupies the upper part of the meatus. The staining of the nerve fibres with hæmatoxylin is rather weak, especially at their central ends where a good deal of disintegration of the myelin sheaths can be recognized. The cells of Scarpa's ganglion show no change apart from the presence of numerous deep red pigment granules. The fundus of the internal auditory meatus contains a mass of red blood cells which have infiltrated the sub-epithelial tissues of the maculae of both saccule and utricle. A few polymorphonuclear leucocytes are to be seen fairly evenly distributed.

The aqueduct of the cochlea.—This is filled throughout its length with a pinkish coagulum containing red cells, endothelial cells, and a few polymorphonuclear leucocytes.

The saccus endolymphaticus.—As in the right temporal bone, there is to be seen a striking absence of the loose perisaccular connective tissue. The epithelium comes into relationship with a dense fibrous tissue inseparable from the surrounding dura mater.

Summary of the Pathological Changes found in the Temporal Bones. Case I

1. Chronic non-suppurative otitis media with thickening of the tympanic membranes in both temporal bones. Bony thickening of the posterior extremity of the left stapes foot-plate, apparently of inflammatory origin.
2. Gross dilatation of the saccule and scala media in the left temporal bone with obliteration of the perilymph spaces of the vestibule and of the scala vestibuli.
3. Degeneration of Corti's organ in the left temporal bone.
4. Absence of the "normal" area of perisaccular connective tissue in both temporal bones.

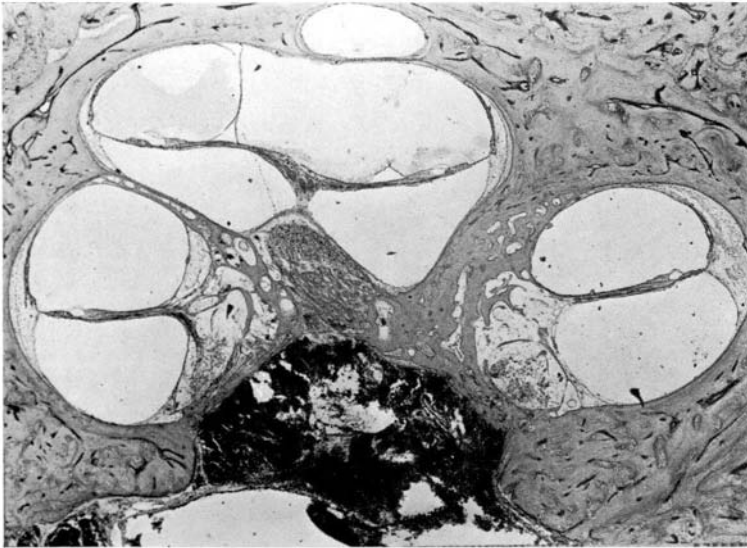


FIG. 13.

Case I. Left temporal bone. The cochlea. Showing the maximal dilatation of the scala media. In the anterior basal whorl the displacement of Reissner's membrane is not complete. The membrane is fixed by newly formed connective tissue.

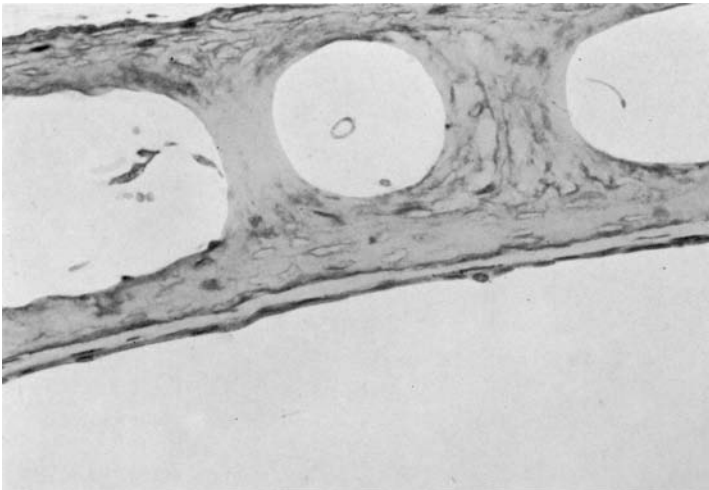


FIG. 14.

Case I. Left temporal bone. Showing a view of the scala vestibuli. Reissner's membrane can be seen flattened against its bony wall.

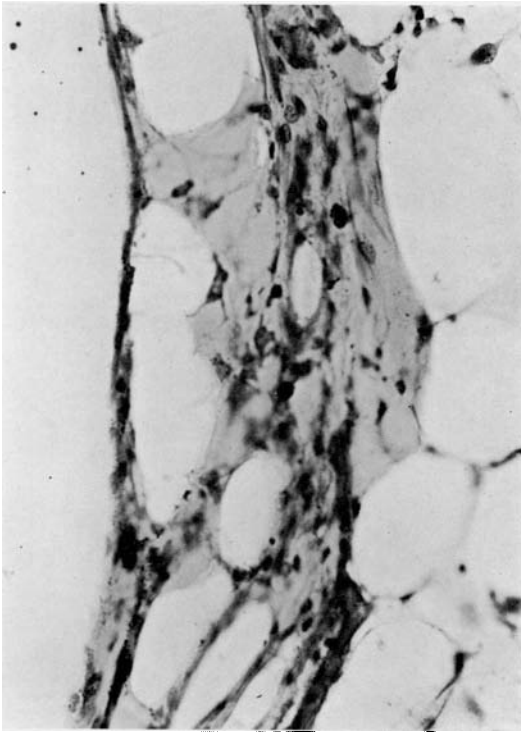


FIG. 15.

Case I. Left temporal bone. Fixation of Reissner's membrane (left) by organizing connective tissue elements.

Pathology of Ménière's Syndrome

CASE II

Clinical History.—J.M., an engineer, aged 28, referred by Professor O'Donovan of Cork, was first seen in November 1936 on account of attacks of vertigo. Apart from the fact that his mother was slightly deaf there was nothing relevant in his family or past history. His attacks of vertigo had begun four years before and, though frequent, had been quite mild until four months before admission when he began to have violent attacks which caused him to give up his work.

The mild attacks occurred on an average about once a week, but were becoming more frequent. There was a feeling of eye-strain, then objects began to quiver, and finally to rotate. During these attacks he found that with practice he could continue to drive a car, but he had a peculiar sensation in the back of the head and a slight tendency to fall in whatever direction he shook his head. During the attack he was unable to read or to walk steadily. He vomited profusely with the first attack but not with others, though he was at times nauseated. The attacks usually passed off within ten minutes, though the first one lasted one and a half hours. Occasionally they wakened him from sleep.

The violent attacks occurred with little or no warning. Objects appeared to whirl rapidly, sometimes clockwise but at other times anti-clockwise, and possibly also in other directions, though he was not sure of this. He usually collapsed to the floor. The violent rotation of objects lasted only a few seconds, but he would remain recumbent for half to one hour, because objects still appeared to move, especially when he opened his eyes, and because of unsteadiness if he tried to walk. He could usually resume his work after one and a half hours. In these attacks he was quite unable to drive a car, and at times did not get enough warning to stop the car if the attack came on while he was driving. These violent attacks occurred on an average of about one a month. He never lost consciousness, nor saw double in an attack.

As a child he had had earache, but he had never had aural discharge. In 1932, at the time of onset of the attacks, he had noticed that the hearing of his left ear was affected, and it gradually got worse, especially after the onset of the violent attacks in June, 1936. With the deafness there was a continuous slight surging noise in his left ear which during the attacks became a ringing noise. A month before he was

C. S. Hallpike and H. Cairns

first seen he began to have ringing noises also in the right ear. Between the attacks he was perfectly well. From June, 1936, he took luminal and bromides regularly and his attacks became less frequent.

Examination.—He was a healthy-looking but rather nervous man, and the only abnormalities found were those connected with hearing and vestibular function. Blood pressure, 134/70. Ocular movements were full and there were nystagmoid jerks to the left. His ear drums were normal. He heard a watch at 6 inches from the left ear and 4 feet from the right. Air conduction was greater than bone conduction. Cold caloric tests produced nystagmus and moderate vertigo on each side after irrigation with cold water for one minute.

Comment.—As this patient had had considerable improvement with 1 gr. of luminal daily, even though he had not been able to return to work, it was decided to continue to treat him with larger doses of this drug, up to 3 grains a day. With this treatment the attacks became much less frequent, and he was able to return to work though not driving a car. But he felt “doped” with the luminal, and he continued to have both mild and violent attacks, one of them in front of a prospective employer. His work was a good deal with machinery. Accordingly, in April, 1937, he returned for operative treatment. Lumbar puncture at this time showed a resting pressure of 145 mm. and normal cerebrospinal fluid. Before operation an audiometric examination was made (Fig. 18) for which we are indebted to Dr. Phyllis Tookey Kerridge.

Operation (April 22nd, 1937).—The left vestibular nerve was divided in the cerebello-pontine angle and the operation presented no unusual difficulty. The posterior part of the foramen magnum was removed at this operation.

Post-operative course.—During the first day after operation the course was satisfactory. There was the usual nystagmus, especially to the right, and tests with Bárány's box in the right ear showed good preservation of hearing in the left ear. During the second night the patient complained of slight headache and was restless, but gave no cause for alarm. On the following morning he suddenly became unconscious and died shortly afterwards while the operation wound was being reopened. This disclosed a moderate amount of blood clot on the posterior aspect of the cerebellum and severe foraminal herniation of the cerebellar tonsils.

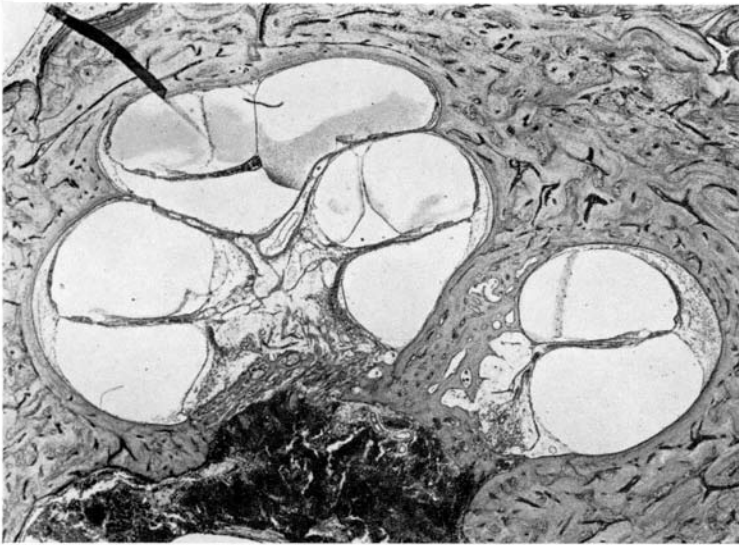

FIG. 16.

Case I. Left temporal bone. Showing the cochlea with the displacement of Reissner's membrane through the helicotrema into the scala tympani.

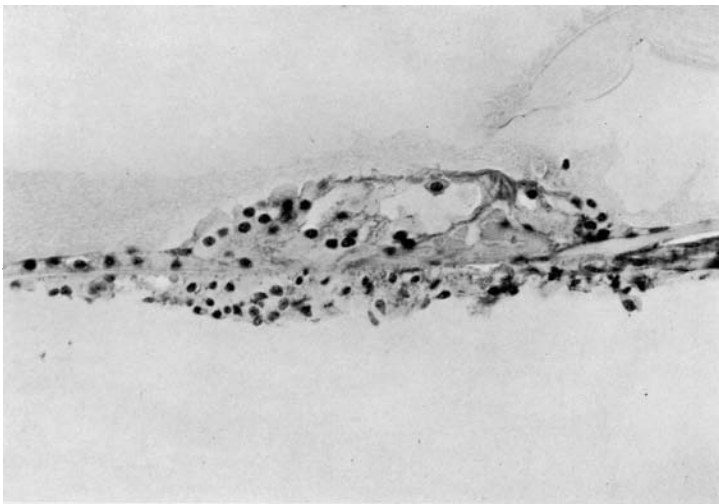
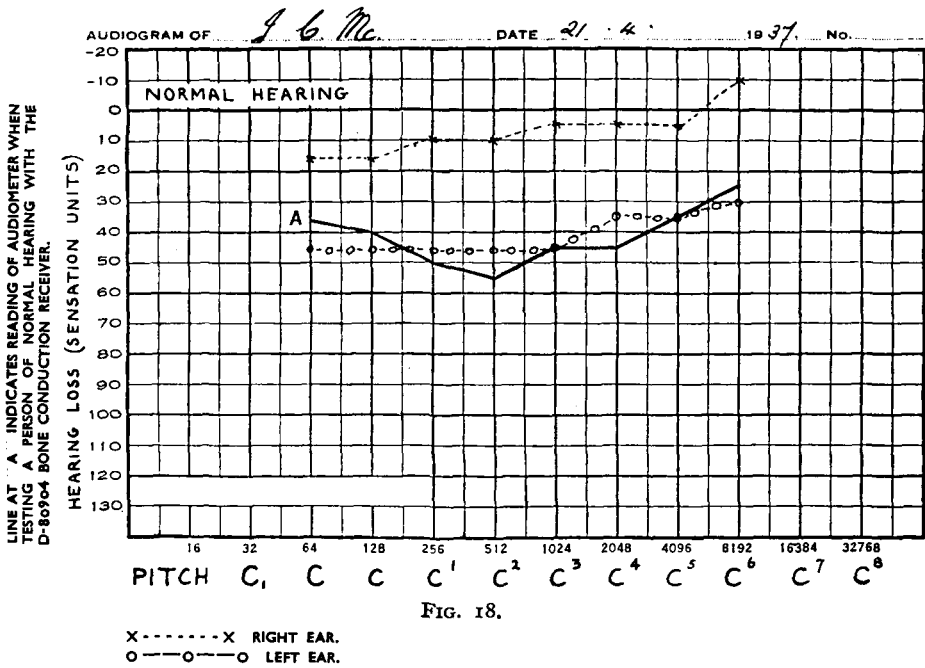


FIG. 17.

Case I. Left temporal bone. Corti's organ, showing degenerative changes.

Pathology of Ménière's Syndrome

Autopsy, four hours after death, limited to the head, showed considerable congestion of the leptomeninges and a softened lacerated hæmorrhagic zone, measuring $3.5 \times 3.0 \times 4$ cm., in the posterior aspect of the left lateral lobe of the cerebellum. The cisterns around the medulla oblongata were filled with blood clot.



PATHOLOGICAL REPORT

The left temporal bone only was received at the Ferens Institute on May 24th, 1937, in 4 per cent. solution of formaldehyde in which it had been preserved since the post-mortem examination which was carried out on April 24th, 1937, four hours after death. The dura mater had been stripped from the posterior aspect of the bone. No other macroscopic defect was to be observed. The bone was completely decalcified under control by X-rays in 1 per cent. nitric acid in distilled water. It was embedded in celloidin and serial sections were cut in the horizontal plane at a thickness of 25μ . Every tenth section was stained with Ehrlich's hæmatoxylin and counter-stained with a mixture of Biebrich scarlet and eosin.

C. S. Hallpike and H. Cairns

Histological Findings

Pneumatization.—There is a well marked development of the air cell system around the antrum but not in the region anterior to the cochlea. The bone here is dense, with small inter-trabecular spaces containing red marrow. The mucosa lining the air cells is normal apart from a slight degree of fibrosis in the sub-mucosa and a conspicuous engorgement of the blood vessels. This is also seen in the vessels of the marrow spaces.

Labyrinth capsule.—This shows no abnormality. The fissula ante fenestram is present and well developed. There is also a well marked fissula post fenestram.

External auditory meatus.—Normal.

Tympanum.—The tympanic membrane and the middle-ear cavity are normal, apart from a marked engorgement of the vessels in the mucosa over the promontory and elsewhere.

The vestibule.—There is a gross dilatation of the endolymph spaces, in particular of the saccule. At the level of the stapes footplate the saccule extends around the lateral aspect of the utricle to enclose it on its posterior aspect and extends into the inner extremity of the lateral semi-circular canal. The perilymph cistern has been obliterated.

The opening of the saccule into the ductus endolymphaticus contains a dense reddish staining coagulum. The communications of the utricle and saccule with the ductus endolymphaticus are clearly observable and the utricular fold shows no displacement.

The condition of the pneumatic cell system, the tympanum, and of the endolymph spaces within the vestibule are shown in Fig. 19.

The vestibular sense organs.—In both the saccule and utricle, elevation of the otolith membrane has occurred. This is of very advanced degree in the utricle. Fig. 20. The macular epithelium shows a well marked abnormality in its staining reaction. Both cytoplasm and nuclei show an increased retention of the hæmatoxylin. Very little differentiation by acid is possible, either of the chromatin granules within the nuclei, or between the nuclei as a whole and the surrounding cytoplasm.

The semi-circular canals.—The epithelium of the cristae shows well-marked pathological changes of the type described in the case of the macular epithelium, though more marked in

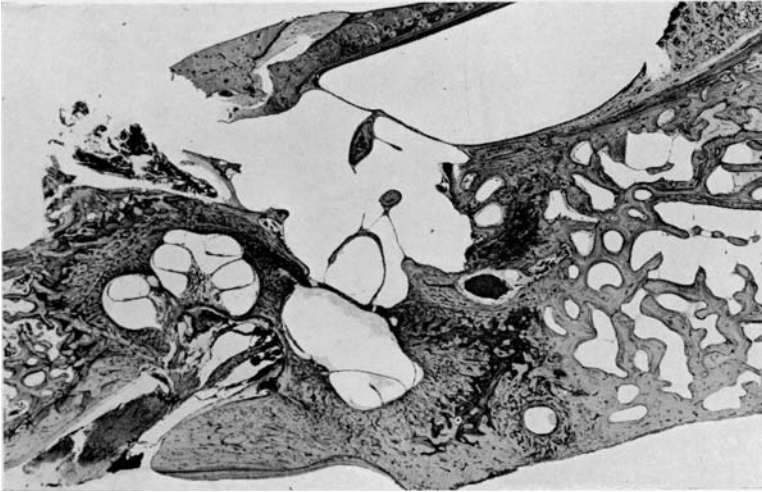

FIG. 19.

Case II. Low power view showing normal condition of the tympanum. There is also extensive development of the air spaces round the antrum. There is also gross dilatation of the scala media in the cochlea with the apparent disappearance of Reissner's membrane. In the vestibule the sacculle is similarly dilated and the perilymph cistern has been obliterated.

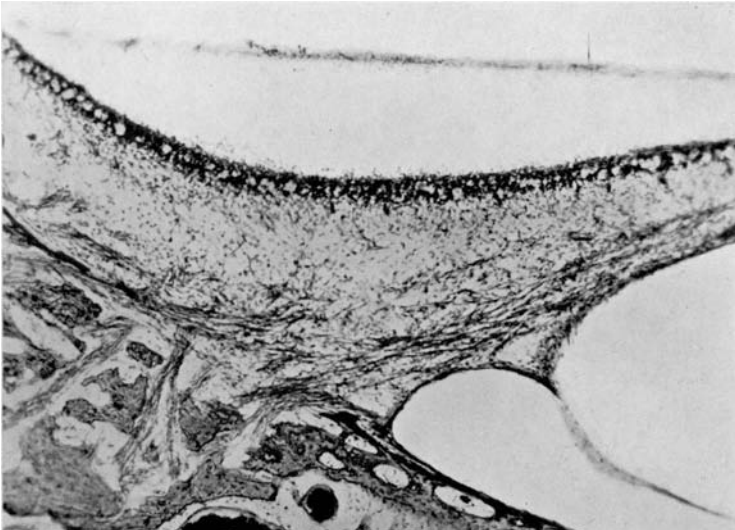


FIG. 20.

Case II. Macula Utriculi, showing gross elevation of the otolith membrane, with degeneration of the sensory epithelium.

Pathology of Ménière's Syndrome

degree. Fig. 21. The epithelium is converted into a deeply stained ill-differentiated mass of nuclei cytoplasm and keratin filaments. There is a marked engorgement of the vessels in the connective tissue framework. It should be noted however that a similar engorgement has been described in the vessels of the tympanic mucosa and of the bone marrow. It is thus probable that this feature is part of a generalized terminal condition and is therefore without pathological significance.

The lateral canal shows a very marked formation of sub-epithelial vesicles. Fig. 22. The internal limb of the anterior vertical canal contains a very dense coagulum which retains the hæmatoxylin stain and gives a positive reaction to Gram's stain for fibrin. Fig. 23A. Fig. 23B shows the same canal 75μ lower. Here the canal wall has ruptured and has become converted, evidently by some degenerative process, into a strongly hæmatoxyphil fibrillated substance.

The cochlea.—Gross dilatation of the scala media has occurred with displacement of Reissner's membrane on to the wall of the scala vestibuli. At the apex of the cochlea Reissner's membrane has become bulged through the helicotrema into the apical portion of the scala tympani. These changes are shown in Fig. 24.

Corti's organ.—A high power view of Corti's organ is shown in Fig. 25. Corti's tunnel is well defined and crossing it can be seen a faint outline of the characteristic nerve filament. There is a marked abnormality of the staining reaction of Corti's organ throughout the cochlea. Differentiation of the hæmatoxylin stain is practically impossible. That is to say that selective retention of the stain by the nuclei and certain other elements after treatment with acid is abolished. Little nuclear structure can be made out and the degree of hæmatoxylin retention as a whole shows a marked increase. The result is a relatively homogeneous darkly staining mass. The condition corresponds to no fixation artefact obtainable with formaldehyde, or to any stage of post-mortem degeneration, and is therefore regarded as definite indication of intravital degeneration.

The stria vascularis.—This shows conspicuous abnormalities in all whorls of the cochlea. The covering layer of flat epithelial cells is intact. As in Corti's organ, there is a marked increase of hæmatoxylin retention with loss of differentiation

C. S. Hallpike and H. Cairns

both in the epithelium and in the deeper layers of the stria. In a few places the intercellular spaces in the deeper layers of the stria are filled with a structureless reddish staining coagulum. This condition is shown in Fig. 26A. Fig. 26B shows the structure and staining reaction of the stria which is found in normal human material fixed and stained in a comparable manner.

The internal auditory meatus and VIIIth nerve.—The VIIIth nerve has been divided through its neurilemmal portion. The staining reaction of its fibres with hæmatoxylin shows no abnormality except in the region which adjoins the point of section. The staining here is very weak and a good deal of disintegration of the myelin sheaths can be made out.

The cells of Scarpa's ganglion appear to be of normal number. In about 50 per cent. of these cells early degenerative changes have occurred. The cell outlines have faded. The granules in the cytoplasm which in the normal human subject show so striking an affinity for the Biebrich scarlet counterstain are either absent or much reduced in size and number. The nuclei are pyknotic with a very conspicuous crenation of their edges.

Large masses of red cells occupy the spaces around the nerve trunk and between its constituent bundles. These masses are particularly dense at the fundus of the meatus. A few polymorphonuclear cells are present and are evenly distributed throughout the area.

The aqueduct of the cochlea.—This is occupied throughout its length by dense masses of red cells with a few scattered small lymphocytes and polymorphonuclear leucocytes. None of these cells is to be seen in the scala tympani adjoining the opening of the aqueduct. The perilymph space here contains a large amount of dense albuminoid coagulum.

The ductus and saccus endolymphaticus.—The ductus is patent and shows no abnormality. The pars distalis of the saccus has been distorted by the removal of the overlying dura mater. Its lumen contains some epithelial débris and a few red cells. The most noteworthy feature is the absence of the "normal" area of loose connective tissue between the saccus wall and the surrounding area. A few red cells can be seen in the meshes of the fibrous tissue deep to the epithelium. Evidence of an inflammatory process is however absent. The condition of the saccus is shown in Fig. 27.

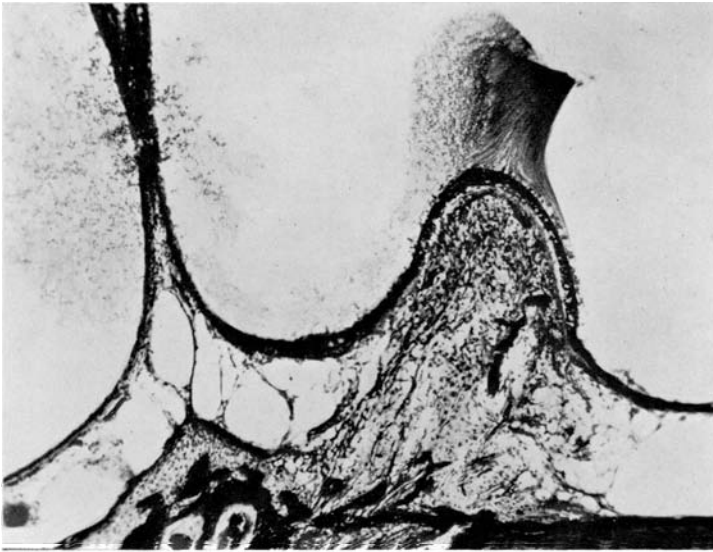

FIG. 21a.

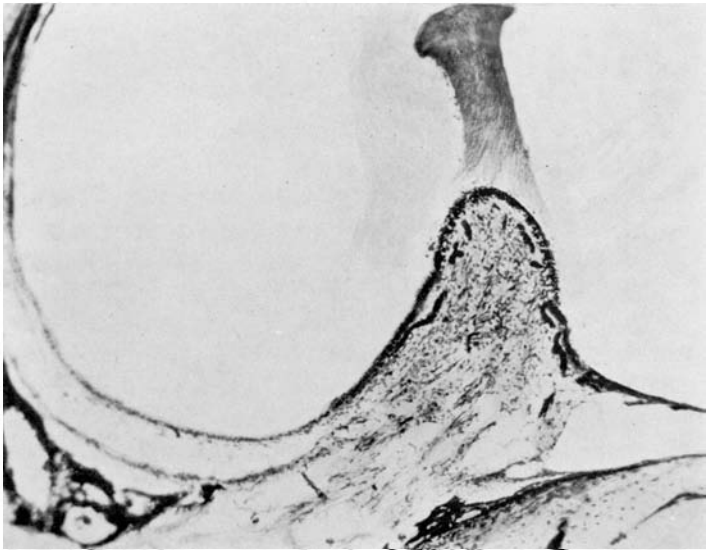


FIG. 21b.

Case II. Cristae of the posterior (*a*) and lateral (*b*) semicircular canals showing albuminoid coagulum upon the cupulae and vascular engorgement, with degeneration of the sensory epithelium.

Pathology of Ménière's Syndrome

Summary of the Pathological Changes found in the Left Temporal Bone. Case II

1. Gross dilatation of the saccule and scala media with obliteration of the perilymph cistern and of the scala vestibuli.
2. Degeneration and rupture of the wall of the anterior vertical membranous canal, associated with the presence within its lumen of dense albuminoid coagulum.
3. Degeneration of Corti's organ.
4. Degeneration of the epithelium of the maculae and of the cristae of the semi-circular canals.
5. Degeneration of the stria vascularis.
6. Absence of the "normal" area of perisaccular connective tissue around the saccus endolymphaticus.

Discussion

The data now at our disposal invite enquiry from two points of view. There is required in the first place a reconstruction of the natural history of the morbid anatomical changes which have been described, and in the second place an explanation in terms of these changes of the clinical features of the disease.

I.—The development of the pathological changes.

The pathological changes in the affected temporal bones of the two cases may be summarized as follows :

There is a gross dilatation of the endolymph system which affects chiefly the scala media of the cochlea and the saccule. Degenerative changes are present in Corti's organ in both cases and in the stria vascularis in the second case only. Scattered albuminoid coagula are present throughout the endolymph spaces. This coagulum is particularly dense in the anterior vertical canal of the second case, and at one point degeneration and rupture of the canal wall has occurred.

In very general terms such changes correspond to those described by Witmaack¹² as representing the reaction of the labyrinth to damage from bacterial or other toxins reaching it through the round window or via the blood stream. To this reaction, commonly known as serous labyrinthitis, he has given the name of "hydrops labyrinthi" ; and in the present instance it might be justifiable to describe the tissue changes as representing such a serous labyrinthitis, in the first case in response

C. S. Hallpike and H. Cairns

to toxins passing through the round window membrane, and in the second case to toxins reaching the internal ear via the blood stream from some unspecified focus of infection, in accordance with the view of Wright².

While no decisive objection can be made to this interpretation, it is necessary to emphasize that such extreme and uniform dilatation of the endolymph system is extremely rare in serous labyrinthitis, and secondly, that while the histological changes in Corti's organ revealed in the present cases may represent some undescribed stage of serous labyrinthitis, they do not present those features which are described by Witmaack and others as being most typical of this condition, a characteristic example of which occurs in Fig. 28.

This shows the organ of Corti in a cat, with the changes typical of a moderate grade of serous labyrinthitis. The hair cells have mostly disappeared. There is a fading of the intercellular boundaries and the cell protoplasm presents a stippled appearance, possibly due to small fluid containing vacuoles.

It must further be considered that some at least of the tissue changes must be regarded as representing a reaction of the labyrinth to the operative interference and the resulting meningeal reaction. In particular should be mentioned the albuminoid coagulum in the scala tympani adjoining the opening of the cochlear aqueduct, as well as the collections of leucocytes in this region and in the lumen of the duct itself.

It is however unlikely that such an explanation can be extended to other of the changes, notably the dilatation of the endolymph system. This view has been controlled by an examination of the temporal bones in five cases of VIIIth nerve tumour in which death occurred a few days after operative removal. (The histological preparations and clinical histories of two of these cases were kindly placed at our disposal by Mr. Philip Scott to whom our thanks are due.) In all of these, considerable collections of red cells were found in the fundus of the internal auditory meatus with scattered polymorphonuclear leucocytes. In all there was a well marked serous labyrinthitis with albuminoid coagulum in the perilymph spaces. This was less marked in the endolymph spaces, and nowhere so dense as that described in the second of the present two cases in association with rupture of the wall of the anterior vertical canal. In all the cases Corti's organ and the stria

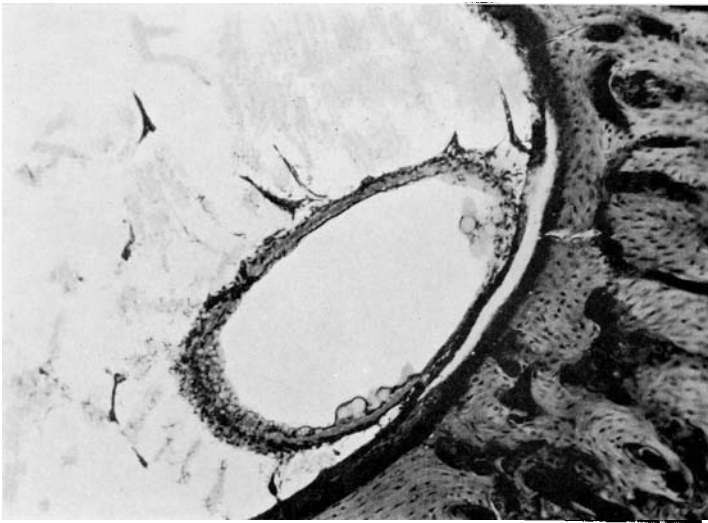


FIG. 22.

Case II. Lateral semicircular canal showing sub-epithelial vesiculation
and albuminoid coagulum in the perilymph space.

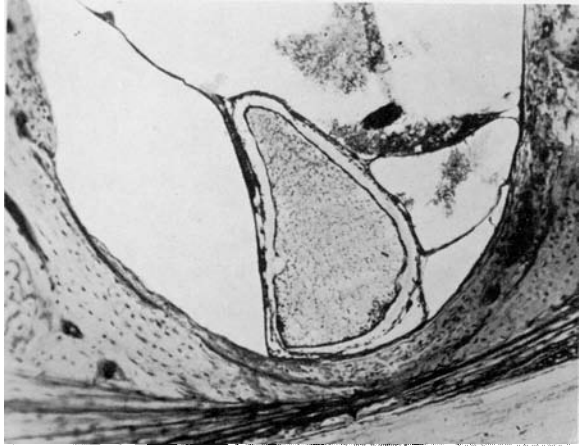


FIG. 23a.

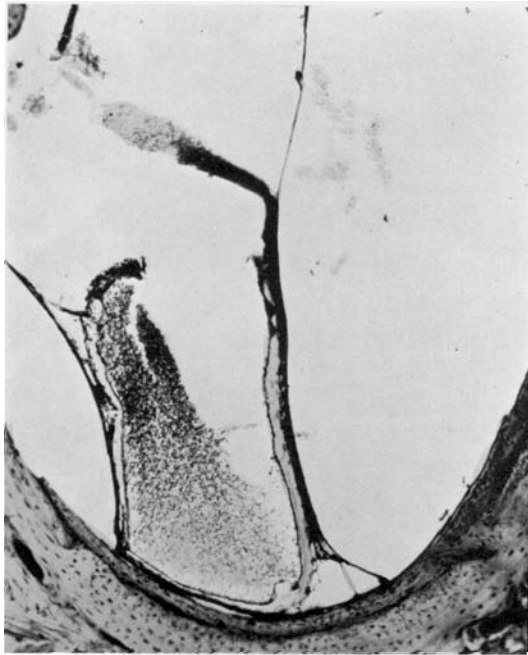

FIG. 23b.

Case II. Showing the inner limb of the anterior vertical canal. The membranous canal contains dense albuminoid coagulum.

b shows a section at a level of 75μ lower than that of *a*. Degeneration and rupture of the canal wall has occurred.

Pathology of Ménière's Syndrome

vascularis showed no change apart from post-mortem degeneration. In two of the cases some dilatation of the endolymph system was present, confined to the scala media of the cochlea and characterized by a relatively insignificant displacement of Reissner's membrane. The much greater degree and extent of the dilatation of the endolymph system in the present cases, associated, as it was in places, with fixation of Reissner's membrane by organized tissue elements, appear to exclude the possibility of the changes being the result of an acute reaction to operative interference.

The available evidence must therefore be regarded as opposing the view that the tissue changes described are attributable to a reaction of the labyrinth, either to operative interference or to an affection of longer standing by bacteria or their toxins, and additional emphasis must accordingly be thrown upon the condition found in and around the saccus endolymphaticus in all of the three temporal bones which have been examined. It will be recalled that in all of these the soft perisaccular connective tissue, identified by Guild as the normal absorption area of the endolymph, was found to be absent. It might well be that the general dilatation of the endolymph system in these cases was due to hypersecretion and had led to the obliteration by pressure of the soft perisaccular tissue. But this seems to be rendered unlikely by the fact that in the unaffected ear of the first case the same absence of this perisaccular tissue is to be seen. The suggestion is therefore made that the endolymphatic dilatation in these cases is due, at any rate in part, to some failure in the normal absorptive mechanism; and that morphological evidence of this failure is provided by the absence from these cases of the normal absorption area of perisaccular connective tissue.

It should however be clearly emphasized that a similar absence of this connective tissue was found in two of the thirteen normal cases examined, and that it is impossible upon the basis of this material alone to regard this anatomical condition as more than a normal variation which acts as a predisposing factor in bringing about the dilatation of the endolymph system.

The primary change may still be either an increased production of the endolymph itself, or else some inscrutable type of alteration in its physico-chemical constitution as suggested by Crowe. It is clear for instance that a continued

C. S. Hallpike and H. Cairns

secretion of endolymph of an abnormally high ionic concentration might well lead to such a dilatation of the endolymph system by osmotic attraction of water molecules through its membranous walls from the surrounding perilymph. One feature of the endolymphatic dilatation remains to be considered in greater detail, namely, the relative immunity of the utricle to the process of dilatation which is so strikingly completed in the case of the saccule. Obstruction to the entry of the endolymph is excluded as an explanation by the finding of normal conditions of communication between the utricle and the ductus endolymphaticus. An alternative explanation might obviously be sought in a relatively greater rigidity of the utricular wall.

Although Retzius¹³ gives a very full description of the form and position of the human utricle and saccule, no details are provided concerning the relative thickness of their walls. Further evidence upon this question has been provided by a study of three transparencies of the human labyrinth which were prepared and kindly placed at our disposal by Mr. E. W. Peet. Stereoscopic examination of these specimens with a low power dissecting microscope under a dark ground illumination shows considerable differences in the apparent thickness of the walls of the utricle and saccule. The utricular wall, particularly in its upper part, possesses a conspicuously greater density.

Examination of normal temporal bones confirms this impression. Three series of horizontal sections cut at 25μ thickness were examined. Considerable possibility of artefact may obviously be brought about by the obliquity in sections of this thickness of the membranes in question, but this would appear to be excluded by the finding that the *average* thickness of the utricular walls was about two to three times greater than that of the saccular walls. This conclusion was arrived at by assessing by eye the average difference of the thickness of the utricular and saccular walls in each of the sections in turn. In 70 per cent. of the sections the ratio in favour of the utricular wall varied between two and three to one. In the remaining 30 per cent., the utricular and saccular walls were of comparable thickness. These results may therefore be taken as providing a satisfactory explanation of the relatively greater dilatation of the saccule in the affected labyrinths in the two cases under present discussion.

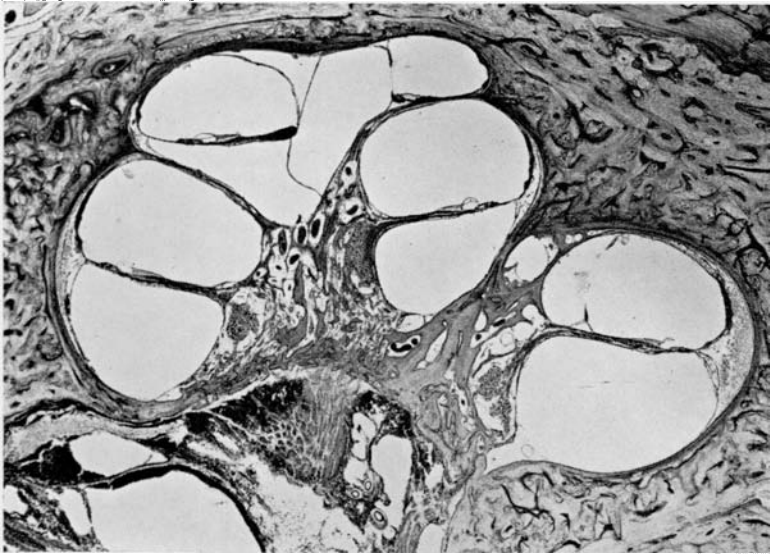

FIG. 24.

Case II. The cochlea. Gross dilatation of the scala media has occurred with displacement of Reissner's membrane on to the wall of the scala vestibuli. At the apex, Reissner's membrane has been displaced through the helicotrema into the scala tympani.

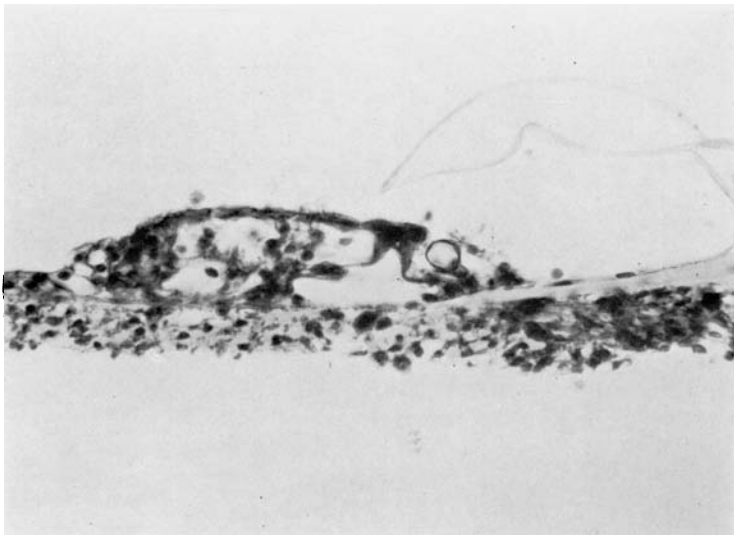


FIG. 25.

Case II. Organ of Corti, showing degenerative changes.

[face p. 646

Pathology of Ménière's Syndrome

II.—The relationship of the pathological changes to the clinical condition.

From the purely clinical point of view the most interesting speculation must be to explain in terms of the anatomical changes the most salient feature of the disease, namely paroxysmal disorder of labyrinthine function.

Fig. 29A shows a diagram of the normal labyrinth. The membranous labyrinth is a closed fluid system and the mechanism for the secretion and absorption of the fluid is resident within its walls. Surrounding it is the perilymph, which reaches the perilymph spaces via the aqueduct of the cochlea from the relatively enormous cisterns of the cerebrospinal subarachnoid space. In this fluid system it is clear that any volume increase in the endolymph will be met by an expansion of its thin and elastic membranes and by the expulsion through the helicotrema and cochlear aqueduct of a corresponding volume of perilymph. The resulting pressure change in the fluid system as a whole will be equivalent to that following the injection of a fraction of a c.c. of fluid into the spinal theca, that is to say, negligible.

A simplified representation of such a fluid system is provided by the smaller diagram of a rigid walled narrow-necked vessel containing fluid. Within it is an elastic walled balloon containing a separate fluid. A volume increase of the fluid within the balloon could clearly only lead to the ejection along the bottle neck of a corresponding amount of the surrounding fluid with little change of pressure in the system. If however the endolymph system becomes fully dilated, then a very different state of affairs is brought about. The elastic membranes are everywhere brought into contact with the rigid bony walls except at the helicotrema. At this point Reissner's membrane is stretched and bulges into the scala tympani and in this relatively limited space represents the sole area of elastic expansion which now remains. This condition is represented by Fig. 29B. Here the balloon has become expanded to fill the bottle and the last remaining area for elastic expansion is the relatively limited area in the bottle neck itself. It is easy to see from this that the pressure change resulting from any sudden increase in volume of the fluid within the balloon would be very considerable, and would in fact be reproduced approximately by the injection into an already filled rigid vessel of an infinitesimal quantity of fluid. In other words,

C. S. Hallpike and H. Cairns

once the dilatation of the endolymph system has attained its maximal degree, then the fluid system of the membranous labyrinth, from being insensitive, becomes at once extremely sensitive in its pressure response to a given volume increase of the endolymph.

In this way it seems possible to explain the attacks as being due to rapidly initiated bouts of asphyxia of the labyrinthine end-organs, brought about by extremely rapid rises of fluid pressure, in response to relatively very small volume increases in the endolymph. Upon the basis of this hypothesis it is supposed that there exists a chronic condition of lowered function of the affected labyrinth due to increased endolymph pressure and resulting anoxæmia of its end-organs. This condition fluctuates in a manner typical of the clinical course of the disease, and may proceed during the course of the attack to complete paralysis of the affected labyrinth. In the chronic state between the attacks, and particularly during the days preceding an attack, there may exist a state of chronic unsteadiness which is much aggravated by sudden movements of the head. In accordance with the well established principle that vertigo in unilateral labyrinthine disease nearly always originates from excitation of the more active labyrinth, this condition would be explained by stating that such head movements evoke a greater response from the sound labyrinth and bring about vertigo by the relative absence of a corresponding response from the affected labyrinth. In such a patient it might well be that the caloric reaction would be grossly defective in the affected ear.

Relief from this condition might clearly be obtained by progress of the disease to complete death of the labyrinth followed by the usual process of central compensation. This however occurs relatively seldom, and the condition which is typically encountered might be described as a chronic relapsing state of lowered function of the affected labyrinth. Similar relief might alternatively be obtained by surgical exenteration of the labyrinth or by section of the VIIIth nerve.

It should be noted that Crowe³ adopts a different view of the functional state of the affected labyrinth which he considers to be strongly excited in the course of the typical attacks. An obvious objection to this view is that such cases may show marked deficiency or even absence of the caloric action. This objection Crowe meets by suggesting that the stimulus

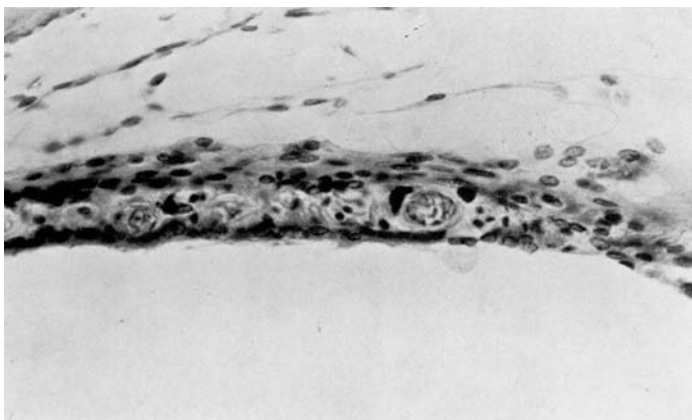


FIG. 26*b*.

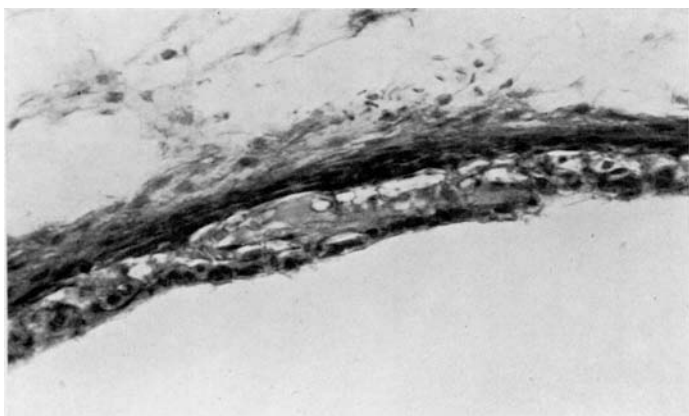


FIG. 26*a*.

Case II. *a* shows the stria vascularis with gross degenerative changes. *b* shows the normal structure of the stria vascularis under comparable conditions of age, fixation, and staining.

Pathology of Ménière's Syndrome

which is responsible for the attacks is even stronger than that involved in the caloric reaction, a suggestion which is however difficult to accept in the absence of any information regarding the nature of the supposed stimulus.

Crowe further explains the sensitivity of these patients to rotation by stating that their reaction to this test, and not to the caloric test, is due to the stronger stimulus provided by the former. It would, we consider, appear unjustifiable to describe the stimulus provided by a relatively long-continued endolymph movement, such as occurs in the caloric reaction, as being physiologically weaker than the more natural stimulus provided by rotation, or indeed to attempt any such comparison. The view should in our opinion be preferred that in the rotation test equal stimuli are applied simultaneously to both labyrinths and so expose a condition of imbalance due to lowered function upon the affected side. These patients are more sensitive to this test than to the caloric test, since in the latter the stimulus is applied to one labyrinth at a time and involves no such exposure of their imbalance.

If, finally, for the sake of argument, it were to be assumed that increased endolymph pressure is the stimulating factor postulated by Crowe, it is difficult to understand how this could act upon the end-organs of the semi-circular canals, since the cupular displacements which are required for their excitation could not be brought about by a simple and evenly distributed increase of endolymph pressure.

For these reasons it is considered that Crowe's hypothesis has less in its favour than that which has now been put forward, namely that the symptoms of labyrinthine disorder are due to a lowered functional state of the affected labyrinth due to anoxæmia of its end-organs induced by a raised pressure of its endolymph.

This explanation of the mechanism of the characteristic attacks involves certain assumptions. In the first place it must be believed that the secretory pressure of the endolymph may attain a level which would materially curtail the vascular supply of the labyrinthine end-organs. This belief would be compatible with the high pressure levels which are known to be attainable by other secretions, notably the saliva.

In the second place it is necessary to suppose that a certain pressure level which is sufficient to bring about an anoxæmia of the labyrinthine end-organs, and so precipitate an attack, is

C. S. Hallpike and H. Cairns

nevertheless insufficient to interfere, at any rate for short periods, with the secretory activity of the stria vascularis itself which is primarily responsible for inducing and sustaining this pressure level. This supposition might be taken as representing a difference in sensitivity to a given degree of anoxæmia between the stria vascularis and the labyrinthine end-organs; but an alternative explanation appears to be provided by certain morphological differences in the vascular supply of these structures.

The maculae and cristae are supported by a soft connective tissue framework with a fairly rich capillary network which is closely related to the overlying epithelium.¹⁴ A different condition is found in the stria vascularis, the deeper layers of which are notable for the presence of numerous small arterioles. More recently, the course and structure of these arterioles have been studied in greater detail by Belemer.¹⁵ The vessels pass from the modiolus across the roof of the scala vestibuli and enter the stria at its upper border. Thereafter they pursue a course of varying obliquity through the stria, to emerge once more from its lower border into the substance of the spiral ligament.

Belemer duly emphasizes the remarkable character of an anatomical arrangement whereby arterioles entering a capillary field so small and well-defined as the stria vascularis should also leave it with their form substantially unchanged. He makes the suggestion that the arterioles, by variation in their calibre, may influence the tension of the basilar membrane, and supports this suggestion with his observation of a particular relationship of the emerging arterioles to the oblique fibres of the spiral ligament. With this suggestion we are less concerned than with the demonstrated existence of numerous arterioles within the stria, the maintenance of their calibre in their passage through the stria, and finally their necessarily intimate relationship to its secretory elements.

These facts appear to necessitate the belief that the capillary supply from the arterioles to the secretory elements is delivered at a particularly short range and consequently at a particularly high pressure, an arrangement which would clearly confer upon the stria vascularis a peculiar competence to maintain its secretory function under conditions of increased pressure in the surrounding fluids.

Upon this basis it would be possible to explain the difference,

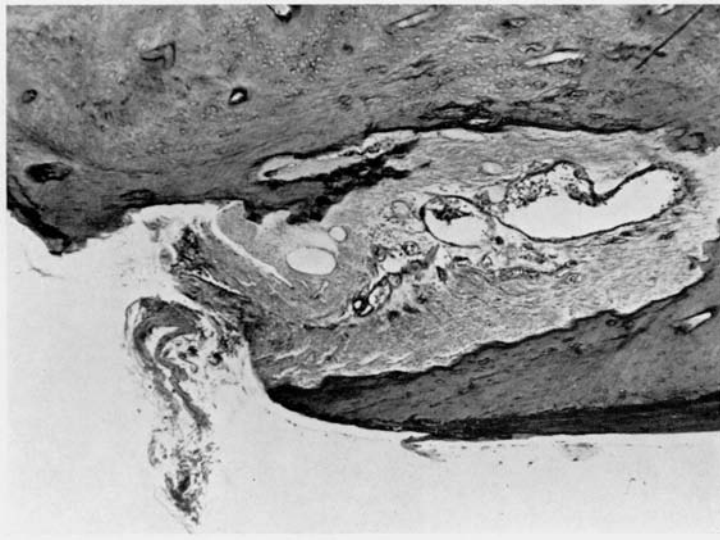


FIG. 27.

Case II. Saccus endolymphaticus showing the absence of the normal perisaccular connective tissue.

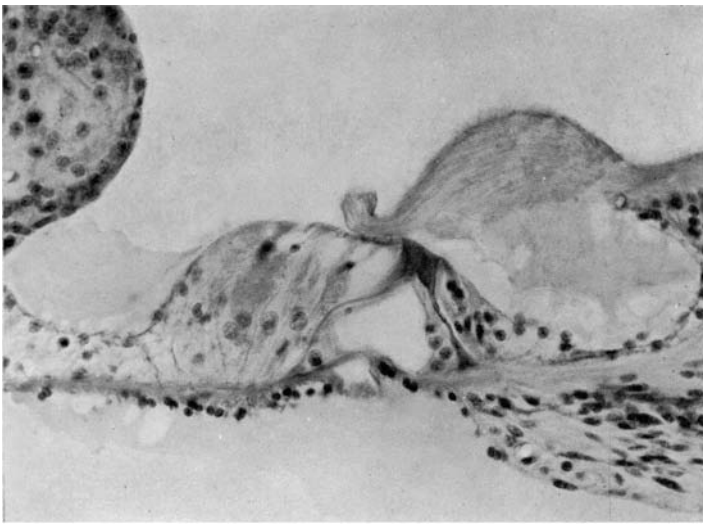

FIG. 28.

Organ of Corti in a cat showing the changes typical of a moderate degree of serous labyrinthitis.

[face p. 650

Pathology of Ménière's Syndrome

during a typical attack of vertigo, between the functional impairment of the vestibular end-organs and of the secretory elements of the stria vascularis as being due, not as first suggested, to a difference in sensitivity to the same degree of anoxæmia induced by a given rise of endolymph pressure, but to a difference in the degrees of anoxæmia so produced in these two sets of structures. This difference would be settled in favour of the stria vascularis by those peculiarities in its vascular supply to which attention has been drawn.

In connection with the impairment of cochlear function which constitutes one of the clinical features of the disease, certain questions arise which can at present be dealt with only in a comparatively speculative manner. This impairment of function might clearly be explained in terms of increased endolymph pressure by postulating either an anoxæmia of the sensory elements or some mechanical interference, either with the structure of the sensory cells, or with the vibrating system as a whole. It may be recalled, with regard to the first possibility, that Kolmer¹⁶ and others have already pointed out the absence of demonstrable capillaries in the organ of Corti itself and have indicated the quite logical conclusion that the tissue respiration of Corti's organ may be conducted through the medium of the endolymph. Crowe³ has recently emphasized this important possibility. Upon this basis it may be supposed that increased endolymph pressure, at least in its earlier stages, would not alone lead to anoxæmia of Corti's organ, in view of the maintenance of the partial pressure of oxygen which would result, and it would therefore be necessary to suppose that some additional change in the quality of the endolymph occurs.

Explanation upon a mechanical basis of the impairment of hearing brought about by increased endolymph pressure is even more confined to speculation. It is clearly permissible to envisage some degree of structural disintegration by pressure of the sensory elements of Corti's organ, though its exact nature and extent cannot well be estimated.

Alternatively, an increased impedance in the vibratory mechanism as a whole may result. The moving parts of the cochlea which are principally involved in hearing are the basilar membrane and the structures which occupy the round and oval windows. In the present instance, the round window membrane would be unaffected by the dilatation of the

C. S. Hallpike and H. Cairns

endolymph system and may therefore be omitted from the argument. The other two structures are exposed to the increase of pressure and would be correspondingly stretched. Whether or not such stretching would be attended by an increased mechanical impedance would depend upon the elastic qualities of the structures in question. In elastic bodies of a certain quality equal increments of tension may lead to equal increments in length over a wide range ; and if this were true in the case of the basilar membrane and annular ligament of the oval window within the possible range of endolymph pressure, then stretching of these structures within these limits would not be attended by any increase in their mechanical impedance. It would not in these circumstances be necessary to anticipate that endolymph hypertension would of necessity bring about a conduction type of deafness.

It might well be expected however that a generalized stretching of the basilar membrane would lead to a change in the natural frequency of its components ; and it follows that suitably designed clinical observation of patients in the less acute stages of a typical attack might lead to information of importance regarding the resonance hypothesis. That is to say, by the recognition in these cases of a systematized type of " paracusis dysharmonica ".

With regard to tinnitus, it cannot be said that the anatomical changes found in the present cases provide any new evidence which bears either upon its mode of origin or upon the well known but puzzling fact that following section of the entire VIIIth nerve cessation of the tinnitus occurs in only a proportion of cases, although relief from the vestibular symptoms is the almost invariable rule. It is true that excitation of the cochlear end-organs might be expected to result from the degenerative changes which have been described in Corti's organ. This explanation cannot however be accepted without question. In end-organs of this type which are designed to respond to rapid and intermittent stimulation, the process of adaptation is extremely rapid. It might thus be argued that a degenerative process of the type described would bring about a more constant type of stimulation, and one which on this account would be particularly incompetent to excite the rapidly adapting receptors of Corti's organ.

With regard to the persistence of the tinnitus after section of the VIIIth nerve which is known to occur in a considerable

Pathology of Ménière's Syndrome

proportion of cases, it is only possible to attribute this to the development of certain obscure changes in the central cochlear neurones, similar in nature to those which may be responsible for painful phantom limb and other sensations of central origin.

It is of interest finally to note that under the abnormal conditions of fluid pressure which are indicated by the anatomical findings in the present two cases, there would necessarily occur a marked increase in the sensitivity of the internal ear to displacements of the stapes footplate resulting either from Eustachian obstruction or impaction of wax upon the tympanic membrane. Under normal conditions such displacements would lead to the expulsion of corresponding amounts of perilymph through the aqueduct of the cochlea with negligible rises of pressure in the fluid system as a whole. In the presence of a maximal dilatation of the endolymph system, such an escape of perilymph would be impossible, and a considerable rise of pressure in the endolymph system would thus occur. It is equally clear that this situation would be open to dramatic alteration by removal of the wax or by Eustachian inflation.

Although such clinical experiences compel the recognition that these and other tympanic abnormalities may precipitate the paroxysms so characteristic of the disease, the possibility clearly exists that they might further be interpreted as indicating the existence of some primary condition within the labyrinth which has rendered it vulnerable to such abnormalities; and that finally, the nature and mechanism of this primary condition may be related to that which has now been described.

SUMMARY

Attention is drawn to recent publications by Wright and Crowe on the clinical aspects of Ménière's syndrome. In these, the opinion is expressed that a considerable proportion of patients exhibiting this syndrome are the victims of a common type of disorder of the internal ear.

Evidence in support of this view is provided by the present paper in which are described the histological changes in the temporal bones of two such patients. In each of these, the affected temporal bone showed a gross distension of the endolymph system together with degenerative changes in the sensory elements. A possible explanation of this distention is

C. S. Hallpike and H. Cairns

suggested by the finding in both cases of certain changes around the saccus endolymphaticus.

A possible mechanism is further suggested whereby the histological changes may be correlated with the clinical features of the disease.

This investigation was assisted by a grant from the Medical Research Council to whom acknowledgment is made. Our thanks are also due to Mr. F. J. Cleminson for valuable discussion.

REFERENCES

- ¹ WATKYN-THOMAS, F. W. and LOWNDES YATES, A., *The principles and practice of Otolaryngology*, 1932, 510. Lewis & Co., London.
- ² WRIGHT, A. J., *J. Laryng. and Otol.*, 1938, liii, 97.
- ³ CROWE, S. J., *Medicine*, 1938, xvii, 1.
- ⁴ DANDY, W. E., *Amer. J. Surg.*, 1933, xx, 693.
- ⁵ WITMAACK, K., *Arch. f. Ohrenheilk.*, 1929, cxxiv, 176.
- ⁶ VIDEBECH, H., *Acta-Oto-laryngol.*, 1932, xxii, 51.
- ⁷ ECKERT-MÖBIUS, A., *Henke-Lubarsch. Handbook of Pathology*, 1926, xii, 89.
- ⁸ GUILD, S. R., *Amer. J. Anat.*, 1927, xxxix, 1.
- ⁹ ANSON, B. J. and NESSELROD, J. P., *Arch. Otolaryngol.*, 1936, xxiv, 127.
- ¹⁰ GUILD, S. R., *Amer. J. Anat.*, 1927, xxxix, 57.
- ¹¹ BAST, T. H., *Anat. Rec.*, 1928, xl, 61.
- ¹² WITMAACK, K., *Henke-Lubarsch. Handbook of Pathology*, 1926, xii, 290.
- ¹³ RETZIUS, G., *Das Gehörorgan der Wirbelthiere*, 1884, ii, 336.
- ¹⁴ NABEYA, quoted by KOLMER, W., *Handbuch d. mikroskopisch. Anat. d. mensch.*, 1927, III/I, 365.
- ¹⁵ BELEMER, J. J., *Arch. Otolaryngol.*, 1936, xxiii, 93.
- ¹⁶ KOLMER, W., *Handbuch d. mikroskopisch. Anat. d. mensch.*, 1927, III/I, 348.

In den neuen Arbeiten von *Wright und Crowe* über die klinischen Erscheinungen der sog. *Ménière'schen Krankheit* wird die Ansicht vertreten, dass bei solchen Kranken bekannte Innenohrerkrankungen vorliegen.

Eine Bestätigung dieser Annahme bietet die vorliegende Arbeit über die histologischen Veränderungen der Felsenbeine von 2 derartigen Kranken. In beiden Fällen lag eine sehr ausgedehnte Erweiterung-Ectasie- des endolymphatischen Systems zugleich mit degenerativen Veränderungen der Sinneszellen vor. Die Erklärung für diese Veränderungen liegt möglicherweise im Vorhandensein gewisser Alternationen im Saccus endolymphaticus beider Fälle.

Verf. gibt ferner jene mechanische Erklärung, welche die histologischen Veränderungen mit den klinischen Erscheinungen in Einklang bringen könnte.

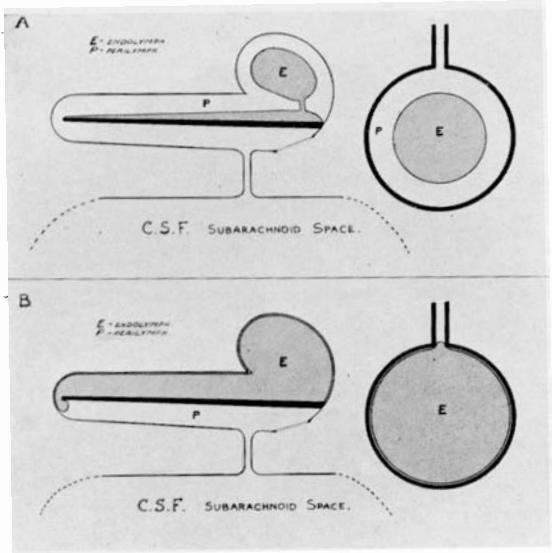


FIG. 29.

Diagrammatic representation of the fluid system within the labyrinth.

- A. Normal.
- B. With maximal dilatation of the endolymph system.

Pathology of Ménière's Syndrome

L'attention a été attirée sur les récentes publications de Wright et Crowe sur les aspects cliniques du syndrome de Ménière. Ces auteurs soumettent leur opinion qu'une proportion considérable des malades sont les victimes d'une affection banale de l'oreille interne. Les changements histologiques de l'os temporal de deux malades sont ici décrites et viennent à l'appui de cette hypothèse. Dans chaque cas l'os temporal affecté démontre une forte distension du système endolymphatique avec des changements dégénératifs du sensorium. Une des raisons pour cette distension peut être supposée due dans ces deux cas, à certains changements dans le saccus endolymphaticus. Ces changements histologiques peuvent également être considérés comme conséquent à l'association de ce mécanisme avec les symptômes cliniques de cette maladie.