

# Neuroimaging Highlight

Editor: David Pelz

## Peace Sign in Calcified Idiopathic Hypertrophic Pachymeningitis

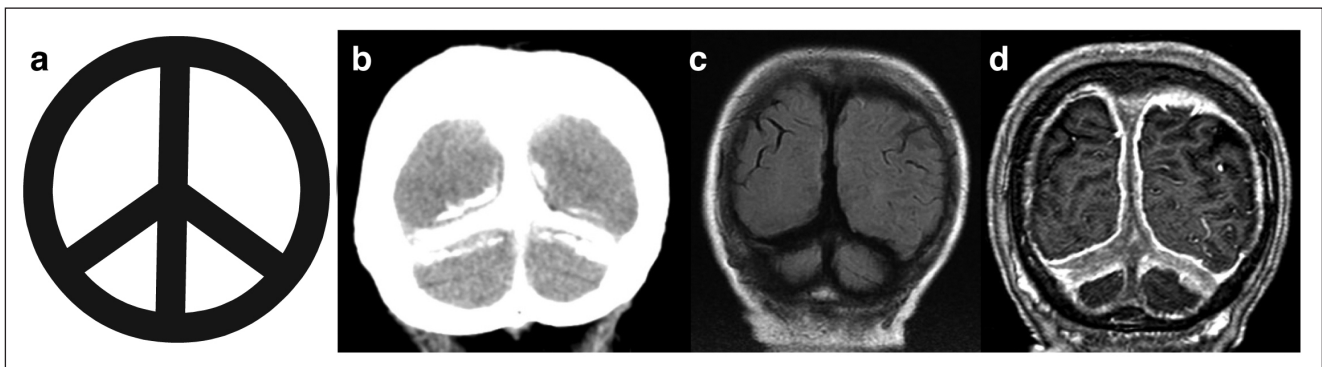
Submitted by: Josef G. Heckmann, Gerhard Oberst

Can J Neurol Sci. 2014; 41: 265-266

The peace sign (Figure 1a) was originally designed in 1958 by Gerald Holtom for the British nuclear disarmament movement. It derived from the semaphore alphabet “N” and “D” representing ‘nuclear’ and ‘disarmament’.<sup>1</sup> We recently cared for an 81-year-old woman with isolated complex-partial seizures who responded well to a medical treatment with carbamazepine. Coronal cranial computed tomography (CCT) (Figure 1b) showed a marked calcification of the tentorium, the posterior supratentorial falx, and the cerebellar falx mimicking a peace sign. Magnet resonance tomography (MRT) showed on a fluid attenuation inversion recovery (FLAIR) sequence (Figure 1c) a diminished signal consistent with calcification. An MRT five years earlier showed marked contrast enhancement of the tentorium and falx and adjacent dura (Figure 1d) on a T1-weighted image. The large sinus had been open. At this time

diagnosis of probable idiopathic hypertrophic pachymeningitis was made as the realized evaluation failed to reveal a cause.<sup>2</sup> A lumbar puncture, however, was not performed. As her clinical signs and symptoms resolved spontaneously no specific therapy was initiated.<sup>3</sup> It is suggested that during time the inflamed dura healed by calcification.

Calcification in the brain is frequent and can be found in a number of clinical conditions such as Morbus Fahr disease, forms of hyper- or hypoparathyroidism, tumor calcifications, trauma and other conditions.<sup>4</sup> Some tentorial or dural calcification can be frequently seen in healthy subjects, in particular, the elderly.<sup>4</sup> Additionally, elderly women in particular tend to develop hyperostotic reactions of the tabula interna. However, marked tentorial or dural calcification is rarely described and, if present, is primarily associated with



**Figure:** (a) Peace sign; coronal reconstructed cranial computed tomography demonstrates marked calcification of the tentorium and posterior part of the supratentorial and cerebellar falx (b). In the fluid attenuation inversion recovery (FLAIR) sequence of the magnet resonance tomography (MRT) (c), these structures reveal a diminished signal consistent with calcification. An MRT five years earlier showed marked contrast enhancement of the tentorium and falx and adjacent dura (d) on a T1-weighted image, compatible with idiopathic hypertrophic pachymeningitis (courtesy of Radiological Institute Mühleninsel, Landshut, Germany).

From the Department of Neurology (JGH), Department of Radiology (GO), Municipal Hospital Landshut, Landshut, Germany.

RECEIVED AUGUST 6, 2013. FINAL REVISIONS SUBMITTED SEPTEMBER 4, 2013.

Correspondence to: Josef G. Heckmann, Department of Neurology, Municipal, Hospital Landshut, Robert-Koch Str. 1, 84034 Landshut, Germany.

Email: josef.heckmann@klinikum-landshut.de.

hyperparathyroidism, vitamin D intoxication, basal cell nevus syndrome, or pseudoxanthoma elasticum<sup>5</sup>. In our patient, renal function, calcium levels, and parathormon levels were normal and vitamin D intoxication was implausible. We assume that prior idiopathic hypertrophic pachymeningitis led to the calcification. As the coronary posterior aspect of the section imaging methods resembles a peace sign, we propose the term for this clinical observation.

#### REFERENCES

1. Wikipedia.org [homepage on the Internet]. Peace symbols. Wikimedia Foundation, Inc. [updated 30.07.2013; cited 28.08.2013]. Available from: [http://en.wikipedia.org/wiki/Peace\\_symbols](http://en.wikipedia.org/wiki/Peace_symbols)
2. Kupersmith MJ, Martin V, Heller G, Shah A, Mitnick HJ. Idiopathic hypertrophic pachymeningitis. *Neurology*. 2004;62(5):686-94.
3. Nishio S, Morioka T, Togawa A, et al. Spontaneous resolution of hypertrophic pachymeningitis. *Neurosurg Rev*. 1995;18(3):201-4.
4. Heckmann JG, Tomandl B, Lang CJ, Kerling F, Dütsch M, Neundörfer B. Cerebral calcinosis. *Med Klin (Munich)*. 2001;96(1):55-6.
5. Dorenbeck U, Leingärtner T, Bretschneider T, Krämer BK, Feuerbach S. Tentorial and dural calcification with tertiary hyperparathyroidism: a rare entity in chronic renal failure. *Eur Radiol*. 2002;12 (Suppl 3):S11-3.