

Research Paper

Cite this article: Salama MA, Alabiad MA and Saleh AA (2023). Impact of resveratrol and zinc on biomarkers of oxidative stress induced by *Trichinella spiralis* infection. *Journal of Helminthology*, **97**, e100, 1–13
<https://doi.org/10.1017/S0022149X23000810>

Received: 17 August 2023

Revised: 28 October 2023

Accepted: 14 November 2023

Keywords:

Trichinella spiralis; oxidative stress; resveratrol; zinc; Nrf2

Corresponding author:

M.A. Salama;

Email: marwa.salama2003@gmail.com

Impact of resveratrol and zinc on biomarkers of oxidative stress induced by *Trichinella spiralis* infection

M.A. Salama¹ , M.A. Alabiad²  and A.A. Saleh¹

¹Department of Medical Parasitology, Faculty of Medicine, Zagazig University, Egypt and ²Pathology Department, Faculty of Medicine, Zagazig University, Egypt

Abstract

Trichinellosis is a re-emerging worldwide foodborne zoonosis. Oxidative stress is one of the most common detrimental effects caused by trichinellosis. In addition, *Trichinella* infection poses an infinite and major challenge to the host's immune system. Resistance and side effects limit the efficiency of the existing anti-*trichinella* medication. Given that concern, this work aimed to investigate the anti-helminthic, antioxidant, anti-inflammatory and immunomodulatory effects of resveratrol and zinc during both phases of *Trichinella spiralis* infection. Sixty-four Swiss albino mice were divided into four equal groups: non-infected control, infected control, infected and treated with resveratrol, and infected and treated with zinc. Animals were sacrificed on the 7th and 35th days post-infection for intestinal and muscular phase assessments. Drug efficacy was assessed by biochemical, parasitological, histopathological, immunological, and immunohistochemical assays. Resveratrol and zinc can be promising antiparasitic, antioxidant, anti-inflammatory, and immunomodulatory agents, as evidenced by the significant decrease in parasite burden, the significant improvement of liver and kidney function parameters, the increase in total antioxidant capacity (TAC), the reduction of malondialdehyde (MDA) level, the increase in nuclear factor (erythroid-derived 2)-like-2 factor expression, and the improvement in histopathological findings. Moreover, both drugs enhanced the immune system and restored the disturbed immune balance by increasing the interleukin 12 (IL-12) level. In conclusion, resveratrol and zinc provide protection for the host against oxidative harm and the detrimental effects produced by the host's defense response during *Trichinella spiralis* infection, making them promising natural alternatives for the treatment of trichinellosis.

Introduction

Trichinella spiralis (*T. spiralis*) is a common foodborne parasite that causes trichinellosis (Xu *et al.* 2021). It is challenging to estimate the prevalence of trichinellosis worldwide; however, it is possible that 11 million people are affected (Lee *et al.* 2016). Human infection is acquired by ingestion of insufficiently cooked or uncooked meat (especially pork) harboring *T. spiralis* larvae (Jiang *et al.* 2016). In the stomach, the larvae excapsulate, move to the small intestine, and mature into adults. Adult females of *T. spiralis* live in the host's small intestine epithelium, initiating immune-mediated hypersensitivity and inflammatory reactions that provoke the distinct intestinal pathology (Khan 2008). The intestinal phase is crucial in trichinellosis since it defines both the progress and consequences of the disease (Ding *et al.* 2017).

After mating, *T. spiralis* females release newly born larvae that pass into the blood and invade the striated muscles (Wu *et al.* 2008). *Trichinella* infection of the muscles for a long time interacts strongly with the immune system of the host, causing pronounced inflammation of the afflicted muscles (Bruschi and Chiumiento 2011).

Tissue damage in trichinellosis is influenced by various factors. The direct devastation triggered by the parasite and the oxidative stress state accompanying *Trichinella* infection are considered the primary causes of this damage. Additionally, the recruitment of inflammatory cells, when activated, release free radicals, nitrogen species, and an overabundance of reactive oxygen species (ROS) (Chiumiento and Bruschi 2009). Therefore, antioxidants and anti-inflammatory medications are anticipated to aid in protecting hosts from these harmful effects (Kazemzadeh *et al.* 2014). Chemotherapy is the primary efficient method to combat and control helminth parasites worldwide, although it triggers severe negative effects on hosts (Wang *et al.* 2015). Also, resistance against anti-helminthic drug substances is a widespread problem (Gang and Hallem 2016). Moreover, the frequently prescribed non-steroidal or steroidal anti-inflammatory medications have numerous side effects that restrict their usage (Badri *et al.* 2016). Thus, there is an urgent need for innovative, safe, and effective compounds with anti-inflammatory and antioxidant properties (Kunnumakkara *et al.* 2018).

Resveratrol (RSV) is a polyphenolic stilbene ubiquitous in the peels of red fruits like grapes, berries, and nuts (Szkudelska and Szkudelski 2010). It is a phytoalexin that is produced by plants and enhances their resistance to adverse environmental conditions and fungal and microbial infections (Chedea *et al.* 2017). RSV is a powerful antioxidant. It lowers intracellular ROS production by several mechanisms that offer an antioxidant defense (Leonard *et al.* 2003; Robb *et al.* 2008; Tanno *et al.* 2010). Furthermore, it has antimicrobial and antiparasitic activities (Wang *et al.* 2006; Soliman *et al.* 2017; Elgendy *et al.* 2020), anti-inflammatory properties (Donnelly *et al.* 2004), as well as cardioprotective (Tanno *et al.* 2010) and neuroprotective effects (Sun *et al.* 2010).

Zinc is one of the most precious trace elements in earth's crust. Many enzymes in plants, people, and animals need it for their cellular and catalytic functions. It can be found in various foods, including eggs, poultry, dairy products, legumes, nuts, red meat, oysters, seafood, and cereals. Additionally, it is crucial for immunological function (Khanam 2018) and has a valuable effect on certain parasitic diseases (Gabrashanska *et al.* 2008).

Given the above concerns, we attempt to investigate the anti-helminthic effect of RSV and zinc on both phases of *Trichinella spiralis* infection, besides their role as substances that can diminish unfavorable peroxidation effects. A parasitological, biochemical, histopathological, immunohistochemical, and immunomodulatory assessment will be conducted.

Materials and methods

Experimental animals

Sixty-four parasite-free male Swiss albino mice (~15–20 gm) of 8-week-old age were used. Mice were purchased from Theodor Bilharz Research Institute (TBRI), Giza, Egypt, and acclimated one week before the experiments. Animal maintenance and infection were in accordance with institutional and national guidelines.

Parasites and infection

T. spiralis larvae were obtained from infected pork muscles from Cairo abattoir and maintained in the laboratories of TBRI by consecutive passages in rats. *Trichinella* isolate used in this study was genotyped as *T. spiralis* (code: ISS6158) by the European Union Reference Laboratory for Parasites, Superior Institute of Health, Rome, Italy. Each mouse was orally infected with 200 larvae, as described by Dunn and Wright (1985).

Experimental design

The current study includes four groups of 16 mice each – Group I: non-infected control (non-infected, non-treated); Group II: infected control (infected, non-treated); Group III: infected, then treated with RSV; Group IV: infected, then treated with zinc. In treated groups, treatment started one day post-infection (dpi) until the day of scarification.

On the 7th day post-infection (dpi), eight mice from each group were euthanized and then sacrificed, and blood samples were collected for biochemical and serological assays. Their small intestine was taken, opened along its entire length, and washed. A small part of each intestinal sample (about 1 cm) was placed in 10% formalin for histopathological and immunohistochemical evaluation, and the remaining part was used for counting *T. spiralis* adult worms. On the 35th dpi, the remaining eight mice from each group

were sacrificed, and blood samples were collected for biochemical and serological assays. Part of the thigh muscles were gently dissected and subjected to histopathological and immunohistochemical studies, and the remaining carcasses were digested for larvae count.

Drug therapy

Resveratrol powder was bought from Sigma-Aldrich Chemie (Steinheim, Germany) and dissolved in distilled water to make a suspension. Each mouse orally received 20 mg/kg once daily (Soliman *et al.* 2017). Zinc: Octozine (Zn) tablets were used (October Pharma SAE). The drug was given orally in the form of an aqueous suspension in distilled water at a dose of 12 mg/kg once daily (Ivanov *et al.* 2014).

Parasitological assessment

Isolation and adult worm counting

The washed intestine was divided into small portions (1 cm) and kept in 10 ml of normal saline for 2 hr at 37°C. The specimens were then shaken and washed with saline several times until the fluid became clear. The collected fluid was centrifuged at 2000 rpm for 2 min, and then the supernatant was discarded. The sediment was reconstituted in 3–5 drops of physiological saline in a petri dish and examined under the dissecting microscope at X10 power to count adult worms (Denham 1965; Wakelin and Ltoyd 1976).

Total larval burden in muscles

On the 35th dpi, mice were euthanized and sacrificed. Muscle larval counts in whole carcasses were determined as described by Dunn and Wright (1985). In brief, each mouse was dissected and digested in 1% pepsin hydrochloride in 200 ml of distilled water. The mixture was incubated for 1 hr at 37°C with continuous agitation by an electric stirrer. After being collected using the sedimentation technique, the larvae were thoroughly washed by distilled water then counted under the microscope using the McMaster counting chamber.

Biochemical, serological, and immunological assessments

Blood samples were taken and then allowed to clot at room temperature for 2 hr before being centrifuged at 2000×g for 20 min. The collected serum was separated and kept at –20°C until used.

Biochemical assessment

For biochemical assays, the following parameters were tested: alanine transaminase (ALT), aspartate transaminase (AST), alkaline phosphatase (ALP), L-lactate dehydrogenase (LD), and creatinine phosphokinase (CPK) using commercial kits supplied by TBRI, Giza, Egypt, as illustrated by the manufacturer's guide.

Assessment of oxidation and antioxidant parameters

The principle for assessment of the antioxidant capacity is based on the reaction of antioxidants in the sample with a predetermined amount of exogenously provided hydrogen peroxide (H₂O₂). Antioxidants in the sample eliminate a part of the provided hydrogen peroxide, and the remaining H₂O₂ is measured colorimetrically

via an enzymatic reaction that involves the transformation of 3,5-dichloro-2-hydroxybenzenesulphonate to a colored product. Total antioxidant capacity (TAC) was spectrophotometrically analysed as described by Koracevic *et al.* (2001). Malondialdehyde (MDA) level (a marker of oxidative stress) was investigated using a commercial kit supplied by TBRI, Giza, Egypt, as illustrated by the manufacturer's guide.

Assessment of immunological parameters

Serum levels of interleukin 12 (IL-12) and interleukin 10 (IL-10) were immunoassayed at 7th and 35th dpi using commercial enzyme-linked immunosorbent (ELISA) sets (R & D Systems, Minneapolis, MN, United States) in keeping with the manufacturer's guidelines.

Histopathological study

All tissue specimens were fixed in 10% formalin for 24 hr and then processed to form paraffin blocks. Five- μ m-thick sections were stained using Hematoxylin and eosin (H&E) stain to assess histopathological criteria (Feldman and Wolfe 2014).

Histopathological evaluation

The scoring process was performed blindly without knowing the examined group. For small intestinal samples, we evaluated the extent of inflammatory infiltrates within the mucosa and sub-mucosa by evaluating five sections per mouse and ten low-power fields (100 \times) for each section, to calculate the average score. Inflammatory infiltrate covers of <10% of the examined sections scored as mild infiltrates = (+1); 10–50% scored as moderate = (+2); and more than 50% scored as intense = (+3) (Erben *et al.* 2014). The mean villus height, the mean crypt depth, and the mean number of goblet cells were also evaluated (Elgendy *et al.* 2020). For skeletal muscle samples, we evaluated the extent of the inflammatory reaction surrounding the capsule as mild reaction = +1 (1% to 30% increase in inflammatory cellular infiltration), moderate reaction = +2 (31% to 60% increase in inflammatory cellular infiltration), and intense reaction = +3 if (61% to 100% increase in inflammatory cellular infiltration) compared to the control group (Eissa *et al.* 2022; Shalaby *et al.* 2023).

Immunohistochemistry

The immunohistochemistry staining was performed in accordance with Saber *et al.* (2019). In brief, the serial sections were dewaxed, hydrated, and submerged in an antigen retrieval solution (EDTA solution, PH 8). After that, it was incubated with rabbit anti-Nrf2 polyclonal antibody (Invitrogen, PA5-27882, USA; 1:100 dilution) after being treated with hydrogen peroxide 0.3% and protein block. The slides were washed three times with

PBS, incubated with anti-rabbit IgG secondary antibodies (EnVision + System HRP; Dako) for 30 minutes at room temperature, visualized using di-aminobenzidine commercial kits (Liquid DAB + Substrate Chromogen System; Dako), and then counterstained with Mayer's hematoxylin. The primary antibody was replaced by normal mouse serum as a negative control procedure. The labeling index of Nrf2 was calculated according to the ratio of positive area to the total area in 8 high-power fields.

Statistical analysis

Data were analyzed using IBM SPSS 18.0 for windows (SPSS Inc., Chicago, IL, USA) and NCSS 11 for windows (NCSS LCC., Kaysville, UT, USA). Quantitative data were expressed as mean \pm standard deviation (SD). Qualitative data were expressed as frequency and percentage. Data were tested for normality using the Kolmogorov Smirnov test. The following tests were performed: ANOVA (Analysis of Variance) F tests were used for comparing multiple means, LSD was used as a post hoc test for in between groups comparison, and Monte Carlo exact test was used for chi square (for histopathological and immunohistochemistry). A probability (P-value) of ≤ 0.05 was considered significant, P-value ≤ 0.001 was considered as highly significant, and P-value > 0.05 was considered insignificant.

Results

Parasitological assessment

The mean number of adult *T. spiralis* in the small intestines of the treated groups was significantly reduced compared with the infected control group ($P < 0.001$). Mice that received zinc showed a lower mean (28.5 ± 4.2) than those treated with RSV (59 ± 11.6). Similarly, the muscles of the treated groups showed a significant decrease in the mean larval count compared with the infected control group ($P < 0.001$). The mean larvae count was lower in the muscles of mice that received zinc than in those who received RSV (504.5 ± 122.4 and 885.8 ± 524.98 , respectively) (Table 1).

Biochemical findings

Serum enzyme changes

Infection with *T. spiralis* induced a statistically significant increase in serum levels of ALT, AST, ALP, CPK, and LDH during the enteral and muscle phases of infection compared with the non-infected control group ($P < 0.001$), whereas a significant reduction in their level was noted in the treated groups compared with the infected control group ($P < 0.001$). Mice treated with zinc showed

Table 1. Mean adult *T. spiralis* and larvae count among the studied groups

	Group I	Group II	Group III	Group IV	P-value
Adult worm on day 7 Mean \pm SD	0 ^{abc}	73 \pm 6.3 ^{de}	59 \pm 11.6 ^f	28.5 \pm 4.2	<0.001
Larva count at day 35 Mean \pm SD	0 ^a	7566.7 \pm 1252.3 ^{de}	885.8 \pm 524.98	504.5 \pm 122.4	<0.001

There is a significant difference between the following groups: a, group I vs. II; b, group I vs. III; c, group I vs. IV; d, group II vs. III; e, group II vs. IV; f, group III vs. IV

Table 2. Serum enzyme changes among the studied groups at 7th dpi

	Group I	Group II	Group III	Group IV	P-value
CPK Mean \pm SD	22.0 \pm 0.54 ^{abc}	77.2 \pm 3.5 ^{de}	59.9 \pm 2.5 ^f	39.4 \pm 2.9	<0.001
ALT Mean \pm SD	34 \pm 0.85 ^{ab}	51.3 \pm 1.5 ^{de}	36.6 \pm 0.43 ^f	33.8 \pm 0.96	<0.001
AST Mean \pm SD	37 \pm 0.59 ^{ab}	54.5 \pm 2.1 ^{de}	40.6 \pm 0.48 ^f	38 \pm 0.82	<0.001
ALP Mean \pm SD	78 \pm 0.25 ^{abc}	136.9 \pm 0.85 ^{de}	123 \pm 1.84	122 \pm 3.6	<0.001
LDH Mean \pm SD	172.6 \pm 0.37 ^a	193.7 \pm 2.44 ^{de}	170.8 \pm 0.97	173.3 \pm 1.41	<0.001

There is a significant difference between the following groups: a, group I vs. II; b, group I vs. III; c, group I vs. IV; d, group II vs. III; e, group II vs. IV; f, group III vs. IV

Table 3. Serum enzyme changes among the studied groups at 35th dpi

	Group I	Group II	Group III	Group IV	P-value
CPK Mean \pm SD	23.3 \pm 0.54 ^{abc}	84.3 \pm 3.22 ^{de}	54.2 \pm 1.45 ^f	46.5 \pm 2.21	<0.001
ALT Mean \pm SD	33.1 \pm 0.85 ^{abc}	71.8 \pm 2.75 ^{de}	52 \pm 1.41 ^f	44.8 \pm 1.71	<0.001
AST Mean \pm SD	37.5 \pm 0.59 ^{abc}	77.8 \pm 0.96 ^{de}	56.8 \pm 0.96 ^f	50 \pm 0.81	<0.001
ALP Mean \pm SD	78.9 \pm 0.25 ^{abc}	180.5 \pm 3.11 ^{de}	147.8 \pm 3.4 ^f	129.3 \pm 1.9	<0.001
LDH Mean \pm SD	172.5 \pm 0.37 ^c	189.8 \pm 0.51 ^e	170.2 \pm 0.51	170.9 \pm 0.5	<0.001

There is a significant difference between the following groups: a, group I vs. II; b, group I vs. III; c, group I vs. IV; d, group II vs. III; e, group II vs. IV; f, group III vs. IV

a greater decrease in serum levels than those treated with RSV (Tables 2 and 3).

Redox status parameters

The total antioxidant capacity level (TAC) was significantly reduced in the infected control group compared with the non-infected control group ($P < 0.001$) during both the enteral and muscle phases of infection. Conversely, a significant increase in TAC serum level was noted in both drug-receiving groups as compared to the infected control group ($P < 0.001$). Regarding MDA serum levels, there was a significantly higher serum value in the infected control group compared to the non-infected control group, signifying the oxidative stress during *T. spiralis* infection. However, its level was decreased in both treated groups with a statistically significant difference compared to the infected control group ($P < 0.001$) during both phases of *T. spiralis* infection (Table 4).

Table 4. Redox status parameters among the studied groups

			Group I	Group II	Group III	Group IV	P-value
MDA	7th dpi	Mean \pm SD	26 \pm 0.15 ^{abc}	63 \pm 2.5 ^{de}	35.6 \pm 0.23 ^f	30.3 \pm 0.36	<0.001
	35th dpi	Mean \pm SD	26.5 \pm 0.15 ^{ab}	77.3 \pm 0.51 ^{de}	44.6 \pm 0.76 ^f	35.5 \pm 0.67	<0.001
TAC	7th dpi	Mean \pm SD	4.0 \pm 0.13 ^{abc}	1.25 \pm 0.28 ^{de}	3.25 \pm 0.29	3.33 \pm 0.18	<0.001
	35th dpi	Mean \pm SD	4.5 \pm 0.13 ^{abc}	1.43 \pm 0.11 ^{de}	3.75 \pm 0.29	4.11 \pm 0.29	<0.001

There is a significant difference between the following groups: a, group I vs. II; b, group I vs. III; c, group I vs. IV; d, group II vs. III; e, group II vs. IV; f, group III vs. IV

Changes in serum cytokine levels

To investigate the effect of RSV and zinc on the immune response, we investigated the serum levels of Th1/Th2 cytokines at both the enteral and muscle phases of *T. spiralis* infection. Th1 cytokine (IL-12) level was significantly increased in the infected control and treated groups on the 7th day of infection and onwards as compared to the non-infected control group. Moreover, its level was higher in the zinc-treated group than in those who received RSV, with a statistically significant difference ($P < 0.001$). Referring to Th2 cytokine (IL-10), a significant increase in its serum level was observed in all groups at both phases of infection compared to the non-infected control group. However, the infected control group showed more elevation than the treated groups. This increase was more evident during the muscle phase of infection. Likewise, the zinc-treated group showed more elevation than the RSV-treated group (Table 5).

Table 5. Changes in serum cytokine levels among the studied groups

		Group I		Group II		Group III		Group IV		P-value
IL-10	7th dpi	Mean ±SD	54.5 ± 0.27 ^{abc}	121 ± 1.31 ^{de}	81.8 ± 1.26 ^f	92.3 ± 2.11			<0.001	
	35th dpi	Mean ±SD	54.6 ± 0.27 ^{abc}	181.3 ± 2.41 ^d	109.2 ± 0.96 ^f	152.5 ± 2.89			<0.001	
IL-12	7th dpi	Mean ±SD	210 ± 0.85 ^{abc}	529.3 ± 18.5 ^{de}	349.5 ± 1.29 ^f	533.8 ± 23.6			<0.001	
	35th dpi	Mean ±SD	211 ± 0.85 ^{abc}	330 ± 21.6 ^{de}	424.6 ± 12.6	420 ± 21.6			<0.001	

There is a significant difference between the following groups: a, group I vs. II; b, group I vs. III; c, group I vs. IV; d, group II vs. III; e, group II vs. IV; f, group III vs. IV

Histopathological finding

Small intestine

The examined sections of small intestine from the infected control group revealed an intense inflammatory reaction in the mucosa and submucosa, predominantly consisting of eosinophils, neutrophils, and lymphocytes. Also, the intestinal mucosa showed ulceration, sloughing, goblet cell hyperplasia, and marked villous atrophy (Figure 1). Regarding the treated groups, there was a noticeable improvement in histopathological findings noted as a reduction in the inflammatory reaction, decrease in goblet cell hyperplasia, and recovery of intestinal villous length; however, this improvement was remarkable in zinc-treated group (Figures 2, 3, and 4). The extent of inflammatory cellular infiltration is shown in Table 6.

Skeletal muscle

Microscopic examination of skeletal muscle sections of the infected control group exhibited numerous encroachment larvae of *T. spiralis* encysted in the skeletal muscle fibers, surrounded by an intense inflammatory reaction. Compared to the treated groups, there was a significant reduction in inflammatory infiltration and the number of infested larvae, with a greater improvement within

the zinc-treated group (Figure 5). The extent of the inflammatory infiltrate is shown in Table 7.

Immunohistochemical assessment

Nrf2 expression in the intestine

In the non-infected control group, a scanty expression of Nrf2 was detected within the intestinal epithelial lining. However, there was a mild increase in Nrf2 expression in the infected control group. This immunoreactivity was observed within the intestinal epithelial lining and was associated with parasitic intestinal invasion. A significant increase in Nrf2 expression was observed in both treated groups; moreover, the zinc-treated group showed a marked expression that was more evident within the intestinal epithelial lining and within the interstitial inflammatory cells (Figure 6).

Nrf2 expression in muscles

The immunohistochemical expression of Nrf2 in skeletal muscle sections of the non-infected control group was low; however, the infected control group revealed a moderate increase in Nrf2 expression within the skeletal muscle fibers infected with *Trichinella* parasites. A significant increase in immunoreactivity of Nrf2 was

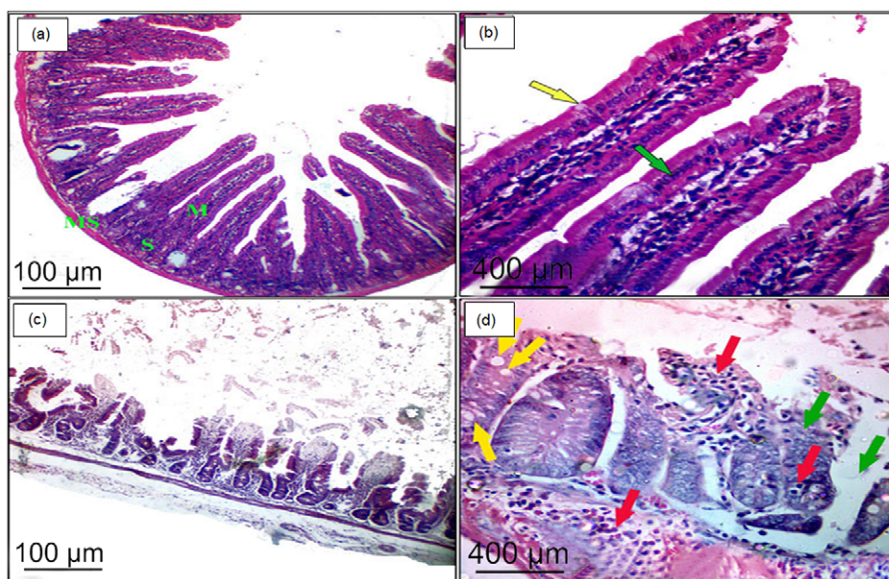


Figure 1. Section in the small intestine of (a) the non-infected control group showing the normal histological structure formed of mucosa (M), submucosa (S), and muscosa (MS) (H&E, ×100), (b) a higher magnification of the previous image demonstrating finger-like villi with a core of lamina propria covered by simple columnar epithelium (green arrow) and goblet cells (yellow arrow) (H&E, ×400), (c) the infected control group showing marked histopathological damage (H&E, ×100), (d) a higher magnification of the previous image demonstrating intense inflammatory reaction infiltrating the mucosa, submucosa, and muscosa (red arrows), increase goblet cell number (yellow arrows), and short, broad villi with increased crypt depth (green arrows) (H&E, ×400).

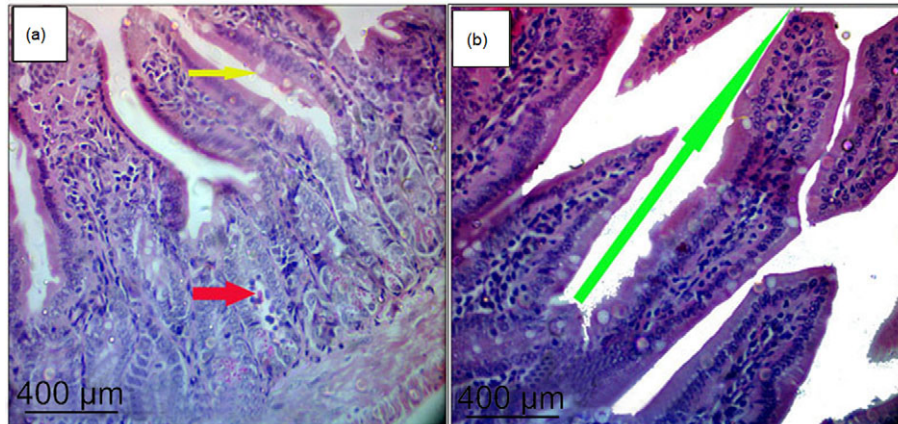


Figure 2. Section in the small intestine of (a) RSV-treated group, (b) zinc-treated group showing marked reduction in the inflammatory infiltrates (red arrow), decreased number of goblet cells (yellow arrows), and marked improvement in the villous lengths (green arrow) (H&E, $\times 100$).

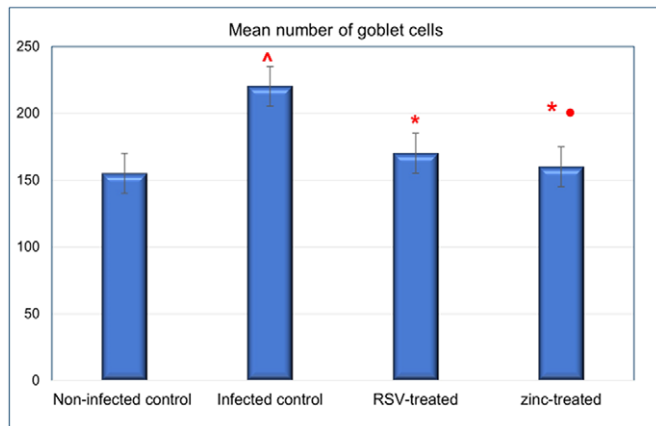


Figure 3. Bar chart showing the mean number of goblet cells among studied groups, *significant vs. control, ^significant vs. positive control group, •significant vs. RSV-treated group.

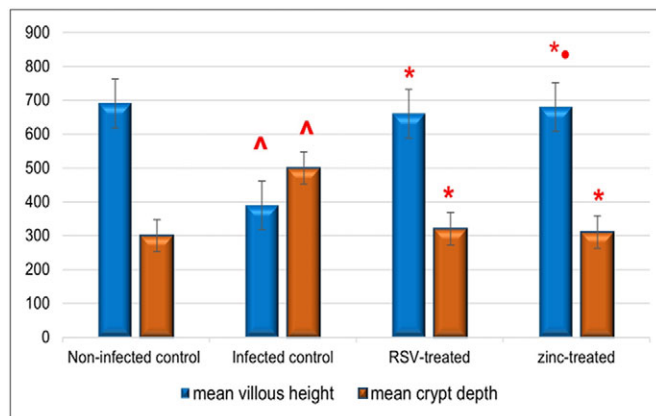


Figure 4. Bar chart showing the means of villus height and crypt depth among studied groups, *significant vs. control, ^significant vs. positive control group, •significant vs. RSV-treated group.

observed in both treated groups compared to the infected control group, with marked expression in zinc-treated group compared to RSV-treated group (Figure 7). Nrf2 expression within the experimental groups is summarized in Table 8.

Table 6. The extent of the inflammatory cellular infiltrates in the small intestine of the studied groups

	The extent of the inflammatory infiltrates (score)			
	+1	+2	+3	P-value
Infected control (n=8)	0	1	7	–
RSV-treated group (n=8)	5	3	0	0.002
Zinc-treated group (n=8)	6	2	0	0.001

Chi-square test was used to compare the treated groups with the infected control group.

Discussion

The management of *T. spiralis* is a challenge because of the variety of tissue involvement, immune response mechanisms, and effector cells during the various stages of infection (Hamed *et al.* 2022).

Nutritional immunity is the manner used by the host to manage its availability of micronutrients in order to limit the advancement and severity of infections (Hood and Skaar 2012). In hosts with balanced micronutrient status, nutritional immunity is an intensely regulated response. Zinc deficiency may disrupt this balance, impairing the body's ability to fight off infections (Fançony *et al.* 2022). Natural foodstuffs have always been an excellent source for bioactive compounds (Bruno *et al.* 2021). One of these constituents is resveratrol (RSV), which is a natural plant extract with an antioxidant effect (Malaguarnera 2019). The biologically active components of this substance enable it to act against numerous medically important protozoa, including *leishmania* (Ferreira *et al.* 2014), *Amoeba* (Pais-Morales *et al.* 2016), *Toxoplasma gondii* (Chen *et al.* 2019), and *Trypanosoma cruzi* (Bruno *et al.* 2021; Isabela *et al.* 2022) as well. Given these facts, there is a reason to be optimistic about the potential role of resveratrol and zinc in the management and prevention of a wide range of chronic and infectious diseases.

In the current study, the effectiveness of RSV and zinc on adult and larva stages of *Trichinella spiralis* was observed, as evidenced by the significant decrease in the mean parasite burden in the small intestines and muscles, improvement in histopathological findings, and enhancement of the immune status of the targeted treatment groups as compared to the infected control group. However, this improvement was more evident in zinc-treated group.




Figure 5. Section in the skeletal muscle of (a) the non-infected control group showing the normal histological structure (H&E, ×100), (b) the infected control group with numerous larvae within the muscle fibers enclosed by an intense inflammatory reaction (green arrows) (H&E, ×100), (c) the RSV-treated group reveals decrease in number of encysted larvae within the muscles and moderate inflammatory reaction (H&E, 100×), (d) the zinc-treated group shows marked reduction in number of deposited larvae with atrophic changes and mild inflammatory infiltrates (H&E, 100×).

Table 7. The extent of the inflammation infiltrates within the skeletal muscle of the studied groups

	The extent of the inflammatory infiltrates (score)			P-value
	+1	+2	+3	
Infected control (n=8)	0	1	7	–
RSV-treated group (n=8)	5	3	0	0.002
Zinc-treated group (n=8)	7	1	0	0.001

Chi-square test was used to compare the treated groups with the infected control group.

In agreement with our results were those of Ozkoc *et al.* (2009) and Elgendy *et al.* (2020). Both reported the direct harmful effect of RSV on larvae and adult stages of *T. spiralis*. RSV can induce marked morphological changes by acting on neuromotor activity, affecting the parasite’s motility and impairing its ability to migrate and acquire nutrients. Furthermore, it can affect the tegument, causing vacuolations, disruption, and extensive lysis of sub-tegumental regions, with subsequent fading of the immunological concealment of the parasite, which, in turn, exposes immunogens and immunogenic epitopes. So, it induced a dual action by both harming the parasite and enhancing host oxidative stress against it as well (Gouveia *et al.* 2019).

Several mechanisms were proposed to justify the parasitocidal effect of RSV. Earlier studies suggested that RSV inhibits polyamine metabolism, terminates tubulin polymerization, blocks calcium channels, and limits oxygen consumption by the parasites

(Stadler *et al.* 1994; Leiro *et al.* 2004; Kedzierski *et al.* 2007; Lamas *et al.* 2009). Furthermore, RSV was reported to reduce the activity of acetylcholinesterase (AChE), resulting in paralysis of the worms with subsequent detachment and expulsion from the host (Giri and Roy 2015). In addition, it exerts indirect harm to parasites through the activation of macrophages with the subsequent release of TNF, which promotes parasite killing (Chen *et al.* 2019).

Regarding zinc, it was a remarkable finding that the zinc-treated group showed the highest reduction in parasite burden. To our knowledge, previous studies investigating the direct effect of zinc on trichinellosis are lacking. Effective immune responses, mainly intestinal immunity, against gastrointestinal nematodes greatly depend on zinc status and zinc nutrition (Hughes and Kelly, 2006). So, the parasitocidal effect obtained may be due to its role as an ‘immune booster’, enhancing the body’s immunity by decreasing oxidative stress markers and generating inflammatory cytokines (Khanam 2018). This is in agreement with Khan *et al.* (2015) and Dorostkar *et al.* (2017), who stated that the anti-helminthic effect of zinc can be attributed to its ability to induce oxidative/nitrosative stress with subsequent membrane damage, observed as a damage to the parasite’s integument, erosion in the superficial papillae, and rupture of superficial annulments. It has been suggested that oxidative stress can result in structural damage and destroy subcellular architecture, including mitochondria, which in turn overwhelms the synthesis of ATP and ultimately results in the paralysis of the worm (Wolstenholme *et al.* 2004). The antiparasitic effect of zinc has previously been a point of concern for many researchers. Exposure to ZnO or ZnONPs has been reported to affect the parasite’s ultrastructure, causing sloughing, disruption,

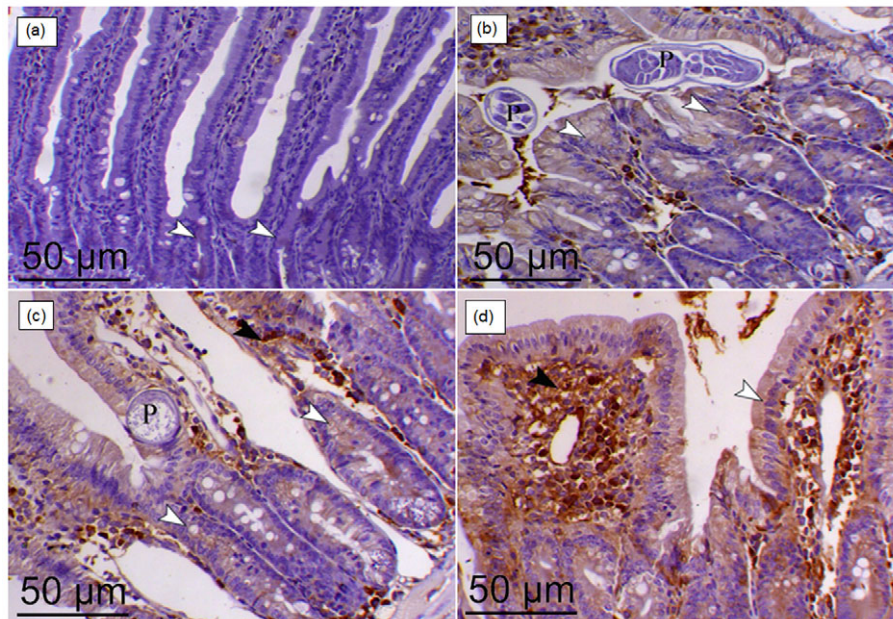


Figure 6. Immunohistochemical staining of Nrf2 in small intestine sections of (a) the non-infected control group with a scanty expression of Nrf2 within intestinal epithelial lining (arrowheads), (b) the infected control group showing a mild increase of Nrf2 expression within intestinal epithelial lining (arrowheads) associated with parasitic intestinal invasion (P), (c) the RSV-treated group showing a moderate increase of Nrf2 expression within intestinal epithelial lining (white arrowheads) and within the interstitial inflammatory cells (black arrowhead) and parasitic invasion (P), (d) the zinc-treated group displaying a marked increase of Nrf2 expression of within intestinal epithelial lining (white arrowhead) and within the interstitial inflammatory cells (black arrowhead), X200.

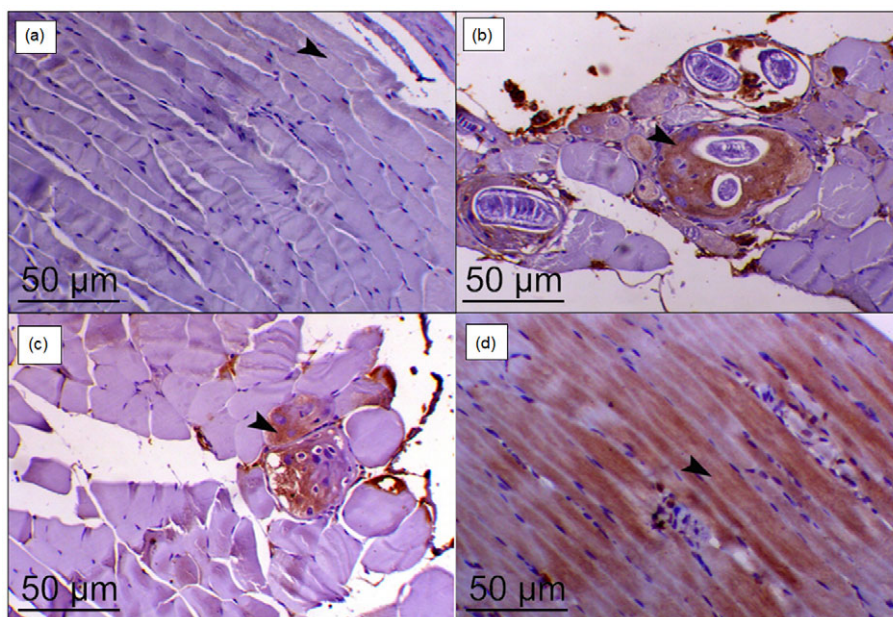


Figure 7. Immunohistochemical staining of Nrf2 in skeletal muscle of (a) the non-infected control group showing a low level of Nrf2 expression within the skeletal muscle fibers (arrowhead) (b) the infected control showing a moderate increase of Nrf2 expression within the skeletal muscle fibers infected with *Trichinella* parasites (arrowhead), (c) the RSV-treated group displaying an increase of Nrf2 expression within the skeletal muscle fibers (arrowhead), (d) the zinc-treated group showing a marked increase of Nrf2 expression within the skeletal muscle fibers (arrowhead), X200.

and loss of cuticular spines, bursting and disruption in surface annulations, disruption in the arrangement and erosion in male pre- and postanal papillae (Morsy *et al.* 2019; Hassan *et al.* 2021b). However, a possible explanation was attributed to the ability of NPs to generate ROS and cause changes in macromolecules such as proteins, nucleic acids, and lipids (Khashan *et al.* 2020). Oxidation

of proteins and peroxidation of lipids lead to damaging the hardness of the cell membrane, changing fluid permeability and ion transport and inhibiting metabolic processes (Akhtar *et al.* 2015).

In trichinellosis, the invasion of muscle tissue by *T. spiralis* larvae coincides with an increase in cellular permeability, leakage of fluid into the adjacent tissue, and an increase in serum aspartate

Table 8. Nrf2 among the studied groups

Variables		Group I	Group II	Group III	Group IV	P-value
intestine	Mean ±SD	4.9 ± 1.5 ^{abc}	13.98 ± 2.5 ^{de}	24.1 ± 2.36 ^f	38.7 ± 2.62	<0.001
skeletal muscle	Mean ±SD	4.81 ± 1.15 ^{abc}	9.02 ± 1.41 ^{de}	19.4 ± 2.66 ^f	29.1 ± 3.15	<0.001

There is a significant difference between the following groups: a, group I vs. II; b, group I vs. III; c, group I vs. IV; d, group II vs. III; e, group II vs. IV; f, group III vs. IV

transaminase (AST), alanine transaminase (ALT), creatine phosphokinase (CPK), and lactate dehydrogenase (LDH) (Kociecka 2000).

AST is present in most cells, but it is used as a marker to evaluate hepatocellular and muscular injuries because it is highly active in these tissues. However, ALT is almost exclusively associated with hepatocellular injury, and its increased serum levels reflect the severity of hepatocellular damage (Aulbach and Amuzie 2017). Also, the abnormal increase in plasma CPK and LDH levels usually reflects disruption of the function and permeability of the muscle cell membrane and is used as an indicator of muscle damage (Brancaccio *et al.* 2007).

In the present work, the levels of ALT and AST were significantly elevated in the infected groups compared to the non-infected control group. These findings agreed with Hassan *et al.* (2021a), Basyoni and Elsabah (2013), and Swilam *et al.* (2022), who reported elevation in serum ALT and AST in mice infected with *T. spiralis* due to liver damage by migrating larvae.

Regarding the treated groups, our results showed a significant decrease in ALT and AST serum levels. The effects of RSV and zinc could be attributed to their ability to protect hepatocytes from primary damage induced by oxidative stress. Likewise, several studies have reported the hepatoprotective effect of RSV (Rubiolo *et al.* 2008; Sahin *et al.* 2012; Jia *et al.* 2019). They suggested that RSV protects hepatocytes from injury through Nrf2 activation and suppression of toll-like receptor-2 (TLR2)-Myd88-NF-κB activation. Also, Hosui *et al.* (2018) reported that zinc supplementation improved liver function and decreased AST and ALT levels in patients with chronic liver disease. The precise mechanism by which zinc exerts its effect on the liver is still unidentified; however, we proposed that the improvement of liver injury is due to the role of zinc in restoring SOD activity to the basal level and reducing ROS levels (Hosui *et al.* 2018).

In this work, a significant decrease in CPK and LDH serum levels was noticed in both treated groups compared to the infected control group. Our results were consistent with those obtained by Xiao (2015), Hsu *et al.* (2020), and Huang *et al.* (2021), who revealed the protective effect of RSV against induced oxidative muscle damage and lipid peroxidation and observed a reduction in CPK and LDH levels, decreased muscle damage, and regeneration of muscle satellite cells after RSV supplementation. Also, Malyar *et al.* (2020) reported a decrease in serum levels of CPK and LDH in rats upon zinc supplementation. Zinc is known to be important for maintaining cell membrane integrity. It binds to thiol groups of biomolecules, protecting them from oxidation, reduces the activities of oxidant-promoting enzymes, boosts the activities of antioxidant enzymes, and prevents the generation of lipid peroxidation products (Prasad 2009).

Given that tissue damage in *T. spiralis* infection is most likely contributed to an oxidative stress state mediated by ROS and produced by the parasite and the host defense reaction (Gabrashanska *et al.* 2019), as well as membrane lipid peroxidation (Mido *et al.* 2012), we investigated redox status parameters and

observed an increase in MDA level and a decrease in TAC in the infected control group compared with the non-infected control group. A similar increase in serum MDA level was verified by Tolstoj *et al.* (2007), Ivanov *et al.* (2014), Gabrashanska *et al.* (2019), and Hamed *et al.* (2022). The increased MDA concentration (a sign of lipid peroxidation extent) in *T. spiralis* infection is an indicator of radical-induced damage in the host (Ivanov *et al.* 2014) and may signify that the infected organism does not have enough antioxidant enzymes to cope with the increased oxidative stress (Xu *et al.* 2007). It is recognized that parasitic nematodes need antioxidant enzymes to survive the ROS generated during cellular metabolism (Dorostkar *et al.* 2017). Moreover, there was a predominance of antioxidant status in the targeted treatment groups, as evidenced by a significant increase in serum TAC and a significant decrease in MDA levels. The alterations in serum TAC and MDA levels clearly show the development of an antioxidant imbalance in the infected host. This finding was in accordance with previous studies (Soliman *et al.* 2017; Chen *et al.* 2019; Turkmen *et al.* 2019; Elgendy *et al.* 2020) that reported the antioxidant efficiency of RSV and its ability to destroy the oxidant-antioxidant homeostasis elaborated by the parasite, and Isabela *et al.* (2022), who reported that RSV can directly activate Sirtuin 1 (SIRT-1), which is an enzyme that performs histone deacetylase and is responsible for increasing the number of antioxidant enzymes via balancing the effects of ROS on Nrf2 (Maldonado *et al.* 2020). Concerning the zinc-treated group, our finding was in line with several studies (Ivanov *et al.* 2014; Pivoto *et al.* 2015; Jarosz *et al.* 2017; Marreiro *et al.* 2017; Váradyová *et al.* 2018) that confirmed the potent antioxidant effect of zinc and suggested that it could possibly be a natural antioxidant minimizing the oxidative stress in nematode infection.

Inflammation is the primary response evolved by the host to infection or injury. Although it helps to preserve tissue homeostasis, limit further tissue damage, and stimulate repair mechanisms (Munn 2017; Kunnumakkara *et al.* 2018), uncontrolled inflammation is well established to be deleterious and causes progressive tissue damage (de Sá Coutinho *et al.* 2018). It was reported that *T. spiralis* infection can alleviate inflammation by enhancing nuclear factor (erythroid-derived 2)-like-2 factor (Nrf2) expression (Chu *et al.* 2020). Nrf2 is a crucial regulatory transcription factor in antioxidant response element-dependent genes (Wei *et al.* 2018).

In the current study, RSV and zinc reduced the severe inflammatory reaction provoked by *T. spiralis* infection, as demonstrated by the improvement in histopathological alterations and increased Nrf2 expression in the intestine and muscle tissues. Our results agreed with Chu *et al.* (2020) and Jin *et al.* (2021), who reported that Nrf2 production was provoked by *T. spiralis* muscle larval excretory/secretory (ES) products. These excretory-secretory (ES) proteins trigger regulatory network components to decrease host immune attacks as a survival strategy (Li *et al.* 2022). Likewise, Ungvari *et al.* (2010) and Farkhondeh *et al.* (2020) reported that resveratrol exerts its effect through upregulating Nrf2 expression. In addition, Nrf2 is a known zinc finger protein (Prasad and Bao

2019), and it has been proven to be upregulated by zinc (Jarosz et al. 2017). Our finding showed that the highest Nrf2 expression was observed in the zinc-treated group; this was consistent with Zhao et al. (2010), who reported a significant increase in oxidative damage and reduced Nrf2 expression in zinc-deficient mice, and Cortese et al. (2008), who stated that zinc can protect endothelial cells from hydrogen peroxide by promoting glutathione production in a Nrf2-dependent manner.

Pointing to the immune response, it is recognized that *T. spiralis* induces a complex Th1/Th2 immune response (Ding et al. 2017), with upregulation of IFN- γ and IL-12 at the early stage of infection, as well as IL-4, IL-10, and IL-13 through the muscle stage (Yu et al. 2013). Nevertheless, *T. spiralis* can suppress Th1 cells and direct the immune response toward Th2 cells, or Tregs (Sofronic et al. 2015; Wang et al. 2020), which are essential for the parasite and the host's survival (Everts et al. 2010).

Concerning the present work, serum cytokine assays revealed an increase in Th1 (IL12) and Th2 (IL-10) cytokines levels in the infected control group at days 7 and 35 dpi compared to the non-infected control group, in harmony with the intestinal and muscular phases of infection, respectively. Similar findings were reported by Aranzamendi et al. (2012), Kang et al. (2012), and Ding et al. (2017).

Regarding the treated groups, a significantly higher level of IL-12 and lower levels of IL-10 were noted when compared to the infected control group. However, zinc seemed to be a more potent stimulator of Th1 cytokines in both phases of infection than RSV, in which Th1 stimulation was more evident during the muscle phase. Since Th1 and Th2 lymphocytes perform different functions to maintain a balanced immune response (Baltaci and Mogulkoc 2012; Koyasu and Moro 2011), our result denotes that both RSV and zinc have restored this disrupted balance.

The immunomodulatory effects of RSV, both in vivo and in vitro, had previously been emphasized. Resveratrol maintains a balanced immunity through the regulation of immune cells and pro-inflammatory cytokines, and the synthesis and expression of immune cells genes (Isabela et al. 2022). Furthermore, RSV was reported to inhibit nod-like receptor pyrin domain-containing 3 (NLRP-3) activation (Chang et al. 2014). Jin et al. (2020) reported that IL-10 was significantly decreased in the absence of NLRP3, suggesting that these molecules play an important role in host defenses against *T. spiralis* by promoting the Th2 and Treg responses. Also, our findings are consistent with several studies that reported the crucial role of zinc in maintaining the balance between different T-cell subsets and in driving the immune response towards the Th1 type (Fraker et al. 2000; Foster and Samman 2012; Haase and Rink 2014; Bonaventura et al. 2015).

It was reported that zinc deficiency disturbs cellular immunity via decreased production of Th1 cytokines and decreased DNA-binding activity of T-bet, which is a key transcription factor for Th1 cytokine gene expression (Bao et al. 2011). Additionally, zinc supplementation enhances the release of IFN- γ , which is the main Th1-stimulating factor (Schroder et al. 2004). Th1 cytokines such as IL-12 and IFN- γ have a significant role in the immunity against *T. spiralis* infection owing to their role in DC maturation (Venturiello et al. 2007). In trichinellosis, during the enteral phase, the host boosts a Th1 immune response mediated by signals from DC and directed at eliminating the parasite (Munoz-Carrillo et al. 2017); however, *Trichinella*-derived molecules can down-regulate the host immune response by interfering with dendritic cell (DC) maturation and signaling (Bella et al. 2017). DC are believed to be one of the main antigen-presenting cells in the intestine (Ding

et al. 2017), essential for eliminating infection, mediating tissue healing against the invading nematode parasites, and maintaining balanced Th1 and Th2 responses as well (Neubert et al. 2014; Gazzinelli-Guimaraes and Nutman 2018; Sorobetea et al. 2018).

Conclusion

We concluded that RSV and zinc can exert a protective effect against oxidant-mediated damage and the destructive impacts of substances elaborated due to the host's defense response during *T. spiralis* infection. They also displayed nematocidal activity in addition to their anti-inflammatory efficacy. Further studies are needed before employing them as a possible natural alternative for trichinellosis treatment.

Financial support. No agency provided a specific grant for the current work.

Competing interest. No conflict of interest.

Ethical standard. The protocol of the current work was accredited by the ethics committee of Faculty of Medicine, Zagazig University (approval number: ZU-IACUC/3/F/341/2022).

References

- Akhtar MJ, Alhadlaq HA, Alshamsan A, Majeed Khan MA, and Ahamed M (2015) Aluminum doping tunes band gap energy level as well as oxidative stress-mediated cytotoxicity of ZnO nanoparticles in MCF-7 cells. *Scientific Reports* 5, 13876. doi:10.1038/srep13876.
- Aranzamendi C, Franssen F, Langelaar M, Franssen F, van der Ley P, van Putten JP, Rutten V, and Pinelli E (2012) *Trichinella spiralis*-secreted products modulate DC functionality and expand regulatory T cells in vitro. *Parasite Immunology* 34(4), 210–223. doi: 10.1111/j.1365-3024.2012.01353.x.
- Aulbach AD and Amuzie CJ (2017) Biomarkers in nonclinical drug development. pp. 447–471 in Faqi AS, *A comprehensive guide to toxicology in nonclinical drug development*. 2nd edn. Boston, Academic Press. doi: 10.1016/B978-0-12-803620-4.00017-7.
- Badri W, Miladi K, Nazari QA, Greige-Gerges H, Fessi H, and Elaissari A (2016) Encapsulation of NSAIDs for inflammation management: overview, progress, challenges, and prospects. *International Journal of Pharmaceutics* 515, 757–773. doi: 10.1016/j.ijpharm.2016.11.002.
- Baltaci AK and Mogulkoc R (2012) Leptin and zinc relation: in regulation of food intake and immunity. *Indian Journal Endocrinology and Metabolism* 16(3), S611–S616. doi: 10.4103/2230-8210.105579.
- Bao B, Prasad AS, Beck FW, Bao GW, Singh T, Ali S, and Sarkar FH (2011) Intracellular free zinc up-regulates IFN-gamma and T-bet essential for Th1 differentiation in Con-A stimulated HUT-78 cells. *Biochemical and Biophysical Research Communications* 407(4), 703–707. doi: 10.1016/j.bbrc.2011.03.084.
- Basyoni MM and El-Sabaa AA (2013) Therapeutic potential of myrrh and ivermectin against experimental *Trichinella spiralis* infection in mice. *The Korean Journal of Parasitology* 51(3), 297–304. doi: 10.3347/kjp.2013.51.3.297.
- Bella CD, Benagiano M, Gennaro M, Gomez-Morales M, Ludovisi A, D'Elisio S, Luchi S, Pozio E, D'Elisio MM, Bruschi F (2017) T-cell clones in human trichinellosis: evidence for a mixed Th1/Th2 response. *Parasite Immunology* 39(3), e12412. doi: 10.1111/pim.12412. PMID: 2553591.
- Bonaventura P, Benedetti G, Albarede F, and Miossec P (2015) Zinc and its role in immunity and inflammation. *Autoimmunity Reviews* 14(4), 277–285. doi: 10.1016/j.autrev.2014.11.008.
- Brancaccio P, Maffulli N, and Limongelli FM (2007) Creatine kinase monitoring in sport medicine. *British Medical Bulletin* 81(82), 209–230. doi: 10.1093/bmb/ldm014.
- Bruno F, Castelli G, Vitale F, Catanzaro S, Badaco VV, Roberti M, Colomba C, Cascio A, and Tolomeo M (2021) Antiparasitic effect of stilbene and

- terphenyl compounds against *Trypanosoma cruzi* Parasites. *Pharmaceuticals* **14**, 1199. doi: 10.3390/ph14111199.
- Bruschi F and Chiumiento L** (2011) *Trichinella* inflammatory myopathy: host or parasite strategy? *Parasites & Vectors* **4**, 42. doi: 10.1186/1756-3305-4-42.
- Chang YP, Ka SM., Hsu WH, Chen A, Chao LK, Lin CC, Hsieh CC, Chen MC, Chiu HW, Ho CL, Chiu YC, Liu ML, Hua KF** (2014) Resveratrol inhibits NLRP3 inflammasome activation by preserving mitochondrial integrity and augmenting autophagy. *Journal of Cellular Physiology* **230**(7), 1567–1579. doi: 10.1002/jcp.24903.
- Chedea VS, Vicas SI, Sticozzi C, Pessina F, Frosini M, Maioli E, and Valacchi G** (2017) Resveratrol: from diet to topical usage. *Food & Function* **8**(11), 3879–3892. doi: 10.1039/c7fo01086a.
- Chen QW, Dong K, Qin HX, Yang YK, He JL, Li J, Zheng ZW, Chen DL, and Chen JP** (2019) Direct and indirect inhibition effects of resveratrol against *Toxoplasma gondii* tachyzoites in vitro. *Antimicrobial Agents and Chemotherapy* **63**, e01233–18. doi: 10.1128/AAC.01233-18.
- Chiumiento L and Bruschi F** (2009) Enzymatic antioxidant systems in helminth parasites. *Parasitology Research* **105**(3), 593–603. doi: 10.1007/s00436-009-1483-0.
- Chu KB, Lee HA, Kang HJ, Moon EK, and Quan FS** (2020) Preliminary *Trichinella spiralis* infection ameliorates subsequent Rsv infection-induced inflammatory response. *Cells* **9**(5), 1314. doi: 10.3390/cells9051314.
- Cortese MM, Suschek CV, Wetzel W, Kröncke KD and Kolb-Bachofen V** (2008) Zinc protects endothelial cells from hydrogen peroxide via Nrf2-dependent stimulation of glutathione biosynthesis. *Free Radical Biology and Medicine* **44**(12), 2002–2012. doi: 10.1016/j.freeradbiomed.2008.02.013. PMID: 18355458.
- De Sá Coutinho D, Pacheco M, Frozza R, and Bernardi A** (2018) Anti-inflammatory effects of resveratrol: mechanistic insights. *International Journal of Molecular Sciences* **19**(6), 1812. doi: 10.3390/ijms19061812.
- Denham DA** (1965) Studies with methyridine and *Trichinella spiralis*. I. Effect upon the intestinal phase in mice. *Experimental Parasitology* **17**(1), 10–14. doi: 10.1016/0014-4894(65)90003-2.
- Ding J, Bai X, Wang X, Shi H, Cai X, Luo X, Liu M, and Liu X** (2017) Immune cell responses and cytokine profile in intestines of mice infected with *Trichinella spiralis*. *Frontiers in Microbiology* **8**, 2069. doi: 10.3389/fmicb.2017.02069.
- Donnelly LE, Newton R, Kennedy GE, Fenwick PS, Leung RH, Ito K, Russell RE, and Barnes PJ** (2004) Anti-inflammatory effects of resveratrol in lung epithelial cells: molecular mechanisms. *American Journal of Physiology-Lung Cellular and Molecular Physiology* **287**(4), 774–783. doi: 10.1152/ajplung.00110.2004.
- Dorostkar R, Ghalavand M, Nazarizadeh A, Tat M, and Hashemzadeh M** (2017) Anthelmintic effects of zinc oxide and iron oxide nanoparticles against *Toxocara vitulorum*. *International Nano Letters* **7**, 157–164. doi: 10.1007/s40089-016-0198-3.
- Dunn IJ and Wright KA** (1985) Cell injury caused by *T. spiralis* in the mucosal epithelium of B10A mice. *Journal of Parasitology* **71**(6), 757–766.
- Eissa FM, Eassa AH, Zalat RS, Negm MS, and Elmallawany MA** (2022) Potential therapeutic effect of platelet-rich plasma and albendazole on the muscular phase of experimental *Trichinella spiralis* infection. *Food and Waterborne Parasitology* **28**, e00180.
- Elgendy DI, Othman AA, Hasby Saad MA, Soliman NA, and Mwafy SE** (2020) Resveratrol reduced oxidative damage and inflammation in mice infected with *Trichinella spiralis*. *Journal of Helminthology* **94**, e140, 1–10. doi: 10.1017/S0022149X20000206.
- Erben U, Loddenkemper C, Doerfel K, Spieckermann S, Haller D, Heimesaat MM, Zeitz M, Siegmund B, and Kühl AA** (2014) A guide to histomorphological evaluation of intestinal inflammation in mouse models. *International Journal of Clinical and Experimental Pathology* **7**(8), 4557.
- Everts B, Smits HH, Hokke CH, and Yazdanbakhsh M** (2010) Helminths and dendritic cells: sensing and regulating via pattern recognition receptors, Th2 and Treg responses. *European Journal of Immunology* **40**, 1525–1537. doi: 10.1002/eji.200940109.
- Fañcony C, Soares A, Lavinha, J, and Brito M** (2022) Zinc deficiency interacts with intestinal/urogenital parasites in the pathway to anemia in preschool children, Bengo–Angola. *Nutrients* **14**, 1392. doi: 10.3390/nu14071392.
- Farkhondeh T, Folgado SL, Pourbagher-Shahri AM, Ashrafzadeh M, and Samarghandian S** (2020) The therapeutic effect of resveratrol: focusing on the Nrf2 signaling pathway. *Biomedicine & Pharmacotherapy* **127**, 110234. doi: 10.1016/j.biopha.2020.110234.
- Feldman AT and Wolfe D** (2014) Tissue processing and hematoxylin and eosin staining. *Methods in Molecular Biology* **1180**, 31–43. doi:10.1007/978-1-4939-1050-2_3.
- Ferreira C, Soares DC, do Nascimento MTC, Pinto-da-Silva LH, Sarzedas CG, Tinoco LW, and Saraiva EM** (2014) Resveratrol is active against *Leishmania amazonensis*: in vitro effect of its association with amphotericin B. *Antimicrobial Agents and Chemotherapy* **58**, 6197–6208. doi: 10.1128/AAC.00093-14.
- Foster M and Samman S** (2012) Zinc and regulation of inflammatory cytokines: implications for cardiometabolic disease. *Nutrients* **4**(7), 676–694. doi: 10.3390/nu4070676.
- Fraker PJ, King LE, Laakko T, and Vollmer TL** (2000) The dynamic link between the integrity of the immune system and zinc status. *Journal of Nutrition* **130**(5S), 1399S–406S. doi: 10.1093/jn/130.5.1399S.
- Gabrashanska M, Petkova S, and Teodorova SE** (2019) The antioxidant status in *Trichinella Spiralis*-infected rats, improved by Selenium supplementation. *Open Journal of Chemistry* **5**(1), 001–008. doi: 10.17352/ojc.000010.
- Gabrashanska M, Teodorova S, and Anisimova M** (2008) Oxidative-antioxidant status of *Fasciola hepatica*-infected rats supplemented with zinc. A mathematical model for zinc bioaccumulation and host growth. *Parasitology Research* **4**, 69–78. doi 10.1007/s00436-008-1160-8.
- Gang SS and Hallem EA** (2016) Mechanisms of host seeking by parasitic nematodes. *Molecular and Biochemical Parasitology* **208**(1), 23–32. doi: 10.1016/j.molbiopara.2016.05.007.
- Gazzinelli-Guimaraes PH and Nutman TB** (2018) Helminth parasites and immune regulation. *F1000Research* **7**(F1000 Faculty Rev),1685. doi: 10.12688/f1000research.15596.1.
- Giri BR and Roy B** (2015) Resveratrol- and α -viniferin-induced alterations of acetylcholinesterase and nitric oxide synthase in *Raillietina echinobothrida*. *Parasitology Research* **114**, 3775–3781. doi: 10.1007/s00436-015-4607-8.
- Gouveia, MJ, Brindley PJ, Azevedo C, Gärtner F, da Costa JM, and Vale N** (2019) The antioxidants resveratrol and N-acetylcysteine enhance anthelmintic activity of praziquantel and artesunate against *Schistosoma mansoni*. *Parasites & Vectors* **12**(1), 309. doi: 10.1186/s13071-019-3566-9.
- Haase H and Rink L** (2014) Multiple impacts of zinc on immune function. *Metallomics* **6**(7), 1175–1180. doi: 10.1039/C3MT00353A.
- Hamed AM, Abdel-Shafi IR, Elsayed MD, Mahfoz AM, Tawfeek SE, and Abdeltawab MS** (2022) Investigation of the effect of curcumin on oxidative stress, local inflammatory response, COX-2 expression, and microvessel density in *Trichinella spiralis* induced enteritis, myositis and myocarditis in mice. *Helminthologia* **59**(1), 18–36. doi: 10.2478/helm-2022-0002.
- Hassan MH, Abd El-Rahman EM, Abd El-Hamed EF, Abdel Fattah AS, Harb OA, Mohamed SA, and Sarhan MH** (2021a) The impact of nitazoxanide loaded on solid lipid nanoparticles on experimental trichinellosis. *Gazagiz University Medical Journal* **27**(6), 1074–1084. doi: 10.21608/zumj.2019.16531.1480.
- Hassan A, Ramdan M, SFA O, and Elkabawy L** (2021b) In vitro anthelmintic effects of iron oxide and zinc oxide nanoparticles against *Fasciola* Spp. in Dakhla Oasis, Egypt. *Benha Veterinary Medical Journal* **41**(1), 144–147. doi: 10.21608/bvmj.2021.83038.1442.
- Hood MI and Skaar EP** (2012) Nutritional immunity: transition metals at the pathogen–host interface. *Nature Reviews Genetics* **10**(8), 525–537. doi: 10.1038/nrmicro2836.
- Hosui A, Kimura E, Abe S, Tanimoto T, Onishi K, Kusumoto Y, Sueyoshi Y, Matsumoto K, Hirao M, Yamada T, and Hiramatsu N** (2018) Long-term zinc supplementation improves liver function and decreases the risk of developing hepatocellular carcinoma. *Nutrients* **10**, 1955. doi: 10.3390/nu10121955.
- Hsu YJ, Ho CS, Lee MC, Ho CS, Huang CC, and Kan NW** (2020) Protective effects of resveratrol supplementation on contusion induced muscle injury. *International Journal of Medical Sciences* **17**(1), 53–62. doi: 10.7150/ijms.35977.
- Huang, CC, Lee MC, Ho CS, Hsu YJ, Ho CC, and Kan NW** (2021) Protective and recovery effects of resveratrol supplementation on exercise performance and muscle damage following acute plyometric exercise. *Nutrients* **13**(9), 3217. doi: 10.3390/nu13093217.

- Hughes S and Kelly P (2006) Interaction of malnutrition and immune impairment, with specific reference to immunity against parasites. *Parasite Immunology* **28**(11), 577–588. doi: 10.1111/j.1365-3024.2006.00897.x.
- Isabela BM, Ana JF, Anne KD, Giulia EO, Isabella MB, Maria LC, Nathalia Del Vecchio FB, Yasmin CP and Cristiane T Silva (2022) Therapeutic uses of resveratrol compound in Chagas disease: a literature review. *Biomedical Journal of Scientific & Technical Research* **42**(2), BJSTR. MS.ID.006738. doi: 10.26717/BJSTR.2022.42.006738.
- Ivanov D, Dilcheva V, Felkova S, Nanev V, Cabrashanska M, and Ermakov V (2014) Zinc supplementation and *Trichinella spiralis* infection in mice. *Ecologica* **21**(76), 737–740.
- Jaros M, Olbert M, Wyszogrodzka G, Mlyniec K, and Librowski T (2017) Antioxidant and anti-inflammatory effects of zinc. Zinc-dependent NF- κ B signaling. *Inflammopharmacology* **25**(1), 11–24. doi: 10.1007/s10787-017-0309-4.
- Jia R, Li Y, Cao L, Du J, Zheng T, Qian H, Gu Z, Jeney G, Xu P and Yin G (2019) Antioxidative, anti-inflammatory and hepatoprotective effects of resveratrol on oxidative stress-induced liver damage in tilapia (*Oreochromis niloticus*). *Comparative Biochemistry and Physiology Part C: Toxicology and Pharmacology* **215**, 56–66. doi: 10.1016/j.cbpc.2018.10.002.
- Jiang P, Zhang X, Wang LA, Han LH, Yang M, Duan JY, Sun GG, Qi X, Liu RD, Wang ZQ, and Cui J (2016) Survey of *Trichinella* infection from domestic pigs in the historical endemic areas of Henan province, central China. *Parasitology Research* **115**(12), 4707–4709. doi: 10.1007/s00436-016-5240-x.
- Jin X, Bai X, Yang Y, Ding J, Shi H, Fu B, Boireau P, Liu M, and Liu X (2020) NLRP3 played a role in *Trichinella spiralis*-triggered Th2 and regulatory T cells response. *Veterinary Research* **51**(1), 107. doi: 10.1186/s13567-020-00829-2.
- Jin X, Bai X, Zhao Y, Dong Z, Pang J, Liu M, and Liu X (2021) Nrf2 participates in M2 polarization by *Trichinella spiralis* to alleviate TNBS-induced colitis in mice. *Frontiers in Immunology* **12**, 698494. doi: 10.3389/fimmu.2021.698494.
- Kang SA, Cho MK, Park MK, Kim DH, Hong YC, Lee YS, Cha HJ, Ock MS, and Yu HS (2012) Alteration of helper T-cell related cytokine production in splenocytes during *Trichinella spiralis* infection. *Veterinary Parasitology* **186** (3–4), 319–327. doi: 10.1016/j.vetpar.2011.12.002.
- Kazemzadeh H, Mohammad F, and Mohammad F (2014) Evaluating expression of oxidative stress genes in response to *Trichinella spiralis* infection. *Indian Journal of Scientific Research* **5**(1), 305–309.
- Kedzierski L, Curtis JM, Kaminska M, Jodynis-Liebert J, and Murias M (2007) In vitro antileishmanial activity of resveratrol and its hydroxylated analogues against *Leishmania major* promastigotes and amastigotes. *Parasitology Research* **102**(1), 91–97. doi: 10.1007/s00436-007-0729-y.
- Khan WI (2008) Physiological changes in the gastrointestinal tract and host protective immunity: learning from the mouse-*T. spiralis* model. *Parasitology* **135**(6), 671–682. doi: 10.1017/S0031182008004381.
- Khan YA, Singh BR, Ullah R, Shoeb M, Naqvi AH, and Abidi SMA (2015) Anthelmintic effect of biocompatible zinc oxide nanoparticles (ZnO NPs) on *Gigantocotyle explanatum*, a neglected parasite of Indian water buffalo. *PLoS ONE* **10**(7), e0133086. doi: 10.1371/journal.pone.
- Khanam S (2018) Impact of zinc on immune response. *Current Research in Immunology* **2**(1), 103.
- Khashan KS, Sulaiman GM, Hussain SA, Marzoog TR, and Jabir MS (2020) Synthesis, characterization and evaluation of anti-bacterial, anti-parasitic and anti-cancer activities of aluminum-doped zinc oxide nanoparticle. *Journal of Inorganic and Organometallic Polymers and Materials* **30**, 3677–3693. doi: 10.1007/s10904-020-01522-9.
- Kociecka W (2000) Trichinellosis: human disease, diagnosis and treatment. *Veterinary Parasitology* **93**, 365–383. doi: 10.1016/S0304-4017(00)00352-6.
- Koracevic D, Koracevic G, Djordjevic V, Andrejevic S, and Cosic V (2001) Method for the measurement of antioxidant activity in human fluids. *Journal of Clinical Pathology* **54**(5), 356–361. doi: 10.1136/jcp.54.5.356.
- Koyasu S and Moro K (2011) Type 2 innate immune responses and the natural helper cell. *Immunology* **132**(4), 475–481. doi: 10.1111/j.1365-2567.2011.03413.x.
- Kunnumakkara AB, Sailo BL, Banik K, Harsha C, Prasad S, Gupta SC, Bharti AC, and Aggarwal BB (2018) Chronic diseases, inflammation, and spices: how are they linked? *Journal of Translational Medicine* **16**, 14. doi: 10.1186/s12967-018-1381-2.
- Lamas J, Morais P, Arranz JA, Sanmartín ML, Orallo F, and Leiro J (2009) Resveratrol promotes an inhibitory effect on the turbot scuticociliate parasite *Philasterides dicentrarchi* by mechanisms related to cellular detoxification. *Veterinary Parasitology* **161**(3–4), 307–315. doi: 10.1016/j.vetpar.2008.12.025.
- Lee SH, Kim SS, Lee DH, Kim AR, and Quan FS (2016) Evaluation of protective efficacy induced by virus-like particles containing a *Trichinella spiralis* excretory-secretory (ES) protein in mice. *Parasites & Vectors* **9**, 384. doi: 10.1186/s13071-016-1662-7.
- Leiro J, Cano E, Ubeira FM, Orallo F, and Sanmartín ML (2004) In vitro effects of resveratrol on the viability and infectivity of the microsporidian *Encephalitozoon cuniculi*. *Antimicrobial Agents and Chemotherapy* **48**(7), 2497–2501. doi: 10.1128/AAC.48.7.2497-2501.2004.
- Leonard SS, Xia C, Jiang BH, Stinefelt B, Klandorf H, Harris GK, and Shi X (2003) Resveratrol scavenges reactive oxygen species and effects radical-induced cellular responses. *Biochemical and Biophysical Research Communications* **309**(4), 1017–1026. doi: 10.1016/j.bbrc.2003.08.105.
- Li H, Qiu D, Yuan Y, Wang X, Wu F, Yang H, Wang S, Ma M, Qian Y, Zhan B, and Yang X (2022) *Trichinella spiralis* cystatin alleviates polymicrobial sepsis through activating regulatory macrophages. *International Immunopharmacology* **109**, 108907. doi: 10.1016/j.intimp.2022.108907.
- Malaguarnera L (2019) Influence of resveratrol on the immune response. *Nutrients* **11**(5), 946. doi: 10.3390/nu11050946.
- Maldonado E, Rojas D A, Morales S, Miralles V and Solari A. (2020) Dual and opposite roles of reactive oxygen species (ROS) in Chagas disease: beneficial on the pathogen and harmful on the host. *Oxidative Medicine and Cellular Longevity* **2020**(5), 117. doi: 10.1155/2020/8867701.
- Malyar, RM, Li H, Liu D, Abdulrahim Y, Farid RA, Gan F, and Chen X (2020) Selenium/zinc-enriched probiotics improve serum enzyme activity, antioxidant ability, inflammatory factors and related gene expression of Wistar rats inflated under heat stress. *Life Sciences* **117464**. doi: 10.1016/j.lfs.2020.117464.
- Marreiro DN, Cruz KJC, Morais JB, Besserra JB, Severo JS, and de Oliveira AR (2017) Zinc and oxidative stress: current mechanisms. *Antioxidants (Basel)* **6**(2), 24. doi: 10.3390/antiox6020024.
- Mido S, Fath EM, Farid AS, Nonaka N, Oku Y, and Horii Y (2012) *Trichinella spiralis*: infection changes serum paraoxonase-1 levels, lipid profile, and oxidative status in rats. *Experimental Parasitology* **131**(2), 190–194. doi: 10.1016/j.exppara.2012.03.023.
- Morsy K, Fahmy S, Mohamed A, Ali S, El-Garhy M, and Shazly M (2019) Optimizing and evaluating the antihelminthic activity of the biocompatible zinc oxide nanoparticles against the ascaridid nematode, *Parascaris equorum* in vitro. *Acta Parasitologica* **64**, 873–886. doi: 10.2478/s11686-019-00111-2.
- Munn L (2017) Cancer and inflammation. *Wiley Interdisciplinary Reviews: Systems Biology and Medicine* **9**(2), doi: 10.1002/wsbm.1370.
- Munoz-Carrillo JL, Contreras-Cordero JF, Munoz-Lopez JL, Maldonado-Tapia CH, Munoz-Escobedo JJ, and Moreno-Garcia MA (2017) Resiniferatoxin modulates the Th1 immune response and protects the host during intestinal nematode infection. *Parasite Immunology* **39**(9), e12448. doi: 10.1111/pim.12448.39:e12448.
- Neubert K, Lehmann C, Heger L, Baranska A, Staedtler AM, Buchholz VR, Yamazaki S, Heidkamp GF, Eissing N, Zebroski H, Nussenzweig MC, Nimmerjahn F and Dudziak D (2014) Antigen delivery to CD11c+CD8– dendritic cells induces protective immune responses against experimental melanoma in mice in vivo. *Journal of Immunology* **192**, 5830–5838. doi: 10.4049/jimmunol.1300975.
- Ozkoc S, Tuncay S, Delibas SB, and Akisu C (2009) In vitro effects of resveratrol on *T. spiralis*. *Parasitology Research* **105**(4), 1139–1143. doi: 10.1007/s00436-009-1533-7.
- Pais-Morales J, Betanzos A, García-Rivera G, Chávez-Munguía B, Shibayama M, and Orozco E (2016) Resveratrol induces apoptosis-like death and prevents in vitro and in vivo virulence of *Entamoeba histolytica*. *PLoS One* **11**, e0146287. doi: 10.1371/journal.pone.0146287.
- Pivoto FL, Torbitz VD, Aires AR, da Rocha JF, Severo MM, Grandó TH, Peiter M, Moresco RN, da Rocha JB, and Leal ML (2015) Oxidative stress by *Haemonchus contortus* in lambs: influence of treatment with zinc edetate. *Research in Veterinary Science* **102**, 22–24. doi: 10.1016/j.rvsc.2015.07.001.

- Prasad AS (2009) Zinc: role in immunity, oxidative stress and chronic inflammation. *Current Opinion in Clinical Nutrition & Metabolic Care* **12**(6), 646–652. doi: [10.1097/MCO.0b013e3283312956](https://doi.org/10.1097/MCO.0b013e3283312956).
- Prasad AS and Bao B (2019) Molecular mechanisms of zinc as a pro-antioxidant mediator: clinical therapeutic implications. *Antioxidants* **8**, 164. doi: [10.3390/antiox8060164](https://doi.org/10.3390/antiox8060164).
- Robb EL, Page MM, Wiens BE, and Stuart JA (2008) Molecular mechanisms of oxidative stress resistance induced by resveratrol: specific and progressive induction of MnSOD. *Biochemical and Biophysical Research Communications* **367**(2), 406–412. doi: [10.1016/j.bbrc.2007.12.138](https://doi.org/10.1016/j.bbrc.2007.12.138).
- Rubiolo JA, Mithieux G, and Vega FV (2008) Resveratrol protects primary rat hepatocytes against oxidative stress damage: activation of the Nrf2 transcription factor and augmented activities of antioxidant enzymes. *European Journal of Pharmacology* **591**(1–3), 66–72. doi: [10.1016/j.ejphar.2008.06.067](https://doi.org/10.1016/j.ejphar.2008.06.067).
- Saber S, Khalil RM, Abdo WS, Nassif D, and El-Ahwany E (2019) Olmesartan ameliorates chemically induced ulcerative colitis in rats via modulating NFκB and Nrf-2/HO-1 signaling crosstalk. *Toxicology and Applied Pharmacology* **364**, 120–132. doi: [10.1016/j.taap.2018.12.020](https://doi.org/10.1016/j.taap.2018.12.020).
- Sahin K, Orhan C, Akdemir F, Tuzcu M, Iben C, and Sahin N (2012) Resveratrol protects quail hepatocytes against heat stress: modulation of the Nrf2 transcription factor and heat shock proteins. *Journal of Animal Physiology and Animal Nutrition* **96**(1), 66–74. doi: [10.1111/j.14390396.2010.01123.x](https://doi.org/10.1111/j.14390396.2010.01123.x).
- Schroder K, Hertzog PJ, Ravasi T, and Hume DA (2004) Interferon-gamma: an overview of signals, mechanisms, and functions. *Journal of Leukocyte Biology* **75**(2), 163–189. doi: [10.1189/jlb.0603252](https://doi.org/10.1189/jlb.0603252).
- Shalaby AM, ALbakkosh AM, Shalaby RH, ALabiad MA, ELshamy AM, ALorini M, Jaber FA, and Tawfeek SE (2023) Lemongrass essential oil attenuates perfluorooctane sulfonate-induced jejunal mucosal injury in rat: a histological, immunohistochemical, and biochemical study. *Microscopy and Microanalysis* **29**, 841–857. doi: [10.1093/micmic/ozad009](https://doi.org/10.1093/micmic/ozad009).
- Sofronic-Milosavljevic L, Ilic N, Pinelli E, and Gruden-Movsesijan A (2015) Secretory products of *Trichinella spiralis* muscle larvae and immunomodulation: implication for autoimmune diseases, allergies, and malignancies. *Journal of Immunology Research* **523875**. doi: [10.1155/2015/523875](https://doi.org/10.1155/2015/523875).
- Soliman RH, Ismail OA, Badr MS, and Nasr SM (2017) Resveratrol ameliorates oxidative stress and organ dysfunction in *Schistosoma mansoni* infected mice. *Experimental Parasitology* **174**, 52–58. doi: [10.1016/j.exppara.2017.02.008](https://doi.org/10.1016/j.exppara.2017.02.008).
- Sorobeta D, Svensson-Frej M, and Grecis R (2018) Immunity to gastrointestinal nematode infections. *Mucosal Immunology* **11**, 304–315. doi: [10.1038/mi.2017.113](https://doi.org/10.1038/mi.2017.113).
- Stadler M, Dagne E, and Anke H (1994) Nematicidal activities of two phytoalexins from *Taverniera abyssinica*. *Planta Medica* **60**(6), 550–552. doi: [10.1055/s-2006-959569](https://doi.org/10.1055/s-2006-959569).
- Sun HY, Xiao CF, Cai YC, Chen Y, Wei W, Liu XK, Lv ZL, and Zou Y (2010) Efficient synthesis of natural polyphenolic stilbenes: resveratrol, piceatannol and oxyresveratrol. *Chemical and Pharmaceutical Bulletin* **58**(11), 1492–1496. doi: [10.1248/cpb.58.1492](https://doi.org/10.1248/cpb.58.1492).
- Swilam S, Nasreldin N, Abd-Elrahman S, and Nasr S (2022) Evaluation of clinicopathological alterations in mice experimentally infected with *Trichinella spiralis* and the nematocidal effect of tannic acid and albendazole. *New Vally Veterinary Journal* **2**(1), 16–27. doi: [10.21608/nvbj.2022.141188.1005](https://doi.org/10.21608/nvbj.2022.141188.1005).
- Szkudelska K and Szkudelski T (2010) Resveratrol, obesity, and diabetes. *European Journal of Pharmacology* **635**(3), 1–8. doi: [10.1016/j.ejphar.2010.02.054](https://doi.org/10.1016/j.ejphar.2010.02.054).
- Tanno M, Kuno A, Yano T, Miura T, Hisahara S, Ishikawa S, Shimamoto K, and Horio Y (2010) Induction of manganese superoxide dismutase by nuclear translocation and activation of SIRT1 promotes cell survival in chronic heart failure. *Journal of Biological Chemistry* **285**(11), 8375–8382. doi: [10.1074/jbc.M109.090266](https://doi.org/10.1074/jbc.M109.090266).
- Tolstoj V, Lytvynets A, and Langrova I (2007) Pro-oxidant effects of Mebendazole in albino rats experimentally infected with *Trichinella spiralis*. *Parasitology Research* **100**, 1277–1280. doi: [10.1007/s00436-006-0401-y](https://doi.org/10.1007/s00436-006-0401-y).
- Turkmen R, Birdane YO, Demirel HH, Kabu M, and Ince S (2019) Protective effects of resveratrol on biomarkers of oxidative stress, biochemical and histopathological changes induced by sub-chronic oral glyphosate-based herbicide in rats. *Toxicological Research* **8**(2), 238–245. doi: [10.1039/c8tx00287h](https://doi.org/10.1039/c8tx00287h).
- Ungvari Z, Bagi Z, Recchia F, Sonntag W, Pearson K, de Cabo R, and Csiszar A (2010) Resveratrol confers endothelial protection via activation of the antioxidant transcription factor Nrf2. *American Journal of Physiology-Heart and Circulatory Physiology* **299**(1), H18–H24. doi: [10.1152/ajpheart.00260.2010](https://doi.org/10.1152/ajpheart.00260.2010).
- Váradyová Z, Mravčáková D, Babják M, Bryszak M, Grešáková L, Čobanová K, Kišidayová S, Plachá I, Königová A, Cieslak A, Slusarczyk S, Pecio L, Kowalczyk M, Várady M (2018) Effects of herbal nutraceuticals and/or zinc against *Haemonchus contortus* in lambs experimentally infected. *BMC Veterinary Research* **14**, 78. doi: [10.1186/s12917-018-1405-4](https://doi.org/10.1186/s12917-018-1405-4).
- Venturiello SM, Verzoletti ML, Costantino S, Forastiero MA, and Roux ME (2007) Early pulmonary response in rats infected with *Trichinella spiralis*. *Parasitology* **134**(2), 281–288. doi: [10.1017/S0031182006001454](https://doi.org/10.1017/S0031182006001454).
- Wakelin D and Lloyd M (1976) Immunity to primary and challenge infection of *T. spiralis* in mice a re-examination of conventional parameters. *Parasitology* **72**(2), 173–182. doi: [10.1017/s0031182000048472](https://doi.org/10.1017/s0031182000048472).
- Wang N, Bai X, Tang B, Yang Y, Wang X, Zhu H, Luo X, Yan H, Jia H, Liu M, and Liu X (2020) Primary characterization of the immune response in pigs infected with *Trichinella spiralis*. *Veterinary Research* **51**, 17. doi: [10.1186/s13567-020-0741-0](https://doi.org/10.1186/s13567-020-0741-0).
- Wang Q, Rosa BA, Jasmer DP, and Mitreva M (2015) Pan-Nematoda transcriptomic elucidation of essential intestinal functions and therapeutic targets with broad potential. *EBioMedicine* **2**(9), 1079–1089. doi: [10.1016/j.ebiom.2015.07.030](https://doi.org/10.1016/j.ebiom.2015.07.030).
- Wang WB, Lai HC, Hsueh PR, Chiou RYY, Lin SB, and Liaw SJ (2006) Inhibition of swarming and virulence factor expression in *Proteus mirabilis* by resveratrol. *Journal of Medical Microbiology* **55**(10), 1313–1321. doi: [10.1099/jmm.0.46661-0](https://doi.org/10.1099/jmm.0.46661-0).
- Wei HJ, Gupta A, Kao WM, Almudallal O, Letterio JJ, and Pareek TK (2018) Nrf2-mediated metabolic reprogramming of tolerogenic dendritic cells is protective against aplastic anemia. *Journal of Autoimmunity* **94**, 33–44. doi: [10.1016/j.jaut.2018.07.005](https://doi.org/10.1016/j.jaut.2018.07.005).
- Wolstenholme AJ, Fairweather I, Prichard R, von Samson Himmelstjerna G, and Sangster NC (2004) Drug resistance in veterinary helminths. *Trends in Parasitology* **20**(10), 469–476.
- Wu Z, Sofronic-Milosavljevic L, Nagano I, and Takahashi Y (2008) *Trichinella spiralis*: nurse cell formation with emphasis on analogy to muscle cell repair. *Parasites & Vectors* **1**(1), 27. doi: [10.1186/1756-3305-1-27](https://doi.org/10.1186/1756-3305-1-27).
- Xiao N (2015) Effects of resveratrol supplementation on oxidative damage and lipid peroxidation induced by strenuous exercise in rats. *Biomolecules & Therapeutics* **23**(4), 374–378. doi: [10.4062/biomolther.2015.015](https://doi.org/10.4062/biomolther.2015.015).
- Xu D, Bai X, Xu J, Wang X, Dong Z, Shi W, Xu F, Li Y, Liu M and Liu X (2021) The immune protection induced by a serine protease from the *Trichinella spiralis* adult against *Trichinella spiralis* infection in pigs. *PLoS Neglected Tropical Diseases* **15**(5), e0009408. doi: [10.1371/journal.pntd.0009408](https://doi.org/10.1371/journal.pntd.0009408).
- Xu J, Wang J, and Wang T (2007) Effects of vitamin E and selenium on the metabolism of free radicals in broilers. *Ying Yong Sheng Xue Bao* **18**(8), 1789–1793.
- Yu YR, Deng MJ, Lu WW, Jia MZ, Wu W, and Qi YF (2013) Systemic cytokine profiles and splenic toll-like receptor expression during *Trichinella spiralis* infection. *Experimental Parasitology* **134**, 92–101. doi: [10.1016/j.exppara.2013.02.014](https://doi.org/10.1016/j.exppara.2013.02.014).
- Zhao Y, Tan Y, Dai J, Li B, Guo L, Cui J, Wang G, Shi X, Zhang X, Mellen N, Li W and Cai L (2010) Exacerbation of diabetes-induced testicular apoptosis by zinc deficiency is most likely associated with oxidative stress, p38 MAPK activation, and p53 activation in mice. *Toxicology Letters* **200**(1–2), 100–106. doi: [10.1016/j.toxlet.2010.11.001](https://doi.org/10.1016/j.toxlet.2010.11.001).