

Central Serous Retinopathy in a Monozygotic Twin-pair

G. H. Jonkers

W., a man aged 36, visited our clinic in February 1958 for recently impaired visual acuity of the right eye. On examination the diagnosis of central serous retinopathy was made (fig. 1). Initially the impairment was not serious. Out-treatment was commenced but not successful, therefore the patient was admitted to hospital and treated with rest, vasodilator drugs and antallergics. The disorder improved gradually and after $\frac{3}{4}$ of a year the vision had improved to 10/10. The only residual effects of the disorder were a few pigment migrations in the macular region. Nine months later (September 1959) his twin brother, A., saw us on account of impaired visual acuity of the left eye, which had been existing for approximately 3 months. Examination revealed that the vision was decreased to 2/10, and the macular region also showed the typical aspect of central serous retinopathy (fig. 2). He was immediately admitted to hospital and similarly treated as his brother, with satisfactory results (vision 8/10).

Central serous retinopathy is a sharply demarcated circular swelling of the retina in the posterior pole of the fundus with the fovea centralis as its centre. The aetiology is unknown. Allergic (hyperergic) reactions and neurovascular lesions due to the influence of unknown noxious factors (infection?) are considered probable, to mention only a few possible explanations. Bennet e. g. (1955) has given an extensive survey of considerations on the aetiology of the disease. The choroid at the site of the disorder is also involved.

Apart from the marked facial resemblance of the two patients (figure 3 and 4) the following findings suggest monozygotism:

- corneal radius of W.: right 8,35 mm.; left 8,32 mm.
- corneal radius of A.: right 8,39 mm.; left 8,34 mm.
- refraction of the normal eye: emmetropic in both subjects.
- settings of the anomaloscope for the normal eye:
W. 16/0-18 (left); A.: 16/0-19 (right).
- Bloodgroup of both patients: O, rhesus factor negative.
- The alar length differs 6 mm.

The etiology of the disorder, which usually has a good prognosis, remained obscure in our patients.

The question arises whether in these two brothers a common external factor might be found of determining importance in the etiology.

They were educated in their parental home from birth till the age of 21, both under the same conditions. They represented a binary unit and were treated correspondingly. They were keen football players. During the occupation W. went to Germany and was finally interned in a prison-camp. In 1946 he married in the Netherlands, where

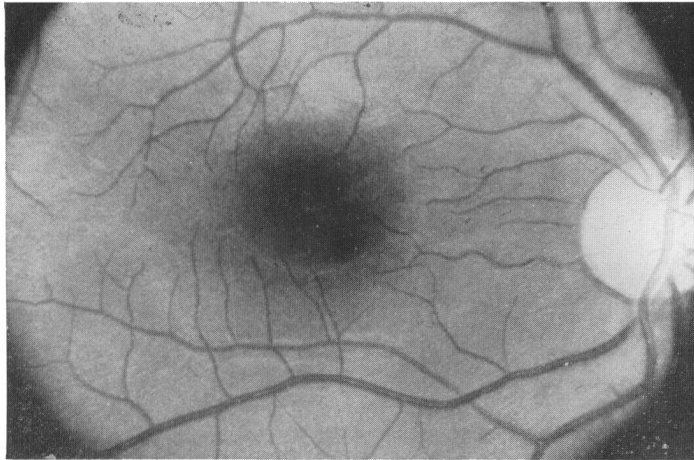


Fig. 1

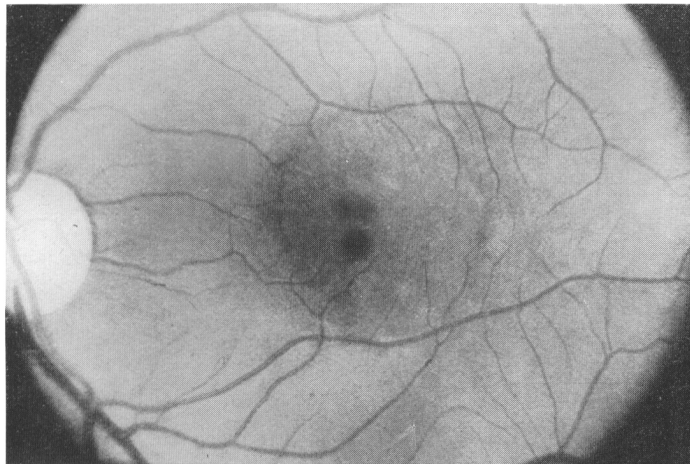


Fig. 2

he led a quiet life as turner, which appears among other things from the fact that he has never had another employer.

In contrast with this, A. led a life of persecution and wandering in the Netherlands during the 1940-1945 period. Afterwards he was a sailor for a short time and

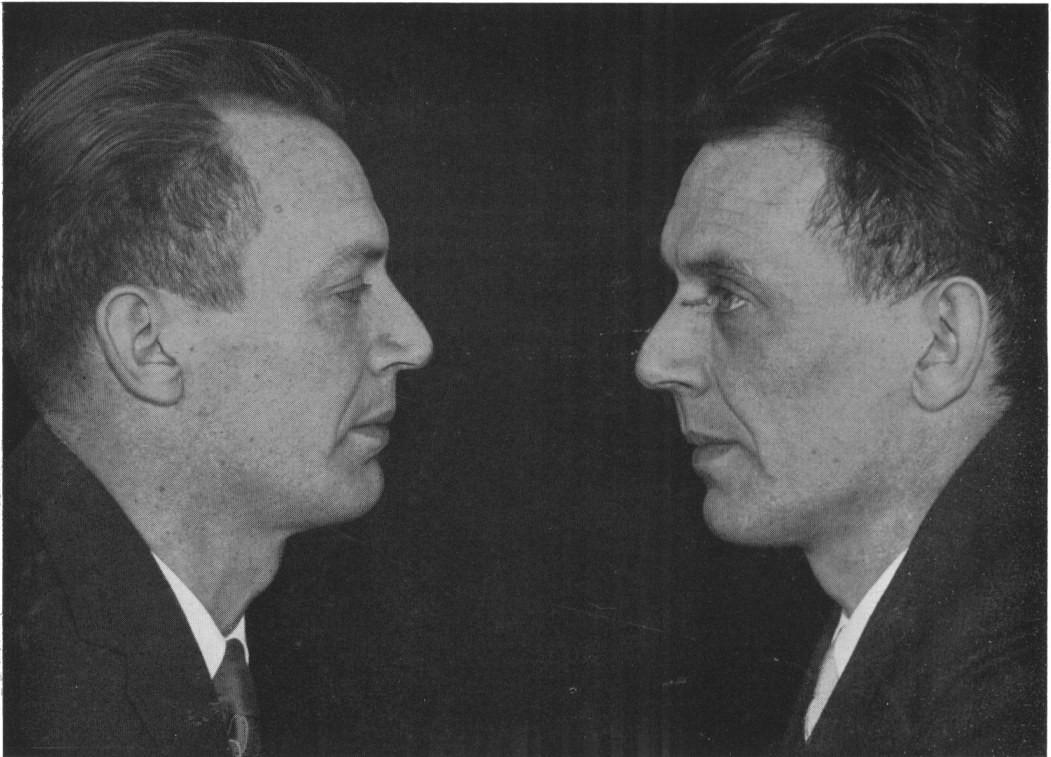

Fig. 3



Fig. 4

he worked in subtropical regions for a considerable period. He returned to the Netherlands in 1958 and has been working for the same employer as his brother since the beginning of 1959.

Neither of them has had any particular diseases. Actually they have always been healthy, except for bad teeth. I did not succeed in demonstrating a distinct stress-factor present in the life of these two happy and cheerful men. They deny the presence of difficulties in their families or occupation. The factor excess of light, which is sometimes held responsible for the development of the disease, can be disregarded in these cases. In my opinion A.'s short stay in the factory where his brother W. has been working for several years is hardly worth considering.

Both were moderate smokers (up to 15 cigarettes daily). In my opinion their life does not supply an obvious etiological factor common to both. The observation of this disorder at practically the same moment in a monozygotic twin-pair supports the theory which considers that constitutional hereditary factors, such as degree and nature of the reaction of the vascular walls to noxious influences-whatever their nature may be- are responsible to a large extent.

Summary

A description is given of the first case in the literature of practically simultaneous occurrence of central serous retinopathy in a monozygotic twin-pair.

References

G. BENNET, Br. J. of Ophthalmology 39, 1955, 605.

RIASSUNTO

Viene descritto il primo caso nella letteratura di una coppia di gemelli MZ colpiti praticamente allo stesso momento da retinopatia sierosa centrale.

RÉSUMÉ

Description du premier cas dans la littérature d'un couple de jumeaux MZ atteints pratiquement simultanément par une rétinopathie sérique centrale.

ZUSAMMENFASSUNG

Der Verfasser beschreibt den ersten Fall in der Literatur eines EZ Zwillingspaars, gleichzeitig mit einer serösen zentraler Retinopathie behaftet.