



Brief Report

Cite this article: Akiba T, Tanaka N, Nakagawa M, Matsui K, Fukunaga H, and Shimizu T (2024) An infant case of autosomal recessive polycystic kidney disease-associated dilated cardiomyopathy-like hypertensive cardiomyopathy diagnosed because of urinary tract infection. *Cardiology in the Young* **34**: 1835–1837. doi: [10.1017/S1047951124025496](https://doi.org/10.1017/S1047951124025496)

Received: 5 March 2024
Revised: 25 April 2024
Accepted: 18 May 2024
First published online: 13 September 2024



Keywords:

Autosomal recessive polycystic kidney disease; dilated cardiomyopathy; heart failure; hypertensive cardiomyopathy; infant

Corresponding author:

N. Tanaka; Email: nobonobo@juntendo.ac.jp

An infant case of autosomal recessive polycystic kidney disease-associated dilated cardiomyopathy-like hypertensive cardiomyopathy diagnosed because of urinary tract infection

Takato Akiba, Noboru Tanaka , Mayu Nakagawa, Kotoko Matsui, Hideo Fukunaga  and Toshiaki Shimizu

Department of Pediatrics, Juntendo University Faculty of Medicine, Tokyo, Japan

Abstract

We report a case of dilated cardiomyopathy-like hypertensive cardiomyopathy (HTN-CM) with polycystic kidney disease without family history when a 3-month-old boy developed bacteraemia secondary to a urinary tract infection. He was later confirmed as having autosomal recessive inheritance due to the proven *PKHD1* gene mutation. The treatment consisted mainly of antihypertensive and anti-heart failure therapies and he was discharged on the 131st day. To prevent the development of heart failure in patients with HTN-CM due to autosomal recessive polycystic kidney disease (ARPKD), it is important to improve the fetal diagnosis rate of ARPKD, detect hypertension early, and strictly control the blood pressure after birth.

Case report

A 3-month-old boy who weighed 6.0 kg was admitted to our hospital with a fever, poor feeding, and a lack of activity. The infant was diagnosed with acute urinary tract infection and was started on intravenous fluid and antibacterial therapy. He had no family history of kidney or cardiac diseases. On the 4th day of hospitalisation, we noticed oedema of the extremities, palpable liver 2.5 cm below the right costal rim, and palpable bilateral kidneys on the back. Vital signs were as follows: temperature, 38.9°C; heart rate, 142 bpm; blood pressure, 128/78 mmHg; and oxygen saturation, 99%. Levine I/VI systolic murmur and gallop rhythm were observed at the left margin of the 4th intercostal sternum. A clinical image of the patient upon admission is shown in Figure 1 (Fig. 1a–e). Chest radiography revealed cardiac enlargement. An electrocardiogram showed sinus tachycardia; the ST was depressed in V₃₋₆, and the R wave was poorly increased in V₅₋₆. Echocardiography revealed an enlarged left ventricular end-diastolic diameter and decreased left ventricular ejection fraction (LVEF). Abdominal ultrasonography revealed bilateral renal enlargement, numerous cysts in the kidney, and mosaic-like and coarse hepatic parenchyma. Laboratory findings are presented in Figure 2. Blood test results showed an elevated B-type natriuretic peptide level (4104 pg/mL), a slightly elevated creatinine level (0.32 mg/dL), and a decreased estimated glomerular filtration rate (60 mL/min/m²). Both blood and urine cultures were positive for *Escherichia coli*. Based on these findings, we diagnosed the patient with heart failure due to hypertensive cardiomyopathy (HTN-CM), autosomal recessive polycystic kidney disease (ARPKD), renal hypertension, renal anaemia, urinary tract infection, and congenital liver fibrosis. *PKHD1* gene analysis revealed two compound heterozygous mutations: c.5912G > C and c.1690C > T.

ARPKD-associated renal hypertension was believed to cause dilated cardiomyopathy (DCM)-like HTN-CM. The treatment consisted mainly of antihypertensive and anti-heart failure therapies. Azilsartan and clonidine hydrochloride were started as antihypertensive therapies with the aim of lowering systolic blood pressure to approximately 100 mmHg, and amlodipine besylate was used as an abortive dose when it was difficult to manage the patient. In the acute phase, dobutamine hydrochloride, olprinone hydrochloride hydrate, and diuretics, including furosemide, spironolactone, and tolvaptan, were used as anti-heart failure therapies, whereas bisoprolol fumarate was started on the 20th day of hospitalisation to slow the heart rate and suppress remodelling. Chest radiography showed improvement in cardiac enlargement, B-type natriuretic peptide level decreased to 10.3 pg/mL, and LVEF improved to 40% (Fig. 3a,b). The patient was discharged on the 131st day.

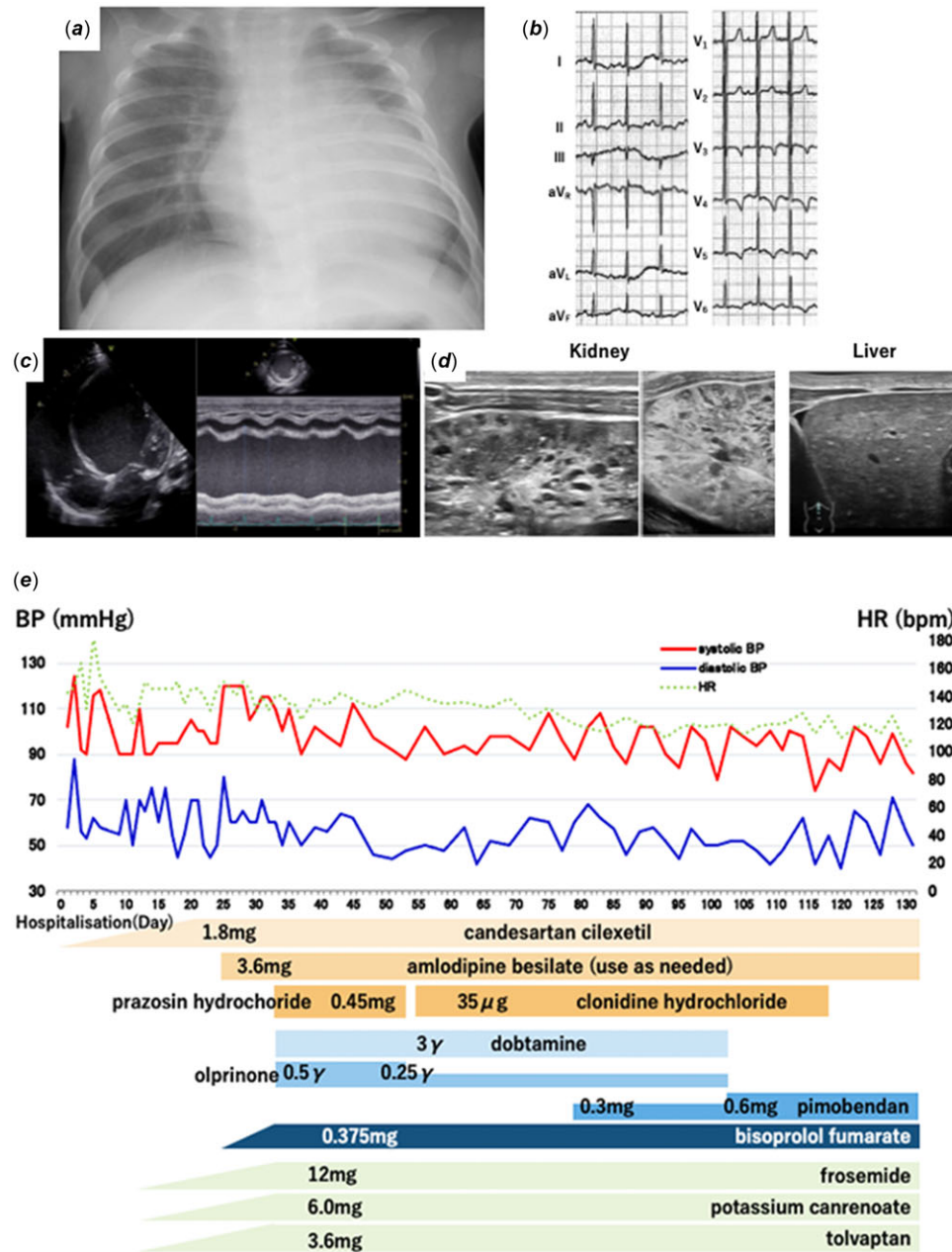


Figure 1. (a) Chest radiography on admission showing cardiac enlargement. (b) Electrocardiogram at rest on admission showing sinus tachycardia; the ST is depressed in V3-6, and the R wave is poorly increased in V5-6. (c) Echocardiography on admission showing a dilatation of left ventricular end-diastolic diameter (44 mm), noticeably decreased left ventricular ejection fraction (16%), and mild mitral regurgitation. (d) Abdominal ultrasound on admission showing bilateral enlargement of the kidneys and numerous small cysts in kidneys. The hepatic parenchyma is mosaic-like and coarse. Shear wave elastography showing increased liver stiffness. (e) Clinical course of the patient.

Discussion

Although children with ARPKD develop concentric left ventricular hypertrophy (LVH) in a significant proportion of cases, no cases of DCM-like HTN-CM in infants have been reported worldwide. Furthermore, previous evidence from rat models of ARPKD has shown a significant temporal relationship between cyst development, hypertension, and LVH.¹⁻³ HTN-CM is often associated with primary histological and functional impairment of the myocardium and damage to other organs, such as blood vessels and kidneys. Almost all cases of ARPKD are complicated by hypertension; however, the onset varies from case to case, and the mechanism of hypertension in ARPKD remains unclear.⁴ As remodelling progresses owing to hypertension, the myocardium

becomes concentric hypertrophied and shows LVH, resulting in heart failure and decreased diastolic function. More severe and prolonged hypertension leads to centrifugal hypertrophy of the myocardium, and progression to DCM-like HTN-CM decreases systolic function.⁵ Therefore, in this case, we believe that severe and prolonged hypertension caused by ARPKD in the early postnatal period led to myocardial remodelling.

Because low-output cardiomyopathy, as in this case, can cause sudden death triggered by infection or other causes, caution should be exercised. ARPKD cysts are difficult to diagnose using fetal echocardiography until the 30th week of life. We hope that the fetal diagnostic rate for ARPKD will improve with the development of fetal echocardiography. To prevent the development of heart

<Blood Cell Count>			<Biochemistry>					
WBC	16,000	/ μ L	AST	28	IU/L	Ferritin	110	ng/mL
RBC	3.89	$\times 10^6$ / μ L	ALT	12	IU/L	<Endocrine>		
Hemoglobin	10.0	g/dL	T-bil	0.84	mg/dL	BNP	4104	pg/mL
Hematocrit	30.0	%	CK	64	IU/L	Aldosteron	47.0	pg/mL
Platelet	22.4	$\times 10^4$ / μ L	Total protein	6.1	g/dL	Renin activity	0.3	ng/mL/h
<Urinalysis>			BUN	14	mg/dL	Adrenalin	0.01	ng/mL
NAG	4.2	IU/L	Creatinine	0.32	mg/dL	Noradrenalin	0.13	ng/mL
β_2 MG	1339	μ g/L	eGFR	60		Dopamine	0.02	ng/mL
VMA	0.9	mg/L	CRP	0.60	mg/dL	TSH	3.79	μ IU/mL
HVA	1.6	mg/day	Na	132	mmol/L	FT ₃	2.4	pg/mL
Urine culture	<i>Escherichia coli</i>		K	4.7	mmol/L	FT ₄	1.3	ng/mL
Blood culture	<i>Escherichia coli</i>		Cl	101	mmol/L			
			Ca	9.3	mg/dL			

Figure 2. Laboratory data on admission. WBC = white blood cell; RBC = red blood cell; NAG = N-acetyl- β -D-glucosaminidase; β_2 MG = β_2 macroglobulin; VMA = vanillylmandelic acid; HMA = homovanillic acid; AST = aspartate aminotransferase; ALT = alanine aminotransferase; T-bil = total bilirubin; CK = creatinine kinase; BUN = blood urea nitrogen; CRP = C-reactive protein.

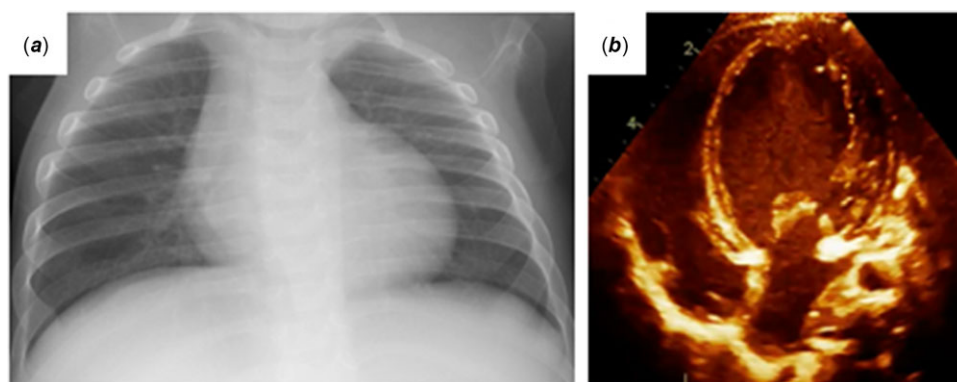


Figure 3. (a) Chest radiography on discharge. (b) Echocardiography on discharge.

failure in patients with HTN-CM due to ARPKD, it is important to improve the fetal diagnosis rate of ARPKD, detect hypertension early, and strictly control the blood pressure after birth.

References

- Phillips JK, Hopwood D, Loxley RA, et al. Temporal relationship between renal cyst development, hypertension and cardiac hypertrophy in a new rat model of autosomal recessive polycystic kidney disease. *Kidney Blood Press Res* 2007; 30: 129–144.
- Chinali M, Lucchetti L, Ricotta A, et al. Cardiac abnormalities in children with autosomal recessive polycystic kidney disease. *Cardiorenal Med* 2019; 9: 180–189.
- Lucchetti L, Chinali M, Emma F, Massella L. Autosomal dominant and autosomal recessive polycystic kidney disease: hypertension and secondary cardiovascular effect in children. *Front Mol Biosci* 2023; 10: 1112727.
- Hartung EA, Guay-Woodford LM. Autosomal recessive polycystic kidney disease: a hepatorenal fibrocystic disorder with pleiotropic effects. *Pediatrics* 2014; 134: e833–e845.
- Ganau A, Devereux RB, Roman MJ, et al. Patterns of left ventricular hypertrophy and geometric remodeling in essential hypertension. *J Am Coll Cardiol* 1992; 19: 1550–1558.