



# Management of prenatally detected vascular rings: a United Kingdom national survey

Trisha V. Vigneswaran<sup>1</sup> , Lindsey E. Hunter<sup>2</sup>, Julene S. Carvalho<sup>3,4,5</sup> and Anna N. Seale<sup>6,7</sup>

## Original Article

**Cite this article:** Vigneswaran TV, Hunter LE, Carvalho JS, and Seale AN (2023) Management of prenatally detected vascular rings: a United Kingdom national survey. *Cardiology in the Young* **33**: 1332–1335. doi: [10.1017/S1047951122002268](https://doi.org/10.1017/S1047951122002268)

Received: 1 April 2022  
Revised: 10 May 2022  
Accepted: 26 June 2022  
First published online: 15 August 2022

### Keywords:

Congenital heart disease; Vascular ring; Prenatal diagnosis

### Author for correspondence:

Dr Trisha V. Vigneswaran MBBS BSc(Hons.) MD(res) MRCPCH, Department of Congenital Heart Disease, Evelina London Children's Hospital, Guy's & St Thomas' NHS Trust, London SE1 7EH, UK.  
E-mail: [Trisha.vigneswaran@gstt.nhs.uk](mailto:Trisha.vigneswaran@gstt.nhs.uk)

<sup>1</sup>Department of Congenital Heart Disease, Evelina London Children's Hospital, Guy's & St. Thomas' NHS Trust, London SE1 7EH, UK; <sup>2</sup>Department of Paediatric Cardiology, Royal Hospital for Children, Glasgow, UK; <sup>3</sup>Brompton Centre for Fetal Cardiology, Royal Brompton Hospital, Sydney Street, London SW3 6NP, UK; <sup>4</sup>Fetal Medicine Unit, St. George's University Hospitals NHS Foundation Trust, London, UK; <sup>5</sup>Cardiovascular Clinical Academic Group, Molecular and Clinical Sciences Research Institute, St. George's University of London, London, UK; <sup>6</sup>Institute of Cardiovascular Sciences, University of Birmingham, Birmingham, UK and <sup>7</sup>Heart Unit, Birmingham Children's Hospital NHS Foundation Trust, Birmingham, UK

### Abstract

**Objective:** To investigate UK variability in prenatal and postnatal management strategy of right aortic arch and double aortic arch (RAA/DAA). **Methods:** Online surveys were sent to senior physicians (consultants) of the National Fetal Cardiology Working Group regarding prenatal diagnosis, counselling, and perinatal management of antenatally diagnosed RAA/DAA and to the British Congenital Cardiovascular Association regarding postnatal management strategies. **Results:** There were 28 prenatal and 90 postnatal surveys completed. Prenatally, there was consensus for potential associated chromosomal/genetic anomalies, but there was variation in the risk quoted. Confidence in defining aortic arch morphology was reported by 43% (12/28) of fetal cardiologists. There was variation in what was felt to be possible symptoms/signs of a compressive vascular ring, postnatal investigation, postnatal management, follow-up duration of asymptomatic patients, and indications for surgical intervention. **Conclusion:** This study has highlighted important areas for future research: improving accuracy of prenatal diagnosis, clarification of potential symptoms, optimal investigation strategies, and indications for surgery.

The United Kingdom Fetal Anomaly Screening Programme (UK-FASP) provides recommendations for screening of all pregnancies at 18–20<sup>+</sup>6 weeks' gestation to identify major anomalies in unborn babies. An update to UK-FASP to assess the great arteries in the upper thorax was introduced in 2015<sup>1</sup> in order to improve the prenatal detection of major cardiac abnormalities which may require early intervention. This routinely acquired, additional view of the upper mediastinum has also led to an increase in the detection of right and double aortic arches (RAA/DAA) prenatally.<sup>2–4</sup> These anomalies can be associated with chromosomal and genetic syndromes and extracardiac anomalies. A DAA and the subtype of a RAA with left ductal ligament encircle the trachea and oesophagus which can lead to symptoms/signs of tracheo-oesophageal compression,<sup>5</sup> but there are no population-based studies to help understand how frequently this develops and how expectant families should be counselled or managed after birth.

### Objective

To investigate variability in prenatal and postnatal management strategy of RAA and DAA in the UK to assist in defining future research questions to provide an evidence base for management.

### Methods

An online questionnaire regarding the prenatal counselling and management of prenatally diagnosed RAA and DAA was distributed between April 2019 and July 2019 to the consultant (senior physician) members of the National Fetal Cardiology Working Group (NFCWG). The NFCWG comprises fetal cardiologists working in all fetal cardiology centres in the UK.

A separate online questionnaire was also distributed to members of the British Congenital Cardiac Association (BCCA) between September 2020 and February 2021. This second questionnaire investigated postnatal management strategies for patients prenatally diagnosed with RAA and DAA from senior physicians working in congenital cardiology, including paediatric cardiologists, cardiothoracic surgeons, paediatricians/neonatologists with a special interest in cardiology, who work in cardiothoracic surgical centres and the cardiac networks across the UK.

For both surveys, the response options for each question included a choice of set answers and a free-text option (supplement 1). Data are presented as counts and percentages, denominators are provided according to the number of responses for each question. Chi-squared test was used to compare responses, and statistical significance was taken to be represented by  $p < 0.05$ .

## Results

### Prenatal survey findings

There were 28 respondents with representation from all 13 centres in the UK with a specialist consultant in fetal cardiology. Most fetal cardiologists (20/28) diagnosed between 10 and 50 new cases of RAA or DAA each year and six fetal cardiologists saw less than 10 cases per year. Confidence in correctly identifying the anatomy of the branching pattern of the aorta and origin of the left subclavian artery on fetal echocardiograms was reported in 12/28 (43%).

During prenatal counselling for a fetus with a RAA, 93% (26/28) of respondents discussed the association with genetic/chromosomal conditions; 30% of respondents quoted  $< 5\%$  association and 47% of respondents gave an association between 5 and 20% of a genetic/chromosomal condition. 7% (2/28) of respondents varied the risk according to the nuchal translucency measurement and associated extracardiac anomalies. Regarding the prenatal management of DAA, whilst 96% (27/28) discussed the potential for genetic/chromosomal conditions, there was acknowledgment that there was no published prenatal data at the time of the questionnaire regarding this specific association.

Thirteen out of 28 (46%) recommended delivery in a hospital with paediatric support, the others giving no specific recommendations.

### Postnatal survey responses

There were 111 respondents of which 21 were incomplete and could not be analysed. All specialist paediatric cardiology centres were represented. Responders comprised consultant-level paediatric cardiologists ( $n = 57$ ), paediatric consultants with expertise in cardiology (PEC) ( $n = 28$ ), neonatologist ( $n = 3$ ), paediatric respiratory specialist ( $n = 1$ ), and one cardiothoracic surgeon. Not all respondents answered all questions. Postnatal outpatient follow-up is undertaken with the paediatric cardiologist or PEC in the vast majority 92% (83/90) of RAA and 90% (81/90) DAA. General paediatricians, neonatologists, respiratory, and ENT specialists performed routine follow-up in the minority of centres.

Table 1 shows the variation in the investigations performed on children following prenatal diagnosis of RAA/DAA and the symptoms/signs which the clinicians felt were associated with compression from a vascular ring. Routine cross-sectional imaging with CT/MRI is undertaken in all symptomatic patients with DAA, with 33% (27/82) respondents performing these investigations irrespective of symptoms. Seven of 88 respondents (8%) performed a CT/MRI in patients with RAA regardless of symptoms. One centre routinely discussed bronchoscopy and CT with all patients with a vascular ring, two further centres discussed routine CT or MRI. Tracheal or oesophageal investigations were not routinely offered by 75% (66/88) respondents for asymptomatic infants with RAA-left arterial duct and 49% (34/70) respondents for DAA.

There was no unifying symptom or sign which was considered to represent a compressive vascular ring although stridor was most

commonly considered to be an indication of compression (Table 1). Follow-up of asymptomatic RAA patients varied, some discharged at first appointment 11% (10/87), but the majority 43% (37/87) monitored patients for 2 years before discharge. The decision for further management varied according to the aortic arch anatomy and position of the arterial duct in 42% (38/90). DAA patients were followed up for longer with 39% (27/70) of respondents reporting that they followed up DAA patients indefinitely.

Decision-making for surgery was reported to involve cardiologists and cardiothoracic surgeons in most units, with airway specialists being routinely involved in decision-making for surgical intervention in 67% (59/86) with RAA and 67% (53/79) with DAA. Criteria for listing for surgical relief of a RAA/DAA are listed in Table 1. There were 19% (17/90) respondents from five different centres that reported all their patients with DAA have surgery irrespective of symptoms.

## Discussion

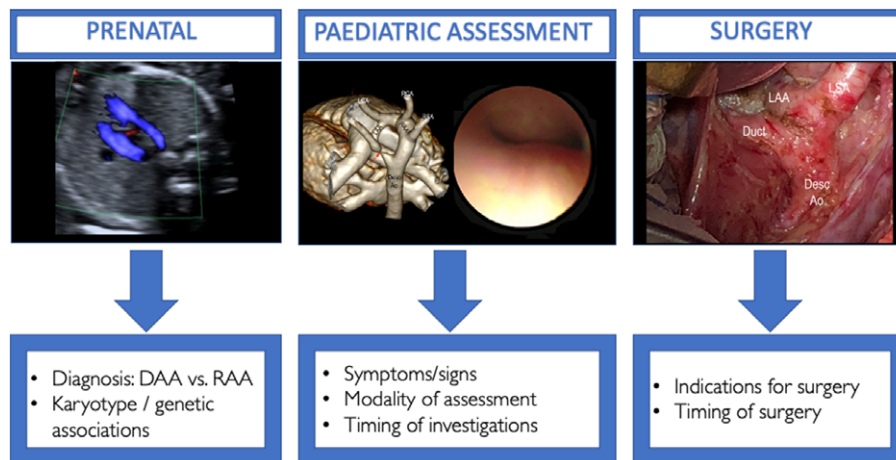
This study highlights the wide variation in the assessment and management of children with a vascular ring in the UK amongst a group of experts in paediatric cardiology. Whilst there has been a large number of cases diagnosed prenatally in the UK for a few years at the time of the survey, most units had not agreed a standardised postnatal pathway for assessment and management. There is no consensus regarding which clinical features may be considered an indication of a compressive vascular ring and necessitate further investigations. Furthermore, postnatal surveillance, investigation strategy, and subsequent management of the cases is variable. In some areas, patients are solely managed by a paediatric cardiologist despite the abnormal cardiovascular anatomy not impacting upon the cardiac status. Surveillance and assessment are undertaken by professionals who understand the vasculature and surgical options, but rarely is this supported by those trained in diseases of the airway or oesophagus which are the structures affected by the vascular ring. The availability of multidisciplinary assessment for prenatally diagnosed cases may accelerate our knowledge and understanding of this new cohort of prenatally diagnosed patients. This survey has also highlighted the challenges of defining symptoms or clinical signs of a vascular ring; there was no single unifying feature which was considered definitive for tracheal or oesophageal compression. Some of these features may be intermittent, subtle, or subjective, such as stridor, wheeze, or poor feeding and some may be considered an overlap of normal such as choking when weaned onto solids and not attributed to the underlying vascular ring. However, astute history taking may reveal the compensatory mechanisms the children have developed to overcome the symptoms, for example chewing food thoroughly to aid swallowing and having been labelled as a 'slow eater'.<sup>6</sup> Furthermore, the threshold for investigation varies amongst units and there is no consensus when to investigate and when to operate in the UK which reflects the opinions of international centres.<sup>7-10</sup>

Five units reported that surgery is usually performed for all cases of DAA regardless of the evolving symptoms and whilst the reason for this strategy was not sought from the respondents, there is much published data to demonstrate that DAA is frequently associated with clinical features of a vascular ring and also that there is a high proportion that are left with secondary tracheomalacia post-operatively,<sup>11</sup> which is thought to be due to longstanding tracheal compression from the DAA.<sup>6,11-16</sup> Three centres offered routine assessment of cases with a RAA and left

**Table 1.** Comparison of assessment and management of RAA and DAA after birth

Question	Variable	RAA	DAA	P value
Initial postnatal investigations in asymptomatic patients	Echocardiogram	79/86 (92%)	70/86 (81%)	0.036
	Karyotype/array CGH	35/86 (41%)	36/86 (42%)	0.9
	CT/MRI	7/86 (8%)	52/86 (60%)	< 0.001
	Bronchoscopy	4/86 (5%)	16/86 (19%)	0.004
Possible clinical features of a compressive vascular ring	Stridor	86/90 (96%)	77/90 (86%)	0.021
	Wheeze / 'asthma'	37/90 (41%)	39/90 (43%)	0.76
	Exertional dyspnoea	37/90 (41%)	44/90 (49%)	0.29
	Recurrent croup	47/90 (52%)	45/90 (50%)	0.71
	Recurrent LRTI	40/90 (44%)	42/90 (47%)	0.76
	Ventilator dependence	41/90 (46%)	49/90 (54%)	0.23
	Choking	71/90 (79%)	67/90 (74%)	0.48
	Dysphagia	80/90 (89%)	71/90 (79%)	0.07
	Poor feeding	57/90 (63%)	54/90 (60%)	0.65
	Faltering weight	44/90 (49%)	42/90 (47%)	0.77
	Do not know	–	14/90 (16%)	–
Investigation of symptomatic patients <sup>§</sup>	CT angiogram	63/86 (73%)	62/86 (72%)	0.86
	Barium swallow	37/86 (43%)	2/86 (2%)	< 0.001
	Bronchoscopy	31/86 (36%)	35/86 (41%)	0.53
	CT or MRI	11/86 (13%)	8/86 (9%)	0.47
	MRI	1/86 (1%)	3/86 (3%)	0.31
	Specialist consult – respiratory/ENT	49/86 (57%)	47/86 (55%)	0.76
	Specialist consult – SALT	14/86 (16%)	17/86 (20%)	0.55
	Specialist consult – general paediatrician	7/86 (8%)	8/86 (9%)	0.79
Criteria for surgery <sup>§</sup>	Respiratory symptoms	78/84 (93%)	60/84 (71%)	< 0.001
	Dysphagia	72/84 (86%)	56/84 (67%)	0.004
	Abnormal imaging*	49/84 (58%)	42/84 (50%)	0.28

\*Indicates CT/MRI/bronchoscopy <sup>§</sup>some questions were not answered by PEC responders as they would discuss with their tertiary team. CGH = comparative genomic hybridisation; ENT = ear nose throat; SALT = speech and language therapist.



**Figure 1.** Graphic outlining key areas for further research at important time points following prenatal diagnosis of right or double aortic arch: prenatal, paediatric, and surgical questions.

ductal ligament in asymptomatic infants. Similarly, the rationale for this approach was not requested, but there are cases reported in the literature where there is a significant degree of tracheal compression in the absence of symptoms/clinical signs<sup>17</sup> and also a persistence of symptoms post-operatively<sup>12,15,16,18,19</sup> which has led to the hypothesis that secondary tracheomalacia could be a result of longstanding compression causing permanent damage or distortion to the tracheal cartilage.<sup>20</sup> In the modern era, vascular ring surgery is a low risk operation<sup>12</sup> and some units chose to investigate and operate early, whereas others pursue a more conservative approach and only undertake surgery when the risk of surgery is deemed to be outweighed by the clinical presentation of the child. The most beneficial approach is not known, but this study has demonstrated the variance in management of cases.

This study highlights some key objectives to plan future research studies which may benefit patients (fig 1). Whilst there is ample data describing the association of RAA with chromosomal/genetic conditions in specialist fetal medicine units,<sup>21</sup> there is limited data regarding these associations in a standard population. For fetuses with DAA there is few published data, suggesting an association lower than that of RAA.<sup>4</sup>

A limitation of many prenatal series of RAA and DAA is the diagnostic accuracy for specific anatomy and this is highlighted in the results of this survey which demonstrated that less than half of fetal cardiologists were confident in their ability to identify the branching pattern of the aortic arch. If the branching pattern of the aortic arch (position of the head and neck arteries) are not sought, then this will lead to cases of a DAA with a small left arch being overlooked and misdiagnosed as a RAA. This may lead to incorrect counselling about the association of chromosomal/genetic conditions and influence prenatal decisions and postnatal management strategy.

## Conclusion

This survey has highlighted key areas which warrant further knowledge and research:

- Accurate prenatal diagnosis
- Defining symptoms/signs/presentations of a vascular ring
- Defining the optimal investigation strategies
- Indications for surgical relief of a vascular ring

Given the large numbers of cases diagnosed each year in the UK, there is ample caseload to conduct well-powered, prospective studies informed by multidisciplinary collaboration to understand these conditions further and inform patient management.

**Supplementary material.** For supplementary material accompanying this paper visit <https://doi.org/10.1017/S1047951122002268>

**Acknowledgements.** We acknowledge the respondents who participated in this study.

**Funding.** The delivery of the survey was supported by the British Congenital Cardiovascular Association (BCCA).

**Conflict of interest.** None.

## References

1. Department of Health. Fetal anomaly screening programme 2015 [Available from: Available at: [https://www.gov.uk/government/uploads/system/uploads/attachment\\_data/file/421650/FASP\\_Standards\\_April\\_2015\\_final\\_2\\_.pdf](https://www.gov.uk/government/uploads/system/uploads/attachment_data/file/421650/FASP_Standards_April_2015_final_2_.pdf).
2. Ctori E, Crucean A, Pinkey B, et al. Morphology of vascular ring arch anomalies influences prognosis and management. In Archives of disease in childhood 2020, [published Online First: 2020/10/28] DOI [10.1136/archdischild-2020-319388](https://doi.org/10.1136/archdischild-2020-319388).
3. Vigneswaran TV, Allan L, Charakida M, et al. Prenatal diagnosis and clinical implications of an apparently isolated right aortic arch. Prenat Diagn 2018; 38: 1055–1061. DOI [10.1002/pd.5388](https://doi.org/10.1002/pd.5388).
4. Vigneswaran TV, Van Poppel MP, Griffiths B, et al. Postnatal impact of a prenatally diagnosed double aortic arch. Archives of disease in childhood 2021 2021; 106: 564–569.
5. Edwards FR. Vascular compression of the trachea and oesophagus. Thorax 1959; 14: 187–200. DOI [10.1136/thx.14.3.187](https://doi.org/10.1136/thx.14.3.187).
6. Worhunsky DJ, Levy BE, Stephens EH, et al. Vascular rings. Semin Pediatr Surg 2021; 30: 151128. DOI [10.1016/j.sempedsurg.2021.151128](https://doi.org/10.1016/j.sempedsurg.2021.151128).
7. Stephens EH, Eltayeb O, Kennedy C, et al. Influence of fetal diagnosis on management of vascular rings. AnnThoracSurg 2022; 113: 630–636. DOI [10.1016/j.athoracsur.2021.01.025](https://doi.org/10.1016/j.athoracsur.2021.01.025).
8. Evans WN, Acherman RJ, Ciccolo ML, et al. Vascular rings and slings: contemporary observations. Prog Pediatr Cardiol 2019; 53: 42–46.
9. Backer CL. The vascular ring decision tree. Eur J Cardio-Thorac Surg 2022; 62: e2ab525. DOI: [10.1093/ejcts/e2ab525](https://doi.org/10.1093/ejcts/e2ab525).
10. Young AA, Hornberger LK, Haberer K, et al. Prenatal detection, comorbidities, and management of vascular rings. AmJCardiol 2019; 123: 1703–1708.
11. Han M-T, Hall DG, Manché A, et al. Double aortic arch causing tracheoesophageal compression. AmJSurg 1993; 165: 628–631.
12. Swarnkar P, Speggorin S, Austin BC, et al. Contemporary surgical outcome and symptomatic relief following vascular ring surgery in children: effect of prenatal diagnosis. Eur J Cardio-thorac Surg.
13. Alsenaidi K, Gurofsky R, Karamlou T, et al. Management and outcomes of double aortic arch in 81 patients. Pediatrics 2006; 118: e1336–e1341.
14. Anand R, Dooley KJ, Williams WH, et al. Follow-up of surgical correction of vascular anomalies causing tracheobronchial compression. Pediatr Cardiol 1994; 15: 58–61.
15. Depypere A, Proesmans M, Cools B, et al. The long-term outcome of an isolated vascular ring - a single-center experience. Pediatr Pulmonol 2019; 54: 2028–2034.
16. Callahan CP, Merritt TC, Canter MW, et al. Symptom persistence after vascular ring repair in children. J Pediatr Surg 2020; 55: 2317–2321.
17. Vigneswaran TV, Kapravelou E, Bell AJ, et al. Correlation of symptoms with bronchoscopic findings in children with a prenatal diagnosis of a right aortic arch and left arterial duct. Pediatr Cardiol 2018; 39: 665–673.
18. Luciano D, Mitchell J, Fraise A, et al. Kommerell diverticulum should be removed in children with vascular ring and aberrant left subclavian artery. AnnThoracSurg 2015; 100: 2293–2297.
19. Francois K, Panzer J, De Groote K, et al. Early and late outcomes after surgical management of congenital vascular rings. Eur J Pediatr 2017; 176: 371–377.
20. Biermann D, Holst T, Huners I, et al. Right aortic arch forming a true vascular ring: a clinical review. Eur J Cardio-thorac Surg, 2021; 60: 1014–1021.
21. D'Antonio F, Khalil A, Zidere V, et al. Fetuses with right aortic arch: a multicenter cohort study and meta-analysis. Ultrasound Obstet Gynecol 2016; 47: 423–432.