

## Knobbly, a new dominant mutation in the mouse that affects embryonic ectoderm organization

By R. J. JACOBS-COHEN,<sup>1</sup> M. SPIEGELMAN, J. C. COOKINGHAM  
AND D. BENNETT

Laboratory of Developmental Genetics, Sloan-Kettering Institute for Cancer  
Research, New York, New York 10021

(Received 12 August 1983 and in revised form 31 October 1983)

### SUMMARY

Knobbly,  $Fu^{Kb}$ , a dominant mutation on chromosome 17 of the mouse, causes a kinked tail in heterozygotes and embryonic lethality at about nine days in homozygotes. Abnormal organization of the embryonic ectoderm is first apparent at about embryonic day 7, and the retarded and malformed embryos die by mid 9 days.

Kink,  $Fu^{Kt}$ , a dominant gene that maps in the same region, is also an embryonic lethal in homozygotes; heterozygotes have kinked tails and often a circling gait. We have shown  $Fu^{Kb}$  and  $Fu^{Kt}$  are allelic; the  $Fu^{Kb}/Fu^{Kt}$  compound dies at the same time as  $Fu^{Kb}/Fu^{Kb}$  embryos with the same morphological syndrome.

The  $Fu^{Kb}$  phenotype is not seen in offspring in expected ratios. The  $Fu^{Kb}$  males may have a low transmission ratio or penetrance may be incomplete.

An incidental finding of our histological studies is a high incidence of complete twinning when  $Fu^{Kb}$  heterozygotes mate *inter se* or when  $Fu^{Kb} \times Fu^{Kt}$  matings are made.

### 1. INTRODUCTION

Knobbly,  $Fu^{Kb}$ , a new dominant mutation in the mouse, arose during a mutagenesis experiment in the laboratory of Dr M. F. Lyon (Lyon, 1977; Lyon & Bechtol, 1977). The locus of  $Fu^{Kb}$  is on chromosome 17 between Brachyury,  $T$ , and tufted,  $tf$  (Lyon, 1978). Heterozygotes have short, bent tails; the mutation is an embryonic lethal in homozygotes. When  $Fu^{Kb}$  was first identified, Lyon suggested that it exhibited low penetrance (Lyon, 1977). Results of our breeding experiments also suggest this or possibly a low transmission ratio for  $Fu^{Kb}$  males.

Although  $Fu^{Kb}$  is within the region covered by the  $T/t$  complex, it is not allelic to  $T$  or to any other genes in  $t$ -haplotypes that have been tested (Lyon & Bechtol, 1977). Dominant  $T$  mutations interact with recessive  $t$ -haplotypes to give tailless offspring (Bennett, 1975). The compounds  $Fu^{Kb}/t^{h17}$ ,  $Fu^{Kb}/t^{h18}$  and  $Fu^{Kb}/t^{w5}$  are all viable, short-tailed animals although  $Fu^{Kb}/t^{h20}$  is an embryonic lethal suggesting

<sup>1</sup> Present address: Department of Anatomy and Cell Biology, College of Physicians and Surgeons, Columbia University, 630 West 168th Street, New York, New York 10032.

that the  $t^{h20}$  haplotype is a deletion over the region of the  $Fu^{Kb}$  locus (Lyon & Bechtol, 1977).

Kink,  $Fu^{Ki}$ , another dominant mutation in this same chromosomal region, bears similarities to Knobbly.  $Fu^{Ki}$ -heterozygotes have short, kinked tails and often a circling behaviour. Kink is lethal in homozygous embryos at about 9–10 days of gestation (Caspari & David, 1940; Dunn & Caspari, 1945). Breeding tests in our laboratory have shown Kink and Knobbly to be allelic.

Results of histological studies reveal that some embryos in litters segregating  $Fu^{Kb}$  have abnormal embryonic ectoderm first apparent at about 7 days; they become severely retarded and disorganized and die by mid 9 day of gestation. Histology of litters resulting from mating of  $Fu^{Ki}$ -heterozygotes by  $Fu^{Kb}$ -heterozygotes reveals abnormalities in 7- and 8-day embryos similar to those seen in embryos resulting from matings between  $Fu^{Kb}$ -heterozygotes.

Abnormalities in  $Fu^{Ki}/Fu^{Ki}$  embryos include partial duplications of axes or parts of embryos and also complete twinning (Gluecksohn-Schoenheimer, 1949). We have found a high incidence of twinning in matings of  $Fu^{Kb}$  heterozygotes *inter se* and of  $Fu^{Kb}$  by  $Fu^{Ki}$  heterozygotes.

## 2. MATERIALS AND METHODS

### (i) *Mouse stocks*

Knobbly,  $Fu^{Kb}tf/+tf$  animals, originally supplied by Dr M. F. Lyon in 1978, were mated to normal-tailed, tufted BTBRTF/Nev mice maintained in this laboratory. The  $F_1$  short-tailed progeny,  $Fu^{Kb}tf/+tf$ , served as our foundation stock.

Animals heterozygous for Kink were originally observed in the stocks of Mr Sidney P. Holman of Manatee, Florida and sent by him to Dr L. C. Dunn of Columbia University in 1937 (Caspari & David, 1940). The stock was maintained continuously by Dr Dunn and then by this laboratory as  $Fu^{Ki}tf/++$ .

### (ii) *Breeding tests*

Determination of the transmission ratio for the  $Fu^{Kb}$  gene and whether it exhibits incomplete penetrance was done by mating  $Fu^{Kb}tf/+tf \times +tf/+tf$  animals and scoring newborns for tail length.

For Kink–Knobbly allelism tests  $Fu^{Ki}tf/++$  animals were mated with  $Fu^{Kb}tf/+tf$  animals. All non-tufted progeny were discarded. Short-tailed tufted progeny, either  $Fu^{Ki}tf/+tf$  or  $Fu^{Ki}tf/Fu^{Kb}tf$ , were mated with  $++/++$  animals and litters scored at birth for tail phenotype.

### (iii) *Histology*

To obtain  $Fu^{Kb}$ -homozygous embryos,  $Fu^{Kb}tf/+tf$  animals were mated *inter se*. For  $Fu^{Ki}/Fu^{Kb}$  compound embryos, crosses were made between  $Fu^{Ki}tf/++$  and  $Fu^{Kb}tf/+tf$  animals. Normal littermates served as controls, as did embryos from matings of random-bred CF-1 mice.

Table 1. Results from breeding tests of  $Fu^{Kb}tf/+tf$  mated *inter se* or with  $+tf/+tf$ 

Parents	Total born	Short tail	% Short tail		$\chi^2$
			Expected	Observed	
$Fu^{Kb}/+tf$ $\times Fu^{Kb}tf/+tf$	1405	761	66.6	54	98.7*
$+tf/+tf$ $\times Fu^{Kb}tf/+tf$	1009	431	50.0	43	21.4*
$Fu^{Kb}tf/+tf$ $\times +tf/+tf$	99	54	50.0	55	0.82

\* Significant ( $P < 0.001$ ) with 1 degree of freedom.Table 2. Summary of results from dissections of litters of  $Fu^{Kb}tf/+tf$  mated *inter se*

Age of litter (days)	Total litters	Total embryos	% Abnormal embryos		(Number of empty or resorbed included)	$\chi^2$
			Expected	Observed		
7-7½	9	101	25	18	5	2.6
8-8½	6	60	25	15	3	3.2
9	4	41	25	17	4	1.19

Table 3. Summary of results from dissections of litters from matings of  $Fu^{Kb}tf/+tf \times Fu^{Ki}tf/+ +$ 

Age of litter (days)	Total litters	Total embryos	% Abnormal embryos		(Number of empty or resorbed included)	$\chi^2$
			Expected	Observed		
7-7½	2	22	25	41	1	4.14*
8-8½	5	50	25	16	1	1.72

\* Significant ( $P < 0.05$ ) with 1 degree of freedom.

Embryos were timed by vaginal plugs; the day of plug was day zero. Pregnant females were killed and decidual capsules were removed from uteri at 7, 7½, 8, 8½ and 9 days of gestation. Embryos in capsules were fixed in Bouin's fluid, embedded in paraffin, and serial sections cut at 8-10  $\mu$ m were stained with haematoxylin and eosin or with alcian blue.

### 3. RESULTS

#### (i) Genetics

Significantly fewer than expected short-tailed progeny resulted from matings of Knobbly heterozygotes *inter se* (Table 1) and from matings between  $+tf/+tf$  females with  $Fu^{Kb}tf/+tf$  males; reciprocal backcrosses produced short-tailed animals within expected limits (Table 1).  $Fu^{Kb}$  males have a low transmission ratio or low penetrance; however, fewer crosses were made between  $+tf/+tf$  females and  $Fu^{Kb}tf/+tf$  males than other crosses.

Litters dissected for histological studies of  $Fu^{Kb}/Fu^{Kb}$  embryos yielded fewer than 25% in the abnormal class at all stages, but in no case were these numbers statistically significant (Table 2). Histology of embryos, from matings between  $Fu^{Kb}$  and  $Fu^{Ki}$  heterozygotes, showed a significant excess number of abnormal embryos at 7–7½ days of gestation (Table 3); and, by 8 days, the number of these abnormal embryos was also within the expected limits for a recessive lethal gene.

Table 4. *Incidence of twinning in embryos from dissections of litters of  $Fu^{Kb}tf/+tf$  mated inter se or of  $Fu^{Kb}tf/+tf \times Fu^{Ki}tf/+ +$*

Mating	Total litters	Total embryos	Twins		Number of litters with twins	Miscellaneous
			Normal	Abnormal		
$Fu^{Kb}tf/+tf$ $\times Fu^{Kb}tf/+tf$	19	202	11	5	8	One set of triplets (all three normal)
$Fu^{Kb}tf/+tf$ $\times Fu^{Ki}tf/+ +$	7	72	5	2*	3†	—

\* One too early to classify.

† One litter had two pairs, one normal and one abnormal, one normal and one too early to classify.

Histological examination of embryos from  $Fu^{Kb}$  heterozygote matings *inter se* and from  $Fu^{Kb}$  heterozygote by  $Fu^{Ki}$  heterozygote matings showed a high incidence of 'twin' embryos (= two embryos in the same decidual capsule) (Table 4). Pairs of twins were of two types; both members of a pair were normal (possible monozygotic twins) or one was normal and the other abnormal (dizygotic twins). There were no instances of partial or conjoined twins, or of both twins being abnormal. One set of three normal triplets occurred in an  $Fu^{Kb}$  *inter se* mating.

### (ii) Morphology

The staging of embryos is based on comparisons of our histological sections with Sobotta's stages (Sobotta, 1911) and with Theiler's descriptions (Theiler, 1972) of normal embryos.

#### 7–7½ days

In normal embryos at 7 days, mesoderm has begun to migrate from the primitive streak at the posterior end of the egg cylinder and the amnion is just forming. Notochord, somites and head folds are not yet apparent (Plate 1, Figs. 1, 2).

In litters segregating  $Fu^{Kb}$ , a class of embryos consistently shows a discrete abnormality at this stage (Table 2). A small region of the embryonic ectoderm appears slightly thickened; within this zone the cells are small and crowded and sometimes contain dark granules (Plate 1, Figs. 3, 4). Usually this cluster of cells is at or near the future head process and is confined to one focus.

Embryos of this abnormal class are of the same average size and stage of development as normal littermates and embryos in control litters; endoderm, mesoderm and extraembryonic structures are normal in appearance.

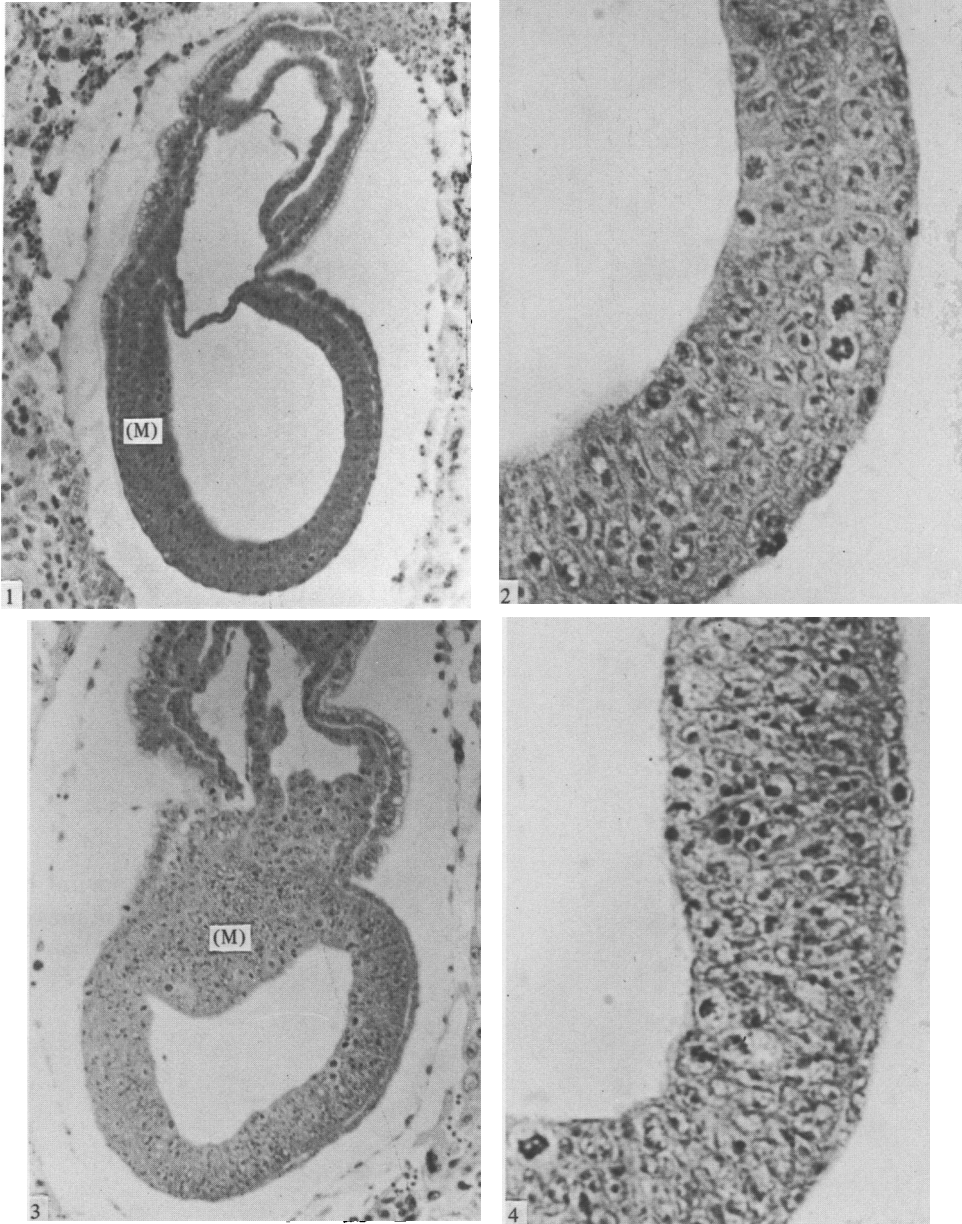


Fig. 1. Sagittal section of 7½-day normal embryo. Primitive streak mesoderm (M) is apparent. × 120.

Fig. 2. Higher magnification of region of embryo from Fig. 1. Mitotic figures are present in embryonic ectoderm. Ectodermal cells show definite alignment. × 440.

Fig. 3. Sagittal section of 7½-day abnormal  $Fu^{Kb}/Fu^{Kb}$  embryo. Note disorganized mass of mesoderm (M) forming one side of embryo. × 120.

Fig. 4. Higher magnification of region of embryo in Fig. 3. Note many small round crowded cells. Mitotic figures are present. Ectodermal cells are not aligned as in Fig. 2. × 440.

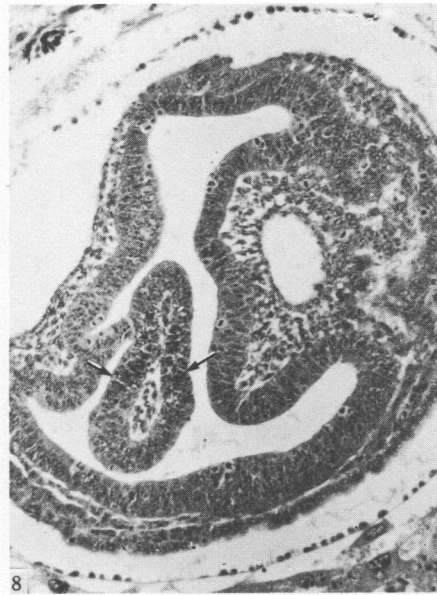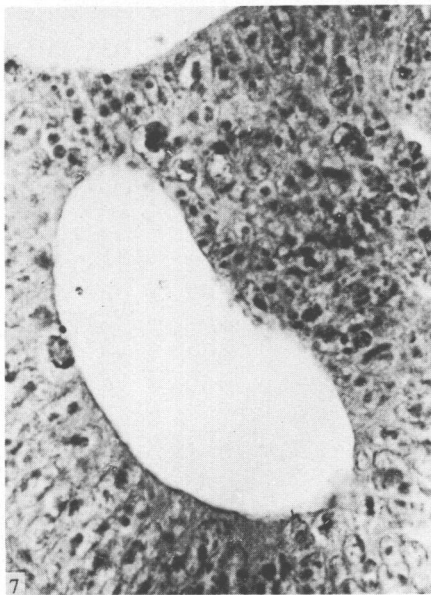
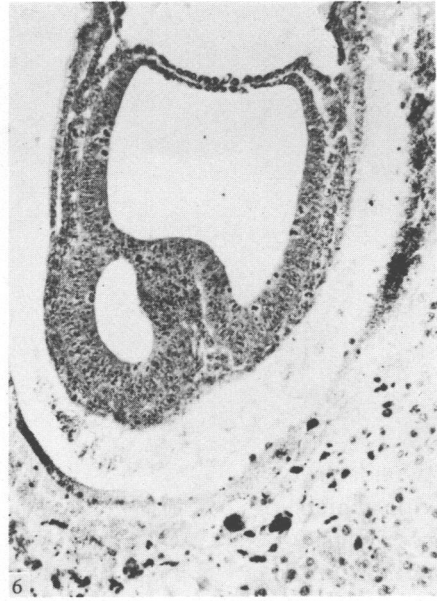

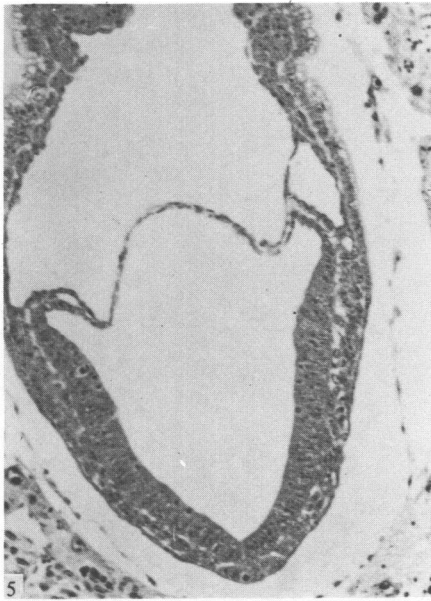
Fig. 5. Normal embryo of 7 $\frac{3}{4}$  days gestation. Mesoderm has spread throughout embryo.  $\times 120$ .

Fig. 6. Section of 7 $\frac{3}{4}$ -day abnormal  $Fu^{Kb}/Fu^{Kt}$  compound embryo. Mesoderm has spread to anterior of embryo but an ectodermal bridge with underlying mesoderm has intruded into the amniotic cavity.  $\times 120$ .

Fig. 7. Higher magnification of region of embryo in Fig. 6. Many pycnotic, round ectodermal cells are evident. Some debris has been shed into the cavity formed.  $\times 440$ .

Fig. 8. Section of 8 $\frac{1}{2}$ -day  $Fu^{Kb}/Fu^{Kb}$  abnormal embryo showing embryonic ectoderm bulging into amniotic cavity in several places. There are two foci of necrotic cells (arrows) in this section. No abnormal embryo has been found which has progressed past this stage.  $\times 120$ .

R. J. JACOBS-COHEN AND OTHERS

Although the number of embryos comprising the abnormal class is smaller than expected, the same defect of the embryonic ectoderm is consistently seen, and was not observed in control litters. The abnormal class is therefore tentatively designated as Knobbly homozygotes (Table 2).

#### *7½–8 days*

Normal embryos have abundant mesoderm and sometimes beginning head folds (Plate 2, Fig. 5). Abnormal embryos in litters segregating *Fu<sup>Kb</sup>*-homozygotes continue to have large groups of aberrant cells in the embryonic ectoderm and often show ectodermal swellings or overgrowths (Plate 2, Figs. 6, 7). At this time the lesion contains many granular cells, and sometimes is overtly necrotic, with dead cells and debris shed into the pro-amniotic cavity. The defective cells are still confined to the embryonic ectoderm, but the area affected has increased in size and may occupy as much as half of the embryonic ectoderm. Typically, many cells are pycnotic or are rounded and contain dark granules. Several embryos were found in which bridges of embryonic ectoderm extend across the amniotic cavity (Plate 2, Figs. 6, 7). Some, but not all, of these abnormal embryos are smaller than normal size and are retarded in development, thus resembling late egg-cylinder stages.

#### *8–8½ days*

Normal embryos of the backgrounds used are usually at the head fold–presomite stage by 8 days of gestation; by 8½ days, up to 12 somites are present but embryos have not yet turned.

The abnormal group of embryos from *Fu<sup>Kb</sup>* matings *inter se* is still consistently found in the population now (Table 2). Most conspicuous are the large bulges of embryonic ectoderm full of dead and dying cells that intrude into the amniotic cavity (Plate II, Fig. 8). The lesion is no longer confined to a single place, but several foci appear discrete and well separated. Mesenchyme underlies the bulging ectodermal masses.

There is a general arrest of development and differentiation in these affected embryos. They are much smaller than normal littermates. Structures such as notochord, somites, heart, and blood vessels are not seen. Brain and neural tube are also absent but the large, irregular curving ectodermal mounds might be misshapen head folds. Some of the defective embryos have a wrinkled chorion and yolk sac, but ectoplacental cone, giant cells, and parietal endoderm appear normal. Furthermore, the cytology of individual mesenchymal, endodermal, and many ectodermal cells seems normal. Although the implantation site seems large enough to accommodate a larger embryo, the putative mutant is arrested in a state resembling an overgrown primitive streak stage with no differentiated derivatives of the three germ layers. Posterior elongation and axial organization have not occurred.

#### *9 days*

Normal early 9-day embryos have up to 22 somites, beating hearts, otic and optic vesicles and anterior limb-bud rudiments. Abnormal embryos of the suspected *Fu<sup>Kb</sup>/Fu<sup>Kb</sup>* class found at 9 days may resemble those seen at any earlier stage;

no abnormal embryo has been found which has developed further than those described at  $8\frac{1}{2}$  days. The few mutants still alive at 9 days probably die soon thereafter because of the large necrotic regions and lack of a circulatory system.

The majority of abnormal embryos resulting from crosses between  $Fu^{K^i}$  and  $Fu^{K^b}$  heterozygotes are found at  $7-7\frac{1}{2}$  days; a small number are still found at  $8-8\frac{1}{2}$  days (Table 3). The suspected  $Fu^{K^b}/Fu^{K^i}$  compounds are indistinguishable from  $Fu^{K^b}/Fu^{K^b}$  mutant embryos at the same stage of development.

A number of resorbed embryos are seen at all stages studied (Tables 2, 3). These have been included within the abnormal class since their number is higher than in random sampling of normal litters. Apparently the homozygous embryos die over a span of time and not at a precise stage, although the majority of them die after 9 days of gestation.

#### 4. DISCUSSION

We have described a new dominant mutation on chromosome 17, some of whose effects include embryonic lethality in homozygotes, a high incidence of twinning and possibly a low transmission ratio for  $Fu^{K^b}$  males. Low transmission of  $Fu^{K^b}$  from males, or incomplete penetrance, is suggested because significantly fewer short-tailed mice resulted from matings of heterozygotes *inter se* or from backcrosses of heterozygous males by normal females, but not from the reciprocal backcross. We cannot determine the cause from our data.  $Fu^{K^b}/Fu^{K^b}$  embryos are competent to make all three germ layers. The early extra-embryonic structures are formed normally. Embryonic ectoderm seems to grow more rapidly than the other layers in the embryo but does not organize appropriately into neural primordia. Mesoderm and embryonic ectoderm may be unable to interact and differentiate into the axial organ rudiments; typical notochord, neural tube and somites do not form. Other organ rudiments also are absent, including heart and blood vessels. Structures resembling neural folds are seen in surviving 9-day mutant embryos. Possibly these thick, curving mounds are regions of embryonic ectoderm which continued to proliferate but not to differentiate. By 9 days, however, the embryo is presumably too large to survive with no circulation other than diffusion, especially since the extensive necrotic lesion may release toxic products.

Our data show  $Fu^{K^b}$  and  $Fu^{K^i}$  are alleles.  $Fu^{K^i}$  is also allelic with the gene Fused,  $Fu$ , in this same region (Dunn & Gluecksohn-Waelsch, 1954). Fused was discovered in stocks at the Bussey Institution in 1931 (Reed, 1937).  $Fu/Fu$  homozygotes are viable;  $Fu^{K^i}/Fu^{K^i}$  homozygotes die at 9-10 days (Gluecksohn-Schoenheimer, 1949; Dunn & Gluecksohn-Waelsch, 1954; Theiler & Gluecksohn-Waelsch, 1956). Homozygous effects of the  $Fu^{K^i}$  gene in embryos cover a wide range of abnormalities from a totally disorganized mass of tissue to partial duplications of axes or parts of embryos to complete twinning.  $Fu$  causes excess growth of neural tissue with duplications of the neural tube in the caudal region (Theiler & Gluecksohn-Waelsch, 1956). In our histological studies, we found a high incidence of complete twinning in litters of  $Fu^{K^b}$  heterozygotes mated *inter se* and from  $Fu^{K^b} \times Fu^{K^i}$  matings. However,  $Fu^{K^b}/Fu^{K^b}$  may be a special case in which the maternal genotype exerts an effect. We found no pair of two abnormal twins. Therefore homozygosity of  $Fu^{K^b}$  alone does not cause twinning. Rather, the finding of two embryos in the same



decidual capsule may be due to an abnormality of implantation expressed by the mother.

The action of the  $Fu^{Kb}$  and  $Fu^{Ki}$  genes together appears to produce earlier embryonic lethality in a greater number of cases than either gene in homozygous condition alone ( $Fu^{Kb}/Fu^{Kb}$  9 days;  $Fu^{Ki}/Fu^{Ki}$  9–10 days). The defect seen in the lethal  $Fu^{Kb}/Fu^{Ki}$  compounds is, however, similar to that seen in  $Fu^{Kb}/Fu^{Kb}$  homozygotes and may simply be a reflection of the different backgrounds of the two genotypes. The compounds do not progress to the point of duplicating axes or organs.

Expression of the Fused and  $Fu^{Kb}$  genes is apparently modified by parental sex. Many fewer  $Fu$  animals resulted from  $Fu$  females by normal matings than vice versa (Dunn & Caspari, 1945; Dunn & Gluecksohn-Waelsch, 1954; Theiler & Gluecksohn-Waelsch, 1956). Our data suggest that  $Fu^{Kb}$  male may have a low transmission ratio or that the mutation is incompletely penetrant.

The three alleles  $Fu^{Kb}$ ,  $Fu^{Ki}$  and  $Fu$  share some characteristics with the associated  $T/t$  complex as well as with each other. Many males carrying  $t$ -mutations have abnormal transmission ratios. Embryonic lethality and shortened tail length are also caused by  $T/t$  complex genes (Bennett, 1975).  $t^{w18}$ , an allele of the  $T/t$  complex, is characterized by partial duplications of neural tissue and by an increase in the incidence of twin embryos found (Bennett & Dunn, 1960).

$Fu^{Kb}$  is not an allele of the  $T/t$  complex as it does not interact with any of the haplotypes thus far tested including  $t^{w5}$  which, in homozygotes, results in a defect of the embryonic ectoderm by 7 days of gestation (Lyon & Bechtol, 1977).  $Fu^{Kb}$  homozygotes also have defective embryonic ectoderm although at a slightly later stage, between primitive streak formation and organization of the axial structures, the neural tube, notochord and somites. The viability of the  $Fu^{Kb}/t^{w5}$  compound implies that the genetic defects are different and complementary.

$Fu^{Kb}$  is another gene on chromosome 17 in the region between the centromere and H-2 which should prove a useful tool in dissecting early embryonic organization.

We are grateful to Dr M. F. Lyon for her gift of Knobbly mice with which to establish our stock, and to Mr Brian Clark for excellent technical assistance. This work was supported by NSF.

#### REFERENCES

- BENNETT, D. (1975). The  $T/t$ -locus of the mouse. *Cell* **6**, 441–454.
- CASPARI, E. & DAVID, P. R. (1940). The inheritance of a tail abnormality in the house mouse. *Journal of Heredity* **31**, 427–431.
- DUNN, L. C. & CASPARI, E. (1945). A case of neighboring loci with similar effects. *Genetics* **30**, 543–568.
- DUNN, L. C. & GLUECKSOHN-WAELSCH, S. (1954). A genetical study of the mutation 'Fused' in the house mouse, with evidence concerning its allelism with a similar mutation 'Kink'. *Journal of Genetics* **52**, 383–391.
- GLEUCKSOHN-SCHOENHEIMER, S. (1949). The effects of a lethal mutation responsible for duplications and twinning in mouse embryos. *Journal of Experimental Zoology* **110**, 47–76.
- LYON, M. F. (1977). *Mouse News Letter* **56**, 37.
- LYON, M. F. & BECHTOL, K. B. (1977). Derivation of mutant  $t$ -haplotypes of the mouse by presumed duplication or deletion. *Genetical Research* **30**, 63–76.

LYON, M. F. (1978). *Mouse News Letter* **59**, 21.

REED, S. C. (1937). The inheritance and expression of Fused, a new mutation in the house mouse. *Genetics* **22**, 1–13.

SOBOTTA, J. (1911). Die Entwicklung des Eies der Maus vom ersten Auftreten des Mesoderms an bis zur Ausbildung der Embryonenanlage und dem Auftreten der Allantois. *Archiv für microscopische Anatomie und Entwicklungsmechanik* **78**, 271–352.

THEILER, K. & GLUECKSOHN-WAELSCH, S. (1956). The morphological effects and the development of the Fused mutation in the mouse. *Anatomical Record* **125**, 83–104.

THEILER, K. (1972). *The House Mouse*. New York: Springer Verlag.