

**LETTER TO THE EDITOR****TO THE EDITOR*****Pneumocystis Jirovecii* Prophylaxis in Neurosurgery**

*Pneumocystis jirovecii* pneumonia (PJP) is an opportunistic interstitial fungal pneumonia.<sup>1</sup> Colonization with *P. jirovecii* occurs in more than 50% of the general population; however, symptomatic infection is rare.<sup>2</sup> Human immunodeficiency virus (HIV) patients and other immunosuppressed patients can develop PJP.<sup>2</sup>

The clinical presentation of PJP includes a low-grade fever, shortness of breath, and a dry cough.<sup>1,2</sup> On physical examination, patients experience tachycardia and tachypnea with minimal findings on chest auscultation.<sup>1,2</sup> In HIV patients, the presentation is more subtle, while non-HIV patients will present with rapid onset respiratory failure.<sup>2</sup> Accordingly, mortality rates in HIV patients are 10%–20%, while in non-HIV patients this rate is 30%–60%.<sup>2</sup>

The incidence among non-HIV immunocompromised patients is rising (6.2%), likely as a result of the increasing use of immunosuppressive agents in the treatment of malignancies, autoimmune and inflammatory diseases, and bone marrow or solid organ transplants.<sup>2</sup> Neurosurgical patients are frequently managed with high-dose steroids, particularly in the perioperative period.<sup>3</sup> In some cases, steroids are continued long term, particularly in the context of adjunctive radiation treatment.<sup>4</sup> Guidelines for PJP prophylaxis among HIV patients are well established, while prophylaxis in neurosurgical patients is variable.<sup>1</sup> Sulfamethoxazole/trimethoprim (TMP/SMX) is effective to reduce the incidence of PJP infections in non-HIV patients (6.2% vs 0.9%).<sup>2</sup> In this article, we present two neurosurgical patients presenting with PJP following steroid exposure. A review of the literature is presented with the objective of providing an update to recommendations useful to teams caring for neurosurgical patients.

A 51-year-old woman presented with a 6-month history of left eye progressive central visual blurring that improved with lateral gaze. Her past medical history was significant for poorly controlled essential hypertension. Computer tomography angiogram of the head revealed a 5.2 × 5.2 cm supraclinoid internal carotid artery aneurysm. She underwent successful urgent endovascular occlusion of the left internal carotid artery proximal to the aneurysm. She was discharged home 5 days postoperatively on a dexamethasone taper and aspirin. Two months after discharge, she presented to the emergency department (ED) with a 1-week history of confusion and malaise 3 days after stopping dexamethasone. In the ED, she developed rapidly progressive hypoxemia and required endotracheal intubation and ventilation in the intensive care unit (ICU). Chest X-ray (CXR) demonstrated diffuse bilateral patchy infiltrates (Figure 1). In the ICU, bronchoalveolar lavage (BAL) was positive for PJP. Fortunately, she improved quickly on ventilatory support, TMP/SMX, and prednisone. She was extubated and discharged home.

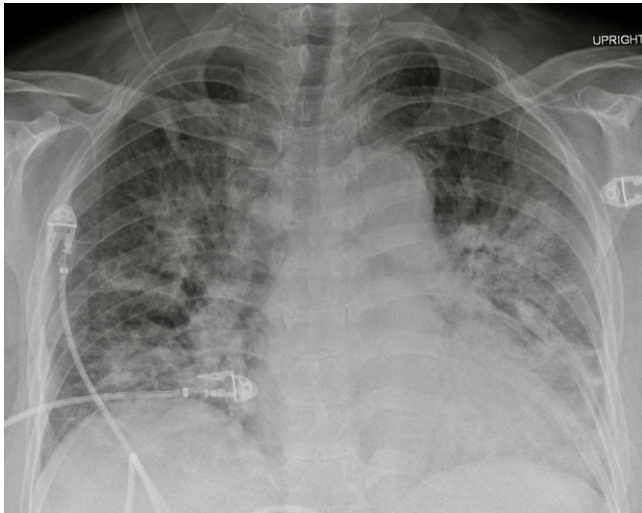
A 31-year-old male presented with a 2-year history of progressive headaches, nausea, vertigo, bilateral arm paresthesias, and blurry vision. His past medical history was unremarkable. A magnetic resonance imaging demonstrated an enhancing lesion

of the posterior fossa and obstructive hydrocephalus. He underwent urgent suboccipital craniectomy and the surgical pathology was consistent with a WHO grade 4 medulloblastoma. After inpatient rehabilitation, the patient was discharged home on dexamethasone 4 mg twice daily (BID) with a plan for radiation followed by chemotherapy. Three weeks later, the dexamethasone dose was increased by the patient's family physician to 8 mg BID. Three months after surgery, he presented acutely to the ED with a history of fever, chills, and dry cough. He had features of sepsis with tachypnea, tachycardia, and relative hypotension. His initial CXR was largely unremarkable and his oxygen saturation was normal on room air. He was started on broad spectrum antibiotics. Two days following his admission to the internal medicine team, he developed acute respiratory failure. Repeat CXR was most consistent with acute respiratory distress syndrome (Figure 2). He was transferred to the ICU for intubation due to profound hypoxemia. BAL was positive for PJP. He was started on high-dose TMP/SMX and steroids. He deteriorated despite lung protective ventilation, neuromuscular blockade, lung recruitment maneuvers, prolonged prone positioning, and inhaled epoprostenol. Comfort measures were instituted and he passed away peacefully in accordance with his previous wishes.

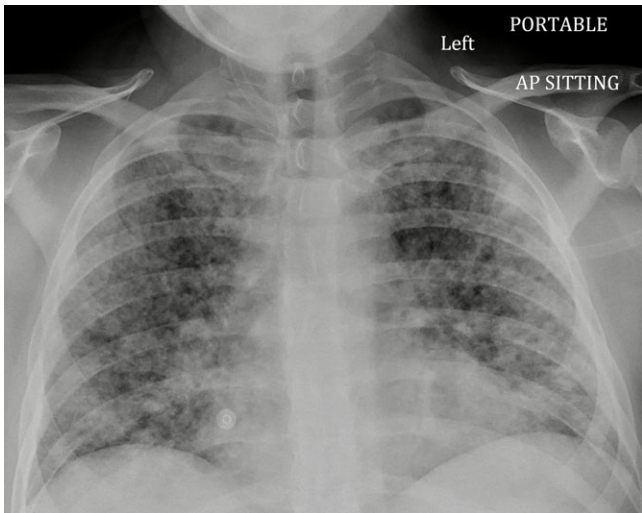
Increased lung inflammation in HIV-negative patients likely contributes to faster disease progression, with more severe hypoxemia, greater need for intensive care, and higher prevalence of shock.<sup>5,6</sup> Limper et al<sup>5</sup> used BAL to quantify pneumocystis and inflammatory cell numbers; HIV-negative patients had greater neutrophil counts, correlating with worse oxygenation and decreased survival. Latency to diagnosis also likely contributes to increased mortality in this population.<sup>6</sup> High-dose steroids increase the risk developing PJP due to immune system impairment.<sup>7</sup> A case series from Mayo found that in 91% of HIV-negative patients with the first episode of PJP, glucocorticoids had been administered within 1 month of diagnosis.<sup>7</sup> Yale et al<sup>7</sup> concluded that patients receiving prolonged, high-dose corticosteroid treatment (16–25 mg prednisolone or >4 mg dexamethasone daily for >4 weeks) are at high risk of PJP infection, regardless of underlying type or stage of malignancy, or use of other chemotherapeutic agents.

Glucocorticoids in neurosurgery are used to reduce inflammation and vasogenic edema.<sup>3</sup> PJP infections occur primarily during steroid taper in patients with primary brain tumors.<sup>4</sup> The dose reduction during a taper may allow for an increased inflammatory response that unmasks a latent infection.<sup>4</sup> Radiation therapy has also been shown to cause increased myelosuppression, further increasing the risk for PJP infection.<sup>4</sup>

PJP prophylaxis is recommended when the risk of PJP is greater than 3.5%.<sup>8</sup> The overall incidence of PJP infection among patients with primary or metastatic CNS tumor is low (1.7%), but with concurrent radiation this risk increases to 6.2%.<sup>8</sup> First-line PJP prophylaxis is TMP/SMX. Other effective antimicrobial agents include clindamycin, atovaquone, pyrimethamine, sulfadoxine, dapsone, and pentamidine.<sup>2</sup> The 2014 Cochrane review concluded that TMP/SMX administered three times per week was



**Figure 1:** AP chest radiograph demonstrating diffuse, bilateral, patchy, and confluent infiltrates with a predominant perihilar distribution.



**Figure 2:** AP chest radiograph demonstrating diffuse, bilateral, and nodular parenchymal opacities.

as effective as once daily.<sup>2,8</sup> Potential side effects of TMP/SMX include skin rash, leukopenia, liver, and renal dysfunction.<sup>2</sup> PJP prophylaxis should be instituted immediately and continue for 6 weeks following the steroid taper period.<sup>8</sup>


There are currently no standardized guidelines for PJP prophylaxis in neurosurgical patients. Collecting before and after data and performing an economic analysis are warranted. We recommend protocolized care with systematic prescription of TMP/SMX three times a week in neurosurgical patients undergoing treatment with prednisone equivalents of 20 mg daily for 4 weeks or longer in duration.

#### CONFLICTS OF INTERESTS

None.

#### STATEMENT OF AUTHORSHIP

MdeLB, MD, and PC were all involved in the project conception, authorship, and editing of the manuscript.

Madeleine de Lotbinière-Bassett   
Department of Clinical Neurosciences, University of Calgary,  
Calgary, Alberta, Canada

Mannat Dhillon  
Department of Medicine, University of Calgary, Calgary,  
Alberta, Canada

Philippe Couillard  
Department of Clinical Neurosciences, University of Calgary,  
Calgary, Alberta, Canada

Department of Critical Care Medicine, University of Calgary,  
Calgary, Alberta, Canada

*Correspondence to:* Madeleine de Lotbinière-Bassett, Department of Clinical Neurosciences, University of Calgary, Calgary, Alberta, Canada. Email: [madeleine.delotbiniere-bassett@albertahealthservices.ca](mailto:madeleine.delotbiniere-bassett@albertahealthservices.ca)

#### REFERENCES

- Kelly DM, Cronin S. PCP prophylaxis with use of corticosteroids by neurologists. *Pract Neurol.* 2014;14:74–76. doi: [10.1136/practneurol-2013-000727](https://doi.org/10.1136/practneurol-2013-000727)
- Stern A, Green H, Paul M, Vidal L, Leibovici L. Prophylaxis for *Pneumocystis pneumonia* (PCP) in non-HIV immunocompromised patients. *Cochrane Database Syst Rev.* 2014;2014: CD005590. doi: [10.1002/14651858.CD005590.pub3](https://doi.org/10.1002/14651858.CD005590.pub3)
- Merkler AE, Saini V, Kamel H, Stieg PE. Preoperative steroid use and the risk of infectious complications after neurosurgery. *The Neurohospitalist.* 2014;4:80–85. doi: [10.1177/1941874413510920](https://doi.org/10.1177/1941874413510920)
- Hughes MA, Parisi M, Grossman S, Kleinberg L. Primary brain tumors treated with steroids and radiotherapy: low CD4 counts and risk of infection. *Int J Radiat Oncol Biol Phys.* 2005;62:1423–26. doi: [10.1016/j.ijrobp.2004.12.085](https://doi.org/10.1016/j.ijrobp.2004.12.085)
- Limper AH, Offord KP, Smith TF, Martin WJ 2nd. *Pneumocystis carinii pneumonia*. Differences in lung parasite number and inflammation in patients with and without AIDS. *Am Rev Respir Dis.* 1989;140(5):1204–1209. doi: [10.1164/ajrccm/140.5.1204](https://doi.org/10.1164/ajrccm/140.5.1204)
- Roux A, Canet E, Valade S, et al. *Pneumocystis jirovecii pneumonia* in patients with or without AIDS, France. *Emerg Infect Dis.* 2014;20(9):1490–97. doi: [10.3201/eid2009.131668](https://doi.org/10.3201/eid2009.131668)
- Yale SH, Limper AH. *Pneumocystis carinii pneumonia* in patients without acquired immunodeficiency syndrome: associated illnesses and prior corticosteroid therapy. *Mayo Clin Proc.* 1996;71:5–13. doi: [10.4065/71.1.5](https://doi.org/10.4065/71.1.5)
- Cooley L, Dendle C, Wolf J, et al. Consensus guidelines for diagnosis, prophylaxis and management of *Pneumocystis jirovecii pneumonia* in patients with haematological and solid malignancies. *Intern Med J.* 2014;44(12b):1350–63.