

## Technical Note

# Slant board immobilisation of head-and-neck radiotherapy patients who cannot tolerate a flat position

Song Qu, Lisa Singer, Josephine Chen, Erin Shugard, Adam A. Garsa, Sue S. Yom

*Department of Radiation Oncology, University of California, San Francisco*

(Received 22 November 2015; revised 8 March 2016; accepted 14 March 2016; first published online 22 April 2016)

## Abstract

**Purpose:** Patients treated with intensity-modulated radiation therapy (IMRT) for head-and-neck cancer are often positioned supine on a carbon fibre board to which a thermoplastic mask is attached to immobilise the head and shoulders. For patients unable to tolerate a supine position, we developed a tilting board that accommodates a full-scale head-and-shoulder mask.

**Materials and methods:** Phantom measurements were obtained to confirm the dosimetric accuracy of our treatment planning system when using this board. A patient was simulated in the flat and tilted positions on the board. The two corresponding treatment plans were evaluated by comparing the target coverage and doses with organs at risk. The patient's intra-fraction motion was quantified during his tilted treatments.

**Results:** Phantom measurements confirmed the accuracy of the dosimetric calculations. The tilted plan met dosimetric standards for clinical acceptability. The intra-fraction motion of the patient in the tilted position was >3 mm in any direction.

**Conclusions:** The tilting board met clinical requirements for IMRT planning and delivery. Full-scale head-and-shoulder immobilisation was achieved in a more tolerable tilted position.

**Keywords:** head-and-neck cancer; radiation treatment planning; radiotherapy immobilisation; tilt or slant board

## INTRODUCTION

In the treatment of head-and-neck cancer (HNC) with intensity-modulated radiation therapy (IMRT), a stable and highly precise immobilisation of the head, neck and upper chest

is required to guarantee the reproducibility of the patient's position between and during treatment fractions. Immobilisation is usually accomplished by simulating the patient in a supine position on a flat carbon fibre board, with stabilisation of the head and neck via fabrication of a custom thermoplastic mask attached to the board. However, some patients have great difficulty tolerating a flat position for the several minutes that are required to deliver an IMRT treatment.

Correspondence to: Sue S. Yom, Department of Radiation Oncology, University of California San Francisco, 1600 Divisadero St, Suite H1031, San Francisco, CA 94143, USA. Tel: 415 353 7175. Fax: 415 353 9883. E-mail: yoms@radonc.ucsf.edu

A variety of medical or physical conditions may make the supine position challenging for a patient. In patients with cardiac insufficiency, redistribution of blood volume into the lungs during recumbency causes reduction in vital capacity and pulmonary compliance.<sup>1,2</sup> Pulmonary disease, common among smokers, is another important cause of orthopnoea.<sup>2,3</sup> For patients experiencing orthopnoea, total lung capacity and vital capacity are enhanced with an elevated position.<sup>4,5</sup> Specifically in patients with HNC, the additional factor of excessive salivation is one of the most common patient-reported symptoms. An elevated position decreases pooling of accumulated saliva in the pharynx, reduces the hazard of choking and assists in fluid clearance.<sup>6</sup> In our clinical experience, even very fit patients who do tolerate a flat position complain about the accumulation of salivary mucus and the choking and orthopnoea that result.

Tilt boards have been used previously for patients unable to tolerate a supine position.<sup>7</sup> There are several commercially available carbon fibre boards designed to tilt the patient's upper body upwards during radiotherapy. Typically used for the treatment of breast or thoracic cancers, some of these boards are compatible with a head-only thermoplastic mask, but a board compatible with a full-length head-and-shoulder mask has not been previously available. Extended-field IMRT has become the dominant mode of HNC radiotherapy treatment and requires full-length immobilisation.

In this report, we developed a prototype head-and-shoulder adapter plate to attach to a tilting board and used this setup to deliver IMRT to a patient in an elevated position using a full-scale head-and-shoulder mask. We verified that the board met standards for dosimetric and clinical acceptability and quantified the impact of the tilted position on dosimetry and intra-fraction motion.

## MATERIALS AND METHODS

The patient was a 28-year-old young male who had near-total glossectomy and bilateral neck dissection, with pathologic diagnosis of pT4aN2cM0, Stage IVA squamous cell carcinoma of the tongue, as per AJCC 7th edition staging.<sup>8</sup> The primary

cancer occupied nearly the entire anterior oral tongue, crossing midline and invading the left tonsil, skeletal muscle and salivary glands. At surgery, there were positive microscopic margins and extranodal extension was identified in one of the two involved lymph nodes. Postoperative chemoradiotherapy was recommended.

The patient weighed 313 pounds, was 6 feet tall and had a body mass index (BMI) of 43.6 (obesity is typically defined as a BMI of 30). Due to the presence of the large soft tissue reconstruction in his mouth, he had near-constant, copious salivary secretions requiring frequent suction. For these reasons, he had difficulty lying flat and was sleeping upright in a chair at home.

## Radiation therapy simulation

It was anticipated that a flat supine setup might be intolerable for the patient. Thus, it was decided to attempt simulation in both the flat and tilted positions to decide which would be more tolerable. The Access Supine Breast and Lung board (QFix, Avondale, PA, USA) was utilised for the base board (Figure 1). A prototype adapter plate, produced by the manufacturer and developed with our group, was attached to the top of the board. The adapter plate has pegs that fit into the tilt board to secure it in place and the adapter plate has the required holes to secure a full-length thermoplastic head-and-shoulder mask (Civco Medical Solutions, Coralville, IA, USA). The tilt board has a set of underbraces that produce various degrees of tilt up to 15°.



Figure 1. Tilting base board and head-and-neck adapter plate.

Except for the tilt board and adapter plate, the remainder of the patient's setup was according to our departmental standards, including the use of custom plastic dental guards to prevent backscatter from metal fillings. The patient could not tolerate a tongue-depressing stent due to gagging. Computed tomography (CT) scans at 3 mm slice thickness were acquired with the patient at a 0° and a 10° tilt. The patient required preparatory suctioning and oxygen via nasal cannula during the 0° simulation but did not require these supports in the tilted 10° position.

### Commissioning of the tilting board

The physical density of the prototype adapter plate was calculated based on volume and weight measurements, and the electron density was estimated by acquiring a megavoltage CT image on a Tomotherapy unit (Accuray Inc., Sunnyvale, CA, USA) and interpolating from the electron density calibration curve. To validate the dose calculations in the treatment planning system for posterior beams that pass through the tilt board, several dose measurements were taken using calibrated Gafchromic film (Ashland Inc., Covington, KY, USA). To investigate the accuracy of patient surface dose calculations, six film pieces were placed directly on the tilt board at various locations with solid water placed on top for backscatter. To investigate the accuracy of the dose calculated at depth in the patient, a 2 cm thick slab of solid water was placed on the tilt board and then six more film pieces and remaining solid water placed on top. Posterior 6 MV fields were delivered and the measured dose was compared with the Pinnacle calculations for the same setup. The standard clinical CT density table was used with no special override performed on the CT image of the tilt board and adapter plate.

### Delineation of target volumes and organs at risk (OARs)

CTV6600 (clinical target volume prescribed to 6,600 cGy) included a small area at particularly high risk for recurrence and received 6,600 cGy over 30 fractions. CTV6000 included the primary tumour bed, the left neck nodal levels 1a–4 and the

right neck nodal levels 1b–2. CTV5600 included the contralateral neck nodal levels 3–4 as well as the bilateral low neck. Uniform expansions of 0.3 cm were added to define the corresponding planning target volumes (PTVs). OARs were contoured per our departmental standards, including the brainstem, spinal cord, optic nerves and chiasm, right and left cochlea, parotid glands and mandible.

### Treatment planning

Two treatment plans were developed in the Pinnacle treatment planning system (Philips Radiation Oncology Systems, Fitchburg, WI, USA) based on the flat position and the tilted position. Both plans used a single isocentre, nine widely distributed gantry angles and employed a step-and-shoot IMRT technique. IMRT was deemed necessary due to the decreased doses to the parotid gland as compared with 3D conformal radiation therapy.<sup>9</sup> Target and OAR dose–volume statistics were compared between the two plans. Plans were deemed clinically acceptable if OAR dosimetry met our pre-specified departmental standards (Table 1).

### Imaging verification

The patient had a difficult experience lying flat and chose to be treated in the tilted position. Daily pre-treatment image guidance using kilovoltage cone-beam CT (CBCT) (XVI; Elekta, Atlanta, GA, USA) was performed; pre-treatment CBCT was registered in real time before each fraction was delivered. To check for intra-fraction motion, CBCTs were obtained immediately following treatment in a subset of fractions, once per week throughout the treatment course. It was decided not to obtain the post-treatment CBCT daily, given the excessive additional lengths of time the patient would be required to be on the table. The post-treatment CBCT was registered offline to the pre-treatment CBCT. The differences between the translations of the patient from the known couch shift performed before treatment and the post-treatment CBCT alignment were used to estimate the intra-fractional patient motion that had occurred between the time of pre-treatment and post-treatment.

**Table 1.** Comparison of dosimetric parameters between plans created in flat and tilted positions

Dose parameters	Departmental standard requirement	Results at 0°	Results at 10°
PTV6600 coverage (% receiving Rx dose)	95.0	97.9	99.9
PTV6000 coverage (% receiving Rx dose)	95.0	96.7	94.7
PTV5600 coverage (% receiving Rx dose)	95.0	96.7	97.5
Spinal cord maximum (Gy)	45.0	43.0	44.9
Brainstem maximum (Gy)	54.0	32.6	42.5
Left parotid mean (Gy)	26.0	29.1	29.0
Right parotid mean (Gy)	26.0	23.8	25.6
Larynx mean (Gy)	35.0	31.3	32.2
Mandible maximum (Gy)	70.0	69.4	68.8

Abbreviation: PTV, planning target volume.

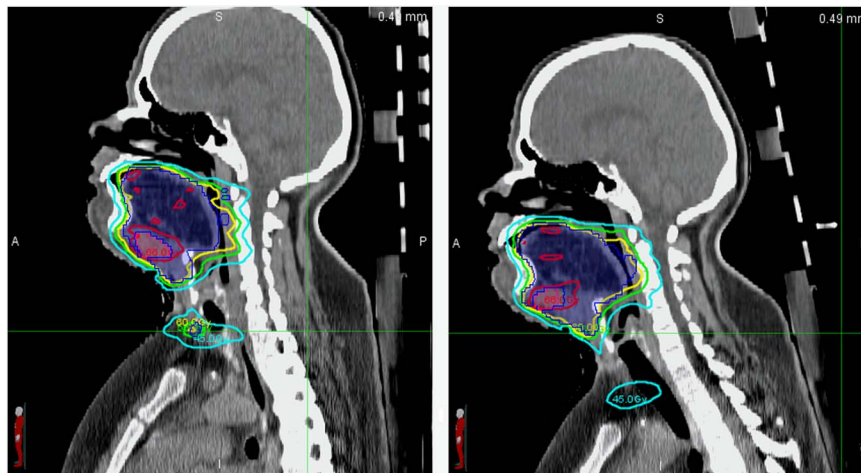


Figure 2. Sagittal computed tomographic slices of the patient in the flat (left) and tilted (right) position.

Notes: The shaded blue contour is the PTV6000. The following isodose lines are displayed: 6,600 cGy (red), 6,000 cGy (yellow), 5,600 cGy (green) and 4,500 cGy (cyan).

Abbreviation: PTV, planning target volume.

## RESULTS

The physical density of the prototype adapter plate was calculated to be 0.98 g/cc and the electron density (relative to water) was 0.8. The attenuation and bolus effect of the adapter plate and tilt board were accurately calculated in the planning system to within 5% (mean absolute difference 2%) and 10% (mean absolute difference 5%) at 2 cm depth in the patient and on the patient surface, respectively.

Figure 2 displays sagittal CT images of the patient in the flat and tilted positions, along with

contours and isodose lines for treatment plans. The plans demonstrate similar PTV coverage and OAR sparing, both within clinical acceptability (Table 1). All pre-specified OAR constraints were met in both plans.

The intra-fraction motion was within 3 mm in all orientations at all time points (Table 2). The intra-fraction motion, estimated to equal the difference between the shifts required for CBCT alignments at the pre- and post-treatment time point, was from 0.1 to 2.6 mm. The absolute value of the intra-fraction motion did not exceed 3 mm.

**Table 2.** Estimated intra-fraction motion obtained from the difference in the shifts required to align pre- and post-treatment cone-beam computed tomographic scans, taken approximately once per week (mm)

Week	Vertical	Lateral	Longitudinal
1	-0.1	-0.2	1.4
2	-0.4	-1.1	-1.1
3	-0.6	0.6	1.7
4	-2.6	0.2	2.2
5	-2.0	0.1	1.4

## DISCUSSION

In this study, we showed that positioning on a novel tilting board was feasible and clinically acceptable for full-scale IMRT treatment of a complex HNC patient. The patient was able to complete his IMRT successfully with less fear of 'choking and drowning' due to the slant board. This setup could particularly benefit HNC patients who have difficulties with a flat, supine position due to orthopnea or salivary accumulation. As the position of the entire upper body is elevated and reproducibly indexed in this setup, one could also conceive that patients with lymphoma, lung cancer or other cancers of the head-and-neck or thoracic regions could be treated in this way.

The quality of the plan in the tilted position was clinically equivalent to a treatment plan in a flat position. Both met our department's dosimetric standards. Voong et al.<sup>10</sup> recently demonstrated that use of 'butterfly' IMRT beam arrangements, in conjunction with immobilisation on an inclined board with breath-hold during radiation treatment, reduced high doses to nearby critical organs and kept the low integral dose at acceptable levels in comparison with anterior-posterior techniques. In our study, meaningful differences between the two IMRT plans in the flat and tilted positions were not identified. This may be explained by the fact that both of our plans were developed using IMRT, which is an inverse planning process, and the same dose limitations were assigned to the critical organs.

Patient stability and intra-fraction motion was of concern because of the angled incline with potential for 'sliding down the board' and possible worsening of this effect with weight loss and loosening of the mask on the patient's body.

Using CBCT imaging taken before and after treatment at intervals throughout the treatment course, the intra-fraction motion was confirmed to be consistently <3 mm, which falls within our standard PTV margins and the usual range of motion associated with conventional flat setup positions in other reports.<sup>11,12</sup>

Limitations of our report are its preliminary and specific nature, the lack of quantification of benefits across a larger number of patients and the unknown variations that may occur for IMRT plans developed for other anatomic regions. There may be a range of applications that may be valid for patients who require radiotherapy treatment to the head, neck, mediastinum or upper chest, but these were outside the scope of this initial report. As we have just begun to utilise the board, structured assessments in the form of patient surveys or quality of life instruments were likewise outside the scope of this initial report. However, we are confident that we have established the feasibility and clinical acceptability of this novel tilting board for the particular application described.

This indexed, tilted board is proposed as a superior option for HNC patients who require full-scale head-and-neck immobilisation and are unable to tolerate IMRT in a flat position.

## References

- Go A S, Mozaffarian D, Roger V L et al. Heart disease and stroke statistics—2013 update: a report from the American Heart Association. *Circulation* 2013; 127 (1): e6–e245.
- Mukerji V. Dyspnea, orthopnea, and paroxysmal nocturnal dyspnea. In: Walker H K, Hall W D, Hurst J W (eds). *Clinical Methods: The History, Physical, and Laboratory Examinations*, 3rd edition. Boston, MA: Butterworths, 1990: 78–80.
- Ang G S, Ong J M, Eke T. Face-to-face seated positioning for phacoemulsification in patients unable to lie flat for cataract surgery. *Am J Ophthalmol* 2006; 141 (6): 1151–1152.
- Navajas D, Farre R, Rotger M M, Milic-Emili J, Sanchis J. Effect of body posture on respiratory impedance. *J Appl Physiol* (1985) 1988; 64 (1): 194–199.
- Vilke G M, Chan T C, Neuman T, Clausen J L. Spirometry in normal subjects in sitting, prone, and supine positions. *Respir Care* 2000; 45 (4): 407–410.
- Epstein J B, Thariat J, Bensadoun R J et al. Oral complications of cancer and cancer therapy: from cancer treatment to survivorship. *CA Cancer J Clin* 2012; 62 (6): 400–422.

7. Yarbro C H, Wujcik D, Gobel B H. *Cancer Nursing: Principles and Practice*, 7th edition. Sudbury, MA: Jones and Bartlett Publishers, 2011.
8. Edge S, Byrd D R, Compton C C, Fritz A G, Greene F L, Trotti A. (eds). *AJCC Cancer Staging Manual*, 7th edition. New York: Springer-Verlag, 2010.
9. Nutting C M, Morden J P, Harrington K J et al. Parotid-sparing intensity modulated versus conventional radiotherapy in head and neck cancer (PARSPORT): a phase 3 multicentre randomised controlled trial. *Lancet Oncol* 2011; 12 (2): 127–136.
10. Voong K R, McSpadden K, Pinnix C C et al. Dosimetric advantages of a 'butterfly' technique for intensity-modulated radiation therapy for young female patients with mediastinal Hodgkin's lymphoma. *Radiat Oncol* 2014; 9 (1): 94.
11. Engelsman M, Rosenthal S J, Michaud S L. Intra- and interfractional patient motion for a variety of immobilization devices. *Med Phys* 2005; 32 (11): 3468–3474.
12. Velec M, Waldron J N, O'Sullivan B et al. Cone-beam CT assessment of interfraction and intrafraction setup error of two head-and-neck cancer thermoplastic masks. *Int J Radiat Oncol Biol Phys* 2010; 76 (3): 949–955.