

Seizure Exacerbation and Developmental Regression with Carbamazepine

A.N. Prasad, M. Stefanelli and L Nagarajan

ABSTRACT: *Background:* Unexpected exacerbation of seizures may occur following initiation of treatment with carbamazepine (CBZ). We reviewed the occurrence of such reactions in our patient population at a tertiary care children's hospital. *Methods:* A retrospective analysis of our clinic database identified 129/691 (18.6%) patients with epilepsy treated with CBZ, as monotherapy. 38/129 children were later switched to another drug. In 11/38 (28.5 %) clinical and/or EEG deterioration was observed. Two patients identified at another institution with similar exacerbation were also included in our analysis. We report on the findings in these 13 cases. *Results:* Two groups were identified: Group I – 6 patients with normal neurological exam, normal EEG background, and a diagnosis of idiopathic generalized epilepsy. Group II - 7 patients with an abnormal neurological exam and/or abnormal EEG background. Following introduction of CBZ therapy, worsening of preexisting seizures, appearance of new seizure types, behavioral regression, and accompanying EEG deterioration were reported in both groups. Dramatic improvement in seizure control occurred, following withdrawal of CBZ and substitution of another anticonvulsant. *Conclusion:* Physicians treating epilepsy must be aware that CBZ can exacerbate seizures, and cause developmental regression in children. Careful patient selection, when choosing CBZ as treatment, and prompt recognition of clinical deterioration and intervention, may help avoid or reverse these paradoxical reactions.

RÉSUMÉ: *Exacerbation des crises et régression développementale sous carbamazépine. Introduction:* Une exacerbation inattendue des crises peut survenir suite au début du traitement avec la carbamazépine (CBZ). Nous avons examiné la fréquence de ces réactions chez notre population de patients dans un hôpital de soins tertiaires pour enfants. *Méthodes:* Une analyse rétrospective de la banque de données de notre clinique a identifié 129/691 (18.6%) patients épileptiques qui ont été traités par la CBZ en monothérapie. On y a substitué une autre médication chez 38/129 enfants. Chez 11/38 (28.5%), une détérioration clinique et/ou EEG a été observée. Deux patients ayant présenté une exacerbation similaire, identifiés dans une autre institution, sont également inclus dans notre analyse. Nous rapportons les observations chez ces 13 cas. *Résultats:* Deux groupes ont été identifiés: le groupe I - 6 patients ayant un examen neurologique normal, une activité de fond de l'EEG normale et un diagnostic d'épilepsie généralisée idiopathique. Le groupe II - 7 patients ayant un examen neurologique anormal et/ou une activité de fond de l'EEG anormale. Suite à l'introduction du traitement par la CBZ, une exacerbation des crises de même type, l'apparition de nouveaux types de crises, une régression comportementale et une détérioration concomitante de l'EEG ont été rapportées dans les deux groupes. Une amélioration dramatique dans le contrôle des crises a été observée suite à l'arrêt de la CBZ et à la substitution d'un autre anticonvulsivant. *Conclusion:* Les médecins qui traitent l'épilepsie doivent être avertis que la CBZ peut exacerber les crises et causer une régression développementale chez les enfants. Une sélection soigneuse des patients qui reçoivent la CBZ et une détection précoce de la détérioration clinique ainsi qu'une intervention précoce peuvent aider à éviter ou à contrer ces réactions paradoxales.

Can. J. Neurol. Sci. 1998; 25: 287-294

Adverse drug reactions (ADRs) to anticonvulsants are not uncommon and constitute an important cause of treatment failure. The nature of the ADRs is varied, and (rarely) includes exacerbation of seizures. Seizure exacerbations (increased frequency and duration) and progressive encephalopathy due to antiepileptic medication were first documented with phenytoin.^{1,2} Carbamazepine (CBZ) is considered a safe drug to treat seizures in both children and adults. It has been used as a first line drug for both partial, as well as primary generalized seizure disorders.^{3,4} Paradoxical exacerbation of seizures associated with carbamazepine therapy has been described previously.^{5,6} The nature of this aberrant response is unresolved and the exact incidence of this reaction remains to be established. Although

well documented, this paradoxical reaction is seldom recognized in clinical practice, reflecting continued lack of awareness of the problem amongst physicians in practice. We retrospectively analyzed our experience with CBZ therapy in childhood epilepsy amongst patients treated in the epilepsy clinic setting in a

From the Discipline of Pediatrics (Neurology) (A.N.P.) The Charles A. Janeway Child Health Centre, and the Discipline of Medicine (Neurology) (M.S.), Memorial University of Newfoundland, St. John's, Newfoundland and the Division of Pediatric Neurology (M.S.), Princess Margaret Hospital Perth, Australia.¹

RECEIVED MARCH 16, 1998. ACCEPTED IN FINAL FORM JULY 15, 1998.

Reprint requests to: Asuri N. Prasad, Discipline of Pediatrics (Neurology), The Charles A. Janeway Child Health Centre, Memorial University of Newfoundland, Janeway Place, St. John's, Newfoundland, Canada A1A 1R8

tertiary care institution (The Charles A. Janeway Child Health Centre, St. John's, Newfoundland, and the Princess Margaret Hospital, Perth, Australia).

METHODS

All children treated with CBZ from (1991-1997) at the epilepsy clinic based at the only tertiary care children's hospital in St. John's, Newfoundland were identified using the clinic database and hospital records. Those children who met any of the following criteria after commencement of CBZ therapy were included in the study and hospital case records were reviewed: 1) worsening seizures (> than 50% increase in frequency above baseline and/or longer duration); 2) onset of new seizure types; 3) documented EEG deterioration after treatment; 4) progressive encephalopathy, and cognitive decline.

Retrospective analysis of our pediatric neurology clinic database from 1991-1997 identified 681 patients with epilepsy. Of these, 128 had been treated only with carbamazepine, usually as monotherapy. Thirty-eight (38) of these 128 were switched to an alternate antiepileptic drug for one of several identifiable reasons namely; development of an unacceptable adverse effect (such as a skin rash), perceived ineffectiveness of the drug, or due to possible exacerbation of seizures. 11 (8.5%) of 128 cases met our selection criteria. We have included in our analysis, two

additional patients identified as having had a similar aberrant reaction to CBZ by one of the authors (LN) at Princess Margaret Hospital, Perth, Australia.

All patients had been assessed, and all EEGs interpreted by a pediatric neurologist. Charts were reviewed for seizure characteristics, antiepileptic drugs (dosages and levels), associated neurological abnormalities, return of seizures to baseline upon withdrawal of carbamazepine, and EEG results. The EEG records that were available were reviewed by one of the authors and found to be consistent with the original interpretations made.

RESULTS

The clinical features and EEG findings of the 13 patients are described in Tables 1 and 2. Their mean age was 7.9 years. The mean dose of carbamazepine was 20.0 mg/kg/day. Two of 13 patients were taking an additional drug when carbamazepine was started, one on gabapentin (GBP), and the other on valproic acid (VPA); these were weaned during CBZ therapy. In two instances no information on blood levels of CBZ was available at the time of deterioration. In four patients, the deterioration coincided with an increase in dosage, even though these increments were in the recommended dosage range for CBZ and did not produce any signs of clinical toxicity. The patients could be

Table 1: Clinical and EEG characteristics of Group I patients (normal neurological examination and normal EEG background).

Pt.	Age/ Sex	Neurologic Abnormalities	Clinical Seizure type	EEG Abnormalities prior to CBZ treatment	EEG Abnormalities during deterioration	Duration of therapy to exacerbation* (mos.)	Total duration on CBZ (mos.)	Dose mg/kg	CBZ level (17- 42mmol)	Other AED's at initiation of CBZ	Substituted drug	Seizure exacerbation observed
1	13/M	None	CPS/ GTC SWC	2 - 2.5 Hz Generalized spikes	Multifocal independent	1	8	18	21	None	VPA	Prolonged frequent absence seizures
2	10/F	None	GTC	Multifocal SWC	Slow background multifocal SWC	2 *	19	20	22	None	VPA	Nonconvulsive Status
3	7.5/M	None	Absence GTC	2 - 4 Hz Poly- SWC	3 Hz SWC	1	11	18	29.3	VPA	VPA	Prolonged and frequent absence seizures
4	16/M	None	CPS/ GTC	Independent focal spikes	3 Hz SWC	2	6	N/A	27	None	VPA	Nonconvulsive Status
5	5/F	None	GTC	Generalized SWC Photo paroxysmal response	Generalized SWC, PSWC	6	3	22	NA	None	LTG CLO	Behavioral change, drop attacks, myoclonic jerks
6	3/M	None	GTC	Generalized sharp and slow wave	Excessive slow	2 weeks	< 1	23	10.2 µg (6-12µg)	None	VPA	Atonic, tonic and myoclonic seizures, GTC seizures also increased in frequency.

* Duration of therapy to exacerbation post increased dose of CBZ (Carbamazepine);

• CLO (Clobazam); VPA (Valproic Acid); CPS (complex partial seizures); GTC (generalized tonic clonic seizures); SWC (Spike Wave Complexes); PSWC (PolySpike and Wave complexes)

Table 2: Clinical and EEG characteristics of Group II patients (Abnormal neurological examination, abnormal EEG background).

Pt.	Age/ Sex	Neurologic Abnormalities	Clinical Sz. type Prior to CBZ	EEG Abnormalities at the time of therapy	EEG Abnormalities Exacerbation seizure Exacerbation	Duration to Therapy * (mos.)	Duration of	Dose mg/kg	CBZ level (17- 42µmol)	Other AED's at time of CBZ initiation	Substituted drug	Seizure exacerbation observed
7	5/M delay	Developmental ADD	Febrile	Normal Slow SWC	Frontal slow	1	24	26	33.7	None	VPA	Myoclonic
8	4.8/F	Cranio-pharyngioma Watershed infarcts	CPS	Slow background Focal repetitive sharp waves	Slow background continuous focal slow SWC	0.5	2	18	NA	GBP	VPA	Atonic
9	7/F	Angelman's syndrome Spastic tetraparesis	CPS/ GTC	Slow background Focal spikes	Slow background Slow SWC	3	5	30	25.8	None	LTG	Complex
10	6/M	Ceroid Lipofuscinosis	CPS/ Atypical Absence	Slow background Generalized Slow SWC	Slow background multifocal spikes	1	3	33	45	None	CLB	Atonic and Myoclonic
11	7/M	Cerebral dysgenesis Right hemiparesis	CPS	Asymmetry Increased beta, Slow posterior rhythm	Focal spike wave with generalization	1	10	20	31.7	None	VPA, PHT	Frequent Complex partial Seizure
12	11/F	Developmental delay, Seizures	CPS /GTC	Slow background Asynchronous SWC, Bursts of generalized SWC	Prolonged runs of Slow SWC.	3	5	15	NA	None	CLB	EEG deterioration alone
13	9/F	Arnold-Chiari malformation Spina-bifida	Atypical absence /GTC	Slow background	Diffuse slow background Generalized slow spike wave	13	18	18	25.4	None	VPA	Frequent complex partial seizures, cognitive decline, behavioral regression

* Duration of therapy to exacerbation following a dose increment of CBZ.

VPA (Valproic Acid); PHT (Phenytoin); LTG (Lamotrigine); GBP (Gabapentin); CLB (Clobazam); NA (Information not available)

CPS (complex partial seizures); GTC (generalized tonic clonic seizures); SWC (Spike Wave Complexes); PSWC (PolySpike and Wave complexes)

categorized retrospectively into two groups on the basis of their neurological findings and EEG profile.

Group I: 6 patients had normal neurological exams and normal EEG backgrounds. CBZ therapy in these patients had been initiated based on a clinical diagnosis of generalized tonic clonic seizures or complex partial seizures. The decision to begin treatment had already been made by the patient's primary care physician prior to referral. During exacerbation, 4 developed prolonged absence seizures, 2 of the 4 developed absence status, 2 developed new seizure types (atonic, myoclonic and tonic seizures), 2 developed behavioral regression. In one patient, preexisting generalized seizures dramatically increased in frequency above the baseline.

Group II: 7 patients had either an abnormal neurological examination and/or an abnormal EEG background. Seizure etiologies were varied and included; developmental delay of unknown etiology in two (2), Angelman syndrome in (1), cerebral dysgenesis in (1), spina bifida with an associated Chiari malformation in (1). Neuronal ceroid lipofuscinosis was diagnosed later in (1) and finally a child with a craniopharyngioma, who had developed cerebral infarction and seizures post resection (1) (Table 2). At onset, these patients often had complex partial seizures as well as other seizure types such as atypical

absences, and or generalized tonic clonic seizures. EEG findings prior to introduction of CBZ showed background abnormalities as well as focal or multifocal epileptiform discharges in 6/7 patients, in one patient the background was normal. After introduction of carbamazepine therapy, three patients (3) developed new seizure types, preexisting seizures worsened in (3). One patient manifested marked EEG deterioration without worsening of seizures. The new seizure types seen included; atonic (1), myoclonic (1), both atonic and myoclonic seizures (1). Exacerbation of preexisting complex partial seizures occurred in (1), new complex partial status epilepticus occurred in (1); the third developed a general decline in cognitive function along with increasingly frequent seizures. EEG deterioration of background (slow wave activity) accompanied by the appearance of focal or generalized slow spike wave abnormalities was seen in all seven patients at the time of seizure exacerbation. These patients experienced a remission in terms of seizure control, and/or reported the disappearance of myoclonic, atonic or tonic seizures following withdrawal of CBZ and substitution with another antiepileptic medication. In a single instance, where there was only a cognitive decline reported, the child's abilities returned to baseline following a similar intervention.

CASE REPORTS

Illustrative case reports from each group are described below.

Patient 3 - Table 1

A 7.5-year-old male suffered a head injury resulting in transient loss of consciousness. His family physician evaluated him; follow up investigation by EEG and cranial CT was normal. Six days later he developed a generalized tonic-clonic seizure, the EEG showing bilaterally synchronous polyspike and wave discharges at 2 - 4 Hz. Low dose valproic acid (VPA) therapy did not result in adequate seizure control, so CBZ was added. Within 4 weeks he developed frequent daily staring spells and the EEG showed prolonged bursts of generalized 3 Hz spike wave complexes (Figure 1). CBZ was discontinued, but high dose valproic acid therapy resulted in seizure remission.

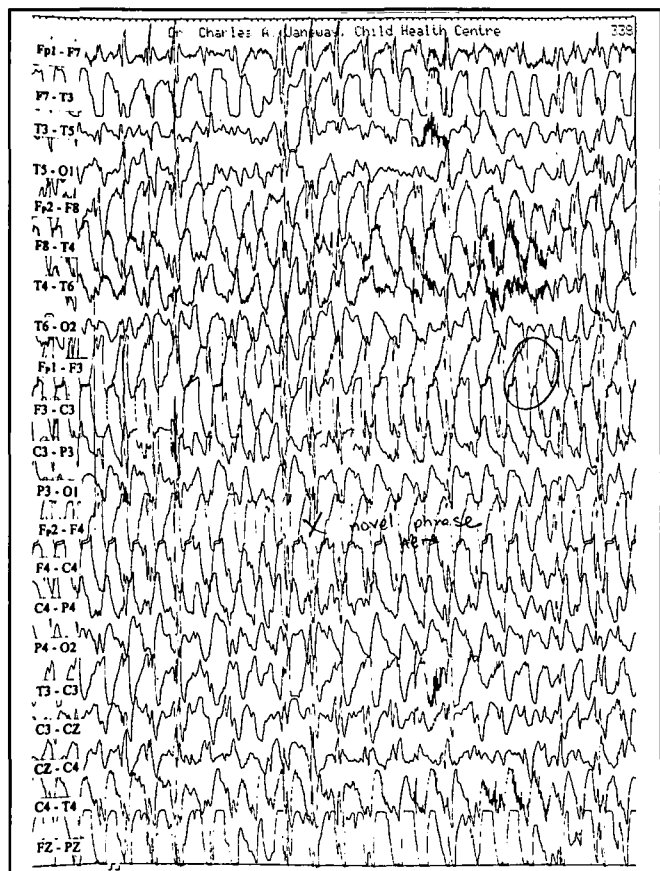


Figure 1: (Patient 3, Table 1) Prolonged paroxysms of generalized spike wave complexes (3Hz) are seen. The recording was obtained during frequent and longer absences reported while on treatment with CBZ and VPA. Vertical lines are 1 sec apart. The recording was obtained at a sensitivity of 7µV/mm.

Patient 8 - Table 2

A 4.8-year-old female, developed a generalized tonic-clonic seizure requiring ICU admission after craniopharyngioma resection. Imaging studies disclosed left frontal and right occipital-parietal watershed infarcts. She then developed frequent focal motor seizures involving the right face and arm. An EEG showed slow disorganized background and focal epileptiform activity in the left frontal region. There was only a partial response to gabapentin, so CBZ was added and gabapentin discontinued which resulted in improved control of her focal seizures. A

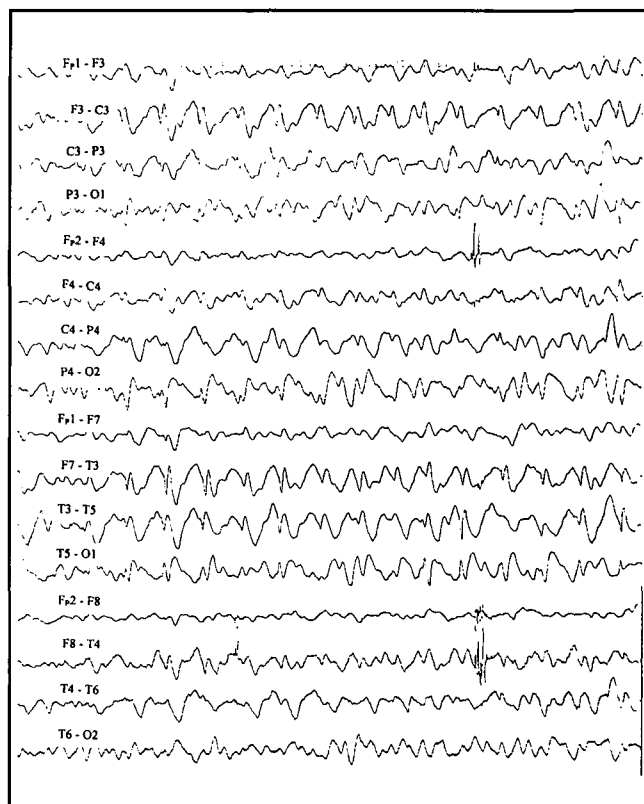


Figure 2: (Patient 8, Table 2) This tracing was obtained when frequent "drop attacks" and myoclonic jerks were reported, while on treatment with CBZ. A slow background with nearly continuous focal and generalized slow spike wave complexes is seen. Vertical lines are 1 sec apart. The recording was obtained at a sensitivity of 7µV/mm.

dose increase two weeks later to 18 mg/kg was followed by the appearance of two generalized tonic-clonic seizures. Within the next two weeks, she was experiencing 2 - 4 "drop attacks" per day, the EEG showing slow background with continuous focal and generalized slow spike wave discharges (Figure 2). These atonic seizures remitted when CBZ was discontinued. VPA was then instituted, with satisfactory seizure control.

Patient 13 - Table 2

A 9-year-old female with surgically repaired neural tube defect, Arnold Chiari II malformation, and a ventriculoperitoneal shunt inserted in neonatal period, developed episodic drowsiness and headaches at the age of 4 years. EEG showed diffuse slowing with occasional right frontal spikes. She was started on CBZ for these episodes with a presumptive diagnosis of complex partial seizures. After 13 months of therapy, she began to experience spells of staring, during which she would appear dazed and be non-communicative. Shortly after falling asleep, she would awaken, sit up, her eyelids would flicker and both her arms would jerk repeatedly. She was noted to regress in behavior, and lost previously learnt skills. The EEG showed diffuse slowing with focal epileptiform discharges in the right fronto-central region and frequent generalized bursts of epileptiform discharges (Figure 3). VPA was added, with only a modest improvement in her behavior. It was only when CBZ was discontinued, that a marked improvement in behavior and complete recovery of her abilities followed. Subsequent EEGs in follow up were normal.

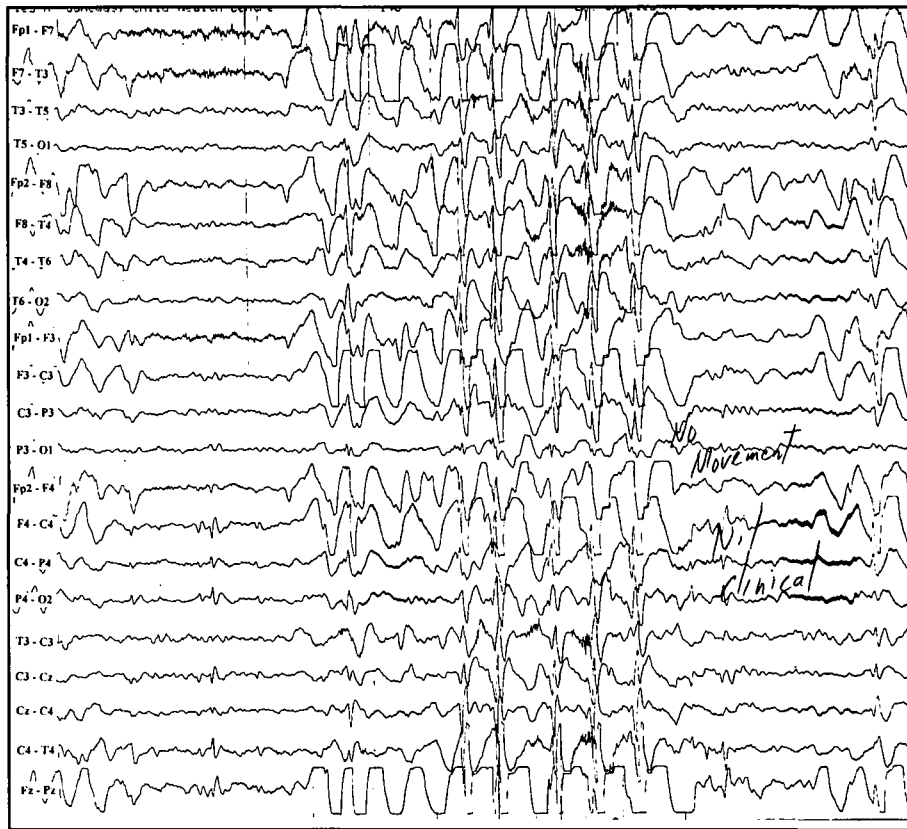

Figure 3: (Patient 13, Table 3) This tracing was obtained during behavioral and developmental regression reported while on treatment with CBZ. Nearly continuous focal right frontal and generalized spike wave paroxysms are seen. Vertical lines are 1 sec apart. The recording was obtained at a sensitivity of $7\mu\text{V}/\text{mm}$.

DISCUSSION

In a recent editorial in *Epilepsia*, the important issue of exacerbation of seizures by anticonvulsants was addressed.⁷ It was pointed out that the phenomenon might be more common than is considered in practice, and is probably overlooked when encountered. Increased seizure frequency after commencing antiepileptic therapy may be due to several factors; an underlying progressive neurological disorder; as a consequence of a drug interaction with a comedication; or a spontaneous fluctuation in the natural history of the seizure disorder. Periods of worsening of seizure frequency occur in the natural course of many epilepsies due to many known (stress, fatigue and hormonal changes) and unknown factors.⁷ However, a direct effect resulting in deterioration in seizure control, or seizure exacerbation may also follow the introduction of antiepileptic medication.

CBZ has been relied upon as a first line antiepileptic drug in the treatment of most primary and secondarily generalized seizures.⁸ However, there are many reports of carbamazepine resulting in paradoxical exacerbation of seizures or onset of new seizure types. Shields and Saslow described five children who had 'an acute aberrant reaction' characterized by the onset of atonic, absence and/or myoclonic seizures following initiation of CBZ therapy.⁵ These seizures resolved in four of the children when CBZ was withdrawn. The remaining patient was later diagnosed with neuronal ceroid lipofuscinosis.

New onset 3 Hz spike and wave activity associated with generalized tonic clonic seizures following initiation of CBZ was observed in three children, but resolved on discontinuation of medication.⁹ A dose-dependent effect was described in four adults with childhood onset absence seizures and generalized tonic clonic seizures in later life, who had increased absence spells with the use of CBZ prescribed for control of generalized tonic clonic seizures.¹⁰

CBZ-exacerbated seizures appear to occur mainly in patients with one of four epileptic syndromes: childhood absence, focal symptomatic frontal lobe, Lennox-Gastaut, or severe myoclonic epilepsy of childhood.¹¹ These absence, tonic-clonic, myoclonic, or atonic seizures can be confirmed by video-EEG.⁶ Precipitation of continuous spike waves in sleep, and neuropsychological deterioration has also been reported in patients with the Landau-Kleffner syndrome treated with CBZ.¹² With discontinuation of CBZ, the frequency and severity of the seizures returned to baseline in the majority. Similar events have been reported with CBZ use in adults with partial and generalized seizures.^{13,14} Raised intracranial pressure and transient MRI abnormalities were also reported in a single patient with refractory absence status following treatment with CBZ.¹⁵ In this situation too, discontinuation of CBZ was important in reversing symptoms.

There are several difficulties in critically analyzing reported data on the occurrence of seizure exacerbation following treatment with CBZ. An estimate the true magnitude of the problem

Table 3: Seizure exacerbation and developmental regression with carbamazepine: seizure types induced, EEG abnormalities seen, and syndromic diagnoses associated.

	Clinical correlates	References
Aberrant reactions induced by CBZ		
Exacerbation of seizures	Typical absences, atypical absences, myoclonic, atonic, tonic seizures	5
	Nonconvulsive status epilepticus	6
	Nonepileptic myoclonus	26
	Infantile spasms	22
Cognitive decline without seizures		16
Pretreatment EEG abnormalities that predict aberrant responses to CBZ		
	Generalized 3Hz spike and wave complexes	6
	Generalized fast poly spike and wave complexes	22
	Generalized slow spike and wave complexes	22
	? Multifocal abnormalities (This study)	
	? Diffuse background slowing (This study)	
Syndromic diagnoses where the use of CBZ may result in seizure exacerbation		
	Juvenile myoclonic epilepsy	27
	Idiopathic generalized epilepsy absence	14
	Myoclonic epilepsies of childhood	11,28
	Frontal lobe symptomatic epilepsy	11
	Landau Kleffner syndrome	12
	Angelman syndrome	29
	Lennox-Gastaut syndrome	11

is not available. Most of the reports are retrospective, carried out on small numbers of patients, with several methodological limitations. There is lack of uniformity in reporting seizure deterioration or worsening. These factors limit the value of a "metanalysis". Nevertheless, meaningful conclusions can still be drawn.

In the present series, most patients were on monotherapy, and in appropriate dosages and with blood levels (where available) within a therapeutic window. No patient reported any clinical signs of toxicity. The aberrant response to CBZ was seen in children with idiopathic generalized epilepsy as well as in those with symptomatic and cryptogenic epilepsy. Over the six-year experience reported here, only 8.5% of all patients treated in our clinic (Janeway Child Health Centre) with CBZ reported seizure exacerbation.

CBZ-induced seizure exacerbations are variable in character. In our patients with idiopathic generalized epilepsy, frequent absences, (2 patients, Table 1) tended to occur. The absence seizures may be longer in duration, culminating in nonconvulsive status (2 patients, Table 1). Such aberrant reactions can also manifest as new seizure types, such as myoclonic jerks, atonic "drop attacks" and myoclonic-astatic seizures as seen in our patients (Table 2), and reported by others.⁵ General decline in cognitive function with behavioral regression (patients 5 and 6) was also seen. Others have reported similar behavioral changes,¹⁶ though in our case there was associated evidence of EEG deterioration. Table 3 summarizes the clinical conditions in which such exacerbations have been reported, and the new seizure types induced.

The effect of CBZ on the EEG of patients with seizures has been widely studied. Early studies reported results that were conflicting, both deterioration¹⁷ and the absence of consistent changes being reported.^{18,19} It led some to suggest that follow up EEG recordings were of little value in patients during CBZ therapy.²⁰ A double blind study comparing CBZ to phenytoin concluded that: "while using carbamazepine, the patients manifested a significant overall increase in diffuse slow waves and an increase in generalized epileptiform discharges without significant changes in seizure incidence".²¹ A recent study specifically examined EEGs before and after CBZ treatment in 59 children aged less than six years. Forty-four percent (44%) had significantly more abnormal EEG findings during therapy, characterized by the appearance of generalized spike/polyspike-and-wave discharges. A majority (65%) of those who experienced seizure exacerbation were likely to have suffered from cryptogenic epilepsy. A number of these patients eventually developed clearly defined epilepsy syndromes during follow up (e.g. myoclonic-astatic syndrome of Doose, cryptogenic infantile spasms). The authors speculate on the possibility that CBZ accentuates the natural history of these epilepsies and allows full expression of paroxysmal discharges associated with these epilepsies.²²

The underlying mechanism, by which CBZ exacerbates certain seizure types and not others, remains unexplained. The anti-convulsant effect of CBZ is mediated through its action on voltage gated sodium channels to slow recovery after inactivation. In the rat pentylentetrazol model, CBZ does not increase seizure threshold, but does prevent seizure spread.²³ Snead has

postulated a greater susceptibility of the developing brain to the types of seizures induced by carbamazepine.⁶ The perturbation underlying absence seizures may lie in a defect within the thalamocortical oscillations that alternate between GABA-mediated inhibition and glutamate-mediated excitation. Pharmacological manipulation of both GABA and non-GABA mediated mechanisms can result in exacerbation of absence seizures.²⁴ The ability of CBZ to influence this thalamocortical oscillatory network may in some way be responsible for the observed exacerbation of absences. The ability to elicit new seizure types in certain epilepsy syndromes is now recognized with other anticonvulsants as in the case of vigabatrin.²⁵ CBZ too, may be involved in generating new seizure types in certain cryptogenic epilepsies of childhood, but the mechanisms underlying such effects remain poorly understood. In six documented cases of CBZ-related seizure exacerbation, a toxic level of carbamazepine-10-11-epoxide was demonstrated. Altered carbamazepine metabolism was thought to be a potential cause of deterioration in seizure control.^{13,26} However, each of these patients was being treated with co-medications that could account for the elevated epoxide levels. Our series provides indirect evidence against drug interactions being implicated as a cause of seizure exacerbation, as only 2 of the 11 patients were on additional anticonvulsants. The doses and blood levels of CBZ at the time of exacerbation indicate that drug dosages were modest, measured CBZ levels were within a therapeutic window, and no secondary adverse effects were reported. Epoxide levels were not measured in our cases, a limitation owing to difficulties in obtaining such an assay at locally, and due to the retrospective nature of this study.

While deterioration in seizure control may occur in the course of many neurodegenerative disorders, such an occurrence may indicate disease progression. In one of our patients (No.10 Table 2) later diagnosed with ceroid lipofuscinosis, seizure exacerbation was noted early following treatment with CBZ. Withdrawal of CBZ and substitution with other antiepileptic medication resulted in improved seizure control. Thus, even in situations where worsening of seizures may be expected as a progression of the underlying disorder, awareness and timely recognition of this complication may be helpful.

Prediction of this paradoxical response would allow an appropriate therapeutic choice of antiepileptic medication at the outset, preventing this complication. On reviewing the published clinical data, seizure exacerbation/deterioration following introduction of CBZ can be anticipated in three groups. Patients selected for treatment with CBZ should be carefully screened for any clinical or EEG features belonging to these groups. 1) Patients with idiopathic generalized epilepsy, particularly those with typical absence seizures,¹¹ juvenile myoclonic epilepsy,²⁷ and patients with generalized tonic clonic seizures with absence attacks in infancy. 2) Patients with mixed seizures in whom a syndromic diagnosis has not been established.^{5,6} In this group, the presence of EEG background abnormalities and of generalized and or multifocal epileptiform abnormalities may be additional grounds for caution. 3) In those patients where a syndromic diagnosis has been established, such as in the Lennox-Gastaut syndrome,⁶ the Landau-Kleffner syndrome,¹² and the myoclonic epilepsies of childhood,^{11,28} an unfavorable outcome may be anticipated and the use of CBZ avoided.

In summary, carbamazepine therapy can result in paradoxical

exacerbation of seizures as well as deterioration in behavior. This response may be seen with all forms of childhood epilepsy, idiopathic, cryptogenic and symptomatic. The onset of this reaction is unpredictable, occurring immediately or appearing after a delay of several months after introduction of CBZ. The deterioration may take the form of increasing seizure frequency and duration, appearance of new seizure types or a general decline in cognitive function and behavioral change. EEG worsening with the appearance of generalized spike and polyspike wave discharges of prolonged duration as well as changes in the background often accompanies this response. The occurrence of this complication during treatment of absence seizures can be easily predicted and avoided. It may be more difficult to do so in the case of symptomatic and cryptogenic epilepsies. However, dramatic benefit to the patient may be derived by early recognition of this complication, withdrawal of CBZ, and substitution with an alternative.

ACKNOWLEDGEMENTS

The authors are indebted to S Penney RN for her help with the clinic database, Drs. D.J. Buckley, and M. Hall, J. C. Jacob, G. Knight and J. D. Hobday for sharing information on their patients, and to Dr. W. Pryse-Phillips for reviewing the manuscript and his valuable comments.

REFERENCES

1. Levy L, Fenichel G. Diphenylhydantoin activated seizures. *Neurology* 1965; 15: 716-722.
2. Vallarta JM, Bell DB, Reichert A. Progressive encephalopathy due to chronic hydantoin intoxication. *Am J Dis Child* 1974; 128: 27-34.
3. Wilder BJ, Rangel R. Carbamazepine efficacy in adults with partial and generalized tonic-clonic seizures. *Epilepsia* 1987; 28 Suppl 3: S25-S28.
4. Dodson WE. Carbamazepine efficacy and utilization in children. *Epilepsia* 1987; 28 Suppl 3: S17-S24.
5. Shields WD, Saslow E. Myoclonic, atonic, and absence seizures following institution of carbamazepine therapy in children. *Neurology* 1983; 33: 1487-1489.
6. Snead OC 3rd, Hosey LC. Exacerbation of seizures in children by carbamazepine. *N Engl J Med* 1985; 313: 916-921.
7. Loiseau P. Do antiepileptic drugs exacerbate seizures? *Epilepsia* 1998; 39: 2-4.
8. de Silva M, MacArdle B, McGowan M, et al. Randomised comparative monotherapy trial of phenobarbitone, phenytoin, carbamazepine, or sodium valproate for newly diagnosed childhood epilepsy. *Lancet* 1996; 347: 709-713.
9. Johnsen S, Tarby T, Sidell A. Carbamazepine induced seizures. *Ann Neurol* 1984; 16: 392-393.
10. Liporace JD, Sperling MR, Dichter MA. Absence seizures and carbamazepine in adults. *Epilepsia* 1994; 35: 1026-1028.
11. Horn CS, Ater SB, Hurst DL. Carbamazepine-exacerbated epilepsy in children and adolescents. *Pediatr Neurol* 1986; 2: 340-345.
12. Marescaux C, Hirsch E, Finck S, et al. Landau-Kleffner syndrome: a pharmacologic study of five cases. *Epilepsia* 1990; 31: 768-777.
13. So EL, Ruggles KH, Cascino GD, Ahmann PA, Weatherford KW. Seizure exacerbation and status epilepticus related to carbamazepine-10,11-epoxide. *Ann Neurol* 1994; 35: 743-746.
14. Sachdeo R, Chokroverty S. Enhancement of absence with Tegretol (Abstract). *Epilepsia* 1985; 26: 534.
15. Callahan DJ, Noetzel MJ. Prolonged absence status epilepticus associated with carbamazepine therapy, increased intracranial pressure, and transient MRI abnormalities. *Neurology* 1992; 42: 198-201.
16. Silverstein FS, Parrish MA, Johnston MV. Adverse behavioral reactions in children treated with carbamazepine (Tegretol). *J Pediatr* 1982; 101: 785-787.

17. Marjerrison G, Jedlicki SM, Keogh RP, Hrychuk W, Poulakakis GM. Carbamazepine: behavioral, anticonvulsant and EEG effects in chronically-hospitalized epileptics. *Dis Nerv Syst* 1968; 29: 133-136.
18. Pryse-Phillips WE, Jeavons PM. Effect of carbamazepine (Tegretol) on the electroencephalograph and ward behaviour of patients with chronic epilepsy. *Epilepsia* 1970; 11: 263-273.
19. Rodin EA, Rim CS, Rennick PM. The effects of carbamazepine on patients with psychomotor epilepsy: results of a double-blind study. *Epilepsia* 1974; 15: 547-561.
20. Jeavons P. Carbamazepine and the EEG. *In*: Wink C, ed. *Tegretol in epilepsy: report of an international clinical symposium*. Manchester: C. Nicholls, 1972: 35-39.
21. Wilkus R, Dodrill C, Troupin A. Carbamazepine and the electroencephalogram in epileptics: a double blind study in comparison to phenytoin. *Epilepsia* 1978; 19: 283-291.
22. Talwar D, Arora MS, Sher PK. EEG changes and seizure exacerbation in young children treated with carbamazepine. *Epilepsia* 1994; 35: 1154-1159.
23. Swinyard E, Woodhead J. Experimental detection, quantification and evaluation of anticonvulsants. *In*: Woodbury D, Penry J, Pip-penger C, eds. *Antiepileptic Drugs*. New York: Raven Press, 1982: 111-126.
24. Snead OC 3rd. Basic mechanisms of generalized absence seizures. *Ann Neurol* 1995; 37: 146-157.
25. Lortie A, Chiron C, Mumford J, Dulac O. The potential for increasing seizure frequency, relapse, and appearance of new seizure types with vigabatrin. *Neurology* 1993; 43: S24-S27.
26. Dhuna A, Pascual-Leone A, Talwar D. Exacerbation of partial seizures and onset of nonepileptic myoclonus with carbamazepine. *Epilepsia* 1991; 32: 275-278.
27. Sozuer D, Atakli D, Atay T, Baybas S, Arpaci B. Evaluation of various antiepileptic drugs in juvenile myoclonic epilepsy. *Epilepsia* 1996; 37: 77.
28. Wakai S, Ito N, Sueoka H, et al. Severe myoclonic epilepsy in infancy and carbamazepine [letter]. *Eur J Pediatr* 1996; 155: 724.
29. Viani F, Romeo A, Viri M, et al. Seizure and EEG patterns in Angelman's syndrome. *J Child Neurol* 1995; 10:467-471.