


Original Article

Adult-Onset EIF2B-Pathies: A Clinical, Imaging and Genetic Profiling with Literature Review

Sangeeth Thuppanattumadam Ananthasubramanian¹, Gautham Arunachal², Hansashree Padmanabha¹ and Rohan Ramachandra Mahale¹ 

¹Department of Neurology, National Institute of Mental Health and Neurosciences, Bengaluru, KA, India and ²Department of Human Genetics, National Institute of Mental Health and Neurosciences, Bengaluru, KA, India

ABSTRACT: Background: Vanishing white matter syndrome is one of the leukoencephalopathies caused by recessive mutations in gene *EIF2B1–5*. Adult-onset EIF2B-pathies (clinical onset after age 16 years) have been reported to be less common. **Objective:** Description of the clinical, imaging and genetic profile of adult-onset EIF2B-pathies and comparison of Indian cohort with Asian and European cohorts. **Methods:** Report of two cases of adult-onset EIF2B-pathies and a comprehensive review of genetically confirmed adult-onset EIF2B-pathies since 2001 from Indian, Asian and European cohorts. **Results:** Two patients were females, with median age at presentation of 25.5 years (24–27 years) and onset at 19 years (18–20 years). The median duration of symptoms was 6.5 years (6–7 years). Both had cerebellar ataxia, spasticity, cognitive impairment and bladder involvement. Brain magnetic resonance imaging (MRI) showed leukoencephalopathy with rarefaction in both patients and corpus callosum involvement in one patient. Genetics showed homozygous missense variant in the *EIF2B3* gene in both patients. The Indian cohort of seven patients had similar clinical and radiological features and common variants in *EIF2B3* ($n = 4$). The Asian cohort had 24 cases, and the European cohort had 61 cases with similar clinical features, radiological features and common variants in *EIF2B5*. **Conclusion:** Adult-onset EIF2B-pathies have a distinct clinical profile of female predominance with cerebellar ataxia, spasticity and cognitive decline as the commonest triad of clinical manifestations and leukoencephalopathy with rarefaction on brain MRI. Variants in *EIF2B5* were common in the Asian and European cohorts and *EIF2B3* in the Indian cohort.

RÉSUMÉ : Pathologies du gène EIF2B chez l'adulte : profil clinique, d'imagerie et génétique avec une revue de la littérature. Contexte : Le syndrome de disparition de la matière blanche (DMB) est l'une des leuco-encéphalopathies causées par des mutations récessives du gène *EIF2B1–5*. Les pathologies du gène EIF2B chez l'adulte (apparition clinique après l'âge de 16 ans) ont été signalées comme étant moins fréquentes. **Objectif :** Décrire le profil clinique, génétique et d'imagerie des pathologies du gène EIF2B de l'adulte et comparer une cohorte de patients indiens avec des cohortes de patients asiatiques et européens. **Méthodes :** Se pencher sur deux cas de pathologies du gène EIF2B apparus à l'âge adulte ; passer en revue de façon complète les pathologies du gène EIF2B apparues à l'âge adulte et confirmées génétiquement depuis 2001 dans des cohortes de patients indiens, asiatiques et européens. **Résultats :** À noter que 2 patients étaient des femmes dont l'âge médian, au moment de la présentation, était de 25,5 ans (24–27) et de 19 ans (18–20) lors de l'apparition des premiers symptômes de la maladie. La durée médiane des symptômes était de 6,5 ans (6–7). Toutes deux donnaient à voir une ataxie cérébelleuse, une spasticité, des troubles cognitifs et une atteinte de la vessie. Un examen d'IRM du cerveau a montré une leuco-encéphalopathie avec raréfaction chez ces deux patientes ainsi qu'une atteinte du corps calleux chez une d'entre elles. Un test génétique a aussi révélé une variante homozygote faux-sens du gène *EIF2B3* chez ces deux femmes. La cohorte indienne de 7 patients présentait quant à elle des caractéristiques cliniques et radiologiques similaires et des variantes communes du gène *EIF2B3* ($n = 4$). La cohorte asiatique, elle, comptait 24 cas tandis que la cohorte européenne comptait 61 cas avec des caractéristiques cliniques et radiologiques similaires et des variantes communes dans le gène *EIF2B5*. **Conclusion :** Les pathologies du gène EIF2B chez l'adulte révèlent un profil clinique distinct ainsi qu'une prédominance féminine. À titre de manifestations cliniques les plus courantes, cela se traduit notamment par l'ataxie cérébelleuse, la spasticité et un déclin cognitif. Ajoutons également la leuco-encéphalopathie avec raréfaction observée lors d'examen d'IRM. Les variantes du gène *EIF2B5* sont fréquentes au sein des cohortes de patients asiatiques et européens tandis que celles du gène *EIF2B3* le sont dans la cohorte de patients indiens.

Keywords: Adult-onset; EIF2B; leukoencephalopathy; vanishing white matter

(Received 31 May 2024; final revisions submitted 3 July 2024; date of acceptance 9 July 2024)

Corresponding author: Rohan Ramachandra Mahale; Email: rohanmahale83@gmail.com

Cite this article: Thuppanattumadam Ananthasubramanian S, Arunachal G, Padmanabha H, and Mahale RR. Adult-Onset EIF2B-Pathies: A Clinical, Imaging and Genetic Profiling with Literature Review. *The Canadian Journal of Neurological Sciences*, <https://doi.org/10.1017/cjn.2024.308>

© The Author(s), 2024. Published by Cambridge University Press on behalf of Canadian Neurological Sciences Federation.

Highlights

- Cerebellar ataxia, spasticity, cognitive decline are common in adult-onset EIF2B-pathies.
- Imaging shows leukoencephalopathy with areas of rarefaction in all patients.
- *EIF2B5* gene variant is the common variant reported so far.

Introduction

Vanishing white matter syndrome (Online Mendelian Inheritance in Man (OMIM) 620315) or childhood ataxia with central hypomyelination is the most prevalent childhood inherited leukoencephalopathy with a recessive mode of transmission.^{1,2} This syndrome is caused by mutations in the five genes encoding the five subunits of the eukaryotic initiation factor 2B (eIF 2B), which was discovered in 2001.^{3,4} The most common presentation is cerebellar ataxia and spasticity with mental decline at the age of 2–5 years. It is also associated with episodic deterioration following febrile illness or minor head trauma. The clinical spectrum is broad, ranging from congenital forms with rapid death to adult-onset forms with slow neurologic progression; collectively, this group of conditions has been referred to as EIF2B-pathies or EIF2B-related disorders.⁵ The frequency of the adult-onset EIF2B-pathies (clinical onset after age 16 years) has been reported to be < 5%.⁶ Adult-onset EIF2B-pathies are characterized by slowly progressive cerebellar ataxia, spasticity, dementia, seizures, psychiatric symptoms like depression and psychosis and unexplained isolated ovarian failure, which is distinct from childhood onset EIF2B-pathies. Brain magnetic resonance imaging (MRI) has shown to be abnormal with diffuse white matter signal changes (T1-weighted hypointensity and T2-weighted hyperintensity) with white matter rarefaction, including in the corpus callosum.^{7,8} There are reported cases of adult-onset EIF2B-pathies from the European population, but data are scarce from the Asian population. In particular, The clinical, imaging and genetic profile of the adult-onset EIF2B-pathies from the Indian cohort is lacking. This study aims to describe the clinical, imaging and genetic profile of our patients with adult-onset EIF2B-pathies. We consolidated the Asian and European cohorts of adult-onset EIF2B-pathies and compared their clinical, imaging and genetic profiles with the Indian cohort.

Methods

Patients and methods

This was a retrospective cross-sectional, descriptive analysis of patients with adult-onset EIF2B-pathies conducted at a quaternary care hospital in India. Hospital records of patients diagnosed as adult-onset EIF2B-pathies between 2018 and 2023 were searched, and genetically confirmed adult-onset EIF2B-pathies patients were included. The adult-onset EIF2B-pathies were diagnosed based on the age at onset ≥ 16 years with variants in the *EIF2B* gene.⁹ The following clinical data were extracted from the hospital records: age at clinical presentation, age at onset of symptoms (age at which the first neurological sign had been noted), duration of disease (onset of first symptom to the time of presentation), sex, types of symptoms (like cerebellar ataxia, seizures, myoclonus, psychiatric symptoms, cognitive symptoms, etc.), triggers worsening the symptoms, birth history, consanguinity and family history. The clinical examination findings including fundus copy, cranial nerves, motor, sensory, cerebellar, extrapyramidal examination

findings were recorded. Abnormalities in the brain MRI in the form of site of lesion (cerebral hemispheres, brainstem, spinal cord, optic nerves and corpus callosum); signal changes on T1-weighted imaging, T2-weighted imaging, fluid-attenuated inversion recovery (FLAIR), diffusion-weighted imaging and apparent diffusion coefficient image; contrast enhancement; white matter rarefaction; presence of atrophy in the cortical, corpus callosum, cerebellar and brainstem regions and magnetic resonance spectroscopy findings were recorded. Data regarding nerve conduction study, evoked potentials, cerebrospinal fluid analysis and tandem mass spectroscopy were recorded. The study was conducted after approval by the ethics committee (No:NIMH/DO/DEAN (Basic Science)/2020-21). Informed written consent was obtained from the patients for publication. The study was conducted in accordance with the Declaration of Helsinki (1964).¹⁰

Genetic analysis

Clinical exome sequencing was done in both patients with genes associated with white matter disorders guided by the MRI pattern analyzed. The genetic testing Genomic DNA extraction using QIAamp DNA Blood Mini Kit (Qiagen Germany, #51104) was performed on the blood samples of the recruited patients. Identification of variants employed the Genome Analysis Toolkit framework (Broad Institute, Cambridge, MA, USA). The variants were annotated utilizing the online platform, ANNOVAR (<http://www.openbioinformatics.org/annovar/>).34791404. The common variants with a minor allele frequency (MAF) > 0.01 were not considered. Comparison was made with Exome Aggregation Consortium (ExAC), 1000 Genome project and gnomAD database (<https://gnomad.broadinstitute.org/>). The individual sequence variants were interpreted using PolyPhen-2, Sorting Intolerant from Tolerant (SIFT) webserver and MutationTaster. The variants were classified in accordance with American College of Medical Genetics and Genomics standards and guidelines into benign, likely pathogenic or pathogenic. The variants were checked for their novelty by analysis in mutation databases (ClinVar).

Review of literature

We conducted a comprehensive search across publicly accessible medical database of PubMed, employing specific medical subject headings: “adult,” “vanishing white matter” and “eIF2b-related disorder,” to identify relevant studies. Initially, studies underwent a rigorous title and abstract screening process. Subsequently, studies focusing on the Asian and European population were included for further analysis. We included our current study data and other cases published in India and compared with the Asian and the European cohort that was last updated in 2023. The data extraction process encompassed the retrieval of critical information, including demographic parameters, clinical phenotype descriptions and variant details, to facilitate a comprehensive evaluation of the existing literature on this topic. Studies not presented in English or lacking patient details were excluded from consideration.

Statistical analysis

Summary statistics were used to describe the clinical characteristics that were reported by the median and the range. The continuous variables were expressed as mean/median and categorical variables as frequency/percentage.

Results

A total of two cases of adult-onset EIF2B-pathies were available for assessment in our cohort. Three cases of adult-onset EIF2B-pathies were already published from our institute; the other two cases already reported from India were included for the comparison of Indian cohort with the Asian and the European cohort. Two patients included in this study were both females aged 24 and 27 years and had onset at 19 years (18–20 years) of age. The median duration of symptoms was 6.5 years (6–7 years).

Clinical profile

Both patients were born out of consanguineous parentage with normal perinatal history. The initial symptoms were gait ataxia in both patients, followed by limb ataxia and ataxic dysarthria. Both patients had cognitive impairment involving executive functions, memory, visuospatial disorientation and emotional lability. One patient had bladder urgency with urge incontinence and epilepsy. There was no fever-related worsening of symptoms or features suggestive of ovarian failure. Ophthalmological and auditory evaluations were normal. Both patients had gaze-evoked jerky horizontal nystagmus. There were pyramidal signs in the form of spasticity in lower limbs with brisk deep tendon reflexes and extensor plantar response in both patients.

Imaging profile

Patient 1 (Figure 1)

Brain MRI showed diffuse T2/FLAIR hyperintensities in the cerebral white matter, with rarefaction predominantly in the frontoparietal region, including the corpus callosum. Posterior limb of the internal capsule and basal ganglia were spared. Mild cerebellar atrophy was observed.

Patient 2 (Figure 2)

Brain MRI showed extensive T2-FLAIR hyperintensities in the cerebral white matter, sparing the internal capsule, along with rarefaction and mineralization of bilateral globus pallidum, substantia nigra, red nucleus and dentate nuclei. Brainstem and spinal cord atrophy were also observed.

Genetic profile

Patient 1

A homozygous missense variant in exon 7 of the *EIF2B3* gene (c.687T > G), resulting in the substitution of isoleucine with methionine at amino acid 229 (p. Ile229Met). This variant (c.687T > G) has been identified in one individual in 1000 genomes, 8 individuals in ExAC and in 22 individuals in GnomAD. This pathogenic variant was identified with a high level of confidence, as it was predicted to be disease-causing by MutationTaster and was located within the nucleotide diphospho-sugar transferases domain. Furthermore, insilico tools such as SIFT and PolyPhen indicated that this variant is likely deleterious and probably damaging. Importantly, this specific amino acid variation has been previously reported in a patient with leukoencephalopathy with vanishing white matter disease in human gene mutation database (HGMD) (Accession Number: CM066788), confirming its pathogenic significance.

Patient 2

A homozygous missense variant was identified in exon 1 of the *EIF2B3* gene (c.190C > T), resulting in the substitution of proline with serine at codon 64 (p. Pro64Ser), consistent with an autosomal recessive (AR) inheritance pattern. The p. Pro64Ser variant has not been reported in the 1000 genomes and gnomAD database. This variant is exceptionally rare, with an MAF of only

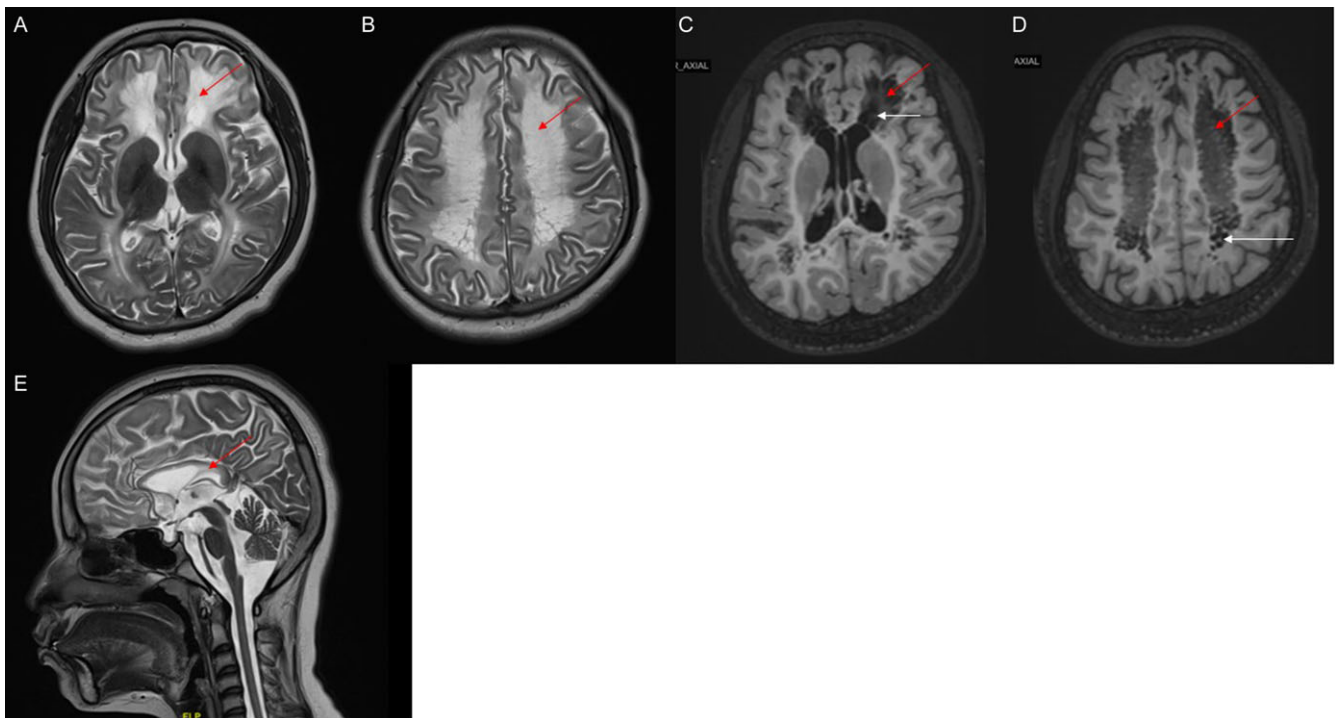


Figure 1. Brain MRI of patient 1. (a) and (b) axial T2-weighted imaging showing diffuse and symmetrical white matter hyperintensities (red arrow); (c) and (d) axial T1-weighted imaging showing symmetrical white matter hypointensities (red arrow) with focal areas of lower signals suggesting rarefaction (white arrow); (e) sagittal T2-weighted image depicts corpus callosum atrophy and hyperintense signal (red arrow). MRI = magnetic resonance imaging.

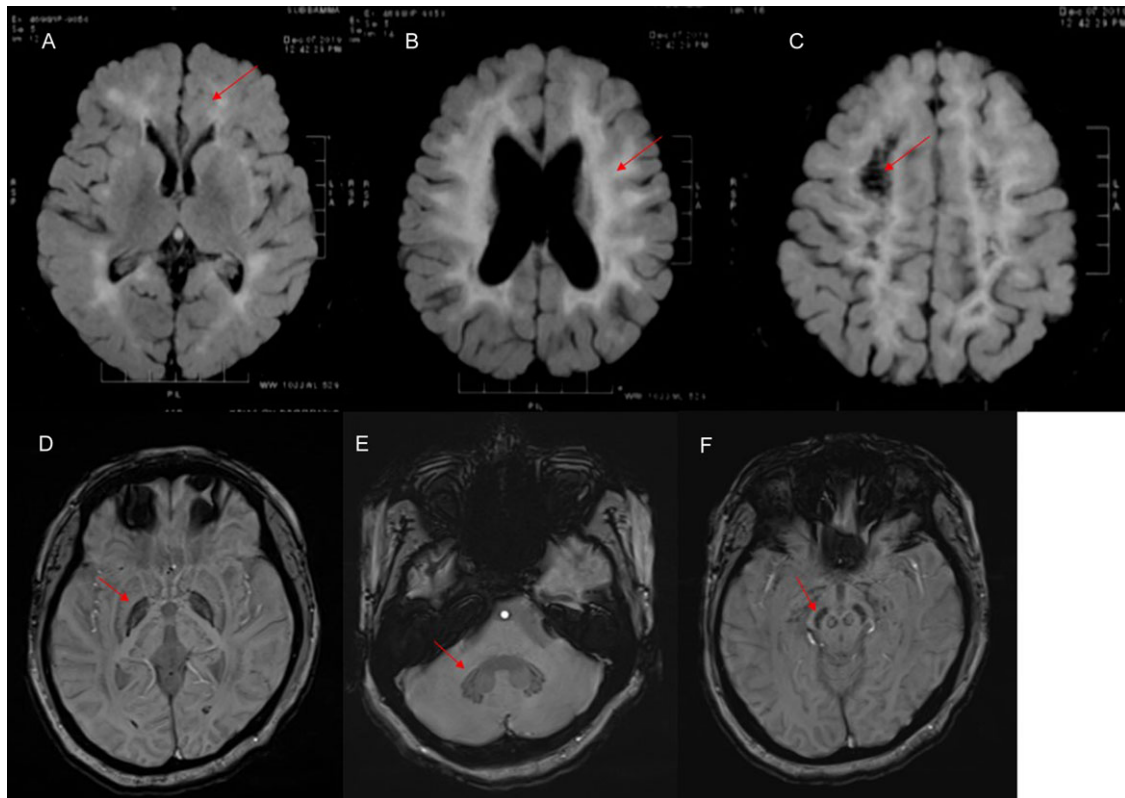


Figure 2. Brain MRI of patient 2. (a), (b) and (c) axial fluid-attenuated inversion recovery images revealing diffuse hyperintense signal of bilateral white matter (a and b) with area of signal suppression suggesting rarefaction (c) (red arrow); (d), (e) and (f) axial susceptibility-weighted image showing mineralization in the globus pallidum, substantia nigra and dentate nucleus (red arrow). MRI = magnetic resonance imaging.

0.002% in an internal database. Notably, multiple *in silico* tools, including PolyPhen-2 (HumDiv), SIFT and likelihood ratio test (LRT), predict that this variant is potentially damaging or probably damaging. The phenotype associated with this variant is supported by strong evidence (PP4), and its extreme rarity in the population aligns with moderate evidence (PM2).

Other cases from Indian cohort (n = 5) (Table 1)

A review of other reported cases from India showed female predominance (80%) and predominant symptoms of cerebellar ataxia, spasticity of limbs, cognitive impairment, psychiatric symptoms and bladder incontinence. All patients had gradually progressive course of the disease. One patient had episodic worsening with febrile illness. Extrapyramidal symptoms in the form of dystonia in one patient and parkinsonism and myoclonus in one patient were seen. One female patient had infertility. All patients had bilateral T2/FLAIR hyperintensities in the cerebral white matter (leukoencephalopathy) with areas of rarefaction within hyperintensities. Genetic analysis in four patients showed homozygous missense variants in the *EIF2B3* (n = 2), *EIF2B1* (n = 1) and *EIF2B4* (n = 1).

Asian cohort (n = 24) (Table 1)

There were 24 reported cases from Asian countries (17 from China; six from Japan and one from South Korea). The median age of presentation was 42 years (range-25–65 years), median age at onset was 34 years (range-22–56 years), median duration was 12.5 years

(4–40 years) and female preponderance (79.1%). Cerebellar ataxia, cognitive impairment and spasticity were the predominant symptoms. Psychiatric disturbances were less common (17%). None of the patients had extrapyramidal symptoms. Episodic worsening of neurologic symptoms was seen in eight patients (34%). Infertility was seen in 25% of patients. Brain MRI showed leukoencephalopathy in all patients (100%) with areas of rarefaction in 20 patients (84%). Other areas of involvement were corpus callosum, brainstem, basal ganglia and cerebellum. Genetic analysis data were available in 22 patients, and *EIF2B5* (45%) was the common gene variant and compound heterozygosity occurred in 15 patients (68%).

European cohort (n = 61) (Table 1)

There were 61 reported cases from European countries. The median age at presentation was 36 years (range-24–60 years), median age at onset was 30 years (range-20–55 years), median duration was 7 years (range-4–10 years) and female preponderance (74%). Cognitive impairment, spasticity and bladder involvement were the commonest symptoms. Psychiatric symptoms were less common (28%). Seizures occurred in 10 patients (16%). Episodic worsening of neurological symptoms was seen in 13 patients (21.5%). Infertility was seen in 51% of patients. Brain MRI showed leukoencephalopathy in all patients (100%) with areas of rarefaction in 55 patients (90%). Other area of involvement was cerebellum (40%). Genetic analysis data were available in 60 patients, and *EIF2B5* (83%) was the common gene variant and compound heterozygosity occurred in 25 patients (41%).

Table 1. Comparison of clinical features and imaging findings among the cohorts

	Indian cohort (n = 7)	Asian cohort (n = 24)	European cohort (n = 61)
Age at presentation (years) (range) ^a	41.1 ± 12.5 (24–58)	42.8 ± 13.1 (25–65)	40.2 ± 13.2 (24–60)
Age at onset (years) (range) ^a	34.3 ± 12.4 (18–53)	34.9 ± 9.8 (22–56)	35.3 ± 10.4 (20–55)
Duration (years) (range) ^a	5.1 ± 5.0 (2–18)	12.1 ± 11.1 (4–40)	7.3 ± 5.4 (4–10)
Females n (%)	6/86	18/82	45/74
Clinical n (%)			
Cerebellar ataxia	6/86	12/50	35/57
Spasticity	7/100	12/50	43/70
Cognitive disturbances	7/100	14/58	44/72
Bladder involvement	6/86	10/42	35/57
Psychiatric disturbances	5/71	4/17	17/28
Movement disorder	2/28	0	2/3
Episodic worsening	1/14	8/34	15/25
Infertility	1/14	6/25	31/51
MRI n (%)			
Leukoencephalopathy	7/100	24/100	61/100
Rarefaction of white matter	7/100	20/84	55/90
Corpus callosum HI	2/29	5/21	2/3
Cerebellum HI	0	2/8	24/39
Brainstem HI	0	3/12.5	1/1.6
Basal ganglia HI	0	3/12.5	2/3
Genetics n (%)	N = 6		
EIF2B1	1/17	1/4.5	0
EIF2B2	0	2/9	1/2.0
EIF2B3	4/67	5/23	8/13
EIF2B4	1/17	4/18	1/2.0
EIF2B5	0	10/45	50/83

HI = hyperintensities.

^aMean ± standard deviation.

Discussion

The EIF2B protein regulates protein synthesis rates under basal and cellular stress conditions, facilitating translation initiation. The failure of the translation process of certain astrocytic mRNAs due to the mutation induces degeneration of white matter through loss of astrocyte function, failure of astrocyte-microglia crosstalk and secondary effect on both oligodendroglia and axons.^{11,12,13} This study aimed at the description of clinical, imaging and genetic profile of patients with adult-onset EIF2B-pathies and compare the same with Asian and European cohort of patients. Upon review of other reported cases of adult-onset EIF2B-pathies from India and cases from this study, there were seven cases reported from India and had median age at onset of 39 years, female predominance (sex patients), predominant symptoms being cerebellar ataxia, spasticity, cognitive impairment in all patients. Bladder disturbances were seen in six (85%) and psychiatric disturbances occurred in five patients (71%). Seizures (14%), extrapyramidal symptoms (14%), episodic worsening (14%) and infertility (14%) were less common. Brain MRI showed leukoencephalopathy in all patients with areas of rarefaction and corpus callosum involvement in one patient. Genetics showed homozygous variants predominantly in EIF2B3 (four patients).^{14,15,16,17}

We compared with the Asian cohort of 24 patients and found similar median age at onset (40 years), female predominance (19 patients) and common symptoms of cerebellar ataxia, spasticity and cognitive impairment. Episodic worsening of neurological symptoms and infertility were more frequent in Asian cohort. However, psychiatric disturbances (17%) were less common as compared to the Indian cohort. Imaging showed similar leukoencephalopathy in all patients but areas of rarefaction in 20 patients. Brainstem, basal ganglia and cerebellum were the additional areas of involvement which were not documented in Indian cohort. The EIF2B5 (45%) was the common gene variant in the Asian cohort, and compound heterozygosity was more common (68%) than homozygosity.^{18–27}

On comparison with the European cohort of 49 patients, there was similar median age at onset (41.5 years), female predominance (38 patients) and common symptoms of cerebellar ataxia, spasticity and cognitive impairment. Similar to the Asian cohort, episodic worsening of neurological symptoms and infertility were more frequent. Psychiatric disturbances (26.5%) were less common as compared to the Indian cohort. Brain MRI showed leukoencephalopathy in all patients with areas of rarefaction in all patients. Cerebellum was the only other area of involvement.

Table 2. Genetic profile of patients from three cohorts

Author	Genetic variant	ACMG criteria
Parihar et al (2022) ¹⁴	<i>EIF2B3</i> /c.687T>G	Pathogenic
Goyal et al (2023) ¹⁶	<i>EIF2B4</i> /exon12	Not available
Shivaram et al (2022) ¹⁷	<i>EIF2B3</i> / c.687T>G/p. Ile229Met	Likely pathogenic
	<i>EIF2B3</i> / c.824A>G/ p. Tyr275Cys	Likely pathogenic
Wei et al (2019) ¹⁸	<i>EIF2B2</i> /c.254T>A/p.V85E/c.496A>G/p.M166V	Not available
Kong et al (2022) ¹⁹	<i>EIF2B5</i> /c.1016G>A/p.R339Q//c.1157G>A/p.G386D	Pathogenic/pathogenic
Ren et al (2022) ²⁰	<i>EIF2B5</i> /c.806G > A/ p.R269Q/ c.1087G > A/ p.G363S	VUS/VUS
	<i>EIF2B5</i> /c.1025 T > C/p. I342T/c.1054C > T/ p.H352Y	VUS/VUS
	<i>EIF2B5</i> / c.1025 T > C/p. I342T/c.1054C > T/ p.H352Y	VUS/VUS
	<i>EIF2B3</i> /c.965C > G/ p.A322G/c.130G > A/p.E44K	Likely pathogenic/VUS
	<i>EIF2B3</i> /c.1261A > T/ p.I421F/c.686 T > G/p.I229S	VUS/VUS
	<i>EIF2B3</i> /c.1261A > T/ p.I421F/c.686 T > G/p.I229S	VUS/VUS
	<i>EIF2B4</i> /c.1334G > A/ p.R445H/c.882 + 2 T > G/ splice-5	Likely pathogenic/likely pathogenic
	<i>EIF2B5</i> /c.302dupA/ p.Q101fs/c.664C > T/p.R222W	Likely pathogenic/likely pathogenic
	<i>EIF2B5</i> /c.302dupA/ p.Q101fs/c.664C > T/p.R222W	Likely pathogenic/likely pathogenic
	<i>EIF2B5</i> /c.302dupA/ p.Q101fs/c.664C > T/p.R222W	Likely pathogenic/likely pathogenic
Tian et al (2022) ²¹	<i>EIF2B4</i> / c.1337G > A/p. R446H	Pathogenic
	<i>EIF2B4</i> / c.617T>C/p. Met206Thr/c.952A>G/p. Ile318Val	Not available
Kanbayashi et al (2015) ²³	<i>EIF2B4</i> / c.617T>C/p. Met206Thr/c.952A>G/p. Ile318Val	Not available
Matsukawa et al (2011) ²⁴	<i>EIF2B2</i> /c.375T>A/p. Val85Glu	Pathogenic
	<i>EIF2B5</i> /c.808 G > C/p. Asp270His	Pathogenic
	<i>EIF2B3</i> /c.80T>A/p. Leu27Gln	Pathogenic
Ohtake et al (2004) ²⁵	<i>EIF2B5</i> /c.545C>T/exon 4	Not available
Shimada et al (2015) ²⁶	<i>EIF2B1</i> /c.715T>G/p.F239V exon 8	Not available
Lee et al (2009) ²⁷	<i>EIF2B5</i> / (p. Ser447Leu)/ p. Thr182Met	Not available
Biancheri et al (2003) ²⁹	<i>EIF2B5</i> /p. R118H	Not available
Van der Knapp et al (2004) ⁵	<i>EIF2B5</i> /c.338G>A/(p. Arg113His)	Pathogenic
Ghezzi et al (2012) ³³	<i>EIF2B3</i> /c.260C>T (p. Ala87Val)	Not available
La Piana et al (2012) ³⁴	<i>EIF2B3</i> /c.260C>T/p. Ala87Val/c.272G>A/p. Arg91His	Pathogenic
Gallo et al (2004) ³⁵	<i>EIF2B5</i> /c.338G>A/(p. Arg113His)	Pathogenic
Trevisan et al (2021) ³⁸	<i>EIF2B5</i> /c.592G>A/p. Glu198Lys//c.1360 C > T (p. Pro454Ser)	Not available
Herwerth et al (2015) ³⁶	<i>EIF2B3</i> /c.260C>T/p. Ala87Val	Pathogenic
Denier et al (2007) ³⁷	<i>EIF2B5</i> /c.338G>A/(p. Arg113His)	Pathogenic
Lynch et al (2017) ³⁹	<i>EIF2B4</i> /c.495 + 3delA (;)/p.? (;)/c.623G>A/p.R208Q	} Not available
	<i>EIF2B5</i> /c.338G>A/ p.R113H/c.380T>C/L127P	
	<i>EIF2B5</i> /c.338G>A/p. R113H/c.913A>T/p.M305L	
	<i>EIF2B5</i> /c.338G>A/p. R113H/c.338G>A/p.R113H	
	<i>EIF2B5</i> /c.338G>A/p. R113H/c.338G>A/p.R113H	
Fogli et al (2003) ⁴⁰	<i>EIF2B5</i> /c.338G>A/(p. Arg113His)	Pathogenic
	<i>EIF2B5</i> /c.338G>A/(p. Arg113His)	Pathogenic
	<i>EIF2B5</i> /c.338G > A/ p. Arg113His/c.583C > T/ p. Arg195Cys	Not available
	<i>EIF2B2</i> /c.638A > G/ p. Glu213Gly/c.818A > G/ p. Lys273Arg	Not available
Tomas et al (2015) ⁴¹	5 patients had <i>EIF2B5</i> /c.338G>A/(p. Arg113His)	Pathogenic
	1 patient <i>EIF2B5</i> /c.338G>A/p. Arg113His/c.943C>T/p. Arg315Cys	Not available

(Continued)

Table 2. Genetic profile of patients from three cohorts (Continued)

Author	Genetic variant	ACMG criteria
Labuage et al (2009) ³²	12 patients had <i>EIF2B5</i> /c.338G>A/p. Arg113His /c.338G>A/p. Arg113His	Pathogenic
	<i>EIF2B5</i> /c.338G>A/ p. Arg113His/c.896G>A /p. Arg299His	} Not available
	<i>EIF2B2</i> /c.638A>G/ p. Glu213Gly/c.818A>G/ /p.K273His	
	<i>EIF2B5</i> /c.584G>A/ p. Arg195His/c.1448A>G /p. Tyr483Cys	
	<i>EIF2B5</i> /c.641A>G/ p. His214Arg/c.805C>T /p. Arg269X	
	<i>EIF2B5</i> /c.743A>T/ p. His248Leu/c.743A>T /p. His248Leu	
Benzoni et al (2023) ²⁸	6 patients – <i>EIF2B5</i> /c.338G>A/p. Arg113His	Pathogenic
	<i>EIF2B5</i> /c. 1360C > T/p. Pro454Ser	} Not available
	<i>EIF2B3</i> /c. 260C > T/p. Ala87Val	
	<i>EIF2B5</i> /c. 337C > T/p. Arg113Cys/c.664C > T/p. Arg222Trp	
	<i>EIF2B5</i> /c.1010A > G/p. His337Arg/c.1850A > G/p. Tyr617Cys	
	<i>EIF2B5</i> /c.1010A > G/p. His337Arg/c.1850A > G/p. Tyr617Cys	
	<i>EIF2B5</i> /c.512G > A/p. Arg171Lys/c.1165G > A/p. Val389Met	
	<i>EIF2B5</i> /c. 337C > T/p. Arg113Cys	
	<i>EIF2B5</i> /c.338G > A/p. Arg113His/c.896G > A/p. Arg299His	
	<i>EIF2B3</i> /c.43C > T/p. Arg15Trp/c.260C > A/p. Ala87Glu	
	<i>EIF2B3</i> /c.43C > T/p. Arg15Trp/c.260C > A/p. Ala87Glu	

Similar to the Asian cohort, *EIF2B5* (83%) was the common gene variant, and compound heterozygosity and homozygosity frequency were equal.^{28–41}

There was female preponderance in all the three cohorts. The possible explanations would be firstly males being less susceptible than females for the disease expression or males might remain asymptomatic or develop disease early in life as compared to the females. Secondly, differences in the myelin breakdown, oligodendrocyte turnover and myelin density between males and females and thirdly, ovarian hormone deprivation on glial cell functions causing higher female susceptibility.^{28,32} There is a variability in the type of onset in the adult-onset EIF2B-pathies wherein the patient can present as gradual onset, progressive course of cerebellar ataxia, cognitive decline and spasticity or acute onset of seizures followed by rapid motor/cognitive decline.²⁸ Acute onset presentation was not seen in the Indian cohort but was reported to be 33% in a study of 18 patients from the European cohort. Cerebellar ataxia, spasticity and cognitive decline were the most common reported presenting symptoms in all three cohorts. Psychiatric disturbances were less frequent in Asian and European cohorts (17%–26%). The episodic neurologic worsening triggered by fever, stress, minor head injury and vaccination is a characteristic feature of EIF2B-pathies, and it ranged from 14%–34% in Indian, Asian and the European cohort. Primary/secondary amenorrhea leading to infertility are known to be associated with the adult-onset EIF2B-pathies and may precede neurological symptoms. It was more common in European cohort than in Asian/Indian cohorts.

Brain MRI in adult-onset EIF2B-pathies shows characteristic diffusely abnormal cerebral white matter (T1-weighted hypointensity, T2-weighted hyperintensity) with rarefaction including corpus callosum, cerebellar white matter and brainstem with associated atrophy. The patients in all three cohorts had the characteristic leukoencephalopathy with areas of rarefaction, whereas in the Asian cohort, there were additional areas of

involvement which included brainstem, basal ganglia and cerebellum, but in the European cohort, only additional cerebellar involvement was reported.

Variants in the *EIF2B5* gene were the commonest in the Asian and European cohorts (45%–83%), whereas *EIF2B5* was not reported from the Indian cohort. The c.338G > A (Arg113His) is the most common variant in the *EIF2B5*, and this variant in homozygosity has been reported to be associated with milder phenotype.³¹ In the European cohort, 50 patients had variants in the *EIF2B5*, and 38 patients (76%) had c.338G > A (Arg113His) variant with homozygosity in 76% patients.^{28–41} In the Asian cohort, 10 patients had variants in the *EIF2B5*, and none of them had c.338G > A (Arg113His) variant.^{18–27} The second commonest variant was seen in *EIF2B3* (total 17 cases from three cohorts). Variants in the *EIF2B1* were least among all five subunits as only two cases, one in the Indian cohort and one in the Asian cohorts, were reported. The genetic profile of patients from all cohorts is summarized in Table 2.

The strength of the study was the detailed clinical, radiological and genetic description of cases from Indian, Asian and European cohorts. The limitations of the study are the small sample size of the Indian cohort, variability in the number of reported cases among the groups and lack of long-term follow-up and prognosis of the Indian cohort.

Conclusion

Adult-onset EIF2B-pathies have a clinical profile of female predominance with cerebellar ataxia, spasticity and cognitive decline as the commonest triad of clinical manifestations followed by psychiatric symptoms, seizures and episodic worsening of neurological symptoms. Patients of all three cohorts showed similar imaging abnormalities of leukoencephalopathy with areas of rarefaction followed by corpus callosum, cerebellum and brainstem involvement. Variants in *EIF2B5* were common in the

European and Asian cohorts, but variants in *EIF2B3* were common in the Indian cohort.

Author contributions. 1. Research project: A. Conception, B. Organization, C. Execution;

2. Statistical Analysis: A. Design, B. Execution, C. Review and Critique;

3. Manuscript Preparation: A. Writing of the first draft, B. Review and Critique;

STA: 1B, 1C, 2A, 2B, 3A.

GA: 1B, 1C, 2B, 2C, 3B.

HP: 1A, 2C, 3B.

RRM: 1A, 1B, 1C, 2A, 2B, 3B.

Funding statement. None.

Competing interests. None.

References

- Schiffmann R, Moller JR, Trapp BD, et al. Childhood ataxia with diffuse central nervous system hypomyelination. *Ann Neurol.* 1994;35:331–40.
- Van der Knaap MS, Barth PG, Gabreëls FJM, et al. A new leukoencephalopathy with vanishing white matter. *Neurology.* 1997;48:845–55.
- Leegwater PA, Vermeulen G, Könst AA, et al. Subunits of the translation initiation factor eIF2B are mutant in leukoencephalopathy with vanishing white matter. *Nat Genet.* 2001;29:383–8.
- van der Knaap MS, Leegwater PA, Könst AA, et al. Mutations in each of the five subunits of translation initiation factor eIF2B can cause leukoencephalopathy with vanishing white matter. *Ann Neurol.* 2002;51:264–70.
- van der Knaap MS, Kamphorst W, Barth PG, Kraaijeveld CL, Gut E, Valk J. Phenotypic variation in leukoencephalopathy with vanishing white matter. *Neurology.* 1998;51:540–7.
- Damon-Perriere N, Menegon P, Olivier A, et al. Intra-familial phenotypic heterogeneity in adult onset vanishing white matter disease. *Clin Neurol Neurosurg.* 2008;110:1068–71.
- Fogli A, Schiffmann R, Bertini E, et al. The effect of genotype on the natural history of eIF2B-related leukodystrophies. *Neurology.* 2004;62:1509–17.
- Fogli A, Boespflug-Tanguy O. The large spectrum of eIF2B-related diseases. *Biochem Soc Trans.* 2006;34:22–9.
- Boespflug-Tanguy O, Labauge P, Fogli A, Vaur-Barriere C. Genes involved in leukodystrophies: a glance at glial functions. *Curr Neurol Neurosci Rep.* 2008;8:217–29.
- Gandevia B, Tovell A. Declaration of Helsinki. *Med J Aust.* 1964;2:320-1.
- Hanson FM, Hodgson RE, de Oliveira MIR, Allen KE, Campbell SG. Regulation and function of eIF2B in neurological and metabolic disorders. *Biosci Rep.* 2022;42:BSR20211699.
- Pavitt GD. Regulation of translation initiation factor eIF2B at the hub of the integrated stress response. *Wiley Interdiscip Rev RNA.* 2018;9:e1491.
- Bugiani M, Vuong C, Breur M, et al. Vanishing white matter: a leukodystrophy due to astrocytic dysfunction. *Brain Pathol.* 2018;28:408–21.
- Parihar J, Vibha D, Rajan R, Pandit AK, Srivastava AK, Prasad K. Vanishing white matter disease presenting as dementia and infertility: a case report. *Neurol Genet.* 2022;8:e643.
- Nagdev G, Vhora RS, Chavan G, Sahu G. Adult onset vanishing white matter disease: a rare case report. *Cureus.* 2022;14:e30177.
- Goyal S, Mudabbir M, Taallapalli AVR, Nashi S, Kulkarni GB. Vanishing white matter leukodystrophy due to novel EIF2B4 mutation in an adult female. *J Neurosci Rural Pract.* 2023;14:191–3.
- Shivaram S, Nagappa M, Seshagiri DV, et al. Mutations in adults. *Can J Neurol Sci.* 2022;49:708–12.
- Wei C, Qin Q, Chen F, et al. Adult-onset vanishing white matter disease with the EIF2B2 gene mutation presenting as menometrorrhagia. *BMC Neurol.* 2019;19:203.
- Kong F, Zheng H, Liu X, Lin S, Wang J, Guo Z. Association between late-onset Leukoencephalopathy with vanishing white matter and compound heterozygous EIF2B5 gene mutations: a case report and review of the literature. *Front Neurol.* 2022;13:8–13032.
- Ren Y, Yu X, Chen B, et al. Genotypic and phenotypic characteristics of juvenile/adult onset vanishing white matter: a series of 14 Chinese patients. *Neurol Sci.* 2022;43:4961–77.
- Tian Y, Liu Q, Zhou Y, et al. Identification of a novel heterozygous mutation in the *EIF2B4*. Gene associated with vanishing white matter disease. *Front Bioeng Biotechnol.* 2022;10:901452.
- Su T, Yuan H, Gao W, Li H, Yuan M. Adult vanishing white matter disease with a novel EIF2B4 mutation. *J Coll Physicians Surg Pak.* 2022;32:SS181–SS183.
- Kanbayashi T, Saito F, Matsukawa T, et al. Adult-onset vanishing white matter disease with novel missense mutations in a subunit of translational regulator, EIF2B4. *Clin Genet.* 2015;88:401–3.
- Matsukawa T, Wang X, Liu R, et al. Adult-onset leukoencephalopathies with vanishing white matter with novel missense mutations in EIF2B2, EIF2B3, and EIF2B5. *Neurogenetics.* 2011;12:259–61.
- Ohtake H, Shimohata T, Terajima K, et al. Adult-onset leukoencephalopathy with vanishing white matter with a missense mutation in EIF2B5. *Neurology.* 2004;62:1601–3.
- Shimada S, Shimojima K, Sangu N, et al. Mutations in the genes encoding eukaryotic translation initiation factor 2B in Japanese patients with vanishing white matter disease. *Brain Dev.* 2015;37:960–6.
- Lee HN, Koh SH, Lee KY, Ki CS, Lee YJ. Late-onset vanishing white matter disease with compound heterozygous EIF2B5 gene mutations. *Eur J Neurol.* 2009;16:e42–3.
- Benzoni C, Moscatelli M, Farina L, et al. Adult-onset leukodystrophy with vanishing white matter: a case series of 19 patients. *J Neurol.* 2023;270:4219–34.
- Biancheri R, Rossi A, Di Rocco M, et al. Leukoencephalopathy with vanishing white matter: an adult-onset case. *Neurology.* 2003;61:1818–9.
- Prass K, Brück W, Schröder NW, et al. Adult-onset Leukoencephalopathy with vanishing white matter presenting with dementia. *Ann Neurol.* 2001;50:665–8.
- van der Knaap MS, Leegwater PA, van Berkel CG, et al. Arg113His mutation in eIF2Bepsilon as cause of leukoencephalopathy in adults. *Neurology.* 2004;62:1598–600.
- Labauge P, Horzinski L, Aygnac X, et al. Natural history of adult-onset eIF2B-related disorders: a multi-centric survey of 16 cases. *Brain.* 2009;132:2161–9.
- Ghezzi L, Scarpini E, Rango M, et al. A 66-year-old patient with vanishing white matter disease due to the p. Ala87Val EIF2B3 mutation. *Neurology.* 2012;79:2077–8.
- La Piana R, Vanderver A, van der Knaap M, et al. Adult-onset vanishing white matter disease due to a novel EIF2B3 mutation. *Arch Neurol.* 2012;69:765–68.
- Gallo A, Rocca MA, Falini A, et al. Multiparametric MRI in a patient with adult-onset leukoencephalopathy with vanishing white matter. *Neurology.* 2004;62:323–6.
- Herwerth M, Schwaiger BJ, Kreiser K, Hemmer B, Ilg R. Adult-onset vanishing white matter disease as differential diagnosis of primary progressive multiple sclerosis: a case report. *Mult Scler.* 2015;21:666–8.
- Denier C, Orgibet A, Roffi F, et al. Adult-onset vanishing white matter leukoencephalopathy presenting as psychosis. *Neurology.* 2007;68:1538–9.
- Trevisan L, Grazzini M, Cianflone A, et al. An eleven-year history of vanishing white matter disease in an adult patient with no cognitive decline and EIF2B5 mutations. A case report. *Neurocase.* 2021; 27:452–6.
- Lynch DS, Rodrigues Brandão de Paiva A, Zhang WJ, et al. Clinical and genetic characterization of leukoencephalopathies in adults. *Brain.* 2017;140:1204–11.
- Fogli A, Rodriguez D, Eymard-Pierre E, et al. Ovarian failure related to eukaryotic initiation factor 2B mutations. *Am J Hum Genet.* 2003;72:1544–50.
- Tomás J, Gouveia A, Galego O, Alonso I, do carmo Macario M. Vanishing white matter disease: clinical and imaging description of seven adult patients. *Sinapse.* 2015;15:13.