

## Original Article

\*Designates equal contribution as first author.

**Cite this article:** Selvaggi P *et al* (2023). Reduced cortical cerebral blood flow in antipsychotic-free first-episode psychosis and relationship to treatment response. *Psychological Medicine* **53**, 5235–5245. <https://doi.org/10.1017/S0033291722002288>

Received: 24 November 2021

Revised: 27 June 2022

Accepted: 4 July 2022

First published online: 25 August 2022

**Key words:**


Arterial spin labelling; cerebral blood flow; first-episode psychosis; schizophrenia

**Author for correspondence:**

Oliver D. Howes,

E-mail: [oliver.howes@kcl.ac.uk](mailto:oliver.howes@kcl.ac.uk)

# Reduced cortical cerebral blood flow in antipsychotic-free first-episode psychosis and relationship to treatment response

Pierluigi Selvaggi<sup>1,2,\*</sup> , Sameer Jauhar<sup>3,4,\*</sup>, Vasileia Kotoula<sup>1</sup>, Fiona Pepper<sup>3</sup>, Mattia Veronese<sup>1</sup>, Barbara Santangelo<sup>1</sup>, Fernando Zelaya<sup>1</sup>, Federico E. Turkheimer<sup>1</sup>, Mitul A. Mehta<sup>1</sup> and Oliver D. Howes<sup>3,5,6</sup>

<sup>1</sup>Department of Neuroimaging, Institute of Psychiatry, Psychology and Neuroscience, King's College London, London, UK; <sup>2</sup>Azienda Ospedaliero-Universitaria Consorziale Policlinico di Bari, Bari, Italy; <sup>3</sup>Department of Psychosis Studies, Institute of Psychiatry, Psychology and Neuroscience, King's College London, London, UK; <sup>4</sup>Early Intervention Psychosis Clinical Academic Group, South London & Maudsley NHS Foundation Trust, London, UK; <sup>5</sup>MRC London Institute of Medical Sciences, Hammersmith Hospital, London W12 0NN, UK and <sup>6</sup>Faculty of Medicine, Institute of Clinical Sciences (ICS), Imperial College London, Du Cane Road, London W12 0NN, UK

**Abstract**

**Background.** Altered cerebral blood flow (CBF) has been found in people at risk for psychosis, with first-episode psychosis (FEP) and with chronic schizophrenia (SCZ). Studies using arterial spin labelling (ASL) have shown reduction of cortical CBF and increased subcortical CBF in SCZ. Previous studies have investigated CBF using ASL in FEP, reporting increased CBF in striatum and reduced CBF in frontal cortex. However, as these people were taking antipsychotics, it is unclear whether these changes are related to the disorder or antipsychotic treatment and how they relate to treatment response.

**Methods.** We examined CBF in FEP free from antipsychotic medication ( $N = 21$ ), compared to healthy controls ( $N = 22$ ). Both absolute and relative-to-global CBF were assessed. We also investigated the association between baseline CBF and treatment response in a partially nested follow-up study ( $N = 14$ ).

**Results.** There was significantly lower absolute CBF in frontal cortex (Cohen's  $d = 0.84$ ,  $p = 0.009$ ) and no differences in striatum or hippocampus. Whole brain voxel-wise analysis revealed widespread cortical reductions in absolute CBF in large cortical clusters that encompassed occipital, parietal and frontal cortices (Threshold-Free Cluster Enhancement (TFCE)-corrected  $<0.05$ ). No differences were found in relative-to-global CBF in the selected region of interests and in voxel-wise analysis. Relative-to-global frontal CBF was correlated with percentage change in total Positive and Negative Syndrome Scale after antipsychotic treatment ( $r = 0.67$ ,  $p = 0.008$ ).

**Conclusions.** These results show lower cortical absolute perfusion in FEP prior to starting antipsychotic treatment and suggest relative-to-global frontal CBF as assessed with magnetic resonance imaging could potentially serve as a biomarker for antipsychotic response.

**Introduction**

Schizophrenia (SCZ) and related psychotic disorders are amongst the leading causes of global disease burden (McCutcheon, Reis Marques, & Howes, 2020b). Current treatments are ineffective for many patients (Kaar, Natesan, McCutcheon, & Howes, 2020), highlighting the need to understand the neurobiology underlying psychosis to inform development of new drug treatments (Jauhar & Howes, 2019; McCutcheon, Krystal, & Howes, 2020a). Altered brain perfusion and metabolism have been implicated in the neurobiology of SCZ (Goozée, Handley, Kempton, & Dazzan, 2014; Hill *et al.*, 2004; Townsend *et al.*, 2022), initially with positron emission tomography (PET). PET studies with [<sup>18</sup>F]-fluorodeoxyglucose (FDG) and [<sup>15</sup>O]H<sub>2</sub>O reported hypometabolism and hypoperfusion in frontal, anterior cingulate, temporal and parietal cortices (Andreasen *et al.*, 1997; Buchsbaum *et al.*, 1982; Gur *et al.*, 1995). More recently, arterial spin labelling (ASL), utilizing magnetic resonance imaging (MRI), has been used to measure cerebral blood flow (CBF). Because of the well-established phenomenon of neuro-vascular coupling, measures of regional CBF are an indirect but highly sensitive signature of regional cellular activity. ASL studies in people with chronic SCZ, treated with antipsychotics, show reduced CBF in frontal, parietal and occipital regions and increased CBF in basal ganglia (Legind *et al.*, 2019; Liu, Qiu, Constable, & Wexler, 2012a; Oliveira *et al.*, 2018; Pinkham *et al.*, 2011, 2015), though the basal ganglia findings have not been consistently replicated (Ota *et al.*, 2014; Zhu *et al.*, 2017). Thus, there is evidence for cortical hypoperfusion in chronic SCZ, but it is unclear from these studies when this occurs in development of the

© The Author(s), 2022. Published by Cambridge University Press. This is an Open Access article, distributed under the terms of the Creative Commons Attribution-NonCommercial-NoDerivatives licence (<http://creativecommons.org/licenses/by-nc-nd/4.0/>), which permits non-commercial re-use, distribution, and reproduction in any medium, provided that no alterations are made and the original article is properly cited. The written permission of Cambridge University Press must be obtained prior to any commercial use and/or adaptation of the article.

disorder. Studies in clinical high risk for psychosis (CHR-P) individuals have reported increased CBF in basal ganglia and hippocampus (Allen et al., 2016, 2018; Modinos et al., 2018b). Increased hippocampal perfusion in CHR-P individuals has also been found with gadolinium-enhanced MRI (Schobel et al., 2013). These findings indicate that CBF alterations may occur early in development of psychosis, though, because the majority of CHR-P subjects do not go on to develop psychosis, it is unclear how specific they are to psychosis. To date, only one study has investigated cerebral perfusion using ASL in people with first-episode psychosis (FEP) (Kindler et al., 2018). This study found increased perfusion in basal ganglia and reduced CBF in frontal cortex in people with FEP, all of whom were taking antipsychotic medication.

However, antipsychotics have effects on brain metabolism and CBF (Goozée et al., 2014; Hawkins et al., 2018; Mehta et al., 2003; Miller et al., 1997; Turkheimer et al., 2020), with evidence from preclinical models (Sander et al., 2013, 2019; Sander, Hooker, Catana, Rosen, & Mandeville, 2016; Viviani, Graf, Wieggers, & Abler, 2013) and experimental medicine studies in healthy individuals (Hawkins et al., 2018; Selvaggi et al., 2019; Viviani et al., 2013) suggesting that antipsychotics increase CBF in the basal ganglia with a mechanism possibly mediated by D<sub>2</sub> receptors (Sander et al., 2013; Selvaggi et al., 2019). The effect of antipsychotics on cortical perfusion is even less understood. Studies using PET and single photon emission computed tomography (SPECT) found consistently reduced perfusion and metabolism in the frontal cortex in both medicated and unmedicated patients with SCZ (Makarić et al., 2017; Molina et al., 2005). Viviani et al. (2013) found decreased cortical perfusion after amisulpride administration in healthy volunteers. It is therefore unclear if previous findings in FEP were confounded by antipsychotic treatment and what is the extent of the interaction between antipsychotic effects and pathophysiology. Thus, we aimed to determine if CBF is altered in people in their first episode of psychosis who are free from antipsychotic medication (baseline study). Based on prior studies in FEP and subjects at CHR-P, we hypothesized that antipsychotic-free people with FEP would show lower absolute CBF in the frontal cortex while keeping CBF in the striatum within physiological ranges.

Moreover, while previous cross-sectional investigations have shown associations between altered CBF and severity of psychotic symptoms in SCZ (Kindler et al., 2018; Pinkham et al., 2011), it is unknown if brain perfusion before treatment is associated with subsequent symptomatic improvement with antipsychotic treatment. Thus, we aimed to explore this association in a prospective study of patients who went on to receive antipsychotic treatment (follow-up study). To summarize, we adopted a partially nested two-study design to (i) investigate differences in brain perfusion in FEP prior to start antipsychotic treatment (baseline study) and (ii) identify brain perfusion markers of treatment response possibly unbiased by antipsychotic effects on CBF.

## Materials and methods

### Study participants

Study participants were recruited from FEP teams within South London and Maudsley NHS Foundation Trust (Fusar-Poli et al., 2020) and Central and West London NHS Trust. All participants provided informed written consent. For both groups' exclusion criteria were history of head trauma, dependence on illicit

drugs, any significant medical co-morbidity (minor illnesses such as seasonal allergies were permitted) and contra-indication to MRI scanning.

### Baseline study

Inclusion criteria for the patient group were: psychotic disorder according to ICD-10 criteria (World Health Organization, 2004) in first episode of illness. Age and gender-matched healthy volunteers were recruited through local advertisement from the same geographical areas. Inclusion criteria for healthy controls (HCs) were: no personal history of psychiatric illness [assessed using the Structured Clinical Interview for the DSM (First, 2014)] and no history of psychotropic medication use. All patients were antipsychotic-naïve or antipsychotic-free for at least 6 weeks for oral antipsychotics or 6 months for depot antipsychotics (Jauhar et al., 2019; Leucht et al., 2015). The sample included nine antipsychotic-naïve and 12 antipsychotic-free patients. All but one patient included in the baseline study was not taking other psychotropic medication (i.e. antidepressants, mood stabilizers, benzodiazepines) at the time of MRI scan. Only one patient was taking antidepressant medication (sertraline) at the time of MRI scan (Viviani, Abler, Seeringer, & Stingl, 2012).

### Follow-up study

Inclusion criteria for the patient group were: psychotic disorder according to ICD-10 criteria (World Health Organization, 2004); in first episode of illness; and antipsychotic-free or -naïve or minimally treated [taking antipsychotics at minimal effective dose for less than 2 weeks (Agid, Kapur, Arenovich, & Zipursky, 2003; Levine & Leucht, 2012)]. All patients were clinically assessed at baseline and reassessed after taking antipsychotic treatment, at a therapeutic dose as specified in the Maudsley Prescribing Guidelines (Taylor, Barnes, & Young, 2018), for a minimum of 4 weeks. All patients were in stable treatment at follow-up after titration. Clinical measures were rated at baseline and follow-up using the Positive and Negative Syndrome Scale (PANSS) (Kay, Fiszbein, & Opler, 1987). Patients received follow-up for at least 6 months to determine if there had been a subsequent response in patients who showed non-response at 4 weeks (duration to follow-up in months  $24.73 \pm 16.89$ ). Subjects with psychosis were classified by antipsychotic exposure as antipsychotic-naïve, antipsychotic-free [prior oral antipsychotic medication but free of treatment for at least 6 week (oral) or 6 months (depot, if relevant)] or minimally treated (taking antipsychotic medication for 2 weeks or less) (Jauhar et al., 2019; Leucht et al., 2015). The sample included seven antipsychotic-naïve, four antipsychotic-free and three people minimally treated with antipsychotics.

### MRI acquisition and pre-processing

#### MRI acquisition

Scans were acquired using a GE MR750 3-T scanner and a 12-channel head coil. A T1-weighted MPRAGE scan was also acquired (FOV = 260 mm; echo time = 2.8 ms; repetition time = 6.98 ms; 256 × 256 matrix; slice thickness = 1.2 mm, flip angle = 11) for normalization purposes. A T2-weighted image (FOV = 240 mm; echo time = 54.68 ms; repetition time = 4380 ms; 320 × 320 matrix; slice thickness = 4 mm) was also acquired and used for the pre-processing of ASL images (see below). ASL data were acquired using a pseudo-continuous arterial spin labelling sequence (PCASL). Four control-label pairs were

used (labelling time = 1525 ms; post labelling delay = 1500 ms). Images were read with a 3D Fast-Spin echo stack of spirals scheme, consisting of eight inter-leaved spiral arms, 512 points per arm and 60 slice-locations of 3 mm thickness. The raw spatial resolution of the perfusion sensitive images was approximately 3.6 mm in plane and 3 mm through plane; and the data points were re-gridded to a rectangular matrix prior to Fourier transformation and written with a voxel size of  $1 \times 1 \times 3$  mm (no gap). The sequence had background suppression for optimum reduction of the static tissue signal (for further details, see online Supplementary materials). A proton density (PD) image was also acquired over 48 s using the same acquisition parameters.

### Pre-processing

PD images were used to obtain quantification of absolute CBF in standard physiological units (ml blood/100 g tissue/min) using the formula suggested in the recent ASL consensus paper (Alsop et al., 2015). The unified segmentation algorithm in SPM12 (Ashburner & Friston, 2005) was used to create grey matter, white matter and cerebrospinal fluid (CSF) images from each T1-weighted image and to create a set of flow fields to later transform each subject's T1-weighted and ASL data into standard space. The T2-weighted images were co-registered to the T1-weighted images. Each raw PD image was then co-registered to the T2 image. The parameters for this transformation were then applied to the CBF maps (as they were already in alignment with the PD image) prior to their normalization. The addition of these two co-registration steps helped us to achieve a better alignment between CBF and T1-weighted images which prevented from distortions during normalization. Images were resampled to 2 mm isotropic voxels and normalized into a standard space (Montreal Neurological Institute, MNI). Finally, the normalized CBF maps were smoothed using a 6 mm full width at half maximum (FWHM) kernel. Normalized T1-weighted images were also smoothed using a 6 mm FWHM kernel.

### Statistical analysis

#### Demographics

Demographic characteristics (i.e. age, gender) were compared between FEP and HC using  $\chi^2$  or independent sample *t* tests for categorical and continuous data respectively.

#### Region of interest (ROI) analysis

Absolute CBF values in the whole grey matter and in each ROI were extracted using spatially normalized to individual grey matter images and the WFU-Pickatlas ROIs with the MarsBar toolbox (<http://marsbar.sourceforge.net>). Based on previous findings (Allen et al., 2016; Kindler et al., 2018), the following bilateral ROIs were selected as our primary ROIs: the frontal cortex (size = 61 104 mm), the hippocampus (size = 15 024 mm) and the striatum (size = 36 816 mm). For comparisons with previous investigations (Allen et al., 2016; Kindler et al., 2018), we also explored differences between FEP and HC in relative-to-global-perfusion CBF (relative CBF). For each ROI a linear regression model was performed with absolute CBF in the ROI as the dependent variable and global grey matter CBF as the independent variable. For each linear regression in each ROI unstandardized residuals were computed.

To test our primary hypothesis that FEP would show reduced absolute CBF in frontal cortex and increased CBF in striatum and hippocampus, a repeated measure analysis of variance (ANOVA)

was used with 'ROI' as the within-subject factor and 'GROUP' as the between-subject factor. Tukey HSD test has been used for post-hoc pairwise comparison. An independent sample *t* test was used to test absolute CBF in the whole grey matter to determine if there was a global group difference in CBF. Cohen's *d* has been computed to obtain estimates of effect size. To test differences in relative-to-global CBF, absolute CBF unstandardized residual against global grey matter CBF were entered as dependent variables in a repeated measure ANOVA with 'ROI' as within-subject variable and 'GROUP' as between-subjects variable. Tukey HSD has been used for post-hoc pairwise comparison.

#### Voxel-wise analysis

Differences in absolute CBF were also tested in whole-brain voxel-wise analyses. Based on recent recommendations (Eklund, Nichols, & Knutsson, 2016), we performed non-parametric analysis as implemented in FSL *randomise* (Winkler, Ridgway, Webster, Smith, & Nichols, 2014) and threshold-free cluster enhancement (TFCE) (Smith & Nichols, 2009) with 5000 permutations to create a non-parametric null distribution and calculate a 5% significant threshold. We also tested relative-to-global-perfusion CBF differences between FEP and HC in voxel-wise analysis using FSL *randomise* by including global grey matter CBF as a nuisance covariate in the model. An independent sample *t* test was used to test differences in intracranial volume (ICV) between FEP and HC.

#### Structural analysis

In order to check whether results could be influenced by differences in grey matter volume differences between FEP and HC, standard voxel-based morphometry (VBM) analysis as implemented in SPM was performed on pre-processed T1-weighted images to determine if there were volumetric differences between groups. Voxel-wise independent sample *t* test as implemented in SPM were performed to assess differences in grey matter volume between FEP and controls. Grey matter, white matter and CSF images of each subject were combined to obtain estimates of total ICV. In addition, T1-weighted images were processed using FreeSurfer (version 7.1.1, <http://surfer.nmr.harvard.edu>) image analysis suite to produce measures of cortical thickness estimates using the FreeSurfer automated brain segmentation process (*recon-all*) (Fischl & Dale, 2000; Salat et al., 2004). An FWHM Gaussian kernel of 10 mm was applied. Vertex-wide independent sample *t* test was performed for both left and right hemisphere to assess differences in cortical thickness between FEP and controls. Both FEP > HC and FEP < HC contrast were analysed. Cluster-level correction for multiple comparison was implemented with  $-\log_{10}(p)$  value = 3 as cluster-defining threshold and alpha = 0.05 (Greve & Fischl, 2018).

#### Correlation with PANSS change

Percentage changes in PANSS was calculated, adjusting for minimum scores (% change in total PANSS =  $[(\text{baseline score} - 30) - (\text{follow-up score} - 30)] / (\text{baseline score} - 30) \times 100$ ) (Leucht et al., 2005).

To explore the association between baseline CBF and improvement in symptoms, linear regression analysis was performed between both baseline absolute and relative-to-global-CBF values from our primary ROIs and percentage change in total PANSS. For each linear regression model Bonferroni correction was applied for the number of ROI tested (alpha = 0.05/3 = 0.016). For all linear regression models Mahalanobis distance and

Cook's distance were computed to examine the presence of multivariate outliers and to estimate the presence of highly influential data points. To identify multivariate outliers, Mahalanobis distance values were compared to a  $\chi^2$  distribution with degrees of freedom equal to the number of variables (two in this case) with  $p = 0.001$  (Finch, 2012). Any data point with Cook's distance higher than 1 was considered a highly influential outlier and excluded from the analysis as recommended [see Cook & Weisberg, 1982]. To further test the robustness of our analysis reducing the effect of extreme observations, we used the bias-corrected accelerated bootstrap technique with 10 000 resamples (Efron & Tibshirani, 1986).

## Results

### Baseline study

#### Demographics

Twenty-one people with FEP [mean age  $\pm$  standard deviation (s.d.), 24.85  $\pm$  3.85, three female] and 22 HC (23.45  $\pm$  3.21, eight female) were included in the baseline study. HC and FEP groups did not significantly differ in age ( $t = 1.29$ ,  $p = 0.3$ ) or gender ( $\chi^2 = 2.8$ ,  $p = 0.1$ ) (Table 1).

#### Absolute CBF

Absolute whole brain CBF was significantly lower in FEP (mean  $\pm$  s.d., 27.642  $\pm$  59.52) as compared to controls (mean  $\pm$  s.d., 32.334  $\pm$  43.75) ( $t = -2.94$ ,  $df = 41$ ,  $p = 0.005$ , Cohen's  $d = 0.89$ ). Results did not change after removal of the subject receiving antidepressant at the time of the scan ( $p < 0.001$ ).

**Table 1.** Summary of demographic and clinical characteristics of the baseline study sample

	FEP, <i>n</i> = 21	HC, <i>n</i> = 22	<i>p</i> value
Age (mean $\pm$ s.d.)	24.85 $\pm$ 3.85	23.45 $\pm$ 3.21	0.3
Gender (M/F)	18/3	14/8	0.1
Education (years, mean $\pm$ s.d.)	14.4 $\pm$ 2.1	15.68 $\pm$ 2.6	0.1
PANSS total baseline (mean $\pm$ s.d.)	70.7 $\pm$ 18.6	–	–
PANSS positive baseline (mean $\pm$ s.d.)	13.7 $\pm$ 4.4	–	–
PANSS negative baseline (mean $\pm$ s.d.)	13.4 $\pm$ 6.3	–	–
Antipsychotic-naïve (%)	43	–	–
Antipsychotic-free (%)	57	–	–
Minimal antipsychotic treatment (%)	0	–	–
Smoking status (never/past/current)	13/2/6	12/6/4	0.3
Substance use (never/past/current)	17/3/1	15/3/4	0.4
Alcohol (never/past/current)	11/2/8	9/1/12	0.5
Ethnicity (white/black/Asian/others)	4/6/5/6	4/13/3/2	–

There was a significant main effect of 'GROUP' ( $F = 4.74$ ,  $p = 0.035$ ) and a significant 'ROI'  $\times$  'GROUP' interaction ( $F = 3.89$ ,  $p = 0.032$  after Greenhouse–Geisser correction) on absolute CBF. Tukey HSD *post hoc* test revealed significantly lower absolute CBF in the frontal cortex in FEP as compared to HC ( $t = -2.75$ ,  $df = 41$ ,  $p = 0.009$ , Cohen's  $d = 0.84$ ) with no statistically significant differences between FEP and HC in the hippocampus ( $t = -1.5$ ,  $df = 41$ ,  $p = 0.13$ ) or striatum ( $t = -1.4$ ,  $df = 41$ ,  $p = 0.1$ ). Results did not change after removal of the subject receiving antidepressant at the time of the scan ( $p < 0.001$ ). Figure 1 shows absolute CBF values in the three ROIs (i.e. frontal cortex, hippocampus and striatum).

We conducted an exploratory analysis separating the patients into antipsychotic-naïve and antipsychotic-free sub-groups. This shows that CBF levels are similar in antipsychotic-naïve and antipsychotic-free sub-groups (see online Supplementary materials).

#### Relative-to-global CBF

There was a trend towards a significant main effect of 'GROUP' ( $F = 3.9$ ,  $p = 0.054$ ), but no significant main effect of 'ROI' ( $p = 0.85$ ) or significant 'ROI  $\times$  GROUP' interaction ( $p = 0.23$ ) on relative CBF.

#### CBF whole-brain voxel-wise analysis

Figure 2 shows whole-brain voxel-wise differences ( $p < 0.05$ , TFCE-corrected) between FEP and HC. The direct voxel-wise comparison revealed significantly lower CBF in FEP compared to HC in widespread cortical areas including frontal, parietal and occipital areas. The opposite contrast (i.e. HC  $<$  FEP) did not reveal any significant clusters.

Whole brain voxel-wise analysis of relative-to-global CBF did not reveal any TFCE-corrected cluster in either FEP  $>$  HC or FEP  $<$  HC contrasts.

#### Structural analysis

FEP and HC did not differ in total grey matter volume ( $t = -1.8$ ,  $df = 41$ ,  $p = 0.08$ ) or total ICV ( $t = 0.95$ ,  $df = 41$ ,  $p = 0.96$ ). Voxel-wise VBM analysis did not reveal any significant differences in grey matter volume between FEP and HC. FreeSurfer analysis did not reveal any significant cluster of cortical thickness differences between FEP and HC.

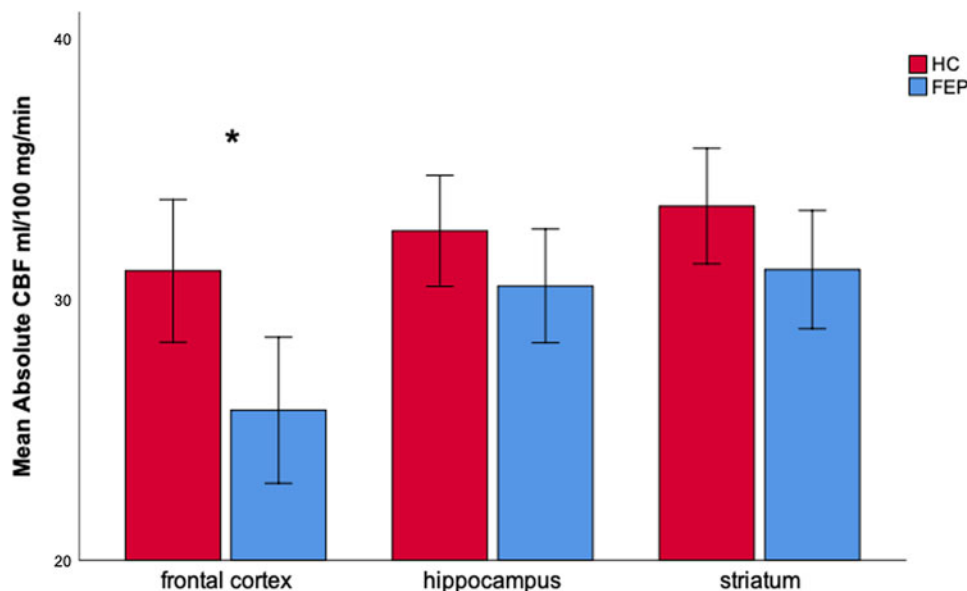
#### Follow-up study

##### Demographics

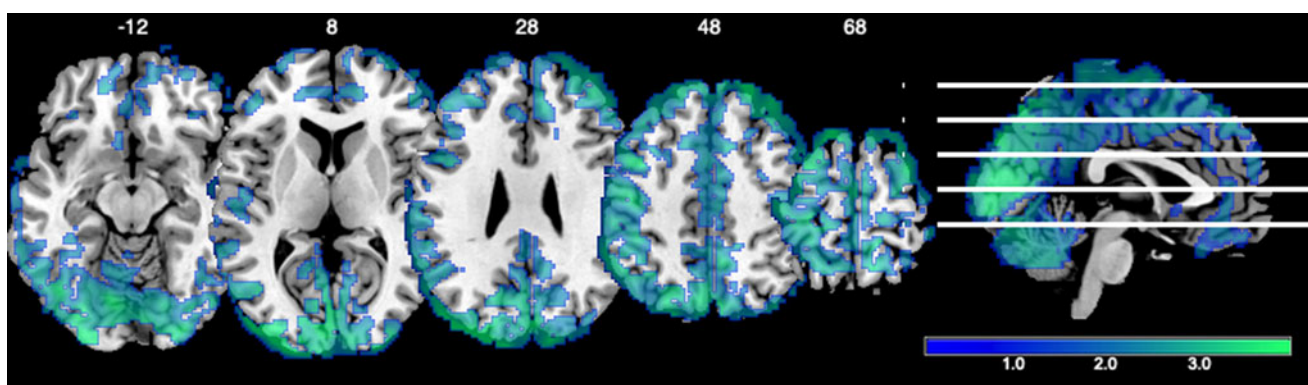
Fourteen FEP (23.85  $\pm$  3.77, four female) were included in the follow-up study. Eleven patients also took part in the baseline study (Table 2).

##### Correlations between baseline CBF and PANSS change

There were no significant associations between absolute CBF extracted from the ROIs and percentage change in total PANSS score ( $p > 0.32$ ). However, relative-to-global CBF in the frontal cortex correlated positively with percentage change in total PANSS (Fig. 3;  $r = 0.67$ ,  $p = 0.008$ ). In all linear regression models, none of the data points were identified as influential outliers (all Cook's distances  $<$  1) or multivariate outliers (all Mahalanobis distances  $p > 0.001$ ). Results were retained after applying bias-corrected accelerated bootstrap technique with 10 000 resamples (bootstrapped  $p = 0.05$ ). In addition, Spearman rank correlations



**Fig. 1.** Absolute CBF in the selected a priori ROIs. There were significant main effects of group and ROI, and a significant group\*ROI interaction ( $p = 0.032$ , Greenhouse-Geisser correction). Post-hoc testing showed that CBF was significantly lower in the frontal cortex (Cohen's  $d = 0.84$ ,  $p = 0.009$ ) but not the other regions in patients with FEP relative to controls. FEP = first episode psychosis, HC = healthy controls. Asterisks (\*) indicated significant tests. Bars indicate 95% confidence intervals.



**Fig. 2.** Brain sections showing significantly lower absolute CBF in FEP relative to HC in frontal, parietal and occipital cortex (TFCE corrected clusters). Colorbar indicates t-statistics.

yielded similar results to linear regression analysis (Spearman  $\rho = 0.574$ ,  $p = 0.032$ ).

## Discussion

We found absolute CBF was significantly lower in frontal cortex but not striatum or hippocampus in people with FEP free of antipsychotic medication. Our whole brain analyses found significantly lower perfusion in the patients in additional cortical areas, including the parietal and occipital cortices.

Lower perfusion and metabolism of frontal cortex at rest is a replicated finding in chronic SCZ (Bullmore et al., 1999; Weinberger & Berman, 1988) demonstrated using various neuroimaging techniques including SPECT, [ $^{18}\text{F}$ ]-FDG and [ $^{15}\text{O}$ ]- $\text{H}_2\text{O}$  PET, blood oxygen level dependent (BOLD) signal [i.e. functional magnetic resonance imaging (fMRI)] and recently with ASL (Hill et al., 2004; Kindler et al., 2015). Interestingly previous studies using PET and SPECT in unmedicated FEP revealed reduced

cortical perfusion and metabolism (Brewer et al., 2007; Makarić et al., 2017; Molina et al., 2005). Our results corroborate and extend this evidence by showing the existence of lower frontal cortical absolute perfusion in FEP without the potential confound of antipsychotic treatment using MRI. In addition, our exploratory whole brain analyses indicate cortical hypoperfusion extends beyond the frontal cortex, including both parietal and occipital cortices. This extends evidence that the function of these regions is altered during cognitive tasks in SCZ (Calderone et al., 2013; Hahn, Robinson, Leonard, Luck, & Gold, 2018; Weiss et al., 2009) to show perfusion is also altered early in illness course. In contrast to findings in antipsychotic-treated patients and people at clinical risk of psychosis (Allen et al., 2018; Kindler et al., 2018), we found no significant difference in relative-to-global CBF in the striatum or hippocampus relative to controls. When our results are considered alongside preclinical (Mandeville et al., 2013; Sander et al., 2013, 2019) and clinical (Handley et al., 2013; Selvaggi et al., 2019; Shcherbinin et al., 2015; Viviani et al., 2013) evidence that antipsychotics increase striatal

**Table 2.** Summary of demographics and clinical characteristics of the follow-up study sample

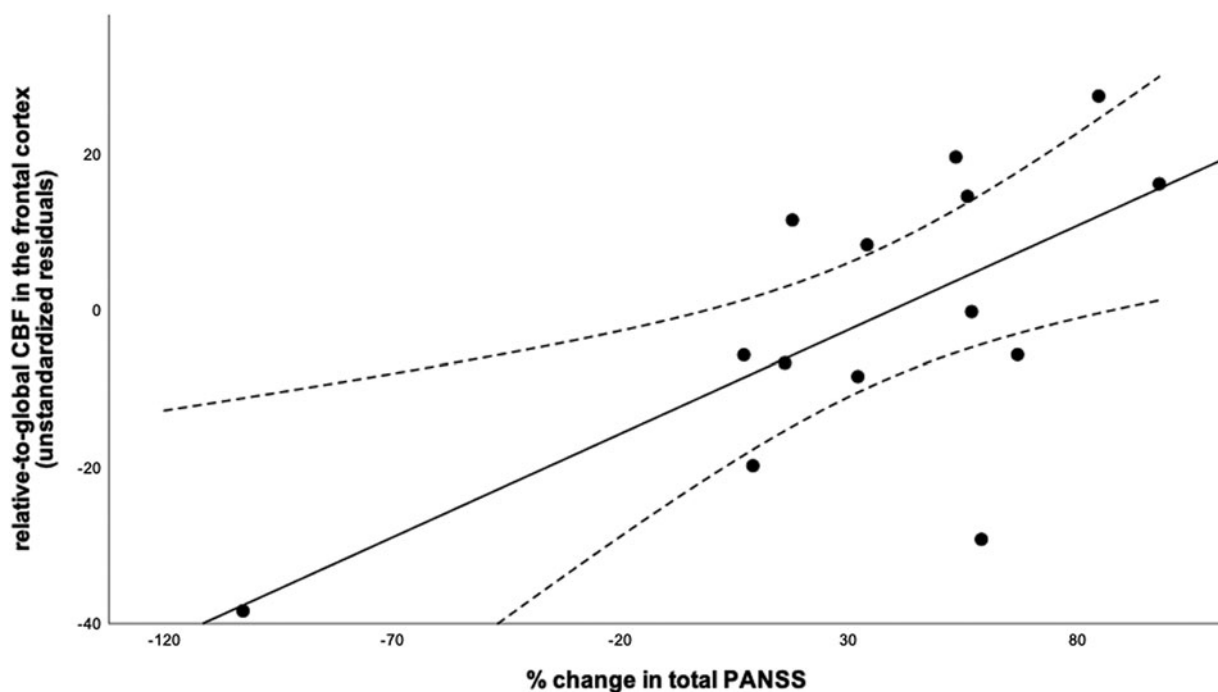
	FEP, <i>n</i> = 14	<i>p</i> value
Age (mean ± s.d.)	23.85 ± 3.77	-
Gender (M/F)	10/4	-
PANSS total baseline (mean ± s.d.)	75.42 ± 18.2	-
PANSS positive baseline (mean ± s.d.)	20.21 ± 6.19	-
PANSS negative baseline (mean ± s.d.)	15.57 ± 6.5	-
PANSS total follow-up (mean ± s.d.)	58.7 ± 19.22	-
PANSS positive follow-up (mean ± s.d.)	13.9 ± 5.5	-
PANSS negative follow-up (mean ± s.d.)	14.5 ± 7.1	-
PANSS total change (mean ± s.d.)	32.6 ± 33.1	0.02
PANSS positive change (mean ± s.d.)	9.4 ± 9.1	0.01
PANSS negative change (mean ± s.d.)	5.9 ± 9.3	0.29
Antipsychotic-naïve (%)	50	-
Antipsychotic-free (%)	29	-
Minimal antipsychotic treatment (%)	21	-
Smoking status (never/past/current)	6/4/4	-
Substance use (never/past/current)	7/4/3	-
Alcohol (never/past/current)	6/3/5	-
Ethnicity (white/black/Asian/others)	1/4/4/5	-

perfusion, with a mechanism possibly mediated by D<sub>2</sub> receptors (Selvaggi et al., 2019), this could indicate that previous evidence of higher striatal CBF in people with SCZ taking antipsychotics might be explained by D<sub>2</sub> receptors blockade.

Longitudinal studies are required to confirm preliminarily evidence (Goozée et al., 2014) suggesting that treatment does increase striatal perfusion in patients.

We did not find any differences in hippocampus in either absolute or relative-to-global perfusion, in contrast to findings in people at clinical risk of psychosis. Taken with our findings in frontal cortex, this could suggest that there is progression of pathophysiological alterations from the hippocampus prior to the onset of psychosis to the frontal cortex with the development of illness. However, it should be recognized that not all subjects at clinical risk develop psychosis and longitudinal studies with repeated scanning are required to test if there are changes in hypoperfusion during the development of psychosis.

Relative-to-global CBF in the frontal cortex at presentation explained approximately 40% of the variance in subsequent response to antipsychotic treatment, such that patients with higher relative-to-global CBF showed higher symptom improvement with treatment. These results extend prior evidence that response to antipsychotic treatment in FEP is associated with functional connectivity (Sarpal et al., 2016), D<sub>2/3</sub> availability (Wulff et al., 2015), and dopamine synthesis capacity (Jauhar et al., 2019) to suggest that relative frontal perfusion could potentially contribute to a biomarker for antipsychotic response in FEP (Veronese et al., 2021). We did not find correlations between relative-to-global CBF in the striatum and hippocampus and PANSS change. However, given the lower CBF in a number of cortical regions in patients, it might be possible that cortical regions other than the frontal cortex are also linked to treatment response but we were underpowered to detect these relationships. We did not find correlations between absolute CBF and PANSS change, suggesting that changes in local perfusion relative to whole brain perfusion are best able to capture variability in clinical response. We found that antipsychotic-free FEP show lower absolute CBF in cortical regions but no significant difference in



**Fig. 3.** Scatterplots showing significant correlations between relative-to-global frontal CBF at baseline and percentage improvement in total PANSS with subsequent treatment ( $r = 0.57$ ,  $p = 0.05$ ).

relative-to-global CBF. Treatment response was associated with relative-to-global frontal CBF but not with absolute CBF. The absence of group differences in relative-to-global CBF are consistent with our whole brain findings that indicate that there is lower absolute CBF in other cortical regions, mainly driven by lower CBF in parietal and occipital cortices as compared with controls. On the other hand, subcortical CBF (i.e. striatal and hippocampal) seems to be unaltered in patients relative to controls (see Bayes factor testing in online Supplementary materials). Thus, taken together, these findings suggest an imbalance between cortical and subcortical blood flow early in SCZ. The association between relative-to-global CBF (but not absolute CBF) with treatment response might seem counterintuitive. However, this finding might be less difficult to interpret considering the direct association between the two variables. Patients with larger positive improvement in symptoms (i.e. greater symptoms reduction) were those with relatively lower alterations in frontal CBF as compared with the rest of the cortex (i.e. higher relative-to-global frontal CBF), suggesting that patients with more marked frontal hypofunction are less responsive to treatment with D<sub>2</sub> blockers. This extends other evidence of frontal dysfunction in patients whose illness does not respond to D<sub>2</sub> blockers (Mouchlianitis, McCutcheon, & Howes, 2016; Potkin et al., 2020). This interpretation is coherent with recent reports indicating neurovascular uncoupling in brain regions such the frontal cortex in SCZ (Sukumar, Sabesan, Anazodo, & Palaniyappan, 2020).

### Strengths and limitations

Strengths of this study include the inclusion of people with FEP free from antipsychotic medication, and longitudinal measures in FEP patients. A methodological strength of the study is the evaluation of both absolute and relative-to-global CBF. Previous studies in CHR-P and FEP have used one metric without reporting the other (Allen et al., 2018; Kindler et al., 2018; Modinos et al., 2018b). However, our results suggest that antipsychotic-free FEP show different pattern of alteration in absolute and relative-to-global CBF. Therefore, we advise that future studies should include both metrics to facilitate comparisons. Previous works testing CBF differences in chronic SCZ as compared with HCs using ASL have shown variability in grey matter perfusion across individuals (Chen et al., 2022; Parkes, Rashid, Chard, & Tofts, 2004; Pinkham et al., 2011; Wang et al., 2004). In our study we used a 3D PCASL with background suppression which offers a non-invasive, efficient and highly reproducible tool to investigate brain perfusion as compared with other ASL methods (Alsop et al., 2015; Chen, Wang, & Detre, 2011). PCASL sequences have shown higher test-retest reliability as compared with other MRI sequences (such as BOLD task or resting state fMRI) used to identify biomarkers in psychosis (Holiga et al., 2018). In addition PCASL has shown good between- and within-subjects reliability [Intraclass coefficient (ICC) range: 0.63–0.83; (Holiga et al., 2018)], and comparable with PET [<sup>18</sup>F]-DOPA [ICC range: 0.42–0.94; (Egerton, Demjaha, McGuire, Mehta, & Howes, 2010)], which has been proposed as a potential biomarker for treatment stratification in psychosis (Veronese et al., 2021). We obtained absolute CBF values on average of 40–50 ml/100 g tissue/min in grey matter in healthy volunteers which are at the lower range of previous investigations using pulsed ASL and/or other scanner manufacturers (Alsop et al., 2015). In our study we used a post-labelling approach and background suppression protocol that was slightly slower than the one recommended by

the ASL white paper (Alsop et al., 2015), which could account for the slightly lower CBF values we obtained. However, we did not find artefactual hyper-perfusion regions in our analysis, suggesting that the post-labelling delay is not having a major effect on data quality. One potential issue in the imaging analysis could be the influence of partial volume effects given structural brain alterations in FEP (Brugger & Howes, 2017). However, we did not find group differences in grey matter volume, total ICV and cortical thickness, suggesting that partial volume effects are unlikely to explain our results, although we cannot completely rule out a contribution of partial volume effects to our findings. Demographic heterogeneity of the sample is thought to be an important factor contributing to variability across individuals. In particular age and gender have been strongly associated with CBF variability (Liu et al., 2012b; Viviani et al., 2009; Zhang et al., 2018). The groups were very similar in mean age and gender distribution. Nevertheless, to check for any influence of these, we conducted further analyses including these as covariates. Our findings remained essentially unchanged when gender and age were added as covariate of no interest (see online Supplementary materials), suggesting these are not influencing our findings. Body-mass index, caffeine intake or nicotine consumption immediately prior to scanning could be other sources of variability. In common with prior studies in psychosis (Davies et al., 2019; Modinos et al., 2018a; Overton, Bhagwat, Viviano, Jacobs, & Voineskos, 2020; Schneider et al., 2019), we did not control for these. However, the two groups were matched by smoking status, alcohol intake and substance use, which suggests that both caffeine intake and nicotine consumption might be similar between groups. Nevertheless, we cannot exclude group differences in use of these substances influencing our findings and further studies matching for intake on these would be useful.

In addition, it should be recognized that the frontal ROI is larger than the hippocampal and striatal ROIs. This may result in a higher signal-to-noise ratio (SNR) for the frontal region over these other regions, and consequently greater sensitivity to detect group differences. However, SNR estimates and sensitivity analyses (see online Supplementary materials) both suggest that it is unlikely that ROI size has affected our results.

Furthermore, in our follow-up study patients were treated in a naturalistic design. Thus, our findings do not provide information about the specific effects of antipsychotic treatment. Finally, although the baseline study constituted a larger cohort than that previously reported in FEP (Kindler et al., 2018), given the relatively modest sample size, further studies are needed to test the generalisability of our findings to other cohorts and settings.

### Implications and future directions

Frontal dysfunction is one of the key mechanisms thought to contribute to the pathophysiology of psychosis (Howes & Murray, 2014; McCutcheon et al. 2020b; Weinberger & Berman, 1988). Our finding that frontal hypoperfusion is present early in the development of the disorder and in unmedicated patients is consistent with these models and other markers of frontal hypofunction in SCZ (Howes and McCutcheon, 2017; Onwordi et al., 2020; Osimo, Beck, Reis Marques, and Howes, 2019). In addition, given the close link between CBF and brain metabolism (Riederer et al., 2018), our results are in line with the evidence of increased lactate levels and pH (Dogan, Yuksel, Du, Chouinard, & Öngür, 2018; Du et al., 2014) and mitochondrial dysfunction in SCZ (Prince,

Blennow, Gottfries, Karlsson, & Oreland, 1999; Rajasekaran, Venkatasubramanian, Berk, & Debnath, 2015) suggesting that altered brain oxidative capacity could be the pathophysiological substrate underlying abnormal brain function in psychosis. In addition, our results suggest alterations in brain perfusion at presentation are associated with subsequent antipsychotic response. These findings suggest that brain perfusion could be used to help predict future response.

Previous evidence suggested antipsychotics may normalize brain metabolism (Buchsbaum et al., 2009), however recently some authors have proposed that this normalization might not be sustainable in some patients (Turkheimer et al., 2020). Future longitudinal studies are therefore needed to understand the effect of antipsychotic treatment on brain metabolism in psychosis.

## Conclusions

Our results provide evidence for lower frontal perfusion in FEP without the potential confound of antipsychotic treatment. In addition, relative CBF in frontal cortex at baseline is associated with subsequent antipsychotic response. These findings indicate there is cortical hypofunction early in the course of psychosis.

**Supplementary material.** The supplementary material for this article can be found at <https://doi.org/10.1017/S0033291722002288>.

**Acknowledgements.** We thank the patients who took part in this study, as well as the clinical teams within SLaM and CNWL who facilitated recruitment. We also thank the Guest editor and the reviewers for the critical in-depth reading of this manuscript and the very constructive comments.

**Financial support.** This study was funded by Medical Research Council-UK (no. MC\_U120097115), Maudsley Charity (no. 666) and Wellcome Trust (no. 094849/Z/10/Z) grants to Prof. Howes. This paper represents independent research part funded by the National Institute for Health Research Biomedical Research Centre at South London and Maudsley NHS Foundation Trust and King's College London that support P. S., S. J., F. Z., M. V., M. A. M. and O. D. H. The views expressed are those of the authors and not necessarily those of the NHS, the NIHR or the Department of Health and Social Care. P. S. is supported by a Ph.D. studentship jointly funded by the NIHR-BRC at SLaM and the Department of Neuroimaging, King's College London. S. J. is funded by a JMAS Sim Fellowship from the Royal College of Physicians, Edinburgh.

**Conflict of interest.** S. J. has received honoraria for educational talks given for Sunovion. K. C. L. has received funding for educational talks S. J. has given. In the past 3 years M. A. M. has acted as an advisory board member for Lundbeck and Forum Pharmaceuticals. He also received research funding from Lundbeck, Takeda and Johnson & Johnson. Dr Howes is a part-time employee of Lundbeck and has received investigator-initiated research funding from and/or participated in advisory/speaker meetings organized by Angelini, Autifony, Biogen, Boehringer-Ingelheim, Eli Lilly, Heptares, Global Medical Education, Invicro, Jansenn, Lundbeck, Mylan, Neurocrine, Otsuka, Sunovion, Rand, Recordati and Roche. Dr Howes has a patent for the use of dopaminergic imaging. No other conflict of interest are disclosed.

**Ethical standards.** The study was approved by the East of England-Cambridge East NHS Research Ethics Committee.

## References

- Agid, O., Kapur, S., Arenovich, T., & Zipursky, R. B. (2003). Delayed-onset hypothesis of antipsychotic action: A hypothesis tested and rejected. *Archives of General Psychiatry*, 60(12), 1228–1235. doi:10.1001/archpsyc.60.12.1228.
- Allen, P., Azis, M., Modinos, G., Bossong, M. G., Bonoldi, I., Samson, C., ... McGuire, P. (2018). Increased resting hippocampal and basal ganglia perfusion in people at ultra high risk for psychosis: Replication in a second cohort. *Schizophrenia Bulletin*, 44(6), 1323–1331. doi:10.1093/schbul/sbx169.
- Allen, P., Chaddock, C. A., Egerton, A., Howes, O. D., Bonoldi, I., Zelaya, F., ... McGuire, P. (2016). Resting hyperperfusion of the hippocampus, midbrain, and basal ganglia in people at high risk for psychosis. *The American Journal of Psychiatry*, 173(4), 392–399. doi:10.1176/appi.ajp.2015.15040485.
- Alsop, D. C., Detre, J. A., Golay, X., Günther, M., Hendrikse, J., Hernandez-Garcia, L., ... Zaharchuk, G. (2015). Recommended implementation of arterial spin-labeled perfusion MRI for clinical applications: A consensus of the ISMRM perfusion study group and the European consortium for ASL in dementia. *Magnetic Resonance in Medicine*, 73(1), 102–116. doi:10.1002/mrm.25197.
- Andreasen, N. C., O'Leary, D. S., Flaum, M., Nopoulos, P., Watkins, G. L., Boles Ponto, L. L., & Hichwa, R. D. (1997). Hypofrontality in schizophrenia: Distributed dysfunctional circuits in neuroleptic-naïve patients. *The Lancet*, 349(9067), 1730–1734. doi:10.1016/s0140-6736(96)08258-x.
- Ashburner, J., & Friston, K. J. (2005). Unified segmentation. *NeuroImage*, 26(3), 839–851. doi:10.1016/j.neuroimage.2005.02.018.
- Brewer, W. J., Yücel, M., Harrison, B. J., McGorry, P. D., Olver, J., Egan, G. F., ... Pantelis, C. (2007). Increased prefrontal cerebral blood flow in first-episode schizophrenia following treatment: Longitudinal positron emission tomography study. *The Australian and New Zealand Journal of Psychiatry*, 41(2), 129–135. doi:10.1080/00048670601109899.
- Brugger, S. P., & Howes, O. D. (2017). Heterogeneity and homogeneity of regional brain structure in schizophrenia: A meta-analysis. *JAMA Psychiatry*, 74(11), 1104–1111. doi:10.1001/jamapsychiatry.2017.2663.
- Buchsbaum, M. S., Haznedar, M., Newmark, R. E., Chu, K.-W., Dusi, N., Entis, J. J., ... Wolkin, A. (2009). FDG-PET and MRI imaging of the effects of serindole and haloperidol in the prefrontal lobe in schizophrenia. *Schizophrenia Research*, 114(1–3), 161–171. doi:10.1016/j.schres.2009.07.015.
- Buchsbaum, M. S., Ingvar, D. H., Kessler, R., Waters, R. N., Cappelletti, J., van Kammen, D. P., ... Sokoloff, L. (1982). Cerebral glucography with positron tomography. Use in normal subjects and in patients with schizophrenia. *Archives of General Psychiatry*, 39(3), 251–259. doi:10.1001/archpsyc.1982.04290030001001.
- Bullmore, E., Brammer, M., Williams, S. C., Curtis, V., McGuire, P., Morris, R., ... Sharma, T. (1999). Functional MR imaging of confounded hypofrontality. *Human Brain Mapping*, 8(2–3), 86–91. doi:10.1002/(SICI)1097-0193(1999)8:2/3<86::AID-HBM3>3.0.CO;2-S.
- Calderone, D. J., Martinez, A., Zemon, V., Hoptman, M. J., Hu, G., Watkins, J. E., ... Butler, P. D. (2013). Comparison of psychophysical, electrophysiological, and fMRI assessment of visual contrast responses in patients with schizophrenia. *NeuroImage*, 67, 153–162. doi:10.1016/j.neuroimage.2012.11.019.
- Chen, J., Xue, K., Yang, M., Wang, K., Xu, Y., Wen, B., ... Wei, Y. (2022). Altered coupling of cerebral blood flow and functional connectivity strength in first-episode schizophrenia patients with auditory verbal hallucinations. *Frontiers in Neuroscience*, 16, 821078. doi:10.3389/fnins.2022.821078.
- Chen, Y., Wang, D. J. J., & Detre, J. A. (2011). Test–retest reliability of arterial spin labeling with common labeling strategies. *Journal of Magnetic Resonance Imaging*, 33(4), 940–949. doi:10.1002/jmri.22345.
- Cook, R. D., & Weisberg, S. (1982). *Residuals and influence in regression*. New York: Chapman and Hall.
- Davies, C., Paloyelis, Y., Rutigliano, G., Cappucciati, M., De Micheli, A., Ramella-Cravaro, V., ... Fusar-Poli, P. (2019). Oxytocin modulates hippocampal perfusion in people at clinical high risk for psychosis. *Neuropsychopharmacology*, 44(7), 1300–1309. doi:10.1038/s41386-018-0311-6.
- Dogan, A. E., Yuksel, C., Du, F., Chouinard, V.-A., & Öngür, D. (2018). Brain lactate and pH in schizophrenia and bipolar disorder: A systematic review of findings from magnetic resonance studies. *Neuropsychopharmacology*, 43(8), 1681–1690. doi:10.1038/s41386-018-0041-9.
- Du, F., Cooper, A. J., Thida, T., Sehovic, S., Lukas, S. E., Cohen, B. M., ... Ongür, D. (2014). In vivo evidence for cerebral bioenergetic abnormalities in schizophrenia measured using <sup>31</sup>P magnetization transfer spectroscopy. *JAMA Psychiatry*, 71(1), 19–27. doi:10.1001/jamapsychiatry.2013.2287.
- Efron, B., & Tibshirani, R. (1986). Bootstrap methods for standard errors, confidence intervals, and other measures of statistical accuracy. *Statistical Science*, 1(1), 54–75. doi:10.1214/ss/1177013815.



- Egerton, A., Demjaha, A., McGuire, P., Mehta, M. A., & Howes, O. D. (2010). The test-retest reliability of  $^{18}\text{F}$ -DOPA PET in assessing striatal and extrastriatal presynaptic dopaminergic function. *NeuroImage*, *50*(2), 524–531. doi:10.1016/j.neuroimage.2009.12.058.
- Eklund, A., Nichols, T. E., & Knutsson, H. (2016). Cluster failure: Why fMRI inferences for spatial extent have inflated false-positive rates. *Proceedings of the National Academy of Sciences of the United States of America*, *113*(28), 7900–7905. doi:10.1073/pnas.1602413113.
- Finch, W. H. (2012). Distribution of variables by method of outlier detection. *Frontiers in Psychology*, *3*, 211. doi:10.3389/fpsyg.2012.00211.
- First, M. B. (2014). Structured clinical interview for the DSM (SCID). In R. L. Cautin & S. O. Lilienfeld (Eds.), *The encyclopedia of clinical psychology* (pp. 1–6). Hoboken, NJ, USA: John Wiley & Sons, Inc. Retrieved from doi:10.1002/9781118625392.wbcp351.
- Fischl, B., & Dale, A. M. (2000). Measuring the thickness of the human cerebral cortex from magnetic resonance images. *Proceedings of the National Academy of Sciences of the United States of America*, *97*(20), 11050–11055. doi:10.1073/pnas.200033797.
- Fusar-Poli, P., Lai, S., Di Forti, M., Iacoponi, E., Thornicroft, G., McGuire, P., & Jauhar, S. (2020). Early intervention services for first episode of psychosis in South London and the Maudsley (SLAM): 20 years of care and research for young people. *Frontiers in Psychiatry*, *11*, 577110. doi:10.3389/fpsyg.2020.577110.
- Goozée, R., Handley, R., Kempton, M. J., & Dazzan, P. (2014). A systematic review and meta-analysis of the effects of antipsychotic medications on regional cerebral blood flow (rCBF) in schizophrenia: Association with response to treatment. *Neuroscience and Biobehavioral Reviews*, *43*, 118–136. doi:10.1016/j.neubiorev.2014.03.014.
- Greve, D. N., & Fischl, B. (2018). False positive rates in surface-based anatomical analysis. *NeuroImage*, *171*, 6–14. doi:10.1016/j.neuroimage.2017.12.072.
- Gur, R. E., Mozley, P. D., Resnick, S. M., Mozley, L. H., Shtasel, D. L., Gallacher, F., ... Reivich, M. (1995). Resting cerebral glucose metabolism in first-episode and previously treated patients with schizophrenia relates to clinical features. *Archives of General Psychiatry*, *52*(8), 657–667. doi:10.1001/archpsyc.1995.03950200047013.
- Hahn, B., Robinson, B. M., Leonard, C. J., Luck, S. J., & Gold, J. M. (2018). Posterior parietal cortex dysfunction is central to working memory storage and broad cognitive deficits in schizophrenia. *The Journal of Neuroscience*, *38*(39), 8378–8387. doi:10.1523/JNEUROSCI.0913-18.2018.
- Handley, R., Zelaya, F. O., Reinders, A. A. T. S., Marques, T. R., Mehta, M. A., O'Gorman, R., ... Dazzan, P. (2013). Acute effects of single-dose aripiprazole and haloperidol on resting cerebral blood flow (rCBF) in the human brain. *Human Brain Mapping*, *34*(2), 272–282. doi:10.1002/hbm.21436.
- Hawkins, P. C. T., Wood, T. C., Vernon, A. C., Bertolino, A., Sambataro, F., Dukart, J., ... Mehta, M. A. (2018). An investigation of regional cerebral blood flow and tissue structure changes after acute administration of antipsychotics in healthy male volunteers. *Human Brain Mapping*, *39*(1), 319–331. doi:10.1002/hbm.23844.
- Hill, K., Mann, L., Laws, K. R., Stephenson, C. M. E., Nimmo-Smith, I., & McKenna, P. J. (2004). Hypofrontality in schizophrenia: A meta-analysis of functional imaging studies. *Acta Psychiatrica Scandinavica*, *110*(4), 243–256. doi:10.1111/j.1600-0447.2004.00376.x.
- Holiga, Š, Sambataro, F., Luzy, C., Greig, G., Sarkar, N., Renken, R. J., ... Dukart, J. (2018). Test-retest reliability of task-based and resting-state blood oxygen level dependence and cerebral blood flow measures. *PLoS One*, *13*(11), e0206583. doi:10.1371/journal.pone.0206583.
- Howes, O. D., & McCutcheon, R. (2017). Inflammation and the neural diathesis-stress hypothesis of schizophrenia: A reconceptualization. *Translational Psychiatry*, *7*(2), e1024. doi:10.1038/tp.2016.278.
- Howes, O. D., & Murray, R. M. (2014). Schizophrenia: An integrated sociodevelopmental-cognitive model. *The Lancet*, *383*(9929), 1677–1687. doi:10.1016/S0140-6736(13)62036-X.
- Jauhar, S., & Howes, O. D. (2019). Understanding and predicting variability in response to treatment in psychotic disorders: In vivo findings. *Clinical Pharmacology and Therapeutics*, *105*(5), 1079–1081. doi:10.1002/cpt.1357.
- Jauhar, S., Veronese, M., Nour, M. M., Rogdaki, M., Hathway, P., Turkheimer, F. E., ... Howes, O. D. (2019). Determinants of treatment response in first-episode psychosis: An  $^{18}\text{F}$ -DOPA PET study. *Molecular Psychiatry*, *24*(10), 1502–1512. doi:10.1038/s41380-018-0042-4.
- Kaar, S. J., Natesan, S., McCutcheon, R., & Howes, O. D. (2020). Antipsychotics: Mechanisms underlying clinical response and side-effects and novel treatment approaches based on pathophysiology. *Neuropharmacology*, *172*, 107704. doi:10.1016/j.neuropharm.2019.107704.
- Kay, S. R., Fiszbein, A., & Opler, L. A. (1987). The positive and negative syndrome scale (PANSS) for schizophrenia. *Schizophrenia Bulletin*, *13*(2), 261–276. doi:10.1093/schbul/13.2.261.
- Kindler, J., Jann, K., Homan, P., Hauf, M., Walther, S., Strik, W., ... Hubl, D. (2015). Static and dynamic characteristics of cerebral blood flow during the resting state in schizophrenia. *Schizophrenia Bulletin*, *41*(1), 163–170. doi:10.1093/schbul/sbt180.
- Kindler, J., Schultze-Lutter, F., Hauf, M., Dierks, T., Federspiel, A., Walther, S., ... Hubl, D. (2018). Increased striatal and reduced prefrontal cerebral blood flow in clinical high risk for psychosis. *Schizophrenia Bulletin*, *44*(1), 182–192. doi:10.1093/schbul/sbx070.
- Legind, C. S., Broberg, B. V., Brouwer, R., Mandl, R. C. W., Ebdrup, B. H., Anhøj, S. J., ... Rostrup, E. (2019). Heritability of cerebral blood flow and the correlation to schizophrenia spectrum disorders: A pseudo-continuous arterial spin labeling twin study. *Schizophrenia Bulletin*, *45*(6), 1231–1241. doi:10.1093/schbul/sbz007.
- Leucht, S., Kane, J. M., Kissling, W., Hamann, J., Etschel, E., & Engel, R. R. (2005). What does the PANSS mean? *Schizophrenia Research*, *79*(2–3), 231–238. doi:10.1016/j.schres.2005.04.008.
- Leucht, S., Winter-van Rossum, I., Heres, S., Arango, C., Fleischhacker, W. W., Glenthøj, B., ... Sommer, I. E. (2015). The optimization of treatment and management of schizophrenia in Europe (OPTiMiSE) trial: Rationale for its methodology and a review of the effectiveness of switching antipsychotics. *Schizophrenia Bulletin*, *41*(3), 549–558. doi:10.1093/schbul/sbv019.
- Levine, S. Z., & Leucht, S. (2012). Early symptom response to antipsychotic medication as a marker of subsequent symptom change: An eighteen-month follow-up study of recent episode schizophrenia. *Schizophrenia Research*, *141*(2–3), 168–172. doi:10.1016/j.schres.2012.08.030.
- Liu, J., Qiu, M., Constable, R. T., & Wexler, B. E. (2012a). Does baseline cerebral blood flow affect task-related blood oxygenation level dependent response in schizophrenia? *Schizophrenia Research*, *140*(1–3), 143–148. doi:10.1016/j.schres.2012.06.028.
- Liu, Y., Zhu, X., Feinberg, D., Guenther, M., Gregori, J., Weiner, M. W., & Schuff, N. (2012b). Arterial spin labeling MRI study of age and gender effects on brain perfusion hemodynamics. *Magnetic Resonance in Medicine*, *68*(3), 912–922. doi:10.1002/mrm.23286.
- Makarić, P., Bošnjak, D., Kekin, I., Jelacic, P., Hauptert, M., Đuran, N., ... Rojnić Kuzman, M. (2017). Alteration of cerebral blood flow measured with SPECT in patients with first episode psychosis. *European Psychiatry*, *41*(S1), S271–S271. doi:10.1016/j.eurpsy.2017.02.099.
- Mandeville, J. B., Sander, C. Y. M., Jenkins, B. G., Hooker, J. M., Catana, C., Vanduffel, W., ... Normandin, M. D. (2013). A receptor-based model for dopamine-induced fMRI signal. *NeuroImage*, *75*, 46–57. doi:10.1016/j.neuroimage.2013.02.036.
- McCutcheon, R. A., Krystal, J. H., & Howes, O. D. (2020a). Dopamine and glutamate in schizophrenia: Biology, symptoms and treatment. *World Psychiatry*, *19*(1), 15–33. doi:10.1002/wps.20693.
- McCutcheon, R. A., Reis Marques, T., & Howes, O. D. (2020b). Schizophrenia – An overview. *JAMA Psychiatry*, *77*(2), 201–210. doi:10.1001/jamapsychiatry.2019.3360.
- Mehta, M. A., McGowan, S. W., Lawrence, A. D., Aitken, M. R. F., Montgomery, A. J., & Grasby, P. M. (2003). Systemic sulpiride modulates striatal blood flow: Relationships to spatial working memory and planning. *NeuroImage*, *20*(4), 1982–1994. doi:10.1016/j.neuroimage.2003.08.007.
- Miller, D. D., Andreasen, N. C., O'Leary, D. S., Rezai, K., Watkins, G. L., Ponto, L. L., & Hichwa, R. D. (1997). Effect of antipsychotics on regional cerebral blood flow measured with positron emission tomography. *Neuropsychopharmacology*, *17*(4), 230–240. doi:10.1016/S0893-133X(97)00042-0.
- Modinos, G., Egerton, A., McMullen, K., McLaughlin, A., Kumari, V., Barker, G. J., ... Zelaya, F. (2018a). Increased resting perfusion of the hippocampus in high positive schizotypy: A pseudocontinuous arterial spin labeling study. *Human Brain Mapping*, *39*(10), 4055–4064. doi:10.1002/hbm.24231.
- Modinos, G., Şimşek, F., Azis, M., Bossong, M., Bonoldi, I., Samson, C., ... McGuire, P. (2018b). Prefrontal GABA levels, hippocampal resting

- perfusion and the risk of psychosis. *Neuropsychopharmacology*, 43(13), 2652–2659. doi:10.1038/s41386-017-0004-6.
- Molina, V., Sanz, J., Reig, S., Martínez, R., Sarramea, F., Luque, R., ... Desco, M. (2005). Hypofrontality in men with first-episode psychosis. *The British Journal of Psychiatry*, 186, 203–208. doi:10.1192/bjp.186.3.203.
- Mouchlianitis, E., McCutcheon, R., & Howes, O. D. (2016). Brain-imaging studies of treatment-resistant schizophrenia: A systematic review. *The Lancet. Psychiatry*, 3(5), 451–463. doi:10.1016/S2215-0366(15)00540-4.
- Oliveira, ÍAF, Guimarães, T. M., Souza, R. M., Dos Santos, A. C., Machado-de-Sousa, J. P., Hallak, J. E. C., & Leoni, R. F. (2018). Brain functional and perfusional alterations in schizophrenia: An arterial spin labeling study. *Psychiatry Research. Neuroimaging*, 272, 71–78. doi:10.1016/j.psychres.2017.12.001.
- Onwordi, E. C., Halff, E. F., Whitehurst, T., Mansur, A., Cotel, M.-C., Wells, L., ... Howes, O. D. (2020). Synaptic density marker SV2A is reduced in schizophrenia patients and unaffected by antipsychotics in rats. *Nature Communications*, 11(1), 246. doi:10.1038/s41467-019-14122-0.
- Osimo, E. F., Beck, K., Reis Marques, T., & Howes, O. D. (2019). Synaptic loss in schizophrenia: A meta-analysis and systematic review of synaptic protein and mRNA measures. *Molecular Psychiatry*, 24(4), 549–561. doi:10.1038/s41380-018-0041-5.
- Ota, M., Ishikawa, M., Sato, N., Okazaki, M., Maikusa, N., Hori, H., ... Kunugi, H. (2014). Pseudo-continuous arterial spin labeling MRI study of schizophrenic patients. *Schizophrenia Research*, 154(1–3), 113–118. doi:10.1016/j.schres.2014.01.035.
- Overton, D. J., Bhagwat, N., Viviano, J. D., Jacobs, G. R., & Voineskos, A. N. (2020). Identifying psychosis spectrum youth using support vector machines and cerebral blood perfusion as measured by arterial spin labeled fMRI. *NeuroImage. Clinical*, 27, 102304. doi:10.1016/j.nicl.2020.102304.
- Parkes, L. M., Rashid, W., Chard, D. T., & Tofts, P. S. (2004). Normal cerebral perfusion measurements using arterial spin labeling: Reproducibility, stability, and age and gender effects. *Magnetic Resonance in Medicine*, 51(4), 736–743. doi:10.1002/mrm.20023.
- Pinkham, A., Loughhead, J., Ruparel, K., Wu, W.-C., Overton, E., Gur, R., & Gur, R. (2011). Resting quantitative cerebral blood flow in schizophrenia measured by pulsed arterial spin labeling perfusion MRI. *Psychiatry Research*, 194(1), 64–72. doi:10.1016/j.psychres.2011.06.013.
- Pinkham, A. E., Liu, P., Lu, H., Kriegsmann, M., Simpson, C., & Tamminga, C. (2015). Amygdala hyperactivity at rest in paranoid individuals with schizophrenia. *The American Journal of Psychiatry*, 172(8), 784–792. doi:10.1176/appi.ajp.2014.14081000.
- Potkin, S. G., Kane, J. M., Correll, C. U., Lindenmayer, J.-P., Agid, O., Marder, S. R., ... Howes, O. D. (2020). The neurobiology of treatment-resistant schizophrenia: Paths to antipsychotic resistance and a roadmap for future research. *Focus*, 18(4), 456–465. doi:10.1176/appi.focus.18309.
- Prince, J. A., Blennow, K., Gottfries, C. G., Karlsson, I., & Oreland, L. (1999). Mitochondrial function is differentially altered in the basal ganglia of chronic schizophrenics. *Neuropsychopharmacology*, 21(3), 372–379. doi:10.1016/S0893-133X(99)00016-0.
- Rajasekaran, A., Venkatasubramanian, G., Berk, M., & Debnath, M. (2015). Mitochondrial dysfunction in schizophrenia: Pathways, mechanisms and implications. *Neuroscience and Biobehavioral Reviews*, 48, 10–21. doi:10.1016/j.neubiorev.2014.11.005.
- Riederer, I., Bohn, K. P., Preibisch, C., Wiedemann, E., Zimmer, C., Alexopoulos, P., & Förster, S. (2018). Alzheimer disease and mild cognitive impairment: Integrated pulsed arterial spin-labeling MRI and <sup>18</sup>F-FDG PET. *Radiology*, 288(1), 198–206. doi:10.1148/radiol.2018170575.
- Salat, D. H., Buckner, R. L., Snyder, A. Z., Greve, D. N., Desikan, R. S. R., Busa, E., ... Fischl, B. (2004). Thinning of the cerebral cortex in aging. *Cerebral Cortex*, 14(7), 721–730. doi:10.1093/cercor/bbh032.
- Sander, C. Y., Hooker, J. M., Catana, C., Normandin, M. D., Alpert, N. M., Knudsen, G. M., ... Mandeville, J. B. (2013). Neurovascular coupling to D2/D3 dopamine receptor occupancy using simultaneous PET/functional MRI. *Proceedings of the National Academy of Sciences of the United States of America*, 110(27), 11169–11174. doi:10.1073/pnas.1220512110.
- Sander, C. Y., Hooker, J. M., Catana, C., Rosen, B. R., & Mandeville, J. B. (2016). Imaging agonist-induced D2/D3 receptor desensitization and internalization in vivo with PET/fMRI. *Neuropsychopharmacology*, 41(5), 1427–1436. doi:10.1038/npp.2015.296.
- Sander, C. Y., Mandeville, J. B., Wey, H.-Y., Catana, C., Hooker, J. M., & Rosen, B. R. (2019). Effects of flow changes on radiotracer binding: Simultaneous measurement of neuroreceptor binding and cerebral blood flow modulation. *Journal of Cerebral Blood Flow and Metabolism*, 39(1), 131–146. doi:10.1177/0271678X17725418.
- Sarpal, D. K., Argyelan, M., Robinson, D. G., Szeszko, P. R., Karlsgodt, K. H., John, M., ... Malhotra, A. K. (2016). Baseline striatal functional connectivity as a predictor of response to antipsychotic drug treatment. *The American Journal of Psychiatry*, 173(1), 69–77. doi:10.1176/appi.ajp.2015.14121571.
- Schneider, K., Michels, L., Hartmann-Riemer, M. N., Burrer, A., Tobler, P. N., Stämpfli, P., ... Kaiser, S. (2019). Cerebral blood flow in striatal regions is associated with apathy in patients with schizophrenia. *Journal of Psychiatry & Neuroscience*, 44(2), 102–110. doi:10.1503/jpn.170150.
- Schobel, S. A., Chaudhury, N. H., Khan, U. A., Paniagua, B., Styner, M. A., Asllani, I., ... Small, S. A. (2013). Imaging patients with psychosis and a mouse model establishes a spreading pattern of hippocampal dysfunction and implicates glutamate as a driver. *Neuron*, 78(1), 81–93. doi:10.1016/j.neuron.2013.02.011.
- Selvaggi, P., Hawkins, P. C. T., Dipasquale, O., Rizzo, G., Bertolino, A., Dukart, J., ... Mehta, M. A. (2019). Increased cerebral blood flow after single dose of antipsychotics in healthy volunteers depends on dopamine D2 receptor density profiles. *NeuroImage*, 188, 774–784. doi:10.1016/j.neuroimage.2018.12.028.
- Shcherbinin, S., Doyle, O., Zelaya, F. O., de Simoni, S., Mehta, M. A., & Schwarz, A. J. (2015). Modulatory effects of ketamine, risperidone and lamotrigine on resting brain perfusion in healthy human subjects. *Psychopharmacology*, 232(21–22), 4191–4204. doi:10.1007/s00213-015-4021-z.
- Smith, S. M., & Nichols, T. E. (2009). Threshold-free cluster enhancement: Addressing problems of smoothing, threshold dependence and localisation in cluster inference. *NeuroImage*, 44(1), 83–98. doi:10.1016/j.neuroimage.2008.03.061.
- Sukumar, N., Sabesan, P., Anazodo, U., & Palaniyappan, L. (2020). Neurovascular uncoupling in schizophrenia: A bimodal meta-analysis of brain perfusion and glucose metabolism. *Frontiers in Psychiatry*, 11, 754. doi:10.3389/fpsyt.2020.00754.
- Taylor, D. M., Barnes, T. R. E., & Young, A. H. (2018). *The Maudsley prescribing guidelines in psychiatry* (13th ed.). Hoboken, NJ: John Wiley & Sons.
- Townsend, L., Pillinger, T., Selvaggi, P., Veronese, M., Turkheimer, F., & Howes, O. (2022). Brain glucose metabolism in schizophrenia: A systematic review and meta-analysis of 18FDG-PET studies in schizophrenia. *Psychological Medicine*, 22, 1–18. doi:10.1017/S003329172200174X.
- Turkheimer, F. E., Selvaggi, P., Mehta, M. A., Veronese, M., Zelaya, F., Dazzan, P., & Vernon, A. C. (2020). Normalizing the abnormal: Do antipsychotic drugs push the cortex into an unsustainable metabolic envelope? *Schizophrenia Bulletin*, 46(3), 484–495. doi:10.1093/schbul/sbz119.
- Veronese, M., Santangelo, B., Jauhar, S., D'Ambrosio, E., Demjaha, A., Salimbeni, H., ... Howes, O. (2021). A potential biomarker for treatment stratification in psychosis: Evaluation of an [18F] FDOPA PET imaging approach. *Neuropsychopharmacology*, 46, 1122–1132. doi:10.1038/s41386-020-00866-7.
- Viviani, R., Abler, B., Seeringer, A., & Stingl, J. C. (2012). Effect of paroxetine and bupropion on human resting brain perfusion: An arterial spin labeling study. *NeuroImage*, 61(4), 773–779. doi:10.1016/j.neuroimage.2012.03.014.
- Viviani, R., Graf, H., Wieggers, M., & Abler, B. (2013). Effects of amisulpride on human resting cerebral perfusion. *Psychopharmacology*, 229(1), 95–103. doi:10.1007/s00213-013-3091-z.
- Viviani, R., Sim, E.-J., Lo, H., Richter, S., Haffer, S., Osterfeld, N., ... Beschoner, P. (2009). Components of variance in brain perfusion and the design of studies of individual differences: The baseline study. *NeuroImage*, 46(1), 12–22. doi:10.1016/j.neuroimage.2009.01.041.
- Wang, J., Li, L., Roc, A. C., Alsop, D. C., Tang, K., Butler, N. S., ... Detre, J. A. (2004). Reduced susceptibility effects in perfusion fMRI with single-shot spin-echo EPI acquisitions at 1.5 Tesla. *Magnetic Resonance Imaging*, 22(1), 1–7. doi:10.1016/S0730-725X(03)00210-8.
- Weinberger, D. R., & Berman, K. F. (1988). Speculation on the meaning of cerebral metabolic hypofrontality in schizophrenia. *Schizophrenia Bulletin*, 14(2), 157–168. doi:10.1093/schbul/14.2.157.

- Weiss, A. P., Ellis, C. B., Roffman, J. L., Stufflebeam, S., Hamalainen, M. S., Duff, M., ... Schacter, D. L. (2009). Aberrant frontoparietal function during recognition memory in schizophrenia: A multimodal neuroimaging investigation. *The Journal of Neuroscience*, *29*(36), 11347–11359. doi:10.1523/JNEUROSCI.0617-09.2009.
- Winkler, A. M., Ridgway, G. R., Webster, M. A., Smith, S. M., & Nichols, T. E. (2014). Permutation inference for the general linear model. *NeuroImage*, *92*, 381–397. doi:10.1016/j.neuroimage.2014.01.060.
- World Health Organization. (2004). *ICD-10: international statistical classification of diseases and related health problems : tenth revision* (2nd ed.). Geneva, Switzerland: World Health Organization.
- Wulff, S., Pinborg, L. H., Svarer, C., Jensen, L. T., Nielsen, M. Ø., Allerup, P., ... Glenthøj, B. Y. (2015). Striatal D(2/3) binding potential values in drug-naïve first-episode schizophrenia patients correlate With treatment outcome. *Schizophrenia Bulletin*, *41*(5), 1143–1152. doi:10.1093/schbul/sbu220.
- Zhang, N., Gordon, M. L., Ma, Y., Chi, B., Gomar, J. J., Peng, S., ... Goldberg, T. E. (2018). The age-related perfusion pattern measured with arterial spin labeling MRI in healthy subjects. *Frontiers in Aging Neuroscience*, *10*, 214. doi:10.3389/fnagi.2018.00214.
- Zhu, J., Zhuo, C., Xu, L., Liu, F., Qin, W., & Yu, C. (2017). Altered coupling between resting-state cerebral blood flow and functional connectivity in schizophrenia. *Schizophrenia Bulletin*, *43*(6), 1363–1374. doi:10.1093/schbul/sbx051.