


Revisiting the retroauricular revolving door island flap: Our experience

Carolina Mora Sánchez¹, Natsuki Oishi^{1,2} , Agustín Campos Catalá¹ and Enrique Zapater Latorre^{1,2}

¹Department of otorhinolaryngology, University General Hospital, Valencia, Spain and ²Surgery Department, Valencia Medical School, University of Valencia, Valencia, Spain

Short Communication

Natsuki Oishi takes responsibility for the integrity of the content of the paper

Cite this article: Mora Sánchez C, Oishi N, Campos Catalá A, Zapater Latorre E. Revisiting the retroauricular revolving door island flap: Our experience. *J Laryngol Otol* 2025;1-3. <https://doi.org/10.1017/S0022215124001440>

Received: 14 March 2024

Revised: 30 May 2024

Accepted: 27 June 2024

Keywords:

pinna; head and neck surgery; cancer; pinna/microsia/atresia; facio-plastic surgery

Corresponding author:

Natsuki Oishi;

Email: Miriam.N.Oishi@uv.es

Abstract

Objectives. Surgical treatment of auricular concha, the helix root and the external auditory canal tumours, and their reconstruction, is a challenge because of the complexity of this anatomic region and the significant functional and aesthetic requirements of these treatments. The purpose of this study is to describe our experience with the retroauricular revolving door island flap technique.

Method. This was a retrospective descriptive study (series of nine clinical cases) conducted between 2020 and 2023 of revolving door island flap reconstruction of auricular conchal and external auditory canal defects caused by tumour removal.

Results. In all the cases, tumour-free margins and total reconstruction of the defect were achieved through the revolving door island flap intervention, with optimal aesthetic and functional results.

Conclusion. Revolving door island flap reconstruction is a viable surgical option for the reconstruction of auricular conchal and external auditory canal defects because of its versatility, reproducibility, low post-operative morbidity and optimal results.

Introduction

The most prevalent tumours of the pinna include basal cell carcinoma (90 per cent of the malignant skin lesions of the head and neck), squamous carcinoma, and other tumours such as melanomas. These primarily affect white males over the age of 65 with a personal history of photoexposure¹ and have a slow evolution with infrequent metastasis.² The treatment for malignant lesions of the pinna is radical surgery, leaving tumour-free margins.³⁻⁶ Radiotherapy may be useful as an adjuvant systemic treatment or in cases where there are affected edges.⁷

Resection and reconstruction of lesions of the auricular concha are complicated because the skin in this area is thin and easily adheres to the auricular cartilage, it is difficult to find a donor site with a versatile pedicle, and aesthetic reconstructions require sufficient support to allow the pinna to be functional.⁸ In cases of tumour resections where simple closure is impossible, there are several possibilities: closure of the defect with a free graft, healing by secondary intention, or reconstruction with pedicled flaps.⁸

The use of retroauricular flaps is a useful and versatile alternative technique for covering defects of the conchal region involving cartilage. They are supplied by the retroauricular artery and its superior, medial, and inferior branches, which irrigate a large part of the pinna, thereby forming an anastomotic network with a large vascular supply.⁸ The aim of this present study was to popularise this technique which, despite having been described some time ago, is not well-known among ENT specialists.

Technique

This series included nine patients operated for benign or malignant lesions of the pinna from 2020 to 2023 in the Department of Otorhinolaryngology and Head and Neck Surgery at a University Hospital. Five of the patients were operated under general anaesthesia, and in four cases, the procedure was performed with local anaesthesia. The retroauricular area was injected with local aesthetic and a vasoconstrictor (mepivacaine + epinephrine 1:50.000) prior to incision.

Regarding the surgical technique, first, the area to be excised from the auricular concha is defined, leaving sufficient space to achieve tumour-free edges. The size of the tumour area defines the retroauricular donor area, which is located partly in the mastoid region and partly in the retroauricular area (Figures 1A and 1B). After excision of the tumour lesion, a flap is fashioned for reconstruction, applying a technique similar to that used in otoplasty. Thus, an incision is made following the previously marked line to form a flap centred on the retroauricular groove (Figure 1C). Part of the cartilage in the flap area is subsequently resected to allow mobilisation of the flap in a forward direction. It is important not to damage the skin of the posterior region of the concha because it forms part of the flap. After pediculating the flap, it is transposed forward through the

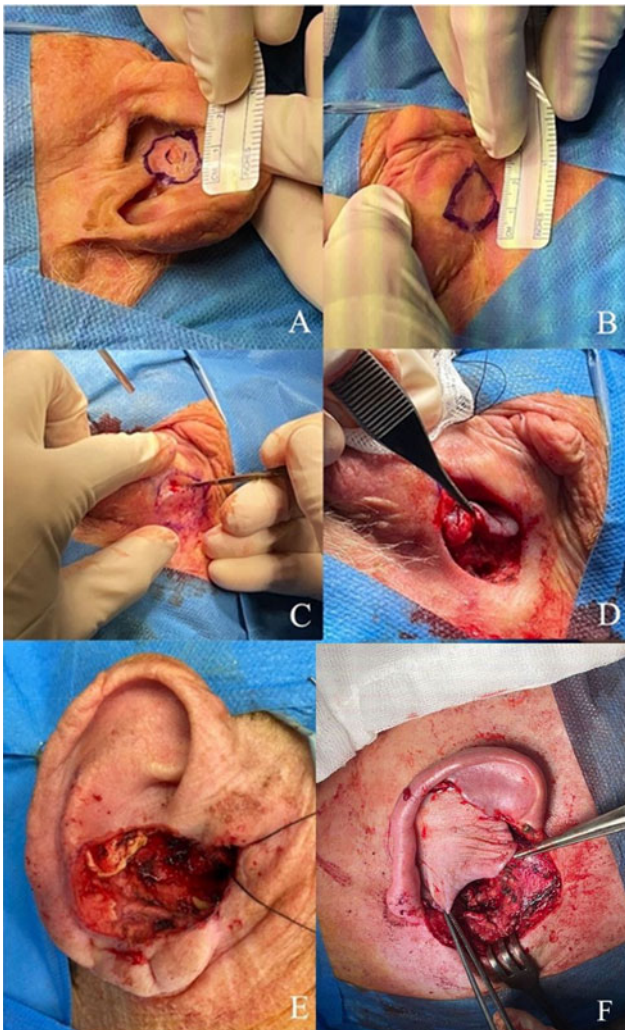


Figure 1. Surgical technique. A, B: Identification of lesion, delimitation of resection area and retroauricular flap zone. C, D: Creation of the retroauricular flap. E: Anterior resection area with oncological margins. F: Anterior transposition of the created flap to cover the concha, in this case the defect was 5.5cm x 5.5cm (case 7 of the table).

cartilage to cover the defect and is then sutured with silk (Figure 1D). The wound at the retroauricular level is also closed with silk with no further manipulations.^{1,2} In all of our cases, POPE® packing was used, and a single dose of otic antibiotic therapy was given after surgery to help avoid external auditory canal (EAC) stenosis.

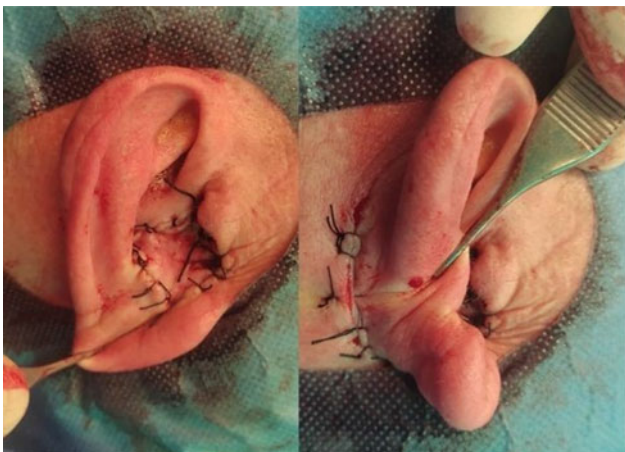

Figure 2. Immediate post-surgical result, anterior and posterior views.

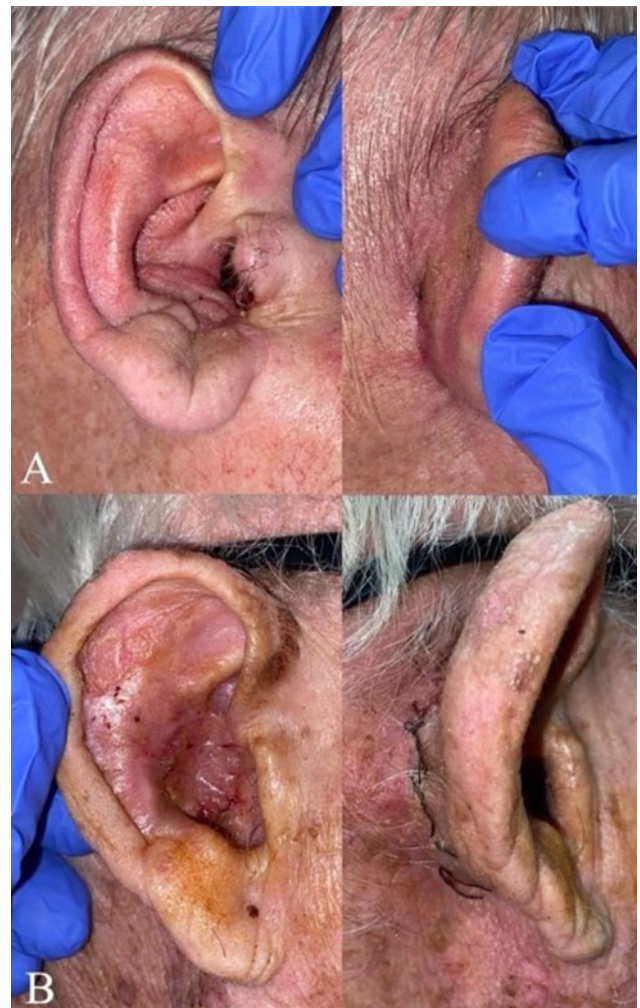


Figure 3. Post-surgical results. A: Patient 1, one month after surgery, anterior and posterior views. B: Patient 2, one week after surgery, anterior and posterior views.

Since 2020, we have performed the retroauricular island flap technique in a total of nine patients (five men and four women) with an average age of 67 years (Table 1). Complete resection of the neoplastic lesion with tumour-free margins and total coverage of the defect by the retroauricular island flap was achieved in all the cases, with favourable aesthetic and functional results in the immediate post-operative period (Figures 2 and 3). After surgery, no cases of flap infection or necrosis were recorded in any of the patients, although there was one case of EAC stenosis.

Discussion

Masson first described the RDIF technique, which would later be used by Jackson.⁹ Creation of a flap has several important advantages over free grafts, including the ability to match the graft thickness, colour, and texture with the skin of the site to be grafted; minimal morbidity; and allowing the possibility of primary closure of the donor area.¹⁰ It is an easily reproducible technique that can be performed with local anaesthesia, does not require too much surgical time, and with no need to search for the flap pedicle. However, despite its advantages in terms of surgical technique and aesthetic and functional outcomes, we have found no evidence that it is popular among ENT surgeons.

The aggressiveness of malignant tumours of the pinna is directly related to the possibility of infiltration of the EAC.³

Table 1. Our series group study

Histological type	Age (years)	Gender	Complications	EAR	Defect size	anesthesia
Squamous cell carcinoma	76	Female	Stenosis of the external auditory canal	Right	Not specified in the surgical report	General
basal cell carcinoma	61	Female	No	Right	Not specified in the surgical report	General
basal cell carcinoma	73	Male	No	Right	2.5 cm at its largest diameter	General
Squamous cell carcinoma	87	Male	No	Right	2 cm at its largest diameter	Local
non-neoplastic vascular lesion	38	Female	No	Left	1.8 x 1.8 cm	Local
basal cell carcinoma	39	Female	No	Right	1 x 1.5 mm	General
basal cell carcinoma	62	Male	No	Right	5.5 x 5.5 cm	General
Squamous cell carcinoma	87	Male	No	Left	2 x 2 cm	Local
keratoacanthoma	79	Male	No	Left	2.5 x 2.5 cm	Local

Among these malignant lesions, squamous carcinoma most often affects the EAC, representing up to 70 per cent of cases in some series.⁴ Surgical treatment of tumours affecting both the pinna and the EAC is a challenge because reconstruction of the latter requires a patency with a minimum diameter of 4 mm to be maintained.¹¹ In these cases, the RDIF technique can be used alone or as a complement to another reconstruction approach, given its versatility in terms of shape and size to cover conchal defects larger than 6 cm.⁵

Possible complications of RDIF are necrosis, infection, recurrence or metastasis.⁸ The academic literature also describes cases of posterior retraction of the auricular pavilion (especially in patients with large pinnae), although the elasticity of the tissues allows resolution of this problem in the long term. Nonetheless, in the case series reported here, none of these complications occurred.

Conclusion

RDIF reconstruction is an easily reproducible and reliable technique that allows the reconstruction of auricular concha defects to achieve both aesthetic and functional objectives. Its use offers great advantages over other reconstructive techniques, which is why we believe its use by ENT surgeons should be revived.

Competing interests. The authors declare no potential conflicts of interest.

Financial disclosure. None.

Level of evidence. 4. Case series

References

- Papa G, Stocco C, Arnez ZM. Middle-retroauricular island flap: A new axial flap for reconstruction of non-helical ear defects. *Plast Reconstr Surg Glob Open* 2020;**8**:e3207
- Dubernard X, Kleiber J-C, Brenet E, Louges M-A, Veleine Y, Labrousse M, et al. [The tumors of the ear]. *Presse Med* 2017;**46**:1079–88
- Iljin A, Antoszewski B, Durko M, Zieliński T, Stabryła P, Pietruszewska W. External ear carcinoma: Evaluation of surgical and reconstructive management with postauricular island flap. *Postepy Dermatol Alergol* 2022;**39**:1134–40
- Ouaz K, Robier A, Lescanne E, Bobillier C, Morinière S, Bakhos D. Cancer of the external auditory canal. *Eur Ann Otorhinolaryngol Head Neck Dis* 2013;**130**:175–82
- Clark DP, Hanke CW. Neoplasms of the conchal bowl: Treatment with Mohs micrographic surgery. *J Dermatol Surg Oncol* 1988;**14**:1223–8
- Prasad S, Janecka IP. Efficacy of surgical treatments for squamous cell carcinoma of the temporal bone: A literature review. *Otolaryngol Head Neck Surg* 1994;**110**:270–80
- Bacciu A, Clemente IA, Piccirillo E, Ferrari S, Sanna M. Guidelines for treating temporal bone carcinoma based on long-term outcomes. *Otol Neurotol* 2013;**34**:898–907
- Zhu J, Zhao H, Wu K, Lv C, Bi H-d, Sun M-Y, et al. Reconstruction of auricular conchal defects with local flaps. *Medicine (Baltimore)* 2016;**95**:e5282
- Jackson IT, Milligan L, Agrawal K. The versatile revolving door flap in the reconstruction of ear defects. *Eur J Plast Surg* 1994;**17**:131–3
- Stiller MB, Gerressen M, Modabber A, Rübber A, Riediger D, Ghassemi A. Anteriorly pedicled retroauricular flap for repair of auricular defects. *Aesthetic Plast Surg* 2012;**36**:623–7
- Shaari AL, Xing MH, Mundi N, Khorsandi AS, Geronemus R, Urken ML. Reconstruction of the external auditory canal: The tragal flap revisited and review of contemporary reconstructive techniques. *Am J Otolaryngol* 2021;**42**:103094