

Clinical Record

Sachin Tushar Patel takes responsibility for the integrity of the content of the paper

*Equal first authors

Cite this article: Patel ST, Dusu K, Moharrum T, Salem M. An unusual presentation: temporomandibular tissue herniation through congenital foramen of Huschke. *J Laryngol Otol* 2024;**138**:811–813. <https://doi.org/10.1017/S0022215124000136>

Received: 30 October 2023

Accepted: 6 December 2023

First published online: 15 January 2024

Keywords:

Embryology; ear canal; diagnosis; otologic surgical procedures

Corresponding author:

Sachin Tushar Patel;
Email: s.patel28@nhs.net

An unusual presentation: temporomandibular tissue herniation through congenital foramen of Huschke

Sachin Tushar Patel^{1,*} , Keli Dusu^{2,*}, Tamir Moharrum²
and Mohammed Salem²

¹Department of Otorhinolaryngology, Leicester Royal Infirmary, Leicester, UK and ²Department of Otorhinolaryngology, Surrey and Sussex Healthcare NHS Trust, East Surrey Hospital, Redhill, UK

Abstract

Background. The herniation of temporomandibular tissue through the foramen of Huschke into the external auditory canal is a rare clinical anomaly. This paper describes one such case and provides an overview of the relevant literature. This paper elaborates upon the aetiology, clinical assessment, management and associated complications.

Case report. A 54-year-old woman presented with a 3-month history of right ear pain and a polypoid lesion in her right ear canal. This lesion expanded during a Valsalva manoeuvre, and imaging demonstrated a defect in the antero-superior aspect of the canal with herniation of soft tissue. The patient was managed conservatively as the symptoms resided.

Conclusion. Ear canal lesions that protrude or change in size with a Valsalva manoeuvre could be due to a persistent foramen of Huschke. In symptomatic cases needing surgical intervention, a variety of materials may be used to close the defect. Titanium mesh, with or without cartilage overlay, appears to be the most popular choice.

Introduction

The external auditory canal is an area that extends from the concha to the tympanic membrane, and is lined with keratinised stratified squamous epithelium.¹ The lateral one-third of the canal is bounded by fibrocartilaginous material, whilst the medial two-thirds are surrounded by the tympanic and squamous parts of the temporal bone. The external auditory canal begins its development around the 1st branchial cleft, growing medially as a solid core of ectoderm. Canalisation occurs between the 8th and 10th week of gestation, during which four ossification centres develop around the tympanic membrane, forming a U-shaped bone.² An anterior and posterior prominence to the U-shaped bone begin to develop and move towards each other, fusing at one year of age. However, a small dehiscence medial to the point of fusion remains until five years of age.

Congenital abnormalities of the external auditory canal are uncommon, of which, anomalies resulting in the herniation of temporomandibular joint (TMJ) tissue into the external auditory canal are extremely rare.³ Defects of the external auditory canal wall are commonly attributed to trauma, infection and malignancy. This report highlights a case of TMJ tissue herniation through a congenital defect, the foramen of Huschke. We provide a summary of the condition alongside treatment options that clinicians may want to consider.

Case report

A 54-year-old female was referred to the ENT clinic by her general practitioner. She had reported a three-month history of right-sided ear pain, and on otoscopy the general practitioner had noted a white lesion in her right external auditory canal. In clinic, she denied any otorrhoea, but did note symptoms consistent with Eustachian tube dysfunction (clicking sounds, muffled sounds and the feeling of a blockage in her ear). She also described feeling dizzy when she changed position with sudden movement. She had a longstanding history of itchy ears and was a regular swimmer. She denied any recent ear infections, previous trauma, surgery or a history of TMJ dysfunction. She was otherwise fit and well apart from hypertension and eczema. Her only regular medication was lisinopril and she had no known drug allergies.

On examination in clinic, her left ear was normal and a lesion was seen in the right external auditory canal. Endoscopic examination demonstrated a small soft polypoid lesion at the antero-superior aspect of the medial external auditory canal ([Figure 1](#)). This lesion increased in size during a Valsalva manoeuvre (as evident in a short video, available on *The Journal of Laryngology & Otology* website (Appendix 1)). The tympanic membranes were normal in both ears. A pure tone audiogram demonstrated bilateral hearing within normal limits.

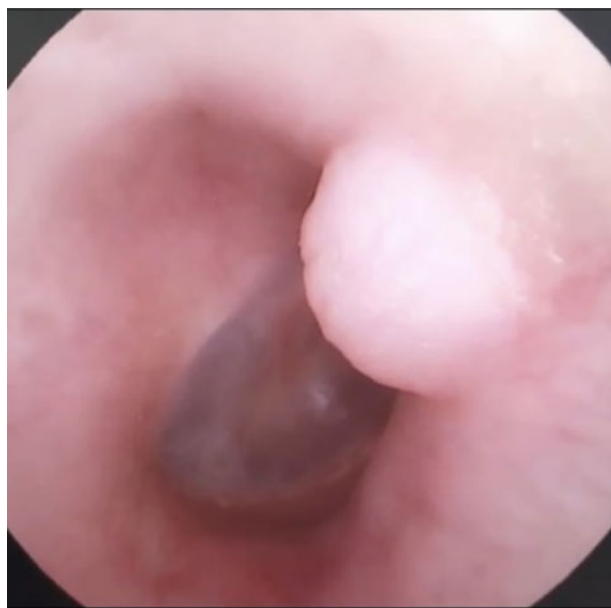

Figure 1. Endoscopic view of the right-sided external auditory canal lesion.

A computed tomography (CT) scan confirmed a defect in the right external auditory canal (Figures 2 and 3) with mucosal thickening in both maxillary antra. Magnetic resonance imaging (MRI) revealed an antero-superior bony defect (3.47 mm × 3.31 mm) within the right external auditory canal, with a small polyp connected to the right TMJ/parotid gland. To better characterise the bony defect, the radiology department suggested performing a CT scan during inspiration. This did not generate any improved images for review. As the patient's symptoms improved without treatment, she was managed conservatively.

Discussion

The failure of the medial dehiscence to close between the anterior and posterior prominences of the external auditory

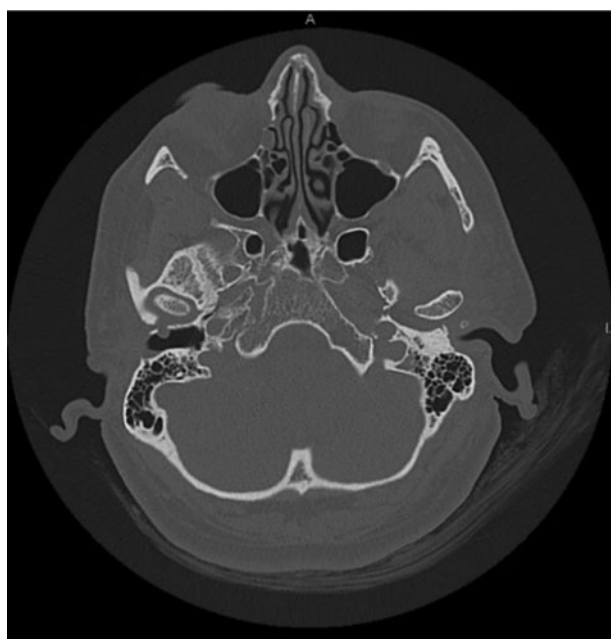


Figure 2. Axial computed tomography view of the right-sided external auditory canal foramen of Huschke and protrusion of soft tissue through the defect.

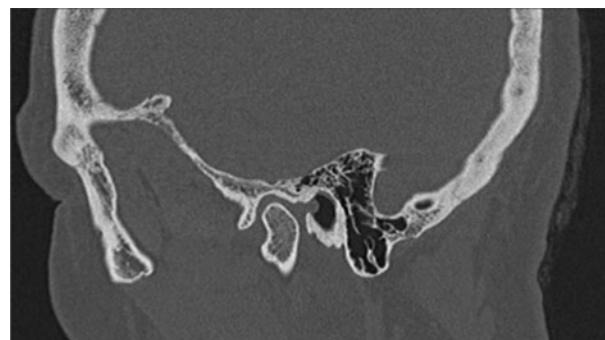


Figure 3. Sagittal computed tomography view of the right-sided external auditory canal foramen of Huschke and protrusion of soft tissue through the defect.

canal results in a defect known as the foramen tympanicum or foramen of Huschke. The foramen of Huschke leads to a sinus between the external auditory canal and the TMJ. This defect is present in around 4 per cent of the population.⁴ The anomaly is typically located at the anterior inferior aspect of the external auditory canal, posteromedial to the TMJ.

A review of the literature showed limited case reports regarding TMJ tissue herniation through a foramen of Huschke. The causes of TMJ herniation into the external auditory canal described in the literature include infection, trauma, mass effect and rheumatoid arthritis of the TMJ. Clinical presentation is also variable, with patients presenting with hearing loss, otalgia or no symptoms. Persistence of the foramen also appears to correlate with patients who have a TMJ disorder (3.4 per cent) compared to those without (0.8 per cent).⁴ Asymptomatic patients are identified upon direct visualisation of the herniated tissue during otoscopy. Typically, this tissue protrudes on closure of the jaw.⁵ There is also a suggestion of female preponderance in the literature, possibly due to reduced tympanic bone thickness, and altered development and growth of the mandible when compared to male counterparts.⁶

We note that our case does not meet the classical diagnosis of a persistent foramen of Huschke. In our patient, the bone defect is located in the antero-superior aspect of the canal, and the lesion does not protrude on a change in jaw position. This case highlights the importance for patients with a mass in the ear canal to be investigated by secondary care. As evident in Appendix 1, the size of the mass was related to a Valsalva manoeuvre. To our knowledge, there have been no reports relating expansion of external auditory canal lesions with a Valsalva manoeuvre. We therefore encourage clinicians to assess patients using a Valsalva manoeuvre as well as changing jaw position. This may aid in the diagnosis of a persistent foramen of Huschke.

The diagnosis is confirmed radiologically, and a high-resolution CT scan of the petrous temporal bone is usually sufficient to delineate the defect and soft tissue protrusion. An MRI scan may aid in defining the content of the soft tissue, particularly joint synovium or salivary tissue content.

Management of this condition is often conservative, unless the mass is causing significant issues (hearing loss or infection). Surgical intervention must be balanced with the benefit to patients and their suitability for surgery.

A review of the literature highlighted 16 cases treated surgically. A variety of techniques have been employed, most commonly mesh and/or cartilage. The most common mesh used is titanium, either in isolation or with tragal cartilage. Lim *et al.* reported no complications at one year following titanium mesh use and cartilage repair.⁷ However, Ryu *et al.* used

titanium mesh only, and their patient had mild residual bulging at the two-month follow up.⁸ Titanium plating and collagen mesh have also been utilised. Singh *et al.* reported no recurrence at one year post-operatively when using a collagen mesh only.⁹ Other surgeons have also used tragal or conchal cartilage alone. One centre used curettage of the lesion and split thickness skin-grafting, with no recurrence reported.¹⁰ As all studies are case reports, with either limited or no follow up, we cannot accurately define which surgical method is most appropriate.

- A persistent foramen of Huschke may cause protrusion of soft tissue into the external auditory canal
- Ear canal lesions should be examined whilst changing jaw position and during a Valsalva manoeuvre
- Asymptomatic patients can be managed conservatively
- Surgical interventions include mesh, cartilage and skin grafts to close the defect

Furthermore, it is important to be aware of the potential issues that a persistent foramen of Huschke may cause. There have been reports of inadvertent injury following TMJ arthroscopy, with the arthroscope passing through the defect, causing damage to the ossicular chain and facial nerve.¹¹ Additionally, its presence can be a conduit for the spread of infection or malignancy. Salivary gland fistula, although rare, may also occur through the foramen of Huschke, resulting in discharge into the external auditory canal.¹²

Supplementary material. The supplementary material for this article can be found at <https://doi.org/10.1017/S0022215124000136>.

Competing interests. None declared

References

- Hentzer E. Histologic studies of the normal mucosa in the middle ear, mastoid cavities and eustachian tube. *Ann Otol Rhinol Laryngol* 1970;**79**:825–33
- Applebaum EL, Kumar A, Berg LF, Mafee MF. Otologic complications following temporomandibular joint arthroscopy. *Ann Otol Rhinol Laryngol* 1988;**97**:675–9
- Heffez L, Anderson D, Mafee M. Developmental defects of the tympanic plate: case reports and review of the literature. *J Oral Maxillofac Surg* 1989;**47**:1336–40
- Hasani M, Haghnegahdar A, Khojastepour L, Golbahar Haghighi MJ. Determining the existence of the foramen of Huschke in patients with temporomandibular joint disorders using cone beam computed tomography: retrospective cohort study. *BMC Med Imaging* 2022;**22**:145
- Mittal S, Singal S, Mittal A, Singal R, Jindal G. Identification of foramen of Huschke with reversible herniation of temporomandibular joint soft tissue into the external auditory canal on multidetector computed tomography. *Proc (Bayl Univ Med Cent)* 2017;**30**:92–3
- Lacout A, Marsot-Dupuch K, Smoker WRK, Lasjaunias P. Foramen tympanicum, or foramen of Huschke: pathologic cases and anatomic CT study. *AJNR Am J Neuroradiol* 2005;**26**:1317–23
- Lim KH, Jung JY, Rhee J, Choi J. Temporomandibular joint herniation through the foramen of Huschke with clicking tinnitus. *Eur Ann Otorhinolaryngol Head Neck Dis* 2019;**136**:497–9
- Ryu KH, Baek HJ, Hur DG. Spontaneous temporomandibular joint herniation into the external auditory canal through a patent foramen of Huschke: a case report. *Ann Med Surg (Lond)* 2017;**18**:33–5
- Singh I, Jain A, Prasad P, Rajpurohit P. Spontaneous temporomandibular joint herniation: a rare case. *Oral Maxillofac Surg* 2017;**21**:87–90
- Park YH, Kim HJ, Park MH. Temporomandibular joint herniation into the external auditory canal. *Laryngoscope* 2010;**120**:2284–8
- Applebaum EL, Kumar A, Berg LF, Mafee MF. Otologic complications following temporomandibular joint arthroscopy. *Ann Otol Rhinol Laryngol* 1988;**97**:675–9
- Sharma PD, Dawkins RS. Patent foramen of Huschke and spontaneous salivary fistula. *J Laryngol Otol* 1984;**98**:83–5

Appendix 1. Supplementary video material

A short video showing an endoscopic view of a right-sided external auditory canal lesion increasing in size during a repeated Valsalva manoeuvre is available online at *The Journal of Laryngology & Otology* website, at https://nam12.safelinks.protection.outlook.com/?url=https%3A%2F%2F1drv.ms%2Fv%2Fs!As_rLPsUUfMc3C3AyAhQNkejD3MT&data=05%7C02%7Cmanoranjani.ramakumar%40novatechset.com%7C738a79b893d54fd5cf6a08dc5a0cc47f%7Ca03a7f6cfbc84b5fb16bf634dbe1a862%7C0%7C638484258126945534%7CUnknown%7CTWFpbGZsb3d8eyJWIjoiMC4wLjAwMDAiLCJQIjoiV2luMzIiLCJBTiI6IjEhaWwILCJXVCi6Mn0%3D%7C0%7C7C%7C&data=ry6kvZ4ieTRlFhClunuCGIDb3ZaMx%2Bw5jWp5W1ErJJE%3D&reserved=0.