

MOTTLED NAILS. AN EARLY SIGN OF FLUOROSIS

BY LEO SPIRA, M.D. (VIENNA), M.D. (PRAGUE), M.R.C.S., CAPTAIN R.A.M.C.

(With Plate 1, containing Figs. 1-12)

Signs and symptoms attributed to a disturbed function of the parathyroid glands as a result of the protracted action of small quantities of fluorine have been described elsewhere (Spira, 1942*c*). It was shown that the lesions on the teeth known as 'mottled enamel' were frequently accompanied by lesions on the skin and its appendages, the nails and hair. The object of the present communication is to give some details of the changes produced in the finger- and toe-nails in chronic fluorine poisoning (fluorosis).

In their most advanced form they are represented by onychia in varied degree. Pits of varying depth develop on the surfaces of one or more nails, in some cases accompanied by deformities resulting from the matrix being affected by co-existent paronychia and by a liquefying process involving the substance of the nail. The condition is very similar to onychomycosis, but a fungus has not been detected. When a fungus is present, the infection is probably of a secondary nature. Excoriations, rhagadae and deep fissures develop on the extensor aspect of the affected finger. Fig. 1 shows these lesions distinctly. In another case, well demonstrated in Fig. 2, onychia and paronychia were accompanied by cheiropompholyx. In all these affections, though pronounced, no fungus was found, and every method of local treatment, including X-rays and radium, applied for over a year, proved to be ineffective. Administration of an adsorbent and an aperient, on the other hand, cleared up the condition in the course of a few weeks.

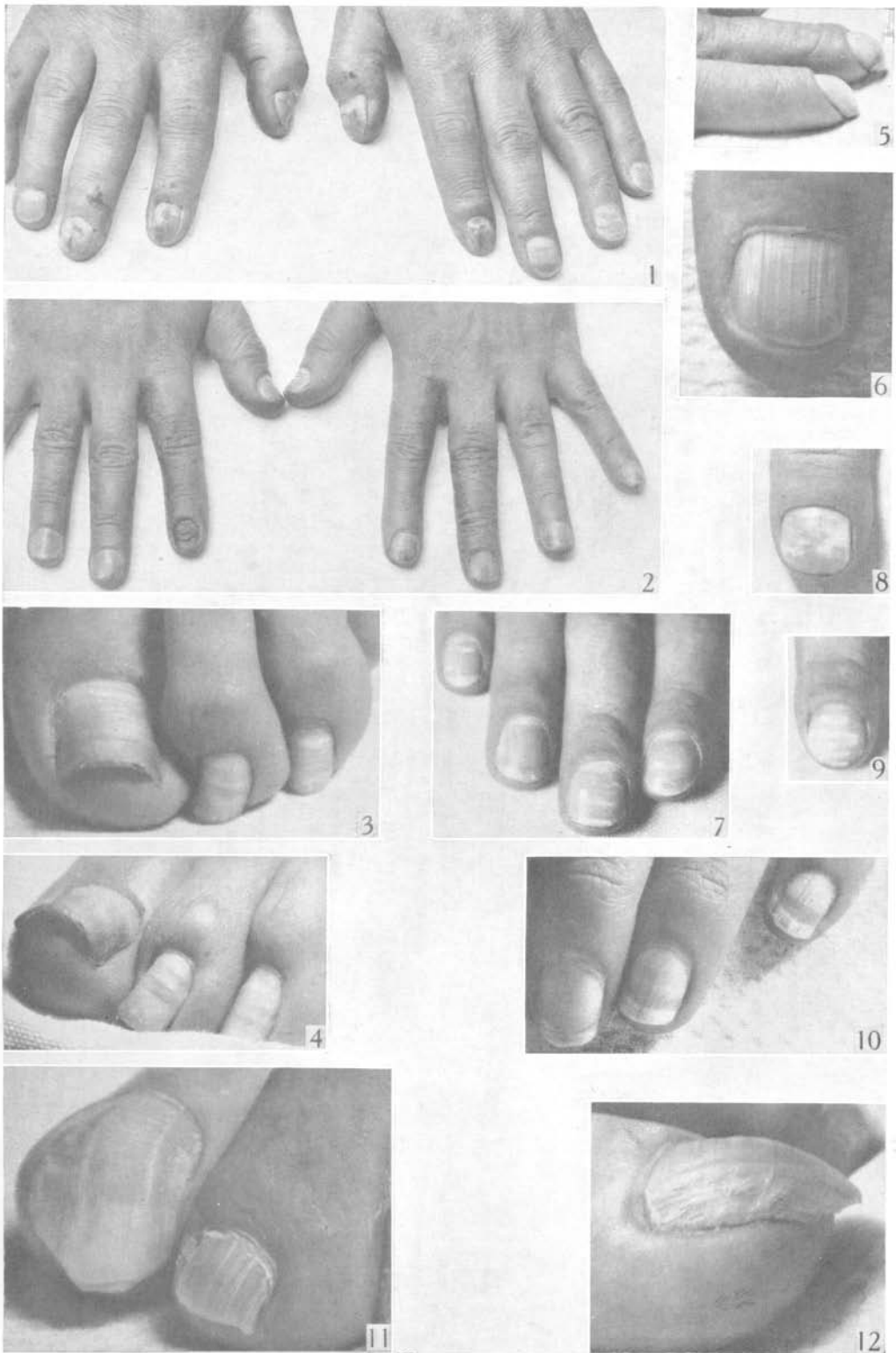
Such advanced changes of the nails are, however, comparatively rare. In the majority of cases the nails lose their lustre and appear opaque. They become so brittle that even a slight accidental knock on a hard object (e.g. a table) causes them to break in a transverse direction. Sometimes they are described as being so soft as to be easily torn at their free edges. They may tear in layers, as if their substance was laminated. Not infrequently transverse thickened elevations of varied width alternate with shallow depressions across the upper surface of the finger- and toe-nails, and give them a furrowed appearance (Figs. 3, 4 and 11). When allowed to grow beyond the finger-tips, the nails tend to curl round them in a claw-like manner (Figs. 5, 11 and 12). In a few instances a loosening of a toe-nail without the slightest warning, even to the extent of its being lifted out of its bed and falling off, has been encountered. When the degree of the dystrophy is milder still only a longitudinal striation is visible (Figs. 6, 10, 11 and 12), either through the longitudinal ridges having penetrated the whole thickness of the nail, or through their remaining limited to its under-surface where they originated. They can be easily felt as well as seen on a cut portion of such a nail. Most curious of all, dull, opaque, chalky-white specks, patches or transverse bands familiar to everybody, appear frequently in several nails (Figs. 1, 3, 4, 7, 8 and 9). Sometimes these bands are so wide as to replace a considerable part of the normal nails (Fig. 10). Toe-nails allowed to grow excessively tend to do so sideways, in a lateral direction, so that their long axis is at an angle with that of the toes (Figs. 3, 4 and 11). The transverse axis of such a toe-nail frequently shows an exaggerated

convexity (Figs. 3, 4). Toe-nails, especially those on the big toes, often show a permanent discoloration, the colour being a dull mixture of preponderantly dark grey and brown of variable intensity.

All these different changes are very similar to those seen on mottled teeth, which are thought to be the first, or at any rate one of the first, visible signs of fluorosis. As a matter of fact, an investigation of the prevalence of mottled teeth revealed that these two conditions, namely mottled teeth and the nail dystrophy, were frequently, though not invariably, co-existent. The one is in appearance so much like the other that it is suggested that, in analogy with the term 'mottled teeth', the corresponding changes in the nails be designated simply as 'mottled nails'. Their presence should be regarded as another early visible sign of fluorosis. Even when co-existent, the degree of mottling does not correspond to that of mottled teeth. Whereas, however, in mottled teeth the lesions are permanent, mottled nails will gradually regain their normal appearance when the appropriate treatment directed against fluorosis has been instituted and the ongrowing portion which was affected has been cut off. A recurrence of fluorosis will, on the other hand, inevitably be demonstrated by the reappearance of at least the longitudinal striation and the paper-white specks and transverse bands. Mottled nails thus represent in many cases a delicate test of the presence of fluorosis.

The appearance of the several forms of the nail dystrophies, as described in the present paper, was found to be so characteristic and of such frequent occurrence that a search for the literature on the subject promised to be fruitful. This literature has, in fact, proved to be extensive, and showed the problem of the nail dystrophies to be one that had occupied the minds of the medical profession for very many years, even as early as the end of the eighteenth century. No attempt, however, has previously been made to co-ordinate the unguis changes, and each of them had always been described separately as a distinct entity under a different name, thus considerably complicating the issue; onychiauxis and onychogryphosis representing hypertrophy, thickening, elongation and claw-shape of the nails with the subungual space filled with a greyish corneous accumulation; onycholysis and onychomadesis for the separation of the nail plate from its bed; leukonychia totalis, striata and punctata for the different degrees and shapes of the opaque, chalky-white specks, patches and transverse bands; onychorrhaxis for the longitudinal striation; 'Beau's lines' for the transverse furrows giving the affected nail a wavy appearance; and fragilitas unguium for the brittleness of the nails. These are some of the designations for the different forms of the onychodystrophies as described on many occasions in the literature in the past. Such changes, however, are identical with those included by me under the summary designation of 'mottled nails', a designation which should be regarded as representing a uniform group amongst the signs and symptoms caused by chronic fluorine poisoning. Just as 'mottled teeth' were shown by me to be frequently accompanied by changes in the nails, skin and hair, so did many descriptions given of the various onychopathies in the past connect them with changes in the teeth, skin and hair. It should be remembered that all these tissues are regulated by the parathyroid glands.

I wish to express my sincere gratitude to Captain E. D. Nisbet, R.A., for the help which he has given me in making the photographs Nos. 3-12.



REFERENCES

- PARDO-CASTELLO, V. (1941). *Diseases of the Nails*. Springfield, Illinois.
 SPIRA, L. (1928). *Franco-Brit. Med. Rev.* 5, 1, 61.
 SPIRA, L. (1933). *The Clinical Aspect of Chronic Poisoning by Aluminium and its Alloys*. London.
 SPIRA, L. (1942*a*). *Lancet*, 1, 649.
 SPIRA, L. (1942*b*). *Brit. Dent. J.* 73, 149.
 SPIRA, L. (1942*c*). *Edinb. Med. J.* 49, 707.
 SPIRA, L. & KOLCOAR, P. T. (1942). *Brit. Dent. J.* 73, 233.

EXPLANATION OF PLATE 1

- Fig. 1. Onychia of several nails, excoriations, rhagadae and fissures, some chalky-white specks.
 Fig. 2. Onychia of both index fingers. Paronychia on right index. Cheiropompholyx, especially on both middle fingers.
 Figs. 3, 4. Transverse elevations alternating with depressions give the nails a furrowed appearance. Exaggerated curvature of the big toe-nail. Some chalky-white specks. Transverse chalky-white bands across the toe-nails.
 Fig. 5. Nails curling round the finger-tips in a claw-like manner.
 Fig. 6. Pronounced longitudinal striation.
 Figs. 7, 8 and 9. Opaque, chalky-white specks, patches and transverse bands.
 Fig. 10. The proximal parts of the finger-nails are opaque and chalky-white. There is some longitudinal striation.
 Fig. 11. Longitudinal striation of the toe-nails. The nails tend to grow sideways and to curl round the tips of the toes.
 Fig. 12. The same big-toe nail as shown in Fig. 11, showing the longitudinal striation and claw-like appearance.

(*MS. received for publication 13. VIII. 42.—Ed.*)