

Case Study






Cite this article: Chakrabarti S, Kulshrestha A, Patel S, Kunikullaya S, and Sharma A. (2023) A rare case of Buschke–Lowenstein tumour of vulva treated with radical radiotherapy. *Journal of Radiotherapy in Practice*. **22**(e64), 1–3. doi: [10.1017/S1460396922000358](https://doi.org/10.1017/S1460396922000358)

Received: 15 June 2022
Revised: 1 September 2022
Accepted: 14 November 2022

Key words: Buschke–Lowenstein tumour; HIV; radiation therapy; vulva

Author for correspondence: Dr. Asmita Kulshrestha, Department of Radiation Oncology, Gujarat Cancer and Research Institute, Civil Hospital Campus, Asarwa, Ahmedabad 380016, Gujarat, India. Tel: 0091-9685994359. E-mail: asmi.kul@gmail.com

A rare case of Buschke–Lowenstein tumour of vulva treated with radical radiotherapy

Sutanuka Chakrabarti¹ , Asmita Kulshrestha¹ , Sonal Patel¹ ,
Suryanarayana Kunikullaya¹  and Ankit Sharma² 

¹Department of Radiation Oncology, Gujarat Cancer and Research Institute, Civil Hospital Campus, Asarwa, Ahmedabad 380016, Gujarat, India and ²Department of Surgical Oncology, Gujarat Cancer and Research Institute, Civil Hospital, Asarwa, Ahmedabad 380016, Gujarat, India

Abstract

Introduction: Buschke–Lowenstein tumour (BLT) is a rare verrucous lesion often associated with human papillomavirus infection. It is an indolent but locally aggressive lesion usually arising from the genitalia or anorectum, with a potential risk of recurrence and malignant transformation. The first line of management is surgical or laser excision. Topical agents cryotherapy, radiotherapy and chemo-immunomodulators are reserved for residual or recurrent cases and smaller lesions.

Methods: A 24-year-old female on antiretroviral therapy presented in our department with a large cauliflower-shaped growth involving the perineum, vulva and lower vagina. A biopsy of the lesion was suggestive of a BLT. Due to the extensive nature of the disease, surgery was deferred. The lesion was treated with definitive external beam radiation therapy (EBRT) using a 6-megavoltage photon beam on a Cobalt-60 unit.

Results: Radiotherapy resulted in a significant response without any acute toxicity, following which, topical podophyllin application was advised for the residual perianal lesion. The patient is disease free after 9 months of follow-up.

Conclusions: A multidisciplinary approach is important to treat the BLT. Lesions not amenable to surgery or local therapies can be treated with EBRT with reasonable control and acceptable toxicities.

Introduction

Buschke–Lowenstein tumour (BLT), also known as giant condyloma acuminatum (GCA) is a rare verrucous lesion. It is usually associated with low-risk human papillomavirus infection, types 6 or 11, and rarely with high-risk types.¹ The significant risk factors include immuno-compromised conditions such as human immunodeficiency virus infection, poor hygiene and sexual or perinatal transmission.² About 0.1% of the general population is affected, often adults in their forties, with a male-to-female ratio of 2.7:1.³

The primary method of treatment is surgical or laser excision. Other modalities, including cryotherapy, immunotherapy, chemotherapy and radiation therapy, are used as adjuvant treatment or when excision is morbid or contraindicated.⁴

Case Report

A 24-year-old female on antiretroviral therapy presented with a slow-growing painless mass over the vulva for 6 months. There was no history of discharge or bleeding per vagina or changes in bladder–bowel habits.

Examination under anaesthesia revealed an exophytic growth approximately 12 × 10 cm, involving the entire perineum. The mass extended into the lower 2 cm of the vagina involving the anterior and right lateral vaginal walls, both the urethral and anal openings, while sparing the rectal mucosa. The overlying skin was ulcerated and had blood-stained and malodorous discharge. Multiple bilateral inguinal nodes were palpable, the largest measuring approximately 2 × 1 cm in size on the right side (see Figure 1a).

A biopsy of the tumour revealed proliferative stratified squamous epithelium with parakeratosis and papillomatosis but no intraepithelial malignancy indicating a BLT (see Figure 1b).

Pelvic magnetic resonance imaging depicted a 3 × 7 × 9 cm altered signal intensity lesion in the perineum, lower part of the vagina and anal canal, along with a few necrotic bilateral inguinal lymph nodes, the largest measuring 2 × 1.5 cm on the right side (see Figure 2a and 2b).

Due to the extensive nature of the lesion, surgical resection was not feasible. Thus, the patient was advised definitive external beam radiation therapy (EBRT). The treatment plan and associated risks were explained to the patient and a written informed consent was taken.

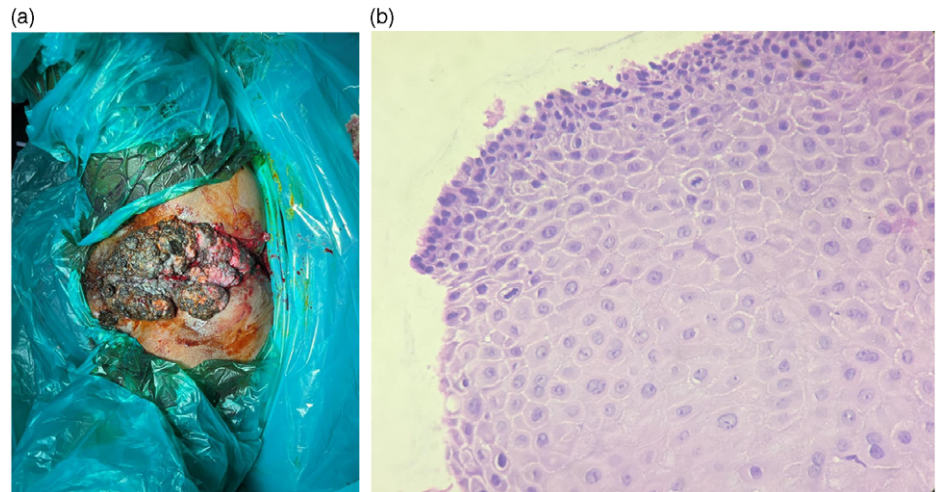


Figure 1. (a) An exophytic mass over vulva involving urethra, lower vagina and perianal region. (b) Histopathological examination reveals stratified squamous epithelium with parakeratosis.

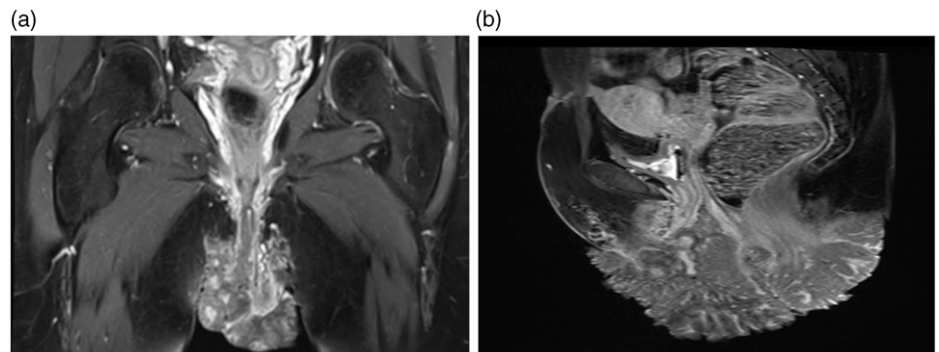


Figure 2. (a, b) Coronal and sagittal section of MRI showing massive exophytic lesion over vulva.

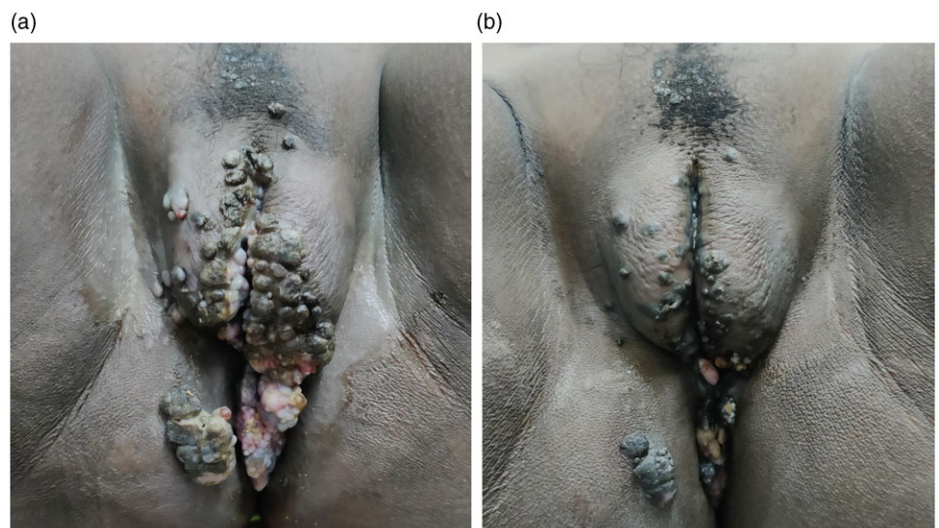


Figure 3. (a) Regression of growth after radiation therapy with 45 Gy in 25 fractions. (b) Minimal residual lesion following curative dose of radiation delivery.

EBRT was planned on the Cobalt-60 teletherapy unit using conventional X-ray-based simulation in a supine frog-leg position using 6 megavoltage photons. A curative dose of 45 Gray (Gy) in 25 fractions to the perineum covering the entire mass with a 15×12 cm X-Y field was delivered.

Assessment after 25 fractions resulted in a good clinical response with a reduction in size to approximately 6×5 cm; hence,

a boost of 10.8 Gy in 6 fractions was given by a small perineal field of 10×9 cm (see Figure 3a).

Upon the conclusion of radiation, the patient experienced a near complete response with a residual lesion approximately 2×1 cm (see Figure 3b). Topical podophyllin application was given for the residual lesion involving the perianal region. She is on 3 monthly follow-up. Nine months following

the conclusion of therapy, the patient is asymptomatic and disease free.

Discussion

BLT is uncommon at such a young age. Judge et al. reported the first case of an extensive GCA in a 50-year-old white female. Two case series of BLT in patients younger than 50 years have been documented to date.⁵

Sobrado et al. demonstrated an excellent response for vulvar BLT and giant perianal condylomas using an EBRT dose of 45 Gy at 1.8 Gy per fraction.⁶ A patient with urethral warts resistant to other forms of treatment was the first reported to use EBRT with 25 Gy using 2.5 Gy fractions for two and a half weeks.⁷

In this particular case, the patient received curative EBRT resulting in a favourable response with minimal skin toxicity. Close observation is essential due to a propensity for recurrence or malignant transformation. EBRT using photons is an effective alternative for treating resistant BLT lesions with acceptable outcomes, followed by local adjuvant therapies for residual lesions. The optimal dose and fractionation are not clearly defined in literature. Although earlier studies cautioned against radiotherapy for the risk of secondary malignant transformation, in recent literature, the use of EBRT has resulted in reasonable local control and significant downstaging of the disease.^{8,9}

Conclusion

BLTs not amenable to surgery or topical therapy can be offered radiotherapy with favourable outcomes. Patients need close observation to detect recurrence or malignant transformation. Further

studies with a larger number of patients and long-term follow-up are required.

Acknowledgements. None.

Financial Support. None.

Conflicts of Interest. None.

References

1. Aydogdu I, Uzun E, Mirapoglu S L et al. Buschke-Löwenstein tumour: three paediatric cases. *Pediatr Int.* 2016; 58(8): 769–772.
2. Purzycka-Bohdan D, Nowicki R J, Herms F, et al. The pathogenesis of giant condyloma acuminatum (Buschke-Lowenstein Tumor): an overview. *Int J Mol Sci.* 2022; 23(9): 4547.
3. Trombetta L J, Place R J. Giant condyloma acuminatum of the anorectum: trends in epidemiology and management: report of a case and review of the literature. *Dis Colon Rectum.* 2001; 44(12): 1878–1886.
4. Pennycook K B, McCready T A. Condyloma acuminata. In: *StatPearls.* Treasure Island, FL: StatPearls Publishing, 2022: 1–15.
5. Chu Q D, Vezeridis M P, Libbey N P, et al. Giant condyloma acuminatum (Buschke-Lowenstein tumour) of the anorectal and perianal regions. Analysis of 42 cases. *Dis Colon Rectum.* 1994; 37(9): 950–957.
6. Creasman C, Haas P A, Fox T A Jr, et al. Malignant transformation of anorectal giant condyloma acuminatum (Buschke-Loewenstein tumour). *Dis Colon Rectum.* 1989; 32(6): 481–487.
7. Sobrado C V V, Mester M, Nadalin V V, et al. Radiation-induced total regression of a highly recurrent giant perianal condyloma: report of a case. *Dis Colon Rectum.* 2000; 43(2): 257–260.
8. White R, Donnellan S, Leong T. Complete resolution of urinary bladder condyloma acuminatum following definitive chemoradiotherapy for anal cancer. *BJU Int.* 2011; 108(Suppl 2): 38–41.
9. Danoff D, Holden S, Thompson R W, et al. New treatment for extensive condylomata acuminata: external radiation therapy. *J Urol.* 1981; 18(1): 47–49.