

LETTER TO THE EDITOR

TO THE EDITOR

Goodpasture's Syndrome Following Alemtuzumab Therapy in Multiple Sclerosis

Keywords: Multiple sclerosis, Immunology, Patient safety

Alemtuzumab, a humanised anti-CD52 monoclonal antibody, is a potent disease-modifying therapy used in the treatment of relapsing-remitting multiple sclerosis (RRMS).¹ Secondary autoimmune disorders have been reported following treatment, thyroid disease being the most common.¹ There have been few reports of alemtuzumab-induced renal disease. Three cases of membranous glomerulonephritis, one of which also had weak positive anti-glomerular basement membrane (GBM) antibodies, and five cases of anti-GBM disease have been described.²⁻⁵ In all five, anti-GBM disease was renal limited with no reports of pulmonary involvement or Goodpasture's syndrome.

Here we report the first case of anti-GBM disease presenting as Goodpasture's syndrome 3 months after the second course of alemtuzumab for treatment of RRMS.

A 37 year-old Caucasian man, active smoker, with active RRMS of 8 years duration previously treated with interferon beta-1a received two courses of alemtuzumab for a cumulative dose of 96 mg. Results of follow-up routine investigations including creatinine and urinalysis were normal up to 3 months after completion of the second cycle (Figure 1).

Twenty-two days after the last renal function testing, he developed low-grade fever, anorexia, nausea, and vomiting. He noted one episode of gross hematuria and became abruptly oligoanuric. He presented to his local hospital 3 days after onset of symptoms with acute kidney injury and creatinine of 579 $\mu\text{mol/L}$. Urinalysis showed haemoglobinuria, proteinuria ($\geq 5 \text{ g/L}$), and no casts. He was started on dialysis within 48 hours of admission and developed frank hemoptysis with CT findings suggestive of limited pulmonary haemorrhage (Figure 2). Anti-GBM antibodies came back highly positive (>112 European Units). Anti-neutrophil cytoplasmic antibodies were negative. The patient was treated with high-dose corticosteroids, plasma exchange, and oral cyclophosphamide.

Renal biopsy showed haemorrhagic infarction of the cortex with no viable glomeruli and mixed inflammatory infiltration in the interstitium. Immunofluorescence revealed tubular basement membrane staining for IgG, C3, and kappa light chain (Figure 3). Despite the non-confirmatory biopsy, Goodpasture's syndrome was considered the most probable diagnosis given the clinical presentation and high anti-GBM antibody titer. While the pulmonary haemorrhage resolved, there is still no renal recovery 9 months after diagnosis.

Anti-GBM disease is a rare autoimmune disorder mediated by autoantibodies against an antigen of type IV collagen expressed on the glomerular and alveolar basement membranes.⁶ It accounts for about 20% of all cases of rapidly progressive glomerulonephritis.⁶ The majority of patients present with concurrent pulmonary alveolar haemorrhage, eponymously referred to as Goodpasture's syndrome,⁶

although this is the first reported case with pulmonary involvement following alemtuzumab therapy in multiple sclerosis (MS) (Table 1). The progression of symptoms was unusually rapid in this case in comparison to the previously reported cases of anti-GBM disease following alemtuzumab therapy²⁻⁵ and to the known evolution of Goodpasture's syndrome. In a retrospective analysis of 28 patients with Goodpasture's syndrome, only 4% of the patients had developed acute onset of symptoms in the week preceding admission, whereas in up to 39% the symptoms had evolved over a month.⁷ Oligoanuria, creatinine $>500 \mu\text{mol/L}$ and immediate dialysis requirement at diagnosis, as in the present case, are strong predictors of long-term dialysis dependence.^{6,8} Recovery is generally variable in anti-GBM disease.^{6,8} Although few cases have been reported, permanent kidney injury has occurred in alemtuzumab treated MS patients who develop this complication with three of the five previously reported cases having evolved to chronic dialysis or transplant.²⁻⁵

Secondary autoimmune events occurrence is delayed following alemtuzumab therapy.⁹ The most frequent autoimmune adverse event is thyroid disease, affecting 42% of the MS patients treated with alemtuzumab in the phase 3 studies through year 6.¹⁰ Thyroid events peak in year 3, with the most frequent being hyperthyroidism, including Grave's disease.¹⁰ Immune thrombocytopenia is the second most frequent autoimmune adverse event, with an incidence of 2.3% in the alemtuzumab clinical development program.¹⁰ It also has a delayed occurrence with a mean timing of onset from the last alemtuzumab course of 17 months.¹⁰ Anti-GBM disease was diagnosed between 10 and 39 months after the last course of alemtuzumab in the previously reported MS cases, consistent with the timing of onset in this case.²⁻⁵ The mechanisms underlying the development of alemtuzumab-induced autoimmunity are not well understood.⁹ Both B-cells and T-cells are involved in the pathophysiology of anti-GBM disease or Goodpasture's syndrome,⁶ and T and B cell reconstitutions after depletion by alemtuzumab have been postulated to drive secondary autoimmunity.⁹ B-cells repopulate rapidly relative to T-cells and thus do so in the absence of regulation from T-cells, which could lead to the development of antibody-mediated autoimmune conditions such as Goodpasture's syndrome.⁹ MS and other autoimmune disorders can co-occur, and at least one case of anti-GBM disease has been described in an untreated MS patient.³ Some MS patients could have enhanced genetic susceptibility to anti-GBM disease, as the HLA-DRB*1501 allele has been associated with both conditions.⁶ In addition, this patient had a first-degree relative with myasthenia gravis with antibodies to Muscle-Specific Kinase (MuSK) and he was an active smoker. A family history of autoimmune disease and current or past smoker status has both been identified as risk factors for secondary immunity in alemtuzumab treated MS patients, with odds ratio of 7.31 and 3.05, respectively.¹ Smoking also increases the likelihood of pulmonary involvement in Goodpasture's syndrome and might have prompted the occurrence of lung haemorrhage in this case.⁶

In summary, this case reflects the potential for extremely rapid progression and unfavourable outcome of Goodpasture's syndrome developing after treatment with alemtuzumab in MS. It highlights the importance of periodic monitoring of creatinine and urinalysis following treatment, especially in light of the non-specific clinical

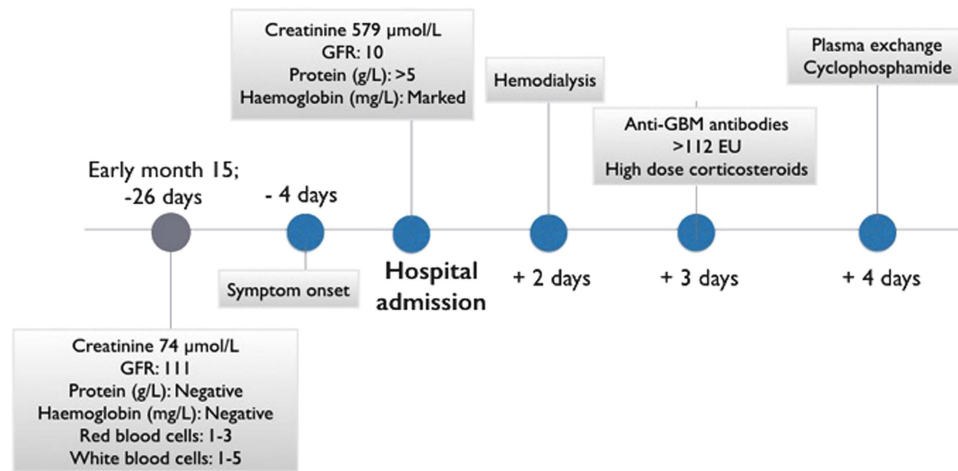


Figure 1: Clinical evolution. Timeline of the evolution of the case depicting the main events from the last normal routine monitoring, including symptoms onset, hospital admission and management. Rapid progression from symptoms onset can be appreciated.

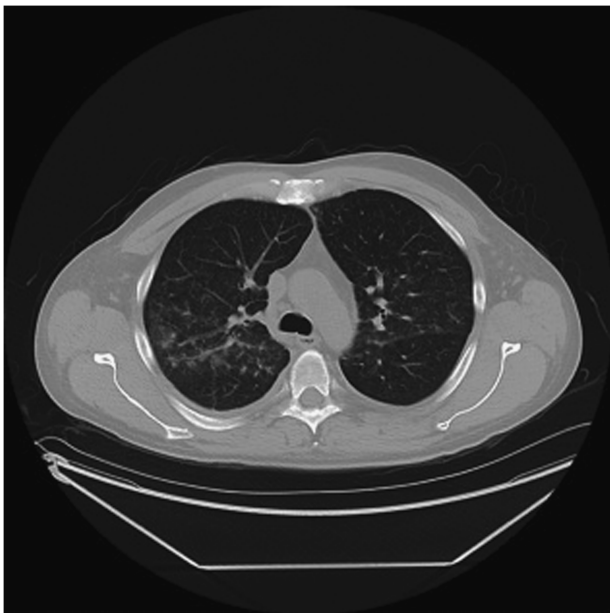

Figure 2: CT of the chest. An area of limited pulmonary hemorrhage is observed in the right middle and upper lung zones.

presentation which may delay the treatment to preserve renal function.⁶ Baseline testing of anti-GBM levels is of unclear predictive value as these autoantibodies may exist in asymptomatic carriers.⁶ However, a high index of suspicion should be maintained for every alemtuzumab treated MS patient, and creatinine and urinalysis disturbances should be monitored closely with early referral to nephrology and anti-GBM testing. Caution should be exercised when prescribing alemtuzumab to active smokers and patients with a family history of autoimmune disorders who may be at increased risk of secondary autoimmunity.

ACKNOWLEDGEMENT

The authors would like to acknowledge Dr Alexander Magil, renal pathologist at St-Paul's Hospital, University of British Columbia, Canada, for providing pictures of the kidney biopsy.

STATEMENT OF AUTHORSHIP

Each author has been involved in the case management, preparation, and revision of the manuscript.

DISCLOSURES

EL has received consulting fees from EMD Serono, Biogen, and Hoffmann La Roche, as well as speaker fees from Genzyme and

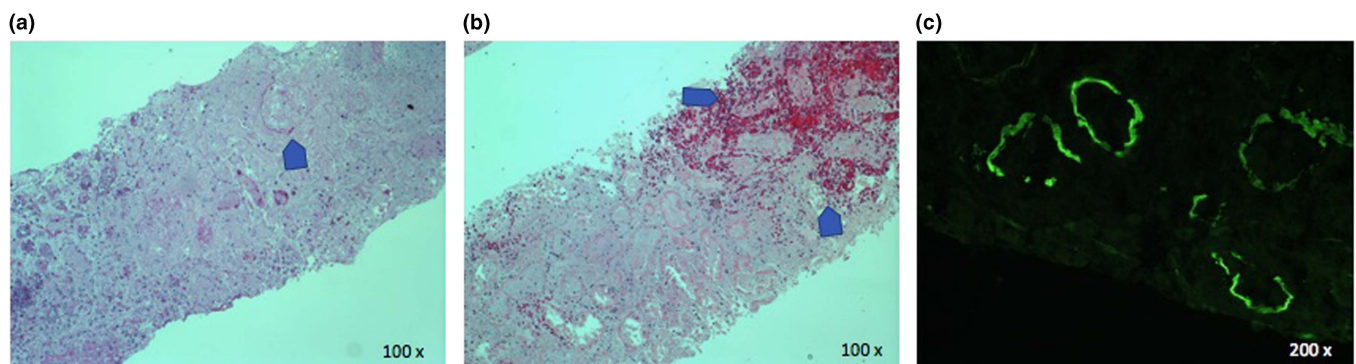


Figure 3: Renal biopsy. H&E stains show complete loss of glomerular architecture (panel a) and infarction and hemorrhage (panel b). Direct immunofluorescence shows linear tubular basement membrane staining for IgG (panel C).

Table 1: Summary of previously reported cases of anti-glomerular basement membrane disease following alemtuzumab therapy in multiple sclerosis

	Case 1 ^{3,4}	Case 2 ^{3,4}	Case 3 ^{2,4}	Case 4 ⁴	Case 5 ⁵	Actual case
Age, years	40	35	35	24	Unknown	37
Gender	Female	Female	Female	Female	Unknown	Male
Timing of occurrence (after last course)	10 months	24 months	39 months	48 months	Unknown	3 months
Rapidity of onset	Antibodies not detected 1 month before onset	Unknown	Creatinine increased over ≥ 1 month	Not rapid, deteriorated due to non-compliance	Asymptomatic	Very rapid (Figure 1)
Smoker status	Unknown					Smoker
Lung involvement	No lung involvement reported					Yes

EMD Serono. BM and PN have no disclosures. KB has received compensation for consultation and a travel grant from Sanofi Genzyme Canada. ALT reports grants from MS Society of Canada, grants and personal fees from Biogen, Sanofi Genzyme, Chugai, Teva and Roche.

Emmanuelle Lapointe

Division of Neurology, Faculty of Medicine, University of British Columbia, Vancouver, British Columbia, Canada

Bahar Moghaddam

Internal Medicine, University of British Columbia, Vancouver, British Columbia, Canada

Krista Barclay

Neurology, Djavad Mowafaghian Center for Brain Health, Vancouver, British Columbia, Canada

Anthony L. Traboulsee

Division of Neurology, Faculty of Medicine, University of British Columbia, Vancouver, British Columbia, Canada

Peter Neufeld

Department of Medicine, Division of Nephrology, University of British Columbia, Vancouver, British Columbia, Canada

Correspondence to: E. Lapointe, Division of Neurology, Faculty of Medicine, University of British Columbia,

2211 Wesbrook Mall, Vancouver, British Columbia, Canada V6T 2B5.

Email: Emmanuelle.lapointe@usherbrooke.ca

REFERENCES

- Cosburn M, Pace AA, Jones J, et al. Autoimmune disease after alemtuzumab treatment for multiple sclerosis in a multicenter cohort. *Neurology*. 2011;77(6):573-79.
- Meyer D, Coles A, Oyuela P, et al. Case report of anti-glomerular basement membrane disease following alemtuzumab treatment of relapsing-remitting multiple sclerosis. *Mult Scler Relat Disord*. 2013;2(1):60-3.
- Coles AJ, Cox A, Le Page E, et al. The window of therapeutic opportunity in multiple sclerosis: evidence from monoclonal antibody therapy. *J Neurol*. 2006;253(1):98-108.
- Phelps R. Autoimmune events: nephropathies. *Scientific exchange forum* 2013.
- Singer BA, Alroughani R, Brassat D, et al. Durable improvements in clinical outcomes with alemtuzumab in patients with active RRMS in the absence of continuous treatment: 7-year follow-up of CARE-MS II patients (TOPAZ study). Poster 736. 7th joint ACTRIMS-ECTRIMS meeting, Paris. 2017.
- Peto P, Salama AD. Update on antiglomerular basement membrane disease. *Curr Opin Rheumatol*. 2011;23(1):32-7.
- Lazor R, Bigay-Game L, Cottin V, et al. Alveolar hemorrhage in anti-basement membrane antibody disease: a series of 28 cases. *Medicine (Baltimore)*. 2007;86(3):181-93.
- Alchi B, Griffiths M, Sivalingam M, et al. Predictors of renal and patient outcomes in anti-GBM disease: clinicopathologic analysis of a two-centre cohort. *Nephrol Dial Transplant*. 2015;30(5):814-21.
- Baker D, Herrod SS, Alvarez-Gonzalez C, et al. Interpreting lymphocyte reconstitution data from the pivotal phase 3 trials of alemtuzumab. *JAMA Neurol*. 2017;74(8):961-69.
- Devonshire V, Phillips R, Wass H, et al. Monitoring and management of autoimmunity in multiple sclerosis patients treated with alemtuzumab: practical recommendations. *J Neurol* 2018 [Epub ahead of print].