

## Letter to the Editor: New Observation

# Safety of Tocilizumab in the Treatment of COVID-19-Related Longitudinally Extensive Transverse Myelitis

Leslie A. Scarffe, Tychicus Chen  and Anthony L. Traboulsee 

Division of Neurology, Department of Medicine, University of British Columbia, Vancouver, Canada

**Keywords:** CNS inflammation; infectious diseases; neuroinfectious disease; spinal cord

Coronavirus disease 2019 (COVID-19)'s primary manifestation is a severe acute respiratory syndrome. COVID-19 has been associated with rare cases of transverse myelitis (reviewed in).<sup>1–3</sup> Recovery has often been incomplete despite early treatment with immunotherapy.<sup>2,3</sup> Here, we report the safety of tocilizumab in the treatment of COVID-19-associated longitudinally extensive transverse myelitis (LETM) in a patient with active COVID-19 symptoms.

A 41-year-old unvaccinated type 1 diabetic male with no prior neurologic history was diagnosed with COVID-19 within 24 hours after resolution of a hyperosmolar hyperglycemic nonketotic event. Initially, he had no neurologic complaints. By 24–48h after admission to hospital, he developed worsening shortness of breath and paresthesias in his arms, rapidly spreading to his chest, torso, and legs. Within 24 hours, he had a flaccid incomplete quadriplegia. He had Medical Research Council (MRC) grade 1–2/5 strength proximally in the arms, worse right than left, 0–1/5 distally in the fingers, and 0/5 in the legs. He also developed a thoracic sensory level, fluctuating hypotension, and urinary retention requiring catheterization. Magnetic resonance imaging (MRI) demonstrated T2 hyperintensity from the cervical medullary junction to T4 with cord swelling and mild punctate enhancement (Fig. 1a–e). Brain MRI was normal. Cerebrospinal fluid (CSF) revealed a neutrophilic pleocytosis (73 WBCs) and elevated protein (1.36g/L). Both serum and CSF were negative for anti-aquaporin 4 and for myelin oligodendrocyte autoantibodies (cell-based assay), and a paraneoplastic antibody panel was negative in both serum and CSF (Mitogen Labs, Calgary, Canada). Anti-nuclear antibody, anti-double stranded DNA, and antineutrophil cytoplasmic antibodies were negative (in serum). CSF angiotensin-converting enzyme was negative. Acid-fast bacillus (CSF), syphilis (serum and CSF), and HIV and HTLV (serum) testing were negative.

Three days after development of neurological symptoms (day 5 of his admission), he was intubated for concerns of rapidly progressive weakness and respiratory failure. Four days after intubation (day 9 of admission), he had increasing oxygen needs and CT chest showed multifocal consolidation, atelectasis, as

well as signs of barotrauma potentially compatible with complications of COVID-19 acute respiratory distress syndrome. He had laboratory findings suggestive of severe COVID-19 pneumonia including leukocytosis with increased neutrophil-to-lymphocyte ratio, elevated CRP, and elevated D-dimer (Table 1).

On day 5 from admission to hospital, a course of 1000mg of intravenous methylprednisolone daily was started for 5 days, with no immediate neurologic improvement. On day 10, he received tocilizumab 600 mg IV (approximately 8mg/kg) for severe COVID-19 but also because tocilizumab has evidence in treating spinal cord inflammation in neuromyelitis optica (NMO).<sup>7</sup> Over the next days, oxygen requirements decreased and laboratory markers partially normalized (Table 1, Figure 1f). He regained near full strength in both arms, (MRC 4/5 in left shoulder abduction and bilateral wrist extension, otherwise MRC 5/5) while his legs remained flaccid (MRC 0/5) at three weeks after LETM onset. Further treatment with five sessions of plasmapheresis (PLEX) initiated 2 weeks after treatment with tocilizumab yielded minimal improvement. Three weeks after onset (and prior to initiation of PLEX), repeat MRI showed partial improvement of LETM. Repeat lumbar puncture at this time showed resolution of pleocytosis, persistently elevated protein (1.79g/L), and was negative for oligoclonal banding. CSF nucleic acid amplification test was negative for SARS-CoV-2 at this time.

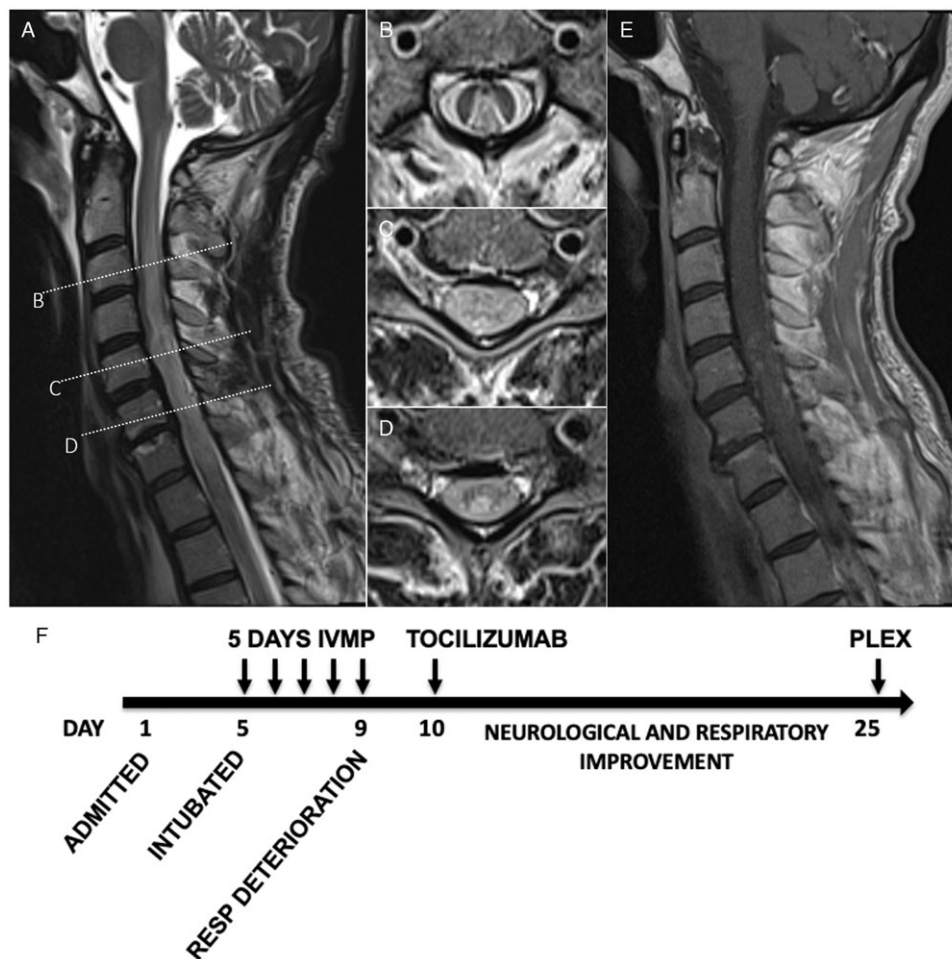
He did not receive any further immunotherapy given his negative testing for anti-aquaporin 4 and myelin oligodendrocyte autoantibodies. Repeat MRI spine was done at 3 months, which showed slight interval improvement of the extensive high T2/proton density signal with cord atrophy from C5–C7. At follow-up about a year from his presentation, he was neurologically unchanged. He continued to have complete paraplegia with a thoracic sensory level and remained urinary catheter dependent. He had not had any further relapses. Imaging was not repeated given his stable course.

About 45 cases of transverse myelitis associated with COVID-19 have been published (reviewed in),<sup>1–3</sup> most cases LETM. Most cases of transverse myelitis occur 2 days to a few weeks after the

**Corresponding author:** T. Chen; Email: [tychicus@mail.ubc.ca](mailto:tychicus@mail.ubc.ca)

**Cite this article:** Scarffe LA, Chen T, and Traboulsee AL. Safety of Tocilizumab in the Treatment of COVID-19-Related Longitudinally Extensive Transverse Myelitis. *The Canadian Journal of Neurological Sciences*, <https://doi.org/10.1017/cjn.2023.244>

© The Author(s), 2023. Published by Cambridge University Press on behalf of Canadian Neurological Sciences Federation. This is an Open Access article, distributed under the terms of the Creative Commons Attribution licence (<http://creativecommons.org/licenses/by/4.0/>), which permits unrestricted re-use, distribution and reproduction, provided the original article is properly cited.



**Figure 1:** (a-e) MRI cervical spine, T2-weighted (A) sagittal and (b-d) axial views demonstrating extensive hyperintensity spanning the medulla to the mid-thoracic cord, with preferential central and dorsal aspects and expansile cord edema maximal at the C4-5 and C6-7 levels; (e) T1-weighted sagittal post-gadolinium shows multifocal areas of punctate enhancement. (f) Timing of immunotherapy relative to days since admission to hospital. IVMP = intravenous methylprednisolone, RESP = respiratory.

onset of COVID-19 symptoms, but there are also a few cases where COVID-19 infection and myelitis present concurrently (reviewed in).<sup>1</sup> SARS-CoV-2 has been undetectable in the CSF in nearly all cases of COVID-19-associated transverse myelitis.<sup>1,2</sup> SARS-CoV-2 was not detected in the CSF of our patient (though testing was done nearly three weeks after our patient's first positive COVID-19 test, limiting interpretation of this result). The lack of detectable SARS-CoV-2 in the CSF suggests that direct CNS invasion is unlikely to be the mechanism of COVID-19-associated myelitis. COVID-19 infection has been found to cause a cytokine storm-like condition associated with severe respiratory symptoms.<sup>4</sup> Many of the published cases of COVID-19-associated transverse myelitis are associated with only mild COVID-19 symptoms and without laboratory findings of severe COVID-19,<sup>2</sup> and so a cytokine storm is unlikely to be required for the development of myelitis. A postinfectious or inflammatory mechanism remains a plausible etiology for COVID-19-associated myelitis. Histopathology from a single case of acute necrotizing myelitis associated with COVID-19 seems to support this, showing gliosis as well as some infiltration by macrophages

and lymphocytes, without evidence of active viral infection.<sup>2</sup> There does not appear to be any reported association between hyperglycemic hyperosmolar state and LETM.

Many of the published cases of COVID-19-associated myelitis have incomplete recovery, suggesting a poor prognosis, despite the rapid initiation of anti-inflammatory treatments.<sup>2,3</sup> In the presence of an active infection, the possibility of suppressing the immune response that is attempting to limit viral spread may be a consideration when selecting a therapy. Published cases of COVID-19 myelitis have employed steroids (typically pulse steroids and sometimes also steroid tapers) and, in some cases, PLEX or intravenous immunoglobulin with mixed results.<sup>2</sup> There is a single case report of rituximab being used to treat COVID-19-associated myelitis in a patient otherwise asymptomatic from COVID-19,<sup>5</sup> a case report in which infliximab was used<sup>6</sup> and, most recently, a case in which cyclophosphamide and eculizumab were used<sup>2</sup> with mixed results. Tocilizumab blocks the IL-6 receptor and is an effective treatment to prevent relapses in NMO spectrum disorder and may be beneficial in the acute treatment of relapses.<sup>7</sup> Tocilizumab has been shown to be beneficial in severe COVID-19,

**Table 1:** COVID-19 testing and serum markers of severe COVID-19

	Day 1	Day 4	Day 9	Day 10	Day 11	Day 12	Day 13	Day 14	Day 15	Day 16	Day 17	Day 18	Day 19	Day 20	Day 21	Day 22	Day 23	Reference
CRP (mg/L)	1.07	4.61	6.6	14.5	120	71	35.2	19.5	12.7	6.7	4.2	3.3	2.4	1.4	1.5	1.6	1.2	< 5
Ferritin (ug/L)	59	53		33	62	81	62	56	46	48	52	46	38	37	32	39	37	15–300
D-Dimer (ug/L)			1389	1763	1711	1700	3284	2419	2207	4865	3733	2406	3966	4853	4676	2016	2377	< 500
Neutrophil (X10 <sup>9</sup> /L)	14.1	25.9	11.8															2–8
Lymphocytes (X10 <sup>9</sup> /L)	2.3	1.7	0.8															1.2–3.5
N:L ratio	6	15	15															
Nasopharyngeal swab (NAT)	+		-					+										-
Tracheal aspirate (NAT)			+					+							-			-
CSF (NAT) <sup>a</sup>																		-

CRP=C-reactive protein; NAT=nucleic acid testing; red font=abnormal result.

decreasing the composite risk of requiring invasive ventilation or dying in patients requiring supplemental oxygen,<sup>8</sup> making tocilizumab an attractive therapeutic option for treatment of COVID-19 myelitis. We do note that the ideal timing of PLEX after tocilizumab is unknown. In our report, PLEX was delayed to 2 weeks after tocilizumab treatment to avoid removing tocilizumab from circulation before it had taken maximal effect and while our patient was still at risk of severe COVID-19.

While multiple case reports have been published of patients with COVID-19-associated transverse myelitis, longitudinal follow-up for these patients is lacking. The patient described here continued to have severe neurological deficits but has not had any further neurological relapses without further immunosuppressive therapy. At the time of his last follow-up, he was about a year from onset of symptoms with no clinical relapse, suggesting that COVID-19-associated transverse myelitis may be a monophasic illness. Longer longitudinal follow-ups of patients with COVID-19-associated myelitis will be important to further elucidate their course.

This is, to our knowledge, the first report of the treatment of COVID-19-associated myelitis with tocilizumab. Our patient showed gradual improvement of hypoxemia and inflammatory biochemical markers as well as neurologic improvement from an incomplete flaccid quadriplegia, with significant motor and sensory recovery in his arms. Unfortunately, he remains paraplegic with minimal leg function. Given the severe neurological disability reported in many of these cases, further studies are warranted to clarify the relationship between COVID-19 and transverse myelitis, possible mechanism of neuroinflammation, and most appropriate therapies for COVID-19-associated myelitis.

**Acknowledgments.** The authors wish to thank the patient for permission to publish this case report.

**Competing Interests.** LAS reports no disclosures relevant to this manuscript; TC reports no disclosures relevant to this manuscript; AT has received

honorarium and/or grant support from Roche, Sanofi Genzyme, Biogen, EMD Serono not related to this work.

**Statement of Authorship.** LAS contributed to drafting/revision of the manuscript for content, including medical writing for content, major role in the acquisition of data, study concept or design, and analysis or interpretation of data. TC contributed to drafting/revision of the manuscript for content, including medical writing for content, major role in the acquisition of data, study concept or design, and analysis or interpretation of data. AT contributed to drafting/revision of the manuscript for content, including medical writing for content, major role in the acquisition of data, study concept or design, and analysis or interpretation of data.

## References

- Roman GC, Gracia F, Torres A, Palacios A, Gracia K, Harris D. Acute transverse myelitis (ATM): Clinical review of 43 Patients with COVID-19-associated ATM and 3 Post-vaccination ATM serious adverse events with the ChAdOx1 nCoV-19 vaccine (AZD1222). *Front Immunol.* 2021;12:653786.
- Guada L, Cabrero FR, Baldwin NL, Levi AD, Gultekin SH, Verma A. Acute ascending necrotizing myelitis after COVID-19 infection: A clinicopathologic report. *Neurol Clin Pract.* 2022;12:e28–e32.
- Schulte EC, Hauer L, Kunz AB, Sellner J. Systematic review of cases of acute myelitis in individuals with COVID-19. *Eur J Neurol.* 2021;28:3230–44.
- Mehta P, McAuley DF, Brown M, et al. COVID-19: consider cytokine storm syndromes and immunosuppression. *Lancet.* 2020;395:1033–4.
- Kaur H, Mason JA, Bajracharya M, et al. Transverse myelitis in a child with COVID-19. *Pediatr Neurol.* 2020;112:5–6.
- Pourmoghaddas Z, Sadeghizadeh A, Tara SZ, et al. Longitudinally extensive transverse myelitis as a sign of multisystem inflammatory syndrome following COVID-19 infection: A pediatric case report. *J Neuroimmunol.* 2021;360:577704.
- Du C, Zeng P, Han JR, et al. Early initiation of tocilizumab treatment against moderate-to-severe myelitis in neuromyelitis optica spectrum disorder. *Front Immunol.* 2021;12:660230.
- Group RC. Tocilizumab in patients admitted to hospital with COVID-19 (RECOVERY): A randomised, controlled, open-label, platform trial. *Lancet.* 2021;397:1637–45.