

ACTION OF CARCINOGENIC TAR UPON LYMPH GLANDS

By A. LASNITZKI

From the Cancer Research Department, University of Manchester

(With Plate XIII)

IN connexion with certain investigations, in the course of which carcinogenic tar was introduced into the animal body, a structural change in lymph glands was observed, which may be of interest. Tar B/19, which is a fraction derived from a pinene synthetic tar and had proved to be highly carcinogenic for the skin of mice (Twort & Fulton, 1930), was diluted with olive oil in the proportion of 1 in 10 by weight. The diluted tar was injected under the skin of the right flank of rats having, usually, a body weight between 150 and 200 g. As a rule 0.5 c.c. was injected every second week, the total number of injections into one animal being, usually, four or five. The tar was not well tolerated. The animals lost weight more or less quickly, and those not killed finally died. Spontaneous death, as a rule, took place about 5-10 weeks after the first injection. Other rats of a similar body weight, without injection or with injection of olive oil alone, served as controls.

It was found that the lymph glands of the animals injected with tar had undergone certain changes with regard to their colour, no striking changes being observed among other organs, apart from a fatty infiltration of the liver. While the lymph glands of the control rats, both non-injected and injected with olive oil, were almost entirely of a light yellowish colour, a certain number of the lymph glands of the tarred rats showed, to a more or less great extent, a colour varying from light to dark red-brown. The change was observed in the submaxillary, axillary, inguinal, thoracic and abdominal glands, although frequently not to the same extent in all situations. It was, on the whole, less pronounced when the animal was still in fairly good condition, when often only part of the surface of certain glands was slightly discoloured.

Microscopical examination of these glands showed that the red-brown colour was mainly due to the presence of red blood corpuscles in the tissue. Broadly speaking, the corpuscles were either aggregated focally, with an apparent preference for the neighbourhood of the surface, or they were more disseminated throughout nearly the whole of the organ. In either case the normal cellular constituents at the relevant parts were, more or less, reduced in number, this reduction being especially great when the blood was localized. The lymph glands of control rats, in general, contained hardly any extravascular red blood corpuscles. Thus it is concluded that, under the influence

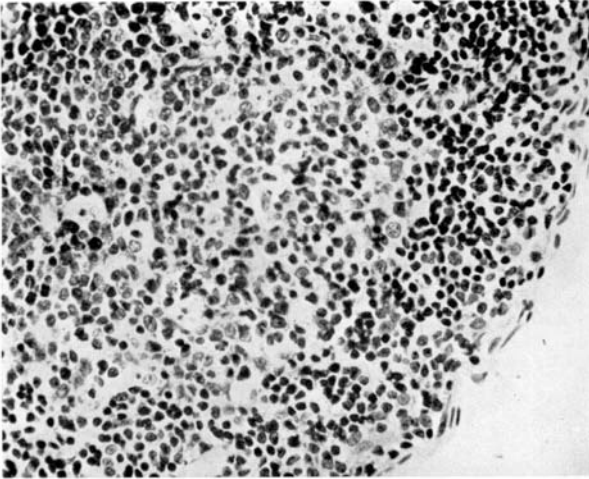


Fig. 1. Part of a submaxillary lymph gland from a control rat.
Haematoxylin and eosin. ($\times 300$.)

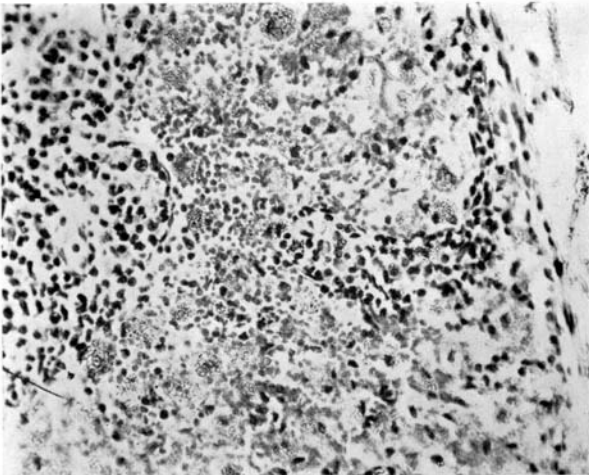


Fig. 2. Part of a submaxillary lymph gland from a tarred rat.
Haematoxylin and eosin. ($\times 300$.)

of the tar, a structural change had taken place, ordinary lymph glands being converted into more or less pronounced haemolymph glands.

Among the cells accompanying the red blood corpuscles a particular type of cells must be mentioned. They were isolated, relatively large cells, frequently showing a faintly stained nucleus, and containing a yellow-brown pigment, usually in great quantity. Apparently these cells were normal tissue cells which had undergone certain proliferation (? macrophages).

In Fig. 1 is shown the structure of a submaxillary lymph gland, taken from an animal which had received, within a period of 74 days, six injections, each of 0.45 c.c. of olive oil. It depicts the greater part of a surface follicle consisting of densely arranged cells of different types. The more peripherally arranged lymphocytes, with their compact nuclei, are particularly to be noted. Fig. 2 shows part of a submaxillary lymph gland, taken from an animal which had received, within a period of 44 days, four injections, each of 0.5 c.c. of the diluted tar. Likewise, it is the surface region of the gland. It will be seen that, towards the surface, the normal cellular constituents have to a great extent disappeared. Their place is taken chiefly by red blood corpuscles, which can be recognized as distinct small spots, especially in the deeper parts. When examined closely, the photograph also shows a fair number of the large, pigmented cells mentioned above. They are mostly within the area containing the red blood corpuscles.

The mechanism underlying this structural change and, in particular, the question as to whether, and to what extent, the change may be considered as specific for carcinogenic agents is a matter for further investigation.

SUMMARY

It has been found that carcinogenic tar acts upon the lymph glands of the rat in converting them into more or less pronounced haemolymph glands.

REFERENCES

- TWORT, C. C. & FULTON, J. D. (1930). *J. Path. & Bact.* **33**, 119.

(*MS. received for publication 22. I. 1938.—Ed.*)