

## Letter to the Editors

### Left atrial myxoma manifesting as acute isolated vertigo

Dear Sirs,

Myxoma is the most common type of primary cardiac tumour.<sup>1</sup> Vertigo has rarely been associated with cardiac myxoma, and has been ascribed to cardiac dysfunction or a peripheral vestibular lesion without detailed description.<sup>2–4</sup> The authors report a patient with cardiac myxoma that manifested as acute isolated vertigo from embolic cerebellar infarcts.

A 50-year-old woman suddenly developed vertigo with nausea and vomiting. She almost fell down because of the vertigo, but did not lose consciousness. She denied hearing loss, tinnitus, diplopia, dysarthria, or sensorimotor symptoms. She had had a history of diabetes and migrainous headache for the past year and had been taking oral hypoglycaemia medication.

In the emergency room, one hour after the onset of symptoms, her vital signs were within the normal range. Blood sugar was measured at 78 mg/dl. The symptoms improved with anti-emetics and vestibular suppressants. She was discharged without a definite diagnosis. Two hours after discharge, she revisited the emergency room due to recurrent vertigo and headache. On examination, her heart beat was regular without murmur. Carotid or subclavian bruit was not audible. Ocular motility was full. However, she showed bilateral gaze-evoked nystagmus without rebound nystagmus. Smooth pursuit was mildly impaired. Saccades were normal. The findings of otoscopic examination, Weber test, and pastpointing were normal. Testing of finger-to-nose and heel-to-shin revealed no dysmetria. She could not stand unaided without veering in all directions. Other neurological examinations were normal. A complete blood count revealed mild anaemia with a haemoglobin of

11.6 g/dl and haematocrit of 35 per cent. Other laboratory findings were within the normal range, except for a small amount of glucose in the urine.

In view of the severe imbalance and gaze-evoked nystagmus, she was suspected to be experiencing vertigo of central origin, and underwent magnetic resonance imaging (MRI) of the brain. The MRI revealed scattered ischaemic foci in both cerebellar hemispheres, which were consistent with embolic infarcts (Figure 1(a)). Subsequent echocardiography disclosed a mass which was attached to the septal wall of left atrium (Figure 1(b)).

The headache, nausea, and vomiting subsided over a day, but mild dizziness persisted. She underwent an excisional biopsy of the cardiac mass, the pathology of which was consistent with cardiac myxoma. After the operation, aspirin 100 mg per day was added to the previous oral hypoglycaemic medication. During follow-up, she reported intermittent migrainous headaches but no more episodes of vertigo or imbalance.

Myxoma is a neoplasm of endocardial origin, usually arising from the interatrial septum at the border of the fossa ovalis in the left atrium.<sup>1</sup> Although symptoms of congestive heart failure such as syncope and dyspnoea on exertion are most common in patients with cardiac myxoma, some manifest with embolic events to the cerebral arteries, which lead to infarction, intracranial haemorrhage, aneurysmal formation, and metastasis.<sup>5</sup> The emboli consist of either myxomatous tissue or thrombus adherent to the myxoma.

The diagnosis of cardiac myxoma is always challenging because it is uncommon and usually presents with nonspecific symptoms. Our patient presented with acute isolated vertigo from multiple embolic infarcts in the cerebellum. Sudden isolated vertigo has generally been

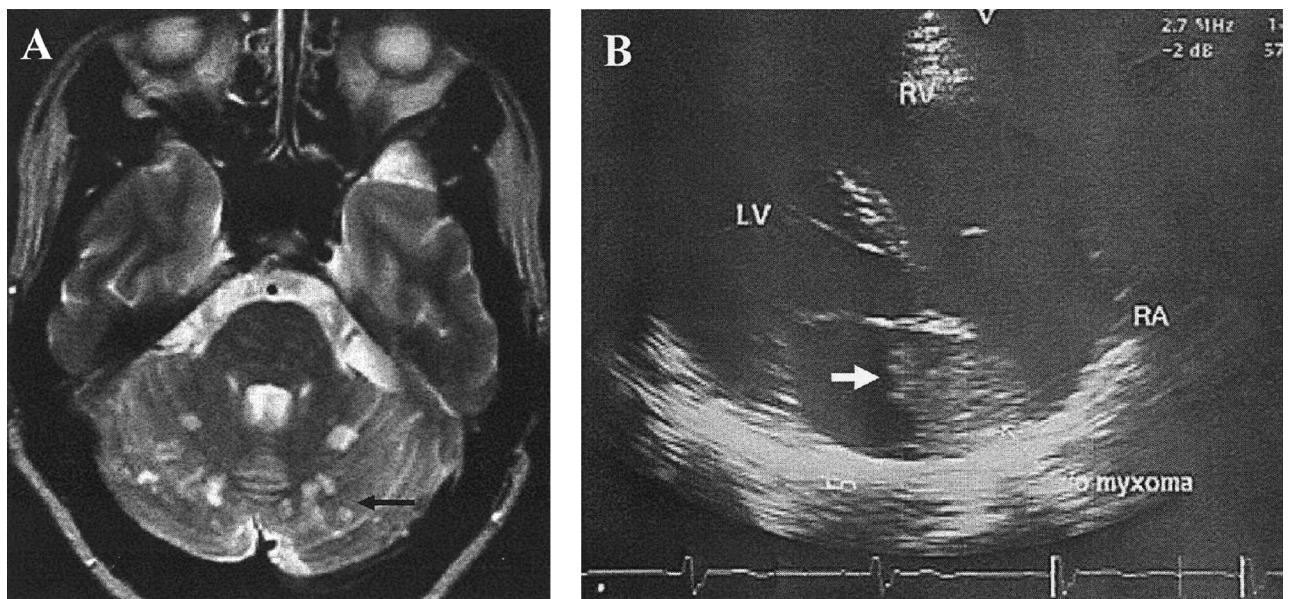


FIG. 1

(a) T2-weighted MRI reveals disseminated small infarcts in bilateral cerebellum (black arrow). (b) Echocardiography demonstrates an echogenic mass, 4 × 3 × 3 cm in diameter, which was attached to the septal wall of the left atrium (white arrow).

ascribed to acute unilateral injury to the peripheral vestibular structures, known as vestibular neuritis.<sup>6</sup> However, sudden damage to the inferior cerebellum or to the rostral, dorsolateral medulla may simulate vestibular neuritis.<sup>6</sup> Caudal cerebellar infarction explained one fourth of the isolated acute vertigo lasting more than 48 hours in the elderly.<sup>7</sup> In patients with isolated spontaneous vertigo, the type of nystagmus, the severity of postural instability, and the time course of vertigo are the main factors that help differentiate peripheral vestibular disorders from the central vestibulopathy. Dysmetria, a major finding of the cerebellar system may be minimal or absent after an inferior cerebellar or rostral medullary stroke as in this patient. The direction-changing, purely vertical, and purely torsional nystagmus are almost always due to a central disorder. Patients with acute cerebellar stroke show severe postural instability and falling when walking is attempted whereas most patients with acute unilateral disorders of the peripheral vestibular system are able to walk with a tendency to veer toward the side of the lesion.<sup>6</sup> In this patient, gaze-evoked nystagmus and severe imbalance suggested vertigo of central origin, and subsequent MRI revealed multiple cerebellar lesions.

Due to the nonspecific presentation of cardiac myxomas, a high index of suspicion is warranted. An embolic stroke in a person without evidence of cerebrovascular disease, particularly in the presence of sinus rhythm, should raise the possibility of intracardiac myxoma, as well as infective endocarditis and prolapse of the mitral valve. Surgical removal of the cardiac myxoma should be performed as soon as possible because of the potential embolic complications.

#### Acknowledgements

This work was supported by a grant (R05-2001-000-00616-0) from the Korea Science and Engineering Foundation.

Ja-Won Koo, M.D.\*,  
So-Young Moon, M.D.,  
Ji-Soo Kim, M.D.  
Departments of Neurology and Otolaryngology\*,  
Seoul National University,  
Bundang Hospital,  
300 Gumi-dong,  
Bundang-gi,  
Seongnam-si,  
Gyeonggi-do, 463-707,  
Korea

Fax: 82-31-7196828

E-mail: jisookim@snu.ac.kr

#### References

- 1 Reynen K. Cardiac myxomas. *New Engl J Med* 1995;**333**: 1610–17
- 2 Mattle HP, Maurer D, Sturzenegger M, Ozdoba C, Baumgartner RW, Schroth G. Cardiac myxomas: a long term study. *J Neurol* 1995;**242**:689–94
- 3 Gersak B, Mikek M, Smrkolj V, Gabrijelcic T. Results of treatment of 17 patients with heart tumour. *Eur J Surg Oncol* 1999;**25**:302–5.
- 4 Pinede L, Pierre D, Robert L. Clinical presentation of left atrial cardiac myxoma: A series of 112 consecutive cases. *Medicine* 2001;**80**:159–72
- 5 Knapper LE, Biller J, Adams HP, Bruno A. Neurologic manifestations of atrial myxoma. *Stroke* 1988;**19**:1435–40
- 6 Hotson J, Baloh RW. Acute vestibular syndrome. *New Engl J Med* 1998;**339**:680–5.
- 7 Norrving B, Magnusson M, Holtas S. Isolated acute vertigo in the elderly; vestibular or vascular disease? *Acta Neurol Scand* 1995;**91**:43–8