

LASER PERIMETRY: SPATIAL ADDITION ANALYSIS IN THE PAPHILLOEDEMA

F. BARTOLI, L. LIUZZI

Eye Clinic, University of Turin, Italy

Two cases of suspected oedema of the optic disk are presented and references is made to the spatial summation technique as a means of diagnostic classification. Comparison of the results obtained with white and laser source pointed to the superiority of the latter.

Conventional campimetry was modified in the present study to the extent of using targets obtained with a laser, that is to say, with a strictly monochromatic light source.

A Goldmann perimeter was connected to a 0.5 mW helium-neon laser with the following characteristics: wavelength 6328 Å ; band width 0.1 Å ; spread 1 milliradian; beam width 0.8 mm. Reasons for selecting a monochromatic source of this type have been given elsewhere (Liuzzi and Bartoli 1972a, 1972b, 1973)

Comparison between laser and white-light findings was made. A certain number of conventional isopters was determined. After a period of rest, to ensure the absence of fatigue, the examination was repeated with the laser, using luminance levels that would ensure coincidence with the white light isopters in lesion-free areas of the visual field. Later, the order of examination was reversed.

In the two cases discussed in the present paper, attention was given to spatial summations. A stimulus, however small, whose brightness is such as to reach threshold values in every receptor concerned, is quantitatively equivalent to one of subliminal brightness, but large enough to ensure that the sum of its spatial effects attains the threshold value of the ganglion cell or cells at which such effects are concentrated.

Failure of two photometrically equivalent isopters to coincide is usually indicative of retinal oedema, since this condition is responsible for divarication of the receptors and hence a decrease in their density.

In some instances, such as the two cases reported here, the clinical picture may be so poorly defined that campimetric confirmation is necessary. Comparison was therefore made between white light and the laser in terms of spatial summations. The validity of this method in conjunction with a laser source had already been established in both normal and frankly pathological cases.

CASE REPORTS

CASE 1

A.G., aged 54, admitted to a neurological clinic for observation.

Objective examination: B.E., 10/10 without glasses. Ocular tone and biomicroscopy, within the limits of normal.

Proc. 4th Int. Congr. Neurogenet. Neuroophthalmol. (1973)

Acta Genet. Med. Gemellol. (Roma), 23: 353-355

© 1974

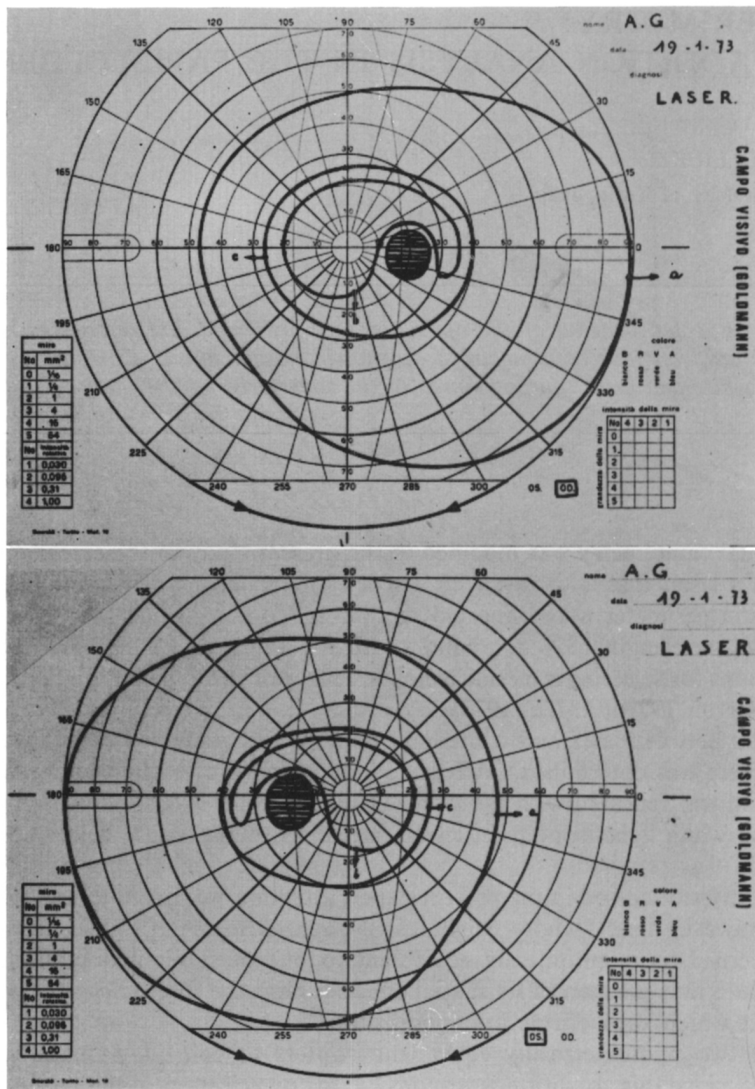


Figure. Laser perimetry of A.G. (Case 1): 1, right eye; 2, left eye.

Ophthalmoscopy: Disks with indistinct borders, slightly enlarged vein calibre. Unimpaired peripheral and macular areas. Clinical suspicion of initial oedema.

Perimetry: White light: isopters with targets 5/4 and 2/1 showed a normal visual field. Slight enlargement of papillae and alteration of spatial summations.

Laser: the isopters indicated with the letter *a* in the Figure correspond to those obtained with the 5/4 white light target. The central isopter was determined with the summation target technique. Using a target with a larger surface and determined at a lower brightness level, a concentric narrowed isopter (*b* in the Figure) open at the low pole of the papilla was observed. The letter *c* shows the

isopter obtained with a quantitatively equivalent target of greater brightness and smaller surface area. The papilla appeared slightly enlarged with this target.

CASE 2

R.B., aged 29, admitted to a neurological clinic on 2-4-1973 for vertigo crises, headaches, and nausea. Subjected to ophthalmological examination for suspected oedema of the optic disk.

Objective examination: B.E., 10/10 without glasses. Ocular tone and biomicroscopy: within the limits of normal.

Ophthalmoscopy: Disks with indistinct borders, no sign of calibre or course irregularities in the retinal veins and arteries. Clinical suspicion of initial oedema.

Perimetry: White light. R.E.: isopter with target 5/4 virtually normal; that obtained with target 4/1 revealed flattening in the upper quadrants. Slight enlargement of papillae and alteration of spatial summations.

L.E.: similar picture, apart from unimportant difference.

Laser: Defects observed with white light accentuated in the coincident isopters; in the case of isopter 4/1, in fact, the normal picture observed with light was replaced by one with an upper sector defect when the laser was used.

Further examination with the ophthalmoscope showed oedema of the optic disk in both cases.

CONCLUSIONS

Our findings make it clear that:

- 1) Spatial summation gives distinct evidence of the presence of peripapillar oedematous areas;
- 2) Such areas are more really detected with the laser than with white light;
- 3) The laser also shows that the area of involvement includes a good part of the posterior pole.

Laser perimetry can thus be recommended as a means of obtaining a more precise degree of discrimination when investigating the functional capacity of the retina.

REFERENCES

- Liuzzi L., Bartoli F. 1972a. Sul problema del monocromatismo delle mire proiettate nella perimetria qualitativa. Atti del LIV Congresso S.O.I., Roma. *In press.*
- Liuzzi L., Bartoli F. 1972b. Introduzione alla perimetria laser. Arch. e Rass. Ital. Ottalmol., 2: 182-188.
- Liuzzi L., Bartoli F. 1973. Perimetria laser: reperti campimetrici in tre casi di adenoma eosinofilo. Arch. e Rass. Ital. Ottalmol., *in press.*

Dr. Franco Bartoli, Clinica Oculistica dell'Università, Via Juvara 19, Torino, Italy.