

## Main Article

Francesco Maccarrone takes responsibility for the integrity of the content of the paper

**Cite this article:** Maccarrone F, Molinari G, Fermi M, Alicandri-Ciufelli M, Presutti L, Tassi S, Villari D, Negri M. Surgical anatomy of posterior tympanotomy: influence of the retrotympaanum on round window exposure. *J Laryngol Otol* 2024;**138**:142–147. <https://doi.org/10.1017/S0022215123000944>

Received: 13 February 2023

Revised: 16 April 2023

Accepted: 28 April 2023

First published online: 29 May 2023

### Keywords:

Retrotympaanum; middle ear anatomy; mastoidectomy; cochlear implantation

### Corresponding author:

Francesco Maccarrone;

Email: [fra.maccarrone@gmail.com](mailto:fra.maccarrone@gmail.com)

# Surgical anatomy of posterior tympanotomy: influence of the retrotympaanum on round window exposure

Francesco Maccarrone<sup>1,2</sup> , Giulia Molinari<sup>3,4</sup>, Matteo Fermi<sup>3,4</sup>,

Matteo Alicandri-Ciufelli<sup>1</sup>, Livio Presutti<sup>3,4</sup>, Sauro Tassi<sup>2</sup>, Domenico Villari<sup>1</sup> and Maurizio Negri<sup>2</sup>

<sup>1</sup>Department of Otolaryngology Head and Neck Surgery, Azienda Ospedaliero-Universitaria Policlinico di Modena, Modena, Italy, <sup>2</sup>Department of Otolaryngology Head and Neck Surgery, Azienda USL di Modena, Ospedale 'Ramazzini' di Carpi, Carpi (MO), Italy, <sup>3</sup>Department of Otorhinolaryngology and Audiology, IRCCS Azienda Ospedaliero-Universitaria di Bologna, Bologna, Italy and <sup>4</sup>Department of Medical and Surgical Sciences, Alma Mater Studiorum University, Bologna, Italy

## Abstract

**Objectives.** To describe how the retrotympaanic structures could influence the visibility of the round window niche and the round window membrane during cochlear implant surgery, and to investigate if a round window approach is possible even in cases with unfavourable anatomy.

**Methods.** Video recordings from 37 patients who underwent cochlear implantation were reviewed. The visibility of the round window niche and round window membrane at different timepoints was assessed according to a modified version of the Saint Thomas Hospital classification. The structures that concealed the round window niche and round window membrane were evaluated.

**Results.** After posterior tympanotomy, 54 per cent of cases had limited exposure (classes IIa, IIb and III) of the round window niche. After remodelling the retrotympaanum, round window niche visibility significantly increased, with 100 per cent class I and IIa cases. Following remodelling of the round window niche, visibility of more than 50 per cent of the round window membrane surface was achieved in 100 per cent of cases.

**Conclusion.** Remodelling the retrotympaanum and the round window niche significantly increased exposure of the round window niche and round window membrane respectively, allowing round window insertion in all cases.

## Introduction

Since its first description by House and Urban in 1973,<sup>1</sup> cochlear implant surgery has undergone some technical variations. Initially, the approach to the scala tympani through the round window was preferred because the short monocoanal array could be easily inserted through the round window membrane.<sup>2</sup> In 1993, Lenhardt systemised an alternative procedure to reach the scala tympani, namely the promontorial cochleostomy, consisting of the creation of a hole antero-inferiorly with respect to the round window.<sup>3</sup> This approach was meant to facilitate access to the cochlea by reducing the angle of insertion, and to have a high rate of hearing preservation, to the extent that it was named 'soft surgery'.<sup>3</sup> Today, the 'gold standard' approach for electrode insertion is via the round window membrane.<sup>4</sup>

However, promontorial cochleostomy or round window enlargement are routinely used in those cases with poor visualisation of the round window membrane.<sup>5,6</sup> The feasibility of the round window approach through posterior tympanotomy could be influenced by the anatomical configuration of the retrotympaanum in relationship to the round window niche. Indeed, some bony structures, such as the pyramidal eminence and the pyramidal ridge, could hide the round window niche.

This study aimed to describe how the retrotympaanic structures could influence the visibility of the round window niche and round window membrane during cochlear implant surgery. We sought to investigate whether a round window approach is possible even in cases with unfavourable anatomy by proper dissection of the surgical route to the round window membrane.

## Materials and methods

A retrospective study was performed on 63 consecutive patients who underwent cochlear implant surgery between January 2019 and October 2021 at two referral centres for ear surgery.

Inclusion criteria consisted of paediatric and adult patients undergoing cochlear implant surgery, whose surgical videos were available for review. Patients with malformed

ears, a high-riding jugular bulb covering the round window niche, cochlear otosclerosis or a history of previous ear surgery, were excluded.

The Saint Thomas Hospital classification<sup>7</sup> was originally proposed for the evaluation of round window membrane visibility after an 'optimal' posterior tympanotomy and the removal of any overhang of the round window niche, without breaching the membrane (Table 1).

We sought to evaluate the visibility of the round window niche and round window membrane, according to the temporal development of the surgical steps (which allow for exposure first of the niche and eventually of the membrane).

In order to assess the visibility of the round window niche during the different steps of surgery, a classification for round window exposure based on the Saint Thomas Hospital scale was applied at two timepoints of the procedure: timepoint one – after posterior tympanotomy, and timepoint two – after drilling of the retrotympenic structures.

Similarly, the proper Saint Thomas Hospital classification was then used to assess the visibility of the round window membrane after drilling of the retrotympenic structures and completion of round window niche exposure, at two timepoints: timepoint one – before milling of the round window bony edges (tegmen, posterior pillar, anterior pillar) and timepoint two – after milling of the round window bony edges (maximal bone drilling) (Figs 1 and 2).

For each surgical procedure, the anatomical retrotympenic structures that concealed the round window niche and round window membrane were assessed, namely the pyramidal eminence, the styloid eminence and the pyramidal ridge. The pyramidal eminence is the most visible and constant landmark in the retrotympenic; it consists of a bony process originating from the region of the second genu of the facial nerve and extending toward the neck of the stapes. It contains the stapedial muscle, with the stapedial tendon arising from its summit.<sup>8</sup> The styloid eminence is the upper end of the styloid process of the temporal bone, located caudally to the pyramidal eminence, and variably protruding into the inferior part of the retrotympenic. This structure shows some variability, as reported by Anschuetz *et al.*<sup>9</sup> The pyramidal ridge is a bony ridge extending from the styloid eminence to the pyramidal eminence.<sup>8</sup>

All surgical video recordings were independently reviewed by two authors (FM and GM), who subsequently met and discussed possible disagreements on classifications. Finally, the classifications were critically reviewed by the senior authors (LP and MN) for the definitive decisions.

The facial nerve was routinely continuously monitored during surgery. At the end of the surgical procedure, during electrophysiological testing, the stapedial reflex was used for

evidence of stapedial tensor tendon contraction under microscopic vision in response to electric stimulation.

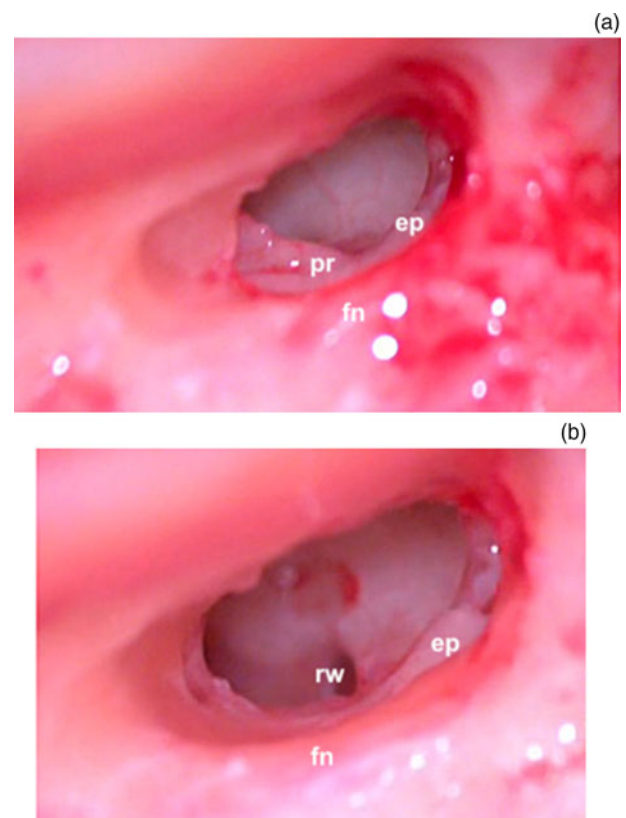
### Statistical analysis

All analyses were conducted with SPSS Statistics software, version 26.0 (IBM, Armonk, New York, USA). Categorical variables were presented as rates (percentages), while continuous variables were presented as means and standard deviations (SD) or medians and interquartile ranges, depending on the normality of distribution, which was determined via the Kolmogorov–Smirnov test. The distribution of Saint Thomas Hospital classifications in the assessment of the round window niche at timepoint one (after posterior tympanotomy) and timepoint two (after drilling of the retrotympenic structures), and assessment of the round window membrane at timepoint one (before milling of the round window bony edges (tegmen, posterior pillar, anterior pillar)) and timepoint two (after milling of the round window bony edges (maximal bone drilling)) was assessed via the Wilcoxon signed rank test.

## Results

### General results

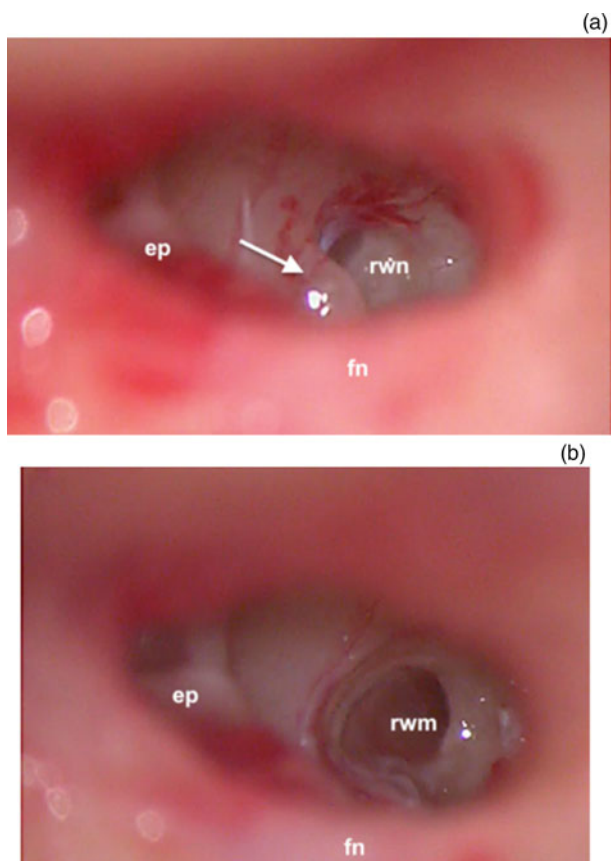
Based on the inclusion criteria, 37 surgical cases were eventually included in the study. Of the included patients, 22 were men and 15 women (male-to-female ratio of 1:1.46). Twenty-eight patients (75.7 per cent) were adults, while 9 (24.3 per cent) were younger than 18 years; the mean age at surgery was 42 years (range, 2–89 years).



**Figure 1.** Left ear. Intra-operative microscopic view of the round window niche: (a) after posterior tympanotomy (timepoint one), and (b) after drilling of the retrotympenic structures (timepoint two). ep = pyramidal eminence; pr = pyramidal ridge; rw = round window; fn = facial nerve

**Table 1.** Saint Thomas Hospital classification

Class	% of exposed round window	Description
I	100	Full exposure of round window
IIa	>50	Exposure of >50% of round window
IIb	<50	Exposure of <50% of round window
III	0	None of round window is visible



**Figure 2.** Right ear. Intra-operative microscopic view of the round window membrane: (a) after drilling of the retrotympenic structures (timepoint one), and (b) after milling of the round window bony edges (arrow) (timepoint two). rwn = round window niche; rwm = round window membrane; fn = facial nerve; ep = pyramidal eminence

Four different brands of cochlear implant were used (Cochlear, Medel, Oticon and Advanced Bionics). In all included cases, a round window approach was achieved and 100 per cent of the electrodes were inserted into the cochlea. Intra-operative tests showed normal impedance values in all cases.

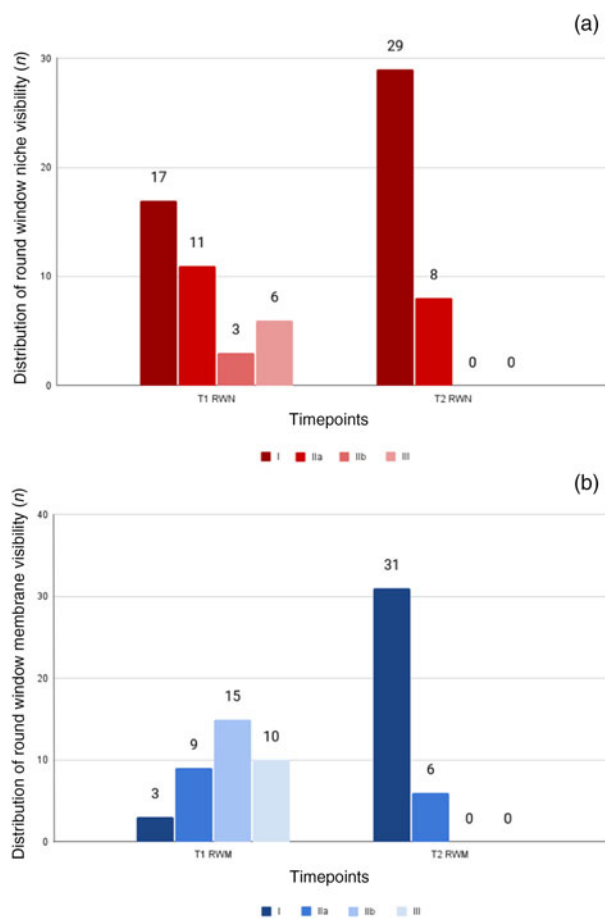
The stapedial reflex at the end of the surgery was maintained in all cases, suggesting the integrity of the stapedial muscle and tendon. There were no intra-operative or post-operative complications.

**Round window niche and membrane visibility**

The distribution of round window niche and round window membrane visibility according to the Saint Thomas Hospital scale at the defined timepoints is reported in Fig. 3.

After posterior tympanotomy (timepoint one), more than half of the cases (54 per cent) had limited exposure (classes IIa, IIb and III) of the round window niche. In those cases, the retrotympenic structures responsible for hiding the round window niche were: the pyramidal eminence (Fig. 4), in five cases (25 per cent); the pyramidal ridge (Fig. 1), in five cases (25 per cent); a combination of these two (Fig. 5), in six cases (30 per cent); and the pyramidal eminence, pyramidal ridge and styloid eminence together (Fig. 6), in two cases (20 per cent).

After drilling and curetting of the above-mentioned retrotympenic structures (timepoint two), round window niche visibility significantly increased ( $p < 0.001$ ), as shown by the



**Figure 3.** (a) Histogram showing the distribution of the visibility of the round window niche after posterior tympanotomy (timepoint one for round window niche (T1 RWN)) and after drilling of the retrotympenic structures (timepoint two for round window niche (T2 RWN)), according to the modified Saint Thomas Hospital classification. (b) Histogram showing the distribution of the visibility of the round window membrane before milling of the round window bony edges (timepoint one for round window membrane (T1 RWM)) and after maximal drilling (timepoint two for round window membrane (T2 RWM)).

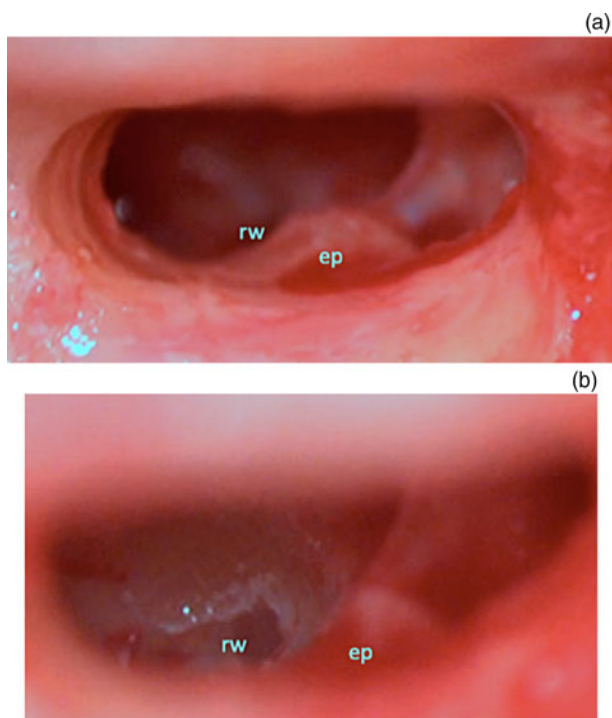
distribution of the Saint Thomas Hospital categories during this assessment of the round window niche, as reported in Fig. 3. Globally, drilling was necessary at the pyramidal eminence in 13 cases (35 per cent), at the pyramidal ridge in 14 cases (38 per cent) and at the styloid eminence in 8 cases (22 per cent).

Visualisation of the round window membrane significantly improved ( $p < 0.001$ ) after milling the bony edges of the round window niche (timepoint two), and visibility of more than 50 per cent (Saint Thomas Hospital score higher or equal to IIa) was achieved in 100 per cent of the cases.

**Discussion**

In recent decades, the development and use of endoscopes in middle-ear surgery has allowed for very accurate studies of the anatomical details and variants of the middle ear. The retrotympenic region represents a very complex region, as it houses the tympanic tract of the facial nerve, the medial and lateral retrotympenic sinuses, and the region of the oval window, all of which could show some anatomical variability relevant for surgery.<sup>9-12</sup> The microscopic view of the tympanic cavity through posterior tympanotomy is not only limited but also extremely variable in relation to the different anatomical

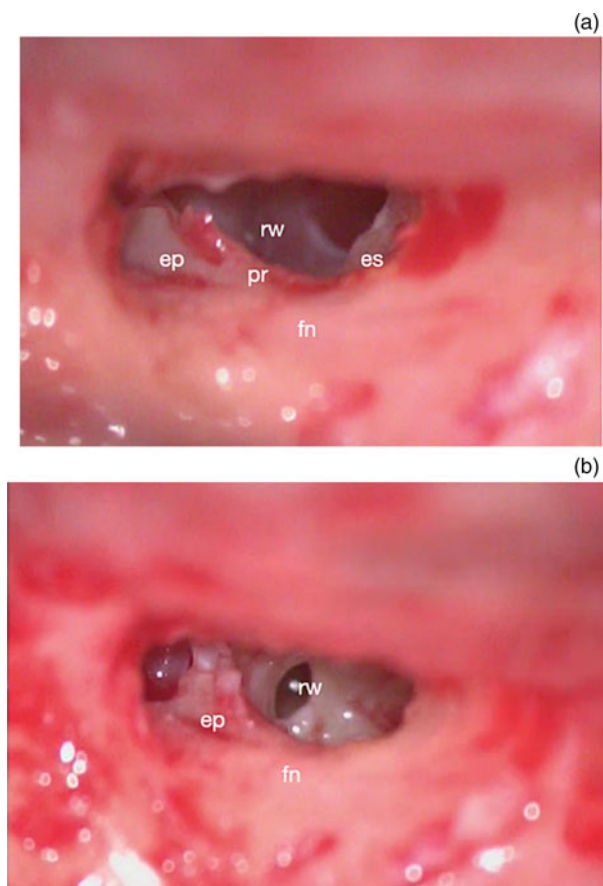




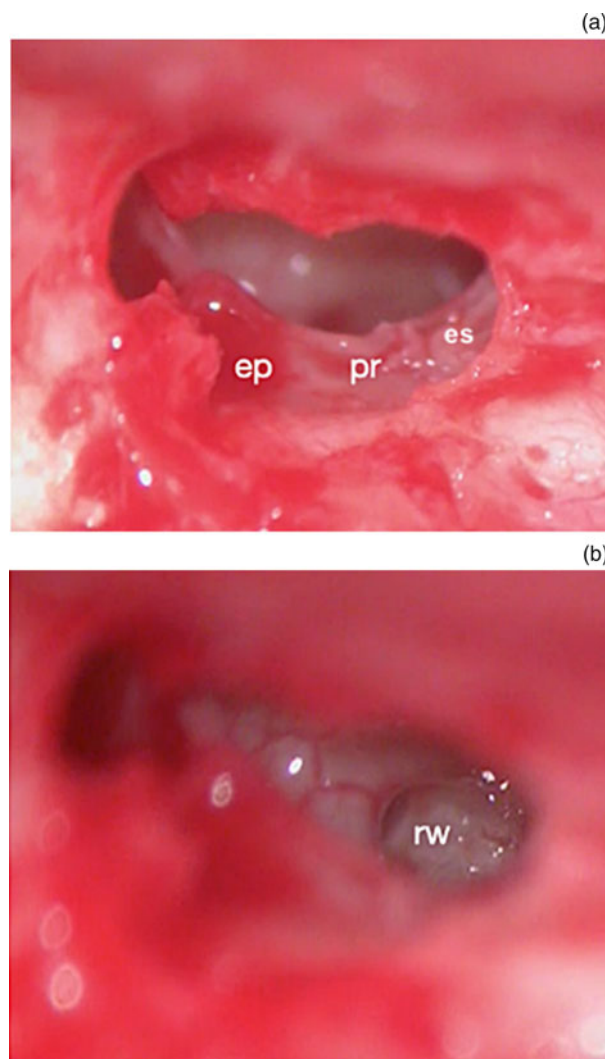
**Figure 4.** Left ear. (a) Pyramidal eminence ('ep') partially conceals the round window ('rw'); (b) exposure of the round window niche after drilling.

possibilities, such that the surgeon has to rely on surgical landmarks to orient themselves, even in the most complex cases.

In cochlear implant surgery, the Saint Thomas Hospital classification of round window visibility has been developed



**Figure 5.** Right ear. (a) Pyramidal eminence ('ep') and pyramidal ridge ('pr') partially conceal the round window ('rw'); (b) exposure of the round window after drilling. fn = facial nerve; es = styloid eminence



**Figure 6.** Right ear. (a) Pyramidal eminence ('ep'), pyramidal ridge ('pr') and styloid eminence ('es') completely conceal the round window ('rw'); (b) exposure of the round window niche after drilling.

to categorise the round window exposure after creating an 'optimal' posterior tympanotomy and removing as much of the round window niche bony overhang as possible, without breaching the membrane.<sup>7</sup>

According to this classification, type I describes the full exposure of the round window membrane. Type II describes partial exposure, and is sub-divided into types IIa and IIb; in type IIa, more than 50 per cent but less than 100 per cent of the round window membrane is exposed, and in type IIb the exposure is less than 50 per cent but more than 0 per cent. In type III, the round window membrane cannot be identified at all, even after the best surgical effort (Table 1).

The 'optimal' posterior tympanotomy has been clarified by Leong *et al.* as being the widest posterior tympanotomy achievable with the operating surgeon's best surgical effort, preserving the integrity of the facial nerve, chorda tympani, posterior canal wall and bony annulus.<sup>6</sup>

According to our results, once access had been gained to the middle ear (after posterior tympanotomy), in around half of the cases the round window niche was variably hidden by the retrotympanic structures, while the pyramidal eminence, which is located above and lateral to it, was constantly identifiable, representing a constant surgical landmark, not only for the round window niche itself but also for the facial

nerve, which lies lateral to it. In most cases, the pyramidal eminence and the pyramidal ridge are responsible for impeding adequate visualisation of the round window niche, with the styloid eminence further contributing to concealing this region in 20 per cent of cases. In these cases, the lower base of the pyramidal eminence, the pyramidal ridge and the upper portion of the styloid eminence should be milled, with awareness of the position of the third tract of the facial nerve, which runs lateral to these structures.

Despite the remodelling of the retrotympanic structures, which creates a larger working area and facilitates the identification of the round window niche, the round window membrane itself was not completely visible (class II and III) in 34 out of 37 cases (92 per cent). This underlines that an optimal posterior tympanotomy is not sufficient for proper membrane visualisation; it is almost always necessary to mill the round window niche (tegmen, posterior pillar, anterior pillar) for adequate membrane exposure. At the same time, optimal drilling of the round window niche could be performed safely only if a wide posterior tympanotomy guarantees a suitable working area and sufficient light on the niche. In the authors' experience, these strategies allow for a round window approach in all cases.

It is currently universally recognised that the access route to the cochlea through the round window is beneficial in several respects. For instance, not only does it represent the anatomical route to the scala tympani, but it also reduces the amount of perforation necessary for electrode positioning, decreasing the risks of acoustic trauma, the loss of perilymph and the entry of bone dust into the scala tympani. The reduced formation of fibrous tissue and ossification, and more effective sealing around the electrode, have also been related to the more conservative round window approach. This seems to accelerate the healing process and reduce the risk of inner-ear infection.<sup>4,6</sup> Furthermore, since the electrode enters the cochlea in a more basal position with the round window approach, it stimulates the neuronal elements located more basally. Finally, the currently available atraumatic straight electrodes are more compatible with the round window approach than with cochleostomy. Therefore, electrode insertion through the round window is strongly recommended to attempt hearing preservation.

Several previous studies have evaluated the visibility of the round window according to the Saint Thomas Hospital classification and correlated it to the type of approach. In a study by Leong and colleagues, a membranous cochleostomy was performed in 96 per cent of type I cases.<sup>6</sup> Approximately two-thirds (63 per cent) of type IIa patients underwent round window access, while the remaining 37 per cent required round window enlargement. Similarly, in cases classified as IIb, 19 per cent underwent a simple membranous cochleostomy, but 71 per cent required bone extension. A minority of type IIb cases (9 per cent) and all type III cases required conventional bone cochleostomy.

Recent work by Stuermer *et al.*, in 2021, evaluated the intra-operative data concerning round window visibility and the surgical approaches through the administration of a questionnaire, focusing on the surgical aspects relevant to obtain adequate visualisation of the round window.<sup>13</sup> The first element of the questionnaire was the surgeon's approach to inserting the electrode array (round window enlargement, round window approach, cochleostomy). The next element of the questionnaire was round window membrane visibility, as per the Saint Thomas Hospital classification. The other

questionnaire items evaluated the surgical steps necessary to achieve maximum round window exposure: was the facial nerve transosseously exposed? Was the facial nerve soft? Was the pyramidal eminence lowered? Was the stapedius muscle soft? Was the chorda tympani not exposed, exposed and preserved, or cut. Regarding round window niche exposure, the questionnaire asked: was the superior bony lip drilled? Was the anterior bony lip drilled? Was the posterior bony lip drilled? What was the size of the posterior tympanotomy in cranio-caudal orientation (in millimetres)? What was the size of the posterior tympanotomy in antero-posterior orientation (in millimetres)? What was the thickness of the upper posterior auditory canal wall (in millimetres) (measured at the outward-facing ridge at medium height of the auditory canal with help of a sterile ruler)? Was the auditory canal wall lowered?

The data that emerged from this interesting analysis by Stuermer *et al.* are almost comparable to the previously cited study by Leong *et al.* In particular, all cases except type III could be managed with a broadened round window or round window approach. A round window approach was possible in 97 per cent of type I cases, but only in 86 per cent of type IIa cases. In the only case of type IIb, a broadened round window approach was performed, while 100 per cent of type III cases required a bone cochleostomy. Cases with round window membrane visibility of greater than 50 per cent (types I–IIa) were handled with a round window approach in 95 per cent of cases and with a round window enlargement approach in 5 per cent.<sup>13</sup>

- The surgical route for cochlear implantation is normally achieved through mastoidectomy and posterior tympanotomy
- Today, the 'gold standard' approach for electrode insertion during cochlear implant surgery is the round window
- Promontorial cochleostomy or round window enlargement are alternative techniques in cases of poor round window membrane visualisation
- Focused analysis of retrotympanic structures that mask the round window has not previously been performed
- Remodelling of the retrotympanic bony structures and round window niche enabled round window insertion in all cases
- Surgical suggestions to overcome variable anatomical configurations after posterior tympanotomy and to increase the round window approach rate are provided

The consideration of lowering the pyramidal eminence, performed in 57 per cent of cases in Stuermer and colleagues' series,<sup>13</sup> is interesting. Its role, however, is not explored in the discussion, and the study did not examine how much this could affect the improvement of round window exposure. The percentages of round window approach differ significantly from our results, and this may be related to our surgical strategy, consisting of milling the retrotympanic structures to enlarge the surgical route and gain better visualisation of the entire anatomical region. It is interesting that, according to our results, drilling of the pyramidal eminence necessary to expose the round window membrane did not correlate with functional damage of the stapedial muscle, as the stapedial reflex was preserved in 100 per cent of patients.

The relatively small number of included patients in our study prevents a comparison between the adult and paediatric populations. The anatomical variability between a developing temporal bone and an adult one may impact differently on the round window niche and membrane visibility, so that different surgical strategies could be applied in the two populations.

## Conclusion

The round window route for electrode insertion is associated with many significant challenges and technical limitations, mostly related to the anatomical variability of round window exposure.

Drilling and curetting of the retrotympanic structures, such as the pyramidal eminence, pyramidal ridge and styloid eminence, significantly increases the round window niche visibility. Parallel to this, milling of the bony lip of the round window niche guarantees improved visualisation of the round window membrane, with visibility of more than 50 per cent (Saint Thomas Hospital score of higher or equal to IIa) achieved in 100 per cent of the cases. The appropriate exposure of the round window niche and round window membrane as described herein allows a transfenestral approach for electrode array insertion in all cases.

**Competing interests.** None declared.

## References

- House WF, Urban J. Long term results of electrode implantation and electronic stimulation of the cochlea in man. *Ann Otol Rhinol Laryngol* 1973;**82**:504–17
- Clark GM, Pyman BC, Webb RL, Bailey QE, Shepherd RK. Surgery for an improved multiple-channel cochlear implant. *Ann Otol Rhinol Laryngol* 1984;**93**(3 Pt 1):204–7
- Lehnhardt E. Intracochlear placement of cochlear implant electrodes in soft surgery technique [in German]. *HNO* 1993;**41**:356–9
- Richard C, Fayad JN, Doherty J, Linthicum FH Jr. Round window versus cochleostomy technique in cochlear implantation: histologic findings. *Otol Neurotol* 2012;**33**:1181–7
- Elafandi H, Khalifa MA, Elguindy AS. Cochlear implantation outcomes with round window electrode insertion versus cochleostomy insertion. *Int J Pediatr Otorhinolaryngol* 2020;**138**:110272
- Leong AC, Jiang D, Agger A, Fitzgerald-O'Connor A. Evaluation of round window accessibility to cochlear implant insertion. *Eur Arch Otorhinolaryngol* 2013;**270**:1237–42
- Jiang D, Fitzgerald-O'Connor A. The assessment of the access to the round window approach through a posterior tympanotomy: a practical classification. In: *Abstracts of 26th Politzer Society Meeting*, Cleveland, USA, 13–16 October 2007. Politzer Society, 2007
- Proctor B. Surgical anatomy of the posterior tympanum. *Ann Otol Rhinol Laryngol* 1969;**78**:1026–40
- Anschuetz L, Alicandri-Ciuffelli M, Bonali M, Fermi M, Caversaccio M, Presutti L *et al.* Novel surgical and radiologic classification of the subtympanic sinus: implications for endoscopic ear surgery. *Otolaryngol Head Neck Surg* 2018;**159**:1037–42
- Bonali M, Fermi M, Alicandri-Ciuffelli M, Mattioli F, Villari D, Presutti L *et al.* Correlation of radiologic versus endoscopic visualization of the middle ear: implications for endoscopic ear surgery. *Otol Neurotol* 2020;**41**:e1122–7
- Molinari G, Yacoub A, Alicandri-Ciuffelli M, Monzani D, Presutti L, Caversaccio M *et al.* Endoscopic anatomy of the chorda tympani: systematic dissection, novel anatomic classification, and surgical implications. *Otol Neurotol* 2021;**42**:e958–66
- Alicandri-Ciuffelli M, Fermi M, Bonali M, Presutti L, Marchioni D, Todeschini A *et al.* Facial sinus endoscopic evaluation, radiologic assessment, and classification. *Laryngoscope* 2018;**128**:2397–402
- Stuermer K, Winter T, Nachtsheim L, Klussmann JP, Luers JC. Round window accessibility during cochlear implantation. *Eur Arch Otorhinolaryngol* 2021;**278**:363–70