

## Adenovirus eye infections in an Australian city, 1972-9

By L. IRVING, M. KENNETT, F. LEWIS, C. BIRCH  
AND A. DONALDSON

*Virus Laboratory, Fairfield Hospital for Communicable Diseases,  
Yarra Bend Road, Fairfield, Victoria 3078, Australia*

(Received 2 July 1980)

### SUMMARY

A number of adenovirus serotypes have been associated with both sporadic cases and outbreaks of conjunctivitis and pharyngoconjunctival fever but only adenovirus type 8 and adenovirus type 19 have been responsible for wide-spread epidemic kerato-conjunctivitis. In Melbourne, Australia, in the past eight years these two serotypes have been prevalent, resulting in an outbreak of adenovirus type 8 kerato-conjunctivitis in 1976-7 followed by adenovirus type 19 kerato-conjunctivitis in 1978-9. During these two periods of peak incidence, 53 cases of adenovirus type 8 and 43 cases of adenovirus type 19 kerato-conjunctivitis were confirmed by isolation.

### INTRODUCTION

The first isolation of an adenovirus was reported in 1953 (Rowe *et al.* 1953) from adenoid tissue of a healthy child and most infections caused by these viruses are subclinical. However, adenoviruses, of which at least 34 human types have been identified, can also cause a range of clinical syndromes including respiratory infections, pharyngoconjunctivitis, follicular conjunctivitis and kerato-conjunctivitis.

Several adenovirus types have been associated with epidemics of eye infection and a number of others isolated from sporadic cases.

Adenovirus type 3 (Bell *et al.* 1955) and adenovirus type 7 (Caldwell *et al.* 1974) have been specifically related to outbreaks of pharyngoconjunctivitis spread via swimming pools and in children's camps, schools and orphanages. Pharyngitis and fever are associated with conjunctivitis in these cases with corneal opacities being rare in children but occurring occasionally in adults.

Adenovirus type 4 is also a well-documented cause of conjunctivitis and pharyngoconjunctivitis (Centre for Disease Control, 1978*a, b*).

'Ship yard eye' was recognized clinically and the manifestations of epidemic kerato-conjunctivitis (EK-C) described in the late nineteenth century by Fulks (Jawetz, 1959). In 1954 a strain of adenovirus type 8 was isolated (Jawetz *et al.* 1955) from the eye of a seaman with typical EK-C and evidence rapidly accumulated to confirm that this was then the principal cause of the disease.

More recently, in 1974, adenovirus type 19 has been associated with epidemics of EK-C (Hierholzer *et al.* 1974). Adenovirus type 19 was first isolated from conjunctival scrapings surveyed for trachoma in Saudi Arabia during 1955 (Bell, Rota, McComb, 1960) and was not commonly reported until outbreaks of EK-C due to this virus occurred in the United States of America, Canada, then Europe and the United Kingdom from 1974 onwards. Adenovirus type 8 and adenovirus type 19 have been found concurrently during an epidemic but have not been isolated from the same patient.

The outstanding features of EK-C have been illustrated repeatedly in many outbreaks (Hogan & Crawford, 1942; Dawson *et al.* 1963; Barnard *et al.* 1973; Sprague *et al.* 1973; Guyer *et al.* 1975). A typical clinical picture is usually seen with acute conjunctivitis, oedema of conjunctiva, pain, photophobia, lacrimation, superficial erosion and subepithelial opacities of the cornea, which may persist for as long as two years (Jawetz, 1959). Outbreaks may involve a large number of people, and epidemics associated with industries where there is eye irritation due to dust are common (Sprague *et al.* 1973). Hospitals, first aid stations and ophthalmology clinics have featured prominently in cross infection (Dawson & Darrell 1963; Laibson, Ortolan & Dupré-Strachan, 1968; Barnard *et al.* 1973) and medical staff often acquire and transmit the disease, most probably via optical instruments, solutions and examining fingers (Dawson & Darrell, 1963; Wegman, Guinee & Millian, 1970; Sprague *et al.* 1973). Laboratory infections have also been reported (Jawetz *et al.* 1959) while household spread has been notable in some outbreaks (Dawson *et al.* 1960; Barnard *et al.* 1973; Guyer *et al.* 1975) but not in others (Jawetz, 1959; Sprague *et al.* 1973).

Outbreaks of adenovirus pharyngoconjunctivitis have been reported in Melbourne. In 1959 adenovirus type 7 was responsible for 44 cases in a migrant hostel (Duxbury *et al.* 1960), while over a period of two years from November 1969 to October 1971 an outbreak of adenovirus type 4 occurred (Ellis *et al.* 1974). At this time one-half of 66 patients from whom adenovirus type 4 was isolated suffered from conjunctivitis.

Virus isolations from specimens received at Fairfield Hospital Virus Laboratory from patients with conjunctivitis of suspected viral aetiology show that in the eight years (January 1972–December 1979) since the adenovirus type 4 outbreak, two other adenovirus serotypes have been prevalent in the community causing wide-spread kerato-conjunctivitis.

## MATERIALS AND METHODS

### *Collection and processing of specimens*

Conjunctival specimens were received from patients seen at Fairfield Hospital, other hospitals, including a specialist eye hospital, and practitioners in Melbourne and country areas in Victoria. Some corneal or conjunctival scrapings were received but most specimens were taken with sterile cotton wool swabs, which were wiped gently on the conjunctiva. All specimens were placed in 3 ml of viral transport medium (Donaldson *et al.* 1978) in screw-capped bottles. These were transported

to the laboratory with as little delay as possible, being kept at 4 °C during transport whenever this could be achieved. On arrival at the laboratory specimens were shaken on an automatic shaker to disperse virus into the medium, which was then inoculated into duplicate cell culture phials of primary cynomolgus monkey kidney cells (MK) obtained from Commonwealth Serum Laboratories (Kennett *et al.* 1972), HeLa-R (Lewis & Kennett, 1976) and human embryo lung (HEL) cells (Lewis & Kennett, 1976). The phials were placed in roller drums, incubated at 33 °C and cell monolayers were examined twice weekly for cytopathic effect for a maximum of five weeks, medium being changed in the phials not showing cytopathic effect at appropriate intervals.

During the eight-year period adenoviruses were also isolated from nose and throat swabs and faecal specimens routinely received from patients suffering from a variety of clinical syndromes. These swabs were treated in the same manner as conjunctival specimens, although some were inoculated into different combinations of cell types. Faecal specimens were processed as has been previously described (Kennett *et al.* 1972).

#### *Identification of viral isolates*

When viral cytopathic effect was observed, phials were removed from the drum and the supernatant medium sometimes passaged into homologous cells to confirm the presence of virus and, if necessary, to increase viral titre. When the cytopathic effect was clearly typical, typing by neutralization test was carried out.

Typing of suspected herpes simplex virus isolates was done by neutralization test in microtitre plates using antisera prepared in our laboratory (Lennette & Schmidt, 1969).

When typical adenoviral cytopathic effect was observed to have completely destroyed the cell sheet, HEL phials were frozen to -20 °C and thawed three times to release virus into the medium, which was used as a source of antigen for identification in a neutralization test (Ellis *et al.* 1974). The test was performed in MK cell culture phials or microtitre plates with type specific antisera obtained from the National Institute of Allergy and Infectious Diseases, National Institutes of Health, Bethesda, Maryland, U.S.A.

The rhinoviruses isolated were characterized by an acid lability test (Lewis & Kennett, 1976) and vaccinia isolates confirmed by EM examination and neutralization test using specific antisera (Lennette & Schmidt, 1969).

## RESULTS

### *Virus isolations from eye specimens*

Over a period of eight years the number of specimens received for virus isolation from patients with eye infections has varied, increasing from 33 in 1972 to 319 in 1979. Herpes simplex virus was isolated each year and there were miscellaneous isolations of vaccinia, rhinovirus, measles virus and enterovirus. During this time two peaks in adenovirus isolations from these specimens were seen corresponding to an outbreak of adenovirus type 8 kerato-conjunctivitis in 1976-77, followed

Table 1. *Incidence of virus isolations from eye specimens*

	Year							
	1972	1973	1974	1975	1976	1977	1978	1979
No. patients from whom specimens received	33	40	74	73	163	262	239	319
Adenovirus isolations	2	5	4	2	19	44	25	43
HSV isolations	5	1	8	14	6	7	15	16
Other virus isolations*	0	2	0	3	2	0	2	2
No. patients positive	7	8	12	19	27	51	42	61
% positive	18	20	16	26	10	19	19	16

\* Other viruses isolated from eye specimens: Vaccinia, 2 in 1973, 3 in 1975; Rhinovirus, 2 in 1976; Measles, 1 in 1978; Coxsackie B3, 1 in 1978; Coxsackie B4, 1 in 1979; Echo 11, 1 in 1979.

Table 2. *Adenoviruses isolated from eye specimens*

Adenovirus	Year							
	1972	1973	1974	1975	1976	1977	1978	1979
Type 1	—	—	—	—	—	—	2	—
3	—	3	—	—	—	1	1	1
4	—	—	1	—	1	—	—	1
7a	—	1	—	1	4	—	4	7
8	1	—	—	—	12	41	—	7
15	—	1	2	—	—	—	—	—
19	—	—	1	1	2	1	18	25
29	1	—	—	—	—	—	—	—
Not typed	—	—	—	—	—	1	—	2
Total	2	5	4	2	19	44	25	43

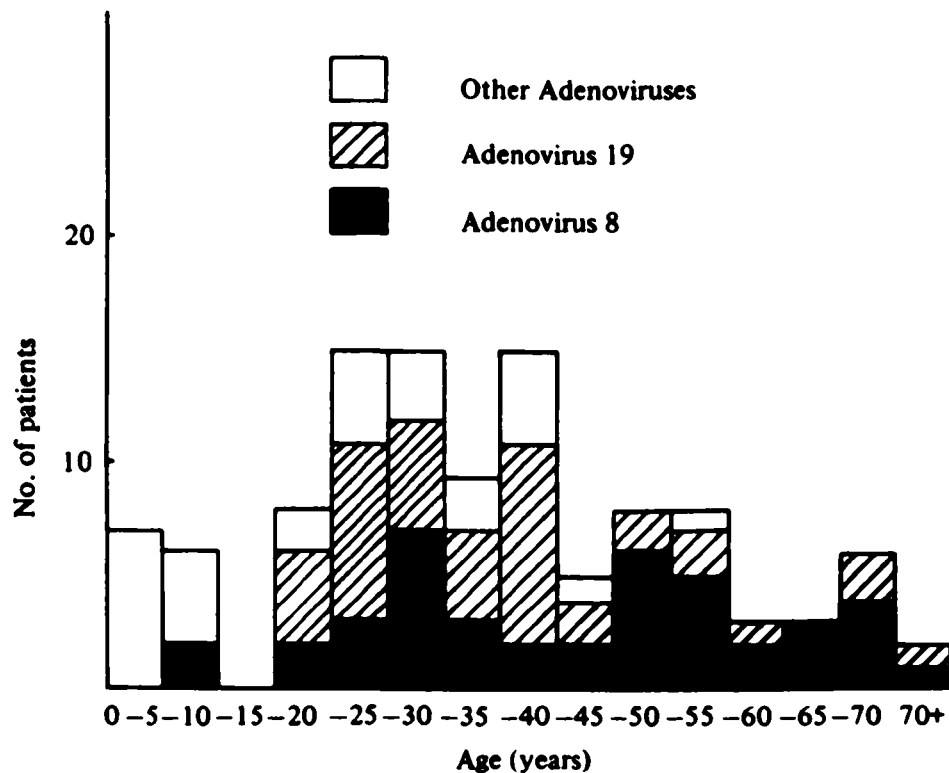
by adenovirus type 19 kerato-conjunctivitis in 1978–79 (Table 1). The overall isolation rate ranged from 10–26 % and did not improve markedly during epidemic years.

#### *Adenoviruses isolated from eye specimens*

Before 1976 adenovirus type 8 was last isolated from one patient in 1972, while there were isolations made from 12 patients in 1976 and 41 in 1977, adenovirus type 8 kerato-conjunctivitis was not diagnosed by virus isolation again until 1979 when there were seven cases. Adenovirus type 19 was isolated from one patient in 1974 and one in 1975, two in 1976 and one in 1977, then, as the adenovirus type 8 outbreak waned, adenovirus type 19 became the prevalent aetiological agent, causing 18 cases of kerato-conjunctivitis in 1978 and 25 in 1979. This virus continues to be isolated from eye swabs in 1980. Other adenovirus serotypes were recovered from conjunctival specimens sporadically during the same period (Table 2). The total number of patients from whom an adenovirus was isolated from eye specimens was 144.

**Table 3. Adenoviruses isolated from other specimens**

Adenovirus	Year							
	1972	1973	1974	1975	1976	1977	1978	1979
Type 1	36	19	15	27	17	14	14	29
2	34	29	20	22	26	10	22	38
3	13	12	5	13	12	7	3	1
4	—	—	6	1	5	—	—	2
5	21	11	10	13	10	6	9	14
7a	13	10	14	11	40	3	25	42
9	—	—	—	—	—	—	1	—
22	—	1	7	—	—	—	1	—
26	—	—	—	—	2	—	—	—
29	—	—	2	—	—	—	—	—
31	1	—	—	—	—	—	—	—
Not typed	1	—	—	—	1	10	1	3
<b>Total</b>	<b>119</b>	<b>82</b>	<b>79</b>	<b>87</b>	<b>113</b>	<b>50</b>	<b>76</b>	<b>129</b>



**Fig. 1. Age distribution of patients with adenovirus eye infections.**

*Adenoviruses isolated from other specimens*

During the same period adenoviruses were isolated from nose and throat swabs and faeces of patients with a wide range of other clinical syndromes, but the aetiological significance of many of these is doubtful. Only 13 of these 735 patients from whom an adenovirus was isolated from a site other than the eye, were noted to have conjunctivitis.

The adenovirus serotypes most frequently isolated from the nasopharynx and faeces were types 1, 2, 3, 5 and 7a and these were present each year. In addition, adenovirus type 4 was isolated in low to moderate numbers in 1974-76 and in 1979,

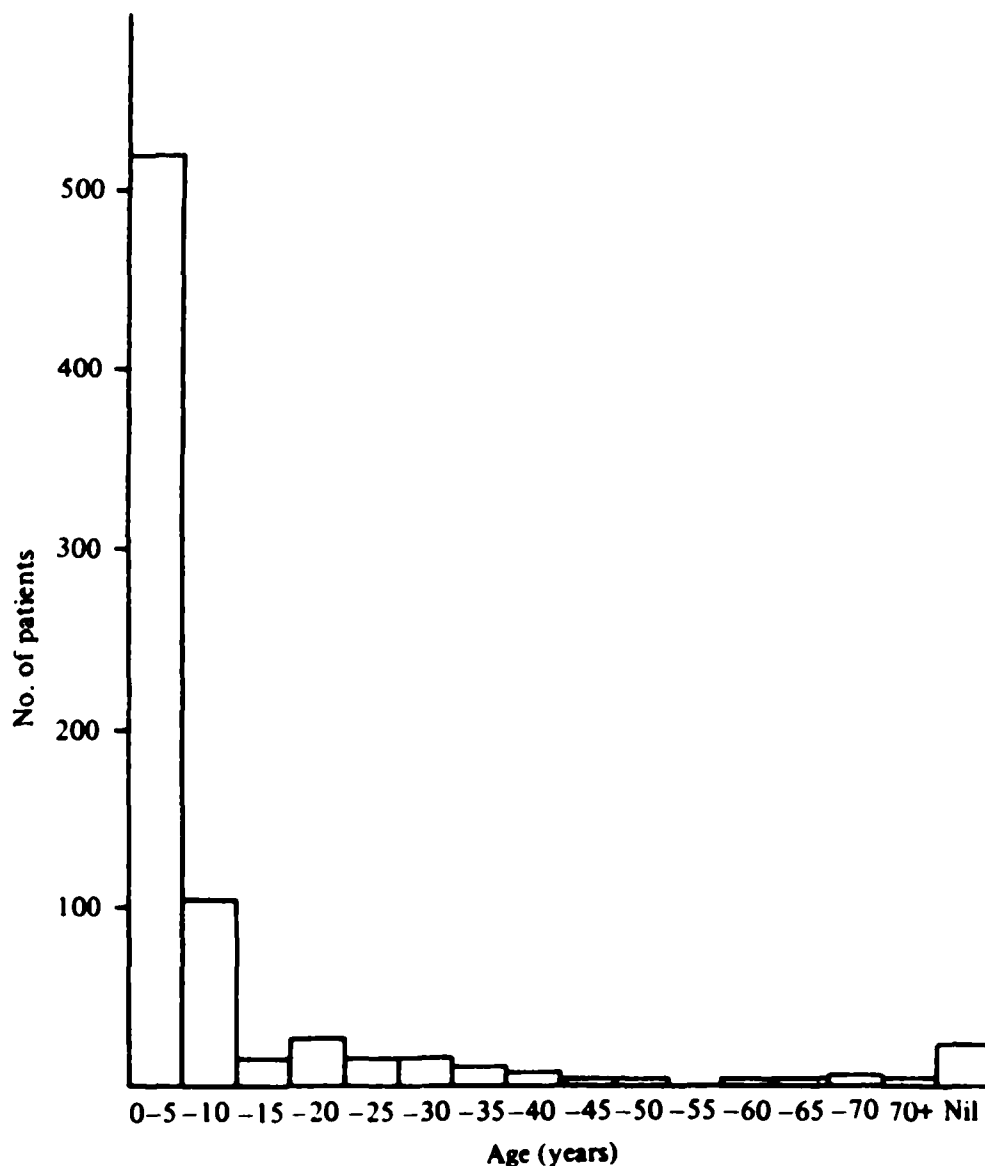


Fig. 2. Age distribution of patients with other clinical syndromes.

while seven isolates of adenovirus type 22 were made in 1974. A few adenovirus isolates could not be typed and types 9, 26, 29 and 31 were isolated sporadically (Table 3).

#### *Age of patients*

A difference can be seen in the age incidence of patients with conjunctivitis as the main or only symptom (Fig. 1). Information regarding age of patients was available for 76 % of the eye specimens, and 88 % of these patients were over ten years. Patients with other clinical syndromes, whose age was known in 97 % of cases, were below ten years in 87 % of these (Fig. 2).

#### *Laboratory infection*

One case of kerato-conjunctivitis was presumably laboratory-acquired. At the height of the adenovirus 8 outbreak in 1977, an experienced virologist who had been routinely engaged in typing isolates for three months reported typical symptoms of kerato-conjunctivitis and conjunctival swabs were collected one day after onset. Clinical assessment confirmed characteristic signs of epidemic kerato-

conjunctivitis, which resolved completely after two weeks. Adenovirus type 8 was isolated from swabs and paired acute and convalescent sera, collected 15 days apart, showed a rising titre (16 to 64) by complement fixation to adenovirus group antigen and by neutralization test to adenovirus type 8 (< 4 to 32).

Fourteen days after the virologist had developed symptoms, a household contact noted slight itchiness of both eyes. Conjunctival swabs were taken and adenovirus type 8 isolated. Apart from the initial minor irritation, there were no other symptoms or signs and medical evaluation was not sought.

#### *Virus isolation in cell cultures*

The most sensitive cells for isolation of adenovirus type 8 and type 19 were HEL, although cytopathic effect was slow to appear. Of the adenovirus type 8 isolations 41 % were made in HeLa and 90 % in HEL cells but the mean time taken for CPE to appear was 17 and 25 days respectively. Of adenovirus type 19 isolated, 65 % were recovered from HeLa and 96 % from HEL cells, while time for CPE to appear was 16 days in HeLa and 20 days in HEL.

### DISCUSSION

Isolations made from eye specimens received for viral studies showed that an outbreak of adenovirus type 8 kerato-conjunctivitis occurred in Melbourne in 1976–77. This was followed by an increase in adenovirus type 19 isolations from patients with kerato-conjunctivitis in 1978–79. Our findings indicate that the adenovirus type 19 outbreak, which is continuing, was sequential to rather than simultaneous with the adenovirus type 8 prevalence as has been reported in some overseas epidemics. Other adenovirus types 1, 3, 4, 7a, 15 and 29 have been associated with eye lesions in a sporadic manner during the eight years since an adenovirus type 4 outbreak in 1970–71.

As background to the outbreaks of eye infection, adenovirus types 1, 2, 3, 4, 5, 7a, 9, 22, 26, 29 and 31 have caused endemic respiratory infections, pharyngitis and fever or have been isolated inadvertently mainly from children under ten years. Conjunctivitis was presumably not a notable feature in all but 13 of these 735 patients as it did not warrant mention on pathology request forms and conjunctival swabs were not taken.

The clinical information provided with requests for viral isolations from patients with eye infections was disappointingly scant. While anecdotal reports of cross infection in three hospitals were received this was never documented and evidence of industrial exposure to dust or grit, contact with other cases of eye disease, previous visits for eye examination within the incubation period, family spread or other epidemiological information was almost impossible to elucidate in retrospect. Although several clusters of the same family name were noted and there were several isolations of adenovirus type 8 and adenovirus type 19 from patients who were known to be members of the medical or nursing professions, details to confirm that these represented instances of household or clinical cross-infection were not readily available. The laboratory and subsequent household spread of adeno-

virus type 8 infection illustrates that, although a high dose (as would be present in a laboratory culture) is necessary for transmission of the virus (Jawetz *et al.* 1958) infection can be acquired in a household situation in spite of routine care being taken by trained personnel.

In some cases ages of patients were not recorded but the older age group of patients with kerato-conjunctivitis due to adenovirus types 8 and 19 was apparent, agreeing with earlier observations (Dawson *et al.* 1960) that in western countries EK-C is a disease of adults, whereas in the Orient (Tanaka, 1957) children are commonly infected by adenovirus type 8 and suffer from systemic illness with fever and respiratory symptoms, as well as conjunctivitis but without keratitis.

It seems a pity that more detailed epidemiological information is not noted when the patient is first seen as, by the time these slow-growing viruses are isolated, it is difficult to elucidate many interesting and relevant facts. Initial awareness of the manner in which the infection is being spread would also help to contain an outbreak early in its course.

The authors wish to thank Miss V. Hunt for her collaboration in this survey, Mr R. Pringle for preparing the figures and Miss Loris Brenton for preparation of the manuscript.

#### REFERENCES

- BARNARD, D. L., DEAN-HART, J. C., MARMION, V. J. & CLARKE, S. K. R. (1973). Outbreak in Bristol of conjunctivitis caused by adenovirus type 8, and its epidemiology and control. *British Medical Journal* **2**, 165-9.
- BELL, J. A., ROWE, W. P., ENGLER, J. I., PARROTT, R. H. & HUEBNER, R. J. (1955). Pharyngo-conjunctival fever: epidemiological studies of a recently recognized disease entity. *Journal of the American Medical Association* **157**, 1083-92.
- BELL, S. D., ROTA, T. R. & MCCOMB, D. E. (1960). Adenovirus isolated from Saudi Arabia. III. Six new serotypes. *American Journal of Tropical Hygiene* **9**, 523-6.
- CALDWELL, G. G., LINDSEY, N. J., WULFF, H., DONNELLY, D. D. & BOHL, F. N. (1974). Epidemic of adenovirus type 7 acute conjunctivitis in swimmers. *American Journal of Epidemiology* **99**, 230-4.
- CENTRE FOR DISEASE CONTROL (1978a). Surveillance of nosocomial infections: adenovirus type 4 (pharyngoconjunctival fever). *Weekly Epidemiological Record* **53**, 79.
- CENTRE FOR DISEASE CONTROL (1978b). Adenovirus infections. *Weekly Epidemiological Record* **53**, 228.
- DAWSON, C. & DARELL, R. (1963). Infections due to adenovirus type 8 in the United States. I. An outbreak of epidemic kerato-conjunctivitis originating in a physician's office. *New England Journal of Medicine* **268**, 1031-4.
- DAWSON, C., DARELL, R. D., HANNA, L. & JAWETZ, E. (1963). Infections due to adenovirus type 8 in the United States. II. Community-wide infection with adenovirus type 8. *New England Journal of Medicine* **268**, 1034-7.
- DAWSON, C., JAWETZ, E., HANNA, L., WINN, W. E. T. & THOMPSON, C. (1960). A family outbreak of adenovirus 8 infection (epidemic kerato-conjunctivitis). *American Journal of Hygiene* **72**, 279-83.
- DONALDSON, A., LEWIS, F. A., KENNETT, M. L., WHITE, J. & GUST, I. D. (1978). The 1976 influenza epidemic in Melbourne. *Medical Journal of Australia* **2**, 45-9.
- DUXBURY, A. E., MCCUTCHAN, R., WHITE, J. & O'KEEFE, L. (1960). Epidemic adenovirus infection in a Victorian migrant centre presenting as pharyngo-conjunctival fever. *Medical Journal of Australia* **2**, 413-17.
- ELLIS, A. W., MCKINNON, G. T., LEWIS, F. A. & GUST, I. D. (1974). Adenovirus type 4 in Melbourne, 1969-71. *Medical Journal of Australia* **1**, 209-11.



- GUYER, B., O'DAY, D. M., HIERHOLZER, J. C. & SCHAFFNER, W. (1975). Epidemic keratoconjunctivitis: a community outbreak of mixed adenovirus type 8 and type 19 infection. *Journal of Infectious Diseases* **132**, 142-50.
- HIERHOLZER, J. C., GUYER, B., O'DAY, D. & SCHAFFNER, W. (1974) Adenovirus type 19 keratoconjunctivitis. *New England Journal of Medicine* **290**, 1436.
- HOGAN, M. & CRAWFORD, J. W. (1942). Epidemic keratoconjunctivitis. *American Journal of Ophthalmology* **25**, 1059-78.
- JAWETZ, E. (1959). The story of shipyard eye. *British Medical Journal* **1**, 873-6.
- JAWETZ, E., HANNA, L., NICHOLAS, A. & HOYT, R. (1958). Some biological characteristics of adenovirus type 8. *American Journal of Hygiene* **67**, 276-85.
- JAWETZ, E., HANNA, L., SONNE, M. & THYGESON, P. (1959). A laboratory infection with adenovirus type 8: laboratory and epidemiologic observations. *American Journal of Hygiene* **69**, 13-20.
- JAWETZ, E., KIMURA, S. J., HANNA, L., COLEMAN, V. R., THYGESON, P. & NICHOLAS, A. (1955). Studies on the etiology of epidemic keratoconjunctivitis. *American Journal of Ophthalmology* **40**, 200-9.
- KENNETT, M. L., ELLIS, A. W., LEWIS, F. A. & GUST, I. D. (1972). An epidemic associated with echovirus type 18. *Journal of Hygiene* **70**, 325-34.
- LAIBSON, P. R., ORTOLAN, G. & DUPRÉ-STRACHAN, S. (1968). Community and hospital outbreak of epidemic keratoconjunctivitis. *Archives of Ophthalmology* **80**, 467-73.
- LENNETTE, E. H. & SCHMIDT, N. J. (1969). *Diagnostic Procedures for viral and Rickettsial Infections*, 4th ed. New York: American Public Health Association Inc.
- LEWIS, F. A. & KENNETT, M. L. (1976). Comparison of rhinovirus-sensitive HeLa cells and human embryo fibroblasts for isolation of rhinoviruses from patients with respiratory disease. *Journal of Clinical Microbiology* **3**, 528-32.
- ROWE, W. P., HUEBNER, R. J., GILMORE, L. K., PARBOTT, R. N. & WARD, T. G. (1953). Isolation of cytopathogenic agent from human adenoids undergoing spontaneous degeneration in tissue culture. *Proceedings of Society of Experimental Biological Medicine* **84**, 570-3.
- SPRAGUE, J. B., HIERHOLZER, J. C., CURRIER, R. W., HATTWICK, M. A. W. & SMITH, M. D. (1973). Epidemic keratoconjunctivitis: a severe industrial outbreak due to adenovirus type 8. *New England Journal of Medicine* **289**, 1341-6.
- TANAKA, C. (1957). Epidemic keratoconjunctivitis in Japan and the Orient. *American Journal of Ophthalmology* **43**, 46-50.
- WEGMAN, D. H., GUINEE, V. F. & MILLIAN, S. J. (1970). Epidemic keratoconjunctivitis. *American Journal of Public Health* **60**, 1230-7.