

# Congenital Entrapment of the Lateral Cutaneous Nerve of the Calf Presenting as a Peroneal Sensory Neuropathy

Daniel G. Hackam and Thomas J. Zwimpfer

**ABSTRACT:** *Objective:* Presentation of an unusual case of congenital entrapment of the lateral cutaneous nerve of the calf (LCNC) mimicking a peroneal sensory neuropathy. *Methods:* We report the case of a 16-year-old girl with a 3 year history of progressive tingling, numbness and pain in her right calf precipitated by athletic activities involving repeated flexion and extension of the knee. A Tinel's sign was present over the common peroneal nerve in the distal popliteal fossa but absent at the fibular neck. Motor and sensory examination of the common peroneal nerve was normal as were electrophysiological studies and MRI. *Results:* At surgery, the LCNC, a sensory branch of the common peroneal nerve, was entrapped at a point where it pierced the tendon of the biceps femoris muscle. Transection of the part of the tendon overlying the LCNC resulted in complete and permanent relief of symptoms. *Significance and Conclusion:* The proximal location of the Tinel's sign, absence of motor or sensory deficits and normal electrophysiology suggested, preoperatively, that this was not an entrapment of the common peroneal nerve at the fibular neck but rather a more proximal abnormality likely involving only a part of the peroneal nerve or one of its sensory branches. As a result, more proximal exposure of the peroneal nerve within the popliteal fossa revealed entrapment of the LCNC due to its anomalous course through the biceps femoris tendon. This case has two noteworthy features. It is a unique example of an entrapment neuropathy of the common peroneal nerve or one of its branches, due to a normal nerve piercing an otherwise normal tendon. Secondly, there are no previously reported cases of surgically documented compression of the LCNC in an otherwise normal patient (i.e., non-diabetic).

**RÉSUMÉ:** Séquestration congénitale du nerf saphène externe du mollet dont la présentation clinique était celle d'une neuropathie sensitive péronière. *But:* Nous présentons un cas inusité de séquestration congénitale du nerf saphène externe (NSE) du mollet dont la symptomatologie simulait celle d'une neuropathie sensitive péronière. Nous rapportons le cas d'une jeune fille de 16 ans présentant depuis 3 ans une histoire progressive de picotements, d'engourdissements et de douleurs au mollet droit provoqués par l'activité sportive impliquant des mouvements de flexion et d'extension du genou. Un signe de Tinel était présent au niveau du nerf sciatique poplité externe dans le creux poplité distal, mais absent au niveau du col du péroné. L'examen sensitif et moteur du nerf sciatique poplité externe était normal ainsi que les études électrophysiologiques et la RMN. *Résultats:* À la chirurgie, le NSE, un rameau sensitif du nerf sciatique poplité externe, était séquestré à l'endroit où il traversait le tendon du biceps crural. La dissection transversale de la portion du tendon au-dessus du NSE a amené un soulagement complet et permanent des symptômes. *Signification et conclusion:* Avant la chirurgie, le site proximal du signe de Tinel, l'absence de déficit moteur ou sensitif et les études électrophysiologiques normales suggéraient qu'il ne s'agissait pas de la séquestration du nerf sciatique poplité externe au niveau du col du péroné mais bien d'une anomalie plus proximale impliquant probablement seulement une partie du nerf ou l'une de ses branches sensitives. Une exposition plus proximale de ce nerf dans le creux poplité a révélé une séquestration du NSE due à un trajet anormal à travers le tendon du biceps crural. Ce cas a deux caractéristiques dignes de mention. C'est un exemple unique d'une neuropathie de séquestration du nerf sciatique poplité externe ou d'une de ses branches due au trajet anormal d'un nerf normal traversant un tendon normal par ailleurs. Deuxièmement, il n'existe pas dans la littérature de cas de décompression du NSE documentée chirurgicalement chez un patient normal (c.-à-d. non diabétique).

Can. J. Neurol. Sci. 1998; 25: 168-170

Common peroneal nerve palsy at the level of the fibular neck is one of the most frequently reported mononeuropathies in the lower extremity.<sup>1</sup> Etiologies are diverse but traumatic injury and external compression are the most common causes. Here we describe an unusual case with an atypical presentation of a peroneal nerve palsy that involved congenital entrapment of the lateral cutaneous nerve of the calf (LCNC) at a point where it pierced the tendon of the biceps femoris muscle. All symptoms resolved with release of the LCNC.

## CASE SUMMARY

A 16-year-old girl presented with a three year history of progressive pain and tingling over the lateral aspect of her right calf, which extended from her knee to the lower third of the leg but did not involve her

foot or toes. This occurred primarily with activities involving repeated flexion and extension of the knee and required her to limit her involvement in soccer, skating and skiing. She did not notice any leg weakness but did describe transient numbness, lasting several minutes, over the upper and lateral aspect of the right calf with strenuous or prolonged physical activity. There was no history of trauma and no family history of any neurological disorders.

On examination, there were no cutaneous manifestations of Type I neurofibromatosis. No muscle atrophy, weakness, reflex abnormality or sensory changes were detected. A positive Tinel's sign was elicited over

From the Division of Neurosurgery, University of British Columbia, Vancouver, Canada.

RECEIVED AUGUST 6, 1997. ACCEPTED IN FINAL FORM NOVEMBER 6, 1997.

Reprint requests to: Thomas Zwimpfer, Suite 300, C Floor, 700 West 10th Avenue, Vancouver, British Columbia, Canada V5Z 4E5

the common peroneal nerve in the distal part of the popliteal fossa, just posterior to the tendon of the biceps femoris muscle. No Tinel's sign was present over the fibular neck. Nerve conduction studies of the common peroneal nerve revealed no conduction delay across the fibular neck and no significant difference in action potential amplitude when compared to the opposite leg. Electromyography of the tibialis anterior muscle demonstrated no denervation and only occasional polyphasic motor units. MRI revealed no abnormalities along the path of the common peroneal nerve and no atrophy or signal changes in the leg musculature.

These clinical features, together with the lack of electrophysiological abnormalities, suggested that this was not an entrapment of the common peroneal nerve at the fibular neck but a more proximal abnormality within the popliteal fossa, likely involving only a part of the peroneal nerve or one of its sensory branches. As a result, at the time of surgery, the common peroneal nerve was exposed more proximally than for a typical common peroneal nerve palsy. It was exposed from within the popliteal fossa down to its passage under the peroneus longus muscle, where it divided normally into the deep and superficial peroneal nerves. No abnormalities or entrapment of the common, deep or superficial peroneal nerves were found. However, a 3 mm diameter nerve that originated from the common peroneal nerve in the distal popliteal fossa was found to pierce the biceps femoris tendon (Figure (A)). This appeared to be a congenital anomaly given the discrete separation in the tendon through which the nerve passed and the absence of any scar around the nerve at this site. The biceps femoris tendon appeared otherwise normal. This nerve then penetrated the deep fascia of the calf at the level of the fibular head to enter the subcutaneous tissue. The origin and course of this nerve was consistent with it being the LCNC and would also explain the patient's pain, tingling and numbness being restricted to the proximal part of the lateral calf.

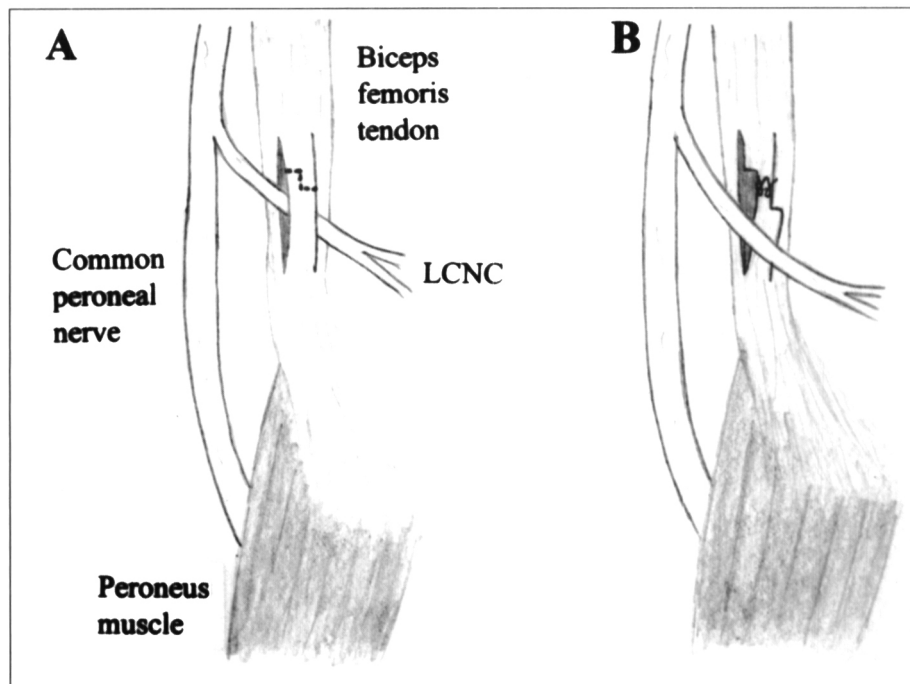
The portion of the biceps femoris tendon overlying the LCNC was transected proximal to the nerve using a Z-shaped incision (Figure (B)), which allowed the nerve to be completely mobilized. The transected portion of the tendon, which represented about 20% of the total cross-sectional area of the biceps tendon, was repaired with a Z-plasty (Figure (B)).

On follow-up, all symptoms had completely resolved and she was able to resume all athletic activities without restriction. She remains asymptomatic one year postoperatively.

## DISCUSSION

The differential diagnosis of leg pain and/or paraesthesia with exercise is quite broad and includes tibial stress fractures, compartment syndromes, periostitis, shin splints (deep medial tibial syndrome) and vascular insufficiency.<sup>2</sup> A study by Mitra et al. implicated peroneal nerve entrapment secondary to chronic muscular swelling and hypertrophy as another cause of exertional leg pain.<sup>2</sup> This is confirmed by Kim et al., who found that 55% of patients with suspected peroneal nerve entrapment were longtime runners.<sup>3</sup>

Because it is subcutaneous, relatively fixed in place and directly overlies the neck of the fibula, the common peroneal nerve is susceptible to injury or compression at this site.<sup>4</sup> Compression by the peroneus longus muscle at the point where the nerve passes between the fascial origin of the peroneus longus and the underlying fibular neck, is the most likely cause of entrapment in competitive athletes and runners.<sup>2</sup> These patients generally present with pain, tingling and numbness over the lateral aspect of the calf and dorsum of the foot, which is brought on or exacerbated by activity.<sup>5</sup> Weakness of ankle dorsiflexion and extension of the toes, atrophy of the anterior compartment muscles, a positive Tinel's sign at the level of the fibular neck and a variable area of altered sensation over the lateral calf and dorsum of the foot are common clinical findings. Electrophysiological studies in the usual peroneal nerve palsy often demonstrate slowing of nerve conduction or a conduction block across



**Figure:** Diagrams of intraoperative findings and procedure. A) The lateral cutaneous nerve of the calf (LCNC) originated from the common peroneal nerve and was entrapped at a point where it pierced the biceps femoris tendon. The portion of the tendon overlying the LCNC was transected proximal to the nerve using a Z-shaped incision (hatched line). B) Following transection of the tendon, the LCNC could be completely mobilized and the transected portion of the tendon was repaired using a Z-plasty.

the fibular neck and in more severe cases, exhibit acute and chronic denervation in anterior compartment muscles.

The presence of a more proximal Tinel's sign (i.e., within the distal popliteal fossa), together with the lack of motor or sensory deficits and the absence of slowing of nerve conduction across the fibular neck, suggested that this case did not involve entrapment of the common peroneal nerve at the fibular neck. The location of the Tinel's sign indicated more proximal involvement within the distal popliteal fossa, while the absence of clinical and electrophysiological findings suggested involvement of only a part of the common peroneal nerve or one of its sensory branches. In this patient, exploration and decompression of the common peroneal nerve only at the level of the fibular neck and under the *peroneus longus* muscle would have failed to detect the more proximal congenital anomaly involving the LCNC and would not have relieved her symptoms.

The LCNC consists of sensory axons from L4, L5 and S1, and supplies the proximal two-thirds of the lateral aspect of the lower leg.<sup>6</sup> The location and size of sensory supply of this nerve varies inversely with that of the posterior femoral cutaneous nerve and sural nerve. This variability likely accounts for the lack of a sensory deficit in our patient. In cadaver studies, the LCNC originates from either the lateral sural nerve (85%) or the common peroneal nerve (15%) and pierces the deep fascia just posterior to the fibular head to enter the subcutaneous space.<sup>7</sup> This fascia has been postulated to be a potential site of entrapment of the LCNC or the lateral sural nerve, presumably from narrowing of a congenitally small fascial opening, especially with knee extension.<sup>7,8</sup> Neither anatomical studies nor clinical reports have demonstrated the LCNC (or any branch of the common peroneal nerve) to pierce a normal tendon.

The clinical findings in our case closely resemble those found in the peroneal sensory neuropathy entrapment syndrome described by Haimovici in 1972.<sup>8</sup> He described a pain syndrome involving the lateral aspect of the leg and posterior aspect of the knee that occurs primarily in females in the fifth and sixth decade of life. It is further characterized by the absence of motor symptoms or signs, minimal sensory changes (mainly hyperesthesia) and localized tenderness and a positive Tinel's sign over the common peroneal nerve at the level of the popliteal fossa.<sup>8</sup> Haimovici postulated that this syndrome is due to entrapment of the LCNC or the lateral sural nerve at the site where they pierce the deep fascia.<sup>8</sup> However, but this is not demonstrated in his study as no patients underwent surgical exploration since all improved with injections of local anesthetic. In addition, no electrophysiological studies were done in these patients to rule out the possibility of a mild common peroneal neuropathy at the fibular neck and no

information was provided concerning the possibility of diabetes.

There are only two reported cases of proven LCNC palsy, both occurring in diabetics.<sup>9,10</sup> This suggests that the deep fascia exerts only minimal pressure on the LCNC and is probably clinically significant only in patients known to be susceptible to nerve compression, such as diabetics. In our case, the main site of entrapment of the LCNC appeared to be where the nerve pierced the biceps femoris tendon but it is possible that additional compression of the nerve occurred at the deep fascia due to increased tension in the LCNC caused by its anomalous path. The deep fascia was cut in the process of following the distal course of the LCNC.

This case demonstrates two noteworthy features. Although compression of the common peroneal nerve by congenital fascial bands has been reported previously,<sup>11,12</sup> this is a unique example of an entrapment neuropathy of the common peroneal nerve or one of its branches, due to a normal nerve piercing an otherwise normal tendon. Secondly, there are no previously reported cases of surgically documented compression of the LCNC in an otherwise normal patient (i.e., non-diabetic).

## REFERENCES

1. Mont MA, Dellon AL, Chen F, et al. The operative treatment of peroneal nerve palsy. *J Bone and Joint Surg* 1996; 78A: 863-869.
2. Mitra AM, Stern JD, Perrotta VJ, Moyer RA. Peroneal nerve entrapment in athletes. *Ann Plast Surg* 1995; 35: 366-368.
3. Kim DH, Kline DG. Management and results of peroneal nerve lesions. *Neurosurgery* 1996; 39: 312-320.
4. Muhammed N, Campbell P, Smith IS. Peripheral nerve entrapment syndromes: diagnosis and management. *Br J Hosp Med* 1995; 53: 141-146.
5. Katirji MB, Wilbourn AJ. Common peroneal mononeuropathy: a clinical and electrophysiologic study of 116 lesions. *Neurology* 1988; 38: 1723-1728.
6. Romanes GJ. The peripheral nervous system. *In: Romanes GJ, ed. Cunningham's Textbook of Anatomy.* Oxford: Oxford University Press, 1981: 739-826.
7. Coert JH, Dellon AL. Clinical implications of the surgical anatomy of the sural nerve. *Plast Reconstr Surg* 1994; 94: 850-855.
8. Haimovici H. Peroneal sensory neuropathy entrapment syndrome. *Arch Surg* 1972; 105: 586-590.
9. Finelli PF, DiBenedetto M. Bilateral involvement of the lateral cutaneous nerve of the calf in a diabetic. *Ann Neurol* 1978; 4: 480-481.
10. Gessini L, Jandolo B, Pascucci P, Pietrangeli A. Diabetic neuropathy of the lateral cutaneous nerve of the calf. A case report. *Ital Neurol Sci* 1985; 6: 107-108.
11. Brown RE, Storm BW. "Congenital" common peroneal nerve compression. *Ann Plast Surg* 1994; 33: 326-329.
12. Jones HR Jr, Felice KJ, Gross PT. Pediatric peroneal mononeuropathy: a clinical and electromyographic study. *Muscle Nerve* 1993; 16: 1167-1173.