

Experimental protein-energy malnutrition in baby baboons

Attempts to reproduce the pathological features of kwashiorkor as seen in Uganda

BY DOROTHY G. COWARD AND R. G. WHITEHEAD

*Medical Research Council Child Nutrition Unit,
PO Box 6717, Kampala, Uganda*

(Received 13 October 1971 – Accepted 21 February 1972)

1. The object of this investigation was to produce an animal model of kwashiorkor like that seen in Ugandan children.
2. In the initial studies the baby baboons were weaned at 8–10 weeks of age and given a full-cream milk diet for 2 weeks. The milk intake was then gradually reduced and local staples with a low-protein, high-carbohydrate content were provided instead. Maintaining the baby baboons for as long as 100 d on this diet markedly impaired body growth but it did not result in a 'kwashiorkor-like' appearance.
3. Subsequent stressing of the animals by the introduction of periods of energy restriction did apparently precipitate them into a clinical condition in many ways reminiscent of kwashiorkor. The baboons exhibited extreme mental apathy, and had sparse hair, oedema of the limbs and face, and skin lesions similar to the flaky-paint rash found in severely malnourished children, but there was no gross accumulation of fat in the liver.
4. The basal diet was subsequently modified by the addition of sucrose to bring the carbohydrate composition more into line with that in food eaten by local Ugandan children. This relatively minor change seemed to cause a more rapid clinical deterioration and the animals did develop fatty livers as well as the other pathological changes.
5. The final condition resembled marasmic kwashiorkor and further modification to the experimental design is required if an animal model truly representative of the more typical Ugandan type of kwashiorkor is to be reproduced.

An animal model is essential for investigations into the metabolic and structural changes which accompany the development of malnutrition and which ultimately result in severe kwashiorkor. This is particularly so when serial tissue biopsies are required for sequential cellular studies. Previous animal investigations by this research team were carried out on young rats and pigs, but the relevance of our results to the pathogenesis of the malnourished child was in doubt since a clinical state which looked like kwashiorkor never appeared.

One theoretical limitation to the use of the rat and the pig is that these and most other mammals grow relatively more quickly than man, who has a very long juvenile period between weaning and puberty (Evans & Miller, 1968). It is almost impossible to introduce chronic malnutrition at a developmental stage equivalent to that in the preschool child. The onset of puberty can complicate the interpretation of nutritional and metabolic findings in such animals (Grimble, Sawyer & Whitehead, 1969; Grimble & Whitehead, 1969; Whitehead & Coward, 1969). The closer relationship between the growth patterns of the higher primates and man and the results of previous nutritional studies in various monkeys (Follis, 1957; Deo, Sood & Ramalingaswami, 1965; Ordy, Samorajski, Zimmerman & Rady, 1966; Racela,

Grady, Higginson & Svoboda, 1966) indicated that the baboon, a common local animal in Uganda, might provide a more realistic model.

We decided that for our particular needs an animal model could only be considered suitable if a pathological state eventually developed that resembled kwashiorkor so closely that an experienced paediatrician would have no difficulty in diagnosing the condition. The principal features of kwashiorkor in Uganda are oedema, failure of growth, sparse light-coloured hair, wasted muscles, pallor of the skin which sometimes shows a flaky-paint dermatosis, a fatty liver and gross misery (Dean & Jelliffe, 1960). The main aim of this investigation was to devise a system for producing these signs in the animal model.

It was also thought important that the pathological changes should be produced under dietary circumstances as similar as possible to those of the Ugandan child who gets kwashiorkor. Parallel with this investigation in baboons, a prospective longitudinal study was started to characterize the essential environmental factors associated with malnutrition in Uganda. Changes, based on this information, were gradually incorporated into the original experimental dietary schedule.

METHODS

Breeding colony

The breeding colony consists of one adult male Ugandan baboon (*Papio 'doguera'*), six females of the same subspecies and five females of the Kenyan variety (*P. 'cynocephalus'*). The colony is housed in four large concrete-floored interconnecting open-air cages. The adults receive a diet of locally available foods, chickwheat, groundnuts, sweet potatoes and fruit.

This paper describes experiments carried out on the first eight baboons (numbered B 1–B 8) who were born in the primate house. B 1 and B 7, both males, and B 4 and B 5, females, had *P. 'cynocephalus'* mothers; B 2, B 3 and B 6, all females, and B 8, a male, had *P. 'doguera'* mothers. B 3 and B 5 were used as control animals and the remainder were fed on low-protein diets. The babies were weaned at 8–10 weeks of age and were then caged individually in a separate room.

Dietary regimens

After weaning, all the animals except B 3 were fed on a full-cream milk diet for the first 2 weeks; B 3 did not like milk and was given a comparable amount of egg. The milk diet was one of those used in our ward for the treatment of malnourished children and contained 12.5 g protein and 603 kcal (2.52 MJ) energy/100 g of dry powder. The controls were provided with these high-protein foods throughout the study. For animals destined to become malnourished, the milk was gradually replaced by diets based on local staples with a low-protein, high-carbohydrate content; these were banana (*Musa sapientum* L.), peeled and cooked matooke (*Musa paradisiaca* L.) and cassava (*Manihot esculentus* Crantz). In addition, each animal received daily a minimum of 33 g paw-paw (*Carica papaya* L.).

Since the investigation was to a large extent an exploratory one, the exact dietary

regimen was varied for the different animals (see Figs 1-5). It was found that the *ad lib.* feeding of mixed staples alone did not directly result in the appearance of a kwashiorkor-like state. Various modifications were therefore made to this basal diet in an attempt to induce the required clinical condition. Initially, the total protein content of the diet was reduced by feeding only cassava which has an even lower protein and higher carbohydrate content than the other staples. The results from a parallel longitudinal study in children had alerted us to the possible importance of periodic energy deprivation, associated with episodes of infection in the aetiology of malnutrition in Ugandan children. Since it was considered important that the animals should be subjected to the same type of dietary stress as the children, the food intake of some of the baboons was restricted over certain periods to simulate this condition experimentally. A further factor which emerged from the food consumption studies in children was that they were drinking quite substantial amounts of very sweet tea; during periods of infection this was often their only source of food. The diet of other baboons was therefore modified to bring it more into line with that of the poorly fed child by adding sucrose to the diet so that it constituted about 20% of the total energy intake. This was achieved by providing the animals with a banana-sugar mixture 180-30 (w/w), together with the staples.

The changes in protein and energy intakes which the different regimens produced were calculated from analyses carried out in this laboratory (I. H. E. Rutishauser unpublished results). The vitamin contents of the foods were calculated from the values of Platt (1962).

Measurements

The progress of the animals was followed in a variety of ways. Weights were measured at least every 7 d. Blood samples were collected by venepuncture under 1-phenylcyclohexyl piperidine monochloride sedation (Sernylan: Parke, Davis and Co., Hounslow, Middlesex) about every 2 weeks and various body measurements were taken at these times. Serial liver and skin biopsies were performed at less frequent intervals on both the experimental and control animals. The liver samples were obtained by open biopsy, the abdominal incisions being made to the right of the midline. The biopsies were taken under Sernylan anaesthesia, as used by Howard & Gresham (1966) and Hoffbauer, Zaki & Hitchcock (1965); when necessary it was supplemented with diethyl ether, as suggested by Vice & Rodriguez (1965). In agreement with Howard & Gresham (1966) we found that young baboons required a larger dose than adult animals; the dose used for sedation for blood sampling was 1.5 mg/kg body-weight and that for complete anaesthesia, during biopsies, 2.5 mg/kg body-weight.

Serum albumin was estimated by a micro-automated technique based on the dye-binding of albumin with 2-(4-hydroxyazobenzene)-benzoic acid (Coward, Sawyer & Whitehead, 1971). Dye-binding capacity of albumin varies in different species and the values for the baboons were calculated after standardization of the technique against values obtained from cellulose acetate electrophoresis.

RESULTS

Control animals

The control animals (B 3 and B 5) grew well throughout the period of study, the average rate over the whole period being 7.2 g/d. Their appetites were good and the mean protein and energy intakes/d were 6.1 g/kg body-weight and 290 kcal (1.21 MJ)/kg body-weight respectively. Serum albumin concentrations were maintained at an average value of 4.05 g/100 ml (range 3.15–4.99 g/100 ml). The general appearance is shown in Pl. 1a).

Malnourished animals

General clinical condition. Clinical deterioration was similar in all experimental animals but there were differences in the length of time spent at any one stage. The baby baboons grew well while on *ad lib.* full-cream milk at an average rate of 11.4 g/d. They were active and their coats were thick, shiny and lay flat over the body. The general pattern of change after the introduction of the deficient diets was as follows. The hair gradually appeared more sparse and the animals became thinner and quieter, adopting a more hunched posture. Pressure sores then developed on the buttocks and small red skin lesions were observed in the groins which gradually spread over the abdomen and up arms and legs. Slight oedema of the upper eyelids, jowls, genitalia and buttocks was subsequently observed but at first only intermittently. There was no diarrhoea in the experimental animals but, in Uganda, diarrhoea is not the pre-eminent factor which precipitates a child into kwashiorkor as it seems to be in other countries; in Uganda a much broader spectrum of infections is involved.

These changes took place over a period of months but the final deterioration into the kwashiorkor-like state (Pl. 1b) was rapid. The animals quite suddenly exhibited extreme apathy and anorexia; a persistent body tremor was also observed. Marked oedema appeared in the face, wrists, feet, buttocks and tail. Skin lesions, reminiscent of the flaky-paint dermatosis seen in malnourished Ugandan children, were present in the groins and on the face (Pl. 1c) and buttocks (Pl. 2), and the pressure sores seen, in this region had now become large and deep. The general appearance of these skin lesions was very similar to that illustrated in the WHO monograph no. 53 (Jelliffe, 1966). Initially the skin just appeared red but later it started to peel and ultimately became hyperpigmented. This feature is clearly seen in Pl. 2: the face also took on an unusual black colour (Pl. 1b). On the hands the combination of oedema and abnormal skin led to the formation of wet skin lesions.

The dietary regimens adopted did result in important differences in detailed pathological response and for this reason each animal must be considered separately.

B 1 (Fig. 1). The period over which milk was progressively restricted was associated with a decrease in protein intake, a fall in serum albumin concentration and a decline in the rate of growth. During the period on *ad lib.* staples, body-weight fell continuously and there was some further deterioration in serum albumin but the concentration finally levelled off at around 1.8 g/100 ml. Although by day 181 the animal looked pale and had had sparse light-coloured hair for some time, there were none of the

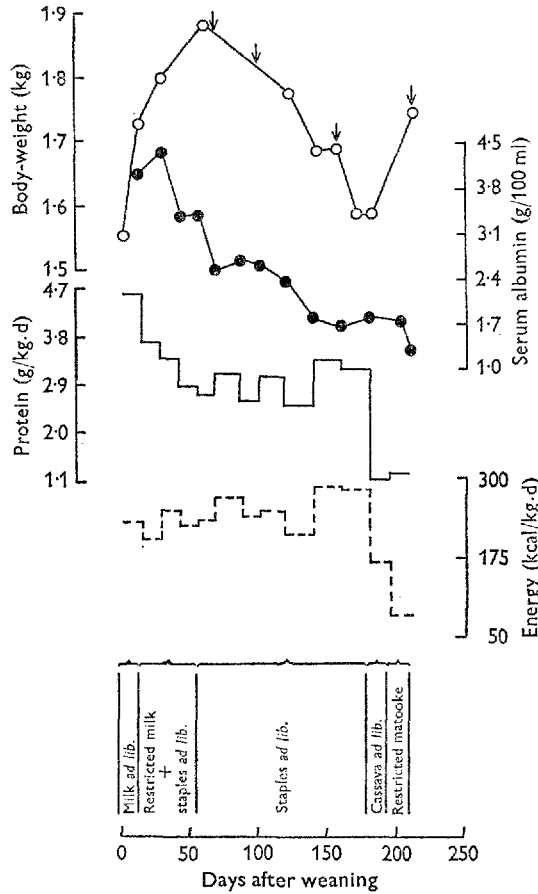


Fig. 1. The dietary regimen and changes in protein and energy intakes, body-weight and serum albumin concentration in baboon B 1 given diets of low-protein staples. O, body-weight; ●, serum albumin; —, protein intake; ---, energy intake; ↓, d of biopsy.

more gross pathological signs of clinical kwashiorkor such as pitting oedema. A lower protein intake produced by feeding just cassava had no effect on the serum albumin concentration, nor apparently on the general clinical condition of the animal.

The total energy intake was then drastically reduced to simulate an anorexic episode by providing only matooke in restricted amounts. This final stress was apparently associated with a distinct fall in serum albumin concentration and the rapid appearance of a kwashiorkor-like state. Though many features of human kwashiorkor had been reproduced in this animal, the liver biopsy sample taken at this stage did not appear very fatty and this was confirmed by subsequent light and electron-microscopy (Patrick, Mackay, Coward and Whitehead, in preparation) as well as chemical analysis (W. A. Coward, in preparation).

B 2 (Fig. 2). The initial phases of the dietary schedule of B 2 were similar to those of B 1. However, the serum albumin concentration did not fall as quickly and the weight loss was not so marked.

Unlike B 1, the provision of restricted amounts of matooke was not associated

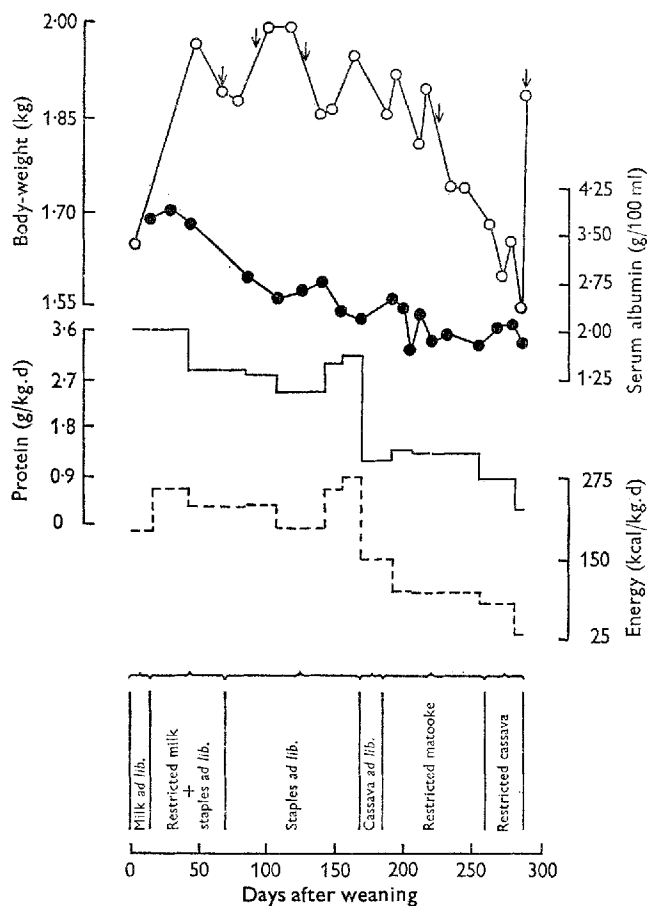


Fig. 2. The dietary regimen and changes in protein and energy intakes, body-weight and serum albumin concentration in baboon B 2 given diets of low-protein staples. ○, body-weight; ●, serum albumin; —, protein intake; ---, energy intake; ↓, d of biopsy.

with any very obvious decline in clinical condition although a trace of oedema, often of a transient nature, was suspected in the face and around the anus during this period and there was further deterioration in the hair and skin. The serum albumin concentration became only marginally lower over this 76 d period.

The increased nutritional stress resulting from the restricted feeding of cassava did, however, produce the required decline in clinical condition. The animal became very weak and hunched and the marginal oedema suddenly became more marked, especially in the face (Pl. 3a). There was a loss of appetite and the animal collapsed on day 282.

Because both hypoglycaemia and dehydration were suspected, the animal was resuscitated by the oral administration of a solution containing 25 g glucose, 61 mequiv. sodium and 17.5 mequiv. potassium/l. The animal apparently responded well and the treatment was repeated the next day. However, 24 h later oedema had appeared all over the body and by day 288 it was grotesque, especially in the face

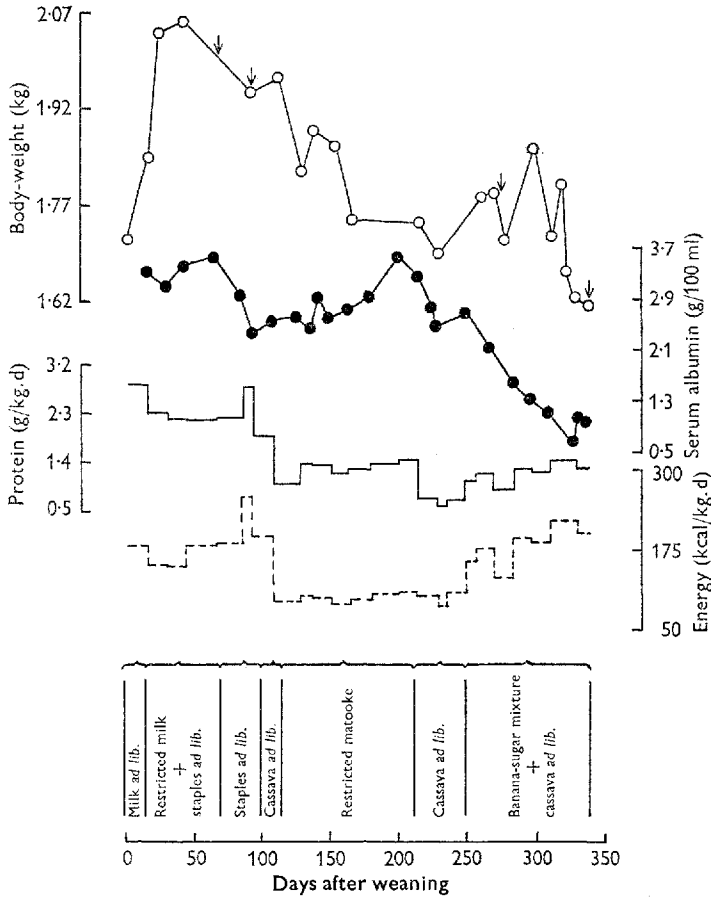


Fig. 3. The dietary regimen and changes in protein and energy intakes, body-weight and serum albumin concentration in baboon B 4 given diets of low-protein staples supplemented with sucrose after day 248. ○, body-weight; ●, serum albumin; —, protein intake; ---, energy intake; ↓, d of biopsy.

(Pl. 3*b*). The onset of oedema was reflected in a sharp increase in body-weight. A final liver biopsy was performed at this time and examination of the specimen again indicated that fatty infiltration was only minimal.

B 4 (Fig. 3). The restriction of food intake was started at a much earlier stage in this animal, but despite this and the fall in body-weight the serum albumin concentration actually began to rise again, ultimately reaching normal levels. The metabolic implications behind this response will be discussed in a subsequent paper (Coward, Coward and Whitehead, in preparation). A further fall in protein intake, associated with feeding cassava, did result in an initial fall in albumin concentration but values levelled off at about 2.5 g/100 ml. There were still no specific signs of severe kwashiorkor.

Surprisingly, the relatively minor dietary change of adding sucrose to the diet so that it constituted about 20% of the total energy intake was associated with an immediate fall in albumin concentration eventually to 1 g/100 ml, a value quite commonly

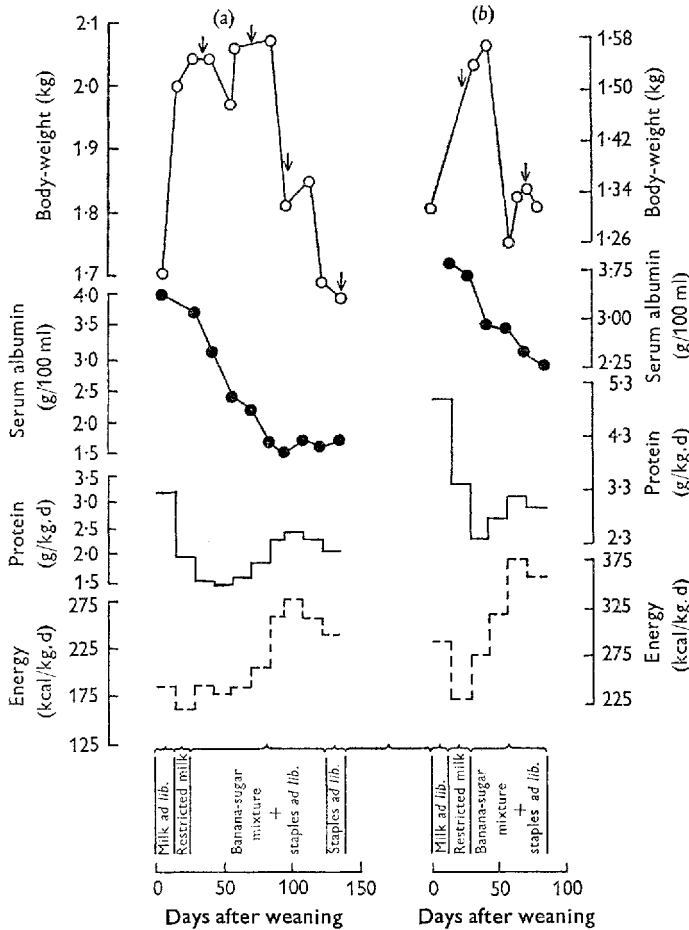


Fig. 4. The dietary regimens and changes in protein and energy intakes, body-weight and serum albumin concentration in two baboons given diets of low-protein staples supplemented with sucrose from the onset of protein deprivation. (a) baboon B 6; (b) baboon B 7. \circ , body-weight; \bullet , serum albumin; —, protein intake; ---, energy intake; \downarrow , d of biopsy.

found in severely malnourished Ugandan children but considerably lower than that which had been reproduced in the first two baboons. The kwashiorkor-like state was reached 6 weeks after making the sucrose addition. A liver biopsy was performed and this time the specimen was very pale and fatty. The animal did not recover.

B 6, B 7 and B 8 (Figs 4 and 5). The apparently dramatic effect of sucrose on serum albumin concentration and liver fat accumulation led us to repeat the modified regimen on a further three animals. Serum albumin concentrations in B 6 and B 7 did fall much more rapidly than in the baboons previously malnourished (Fig. 4). In B 8 the albumin concentration also fell quickly (Fig. 5) but, possibly because of a larger appetite and hence greater protein intake, the fall was not quite as rapid as in B 6 and B 7.

The appearance of the serial liver samples obtained by biopsy also showed that fatty infiltration was occurring at an earlier stage and to a more marked degree. In all

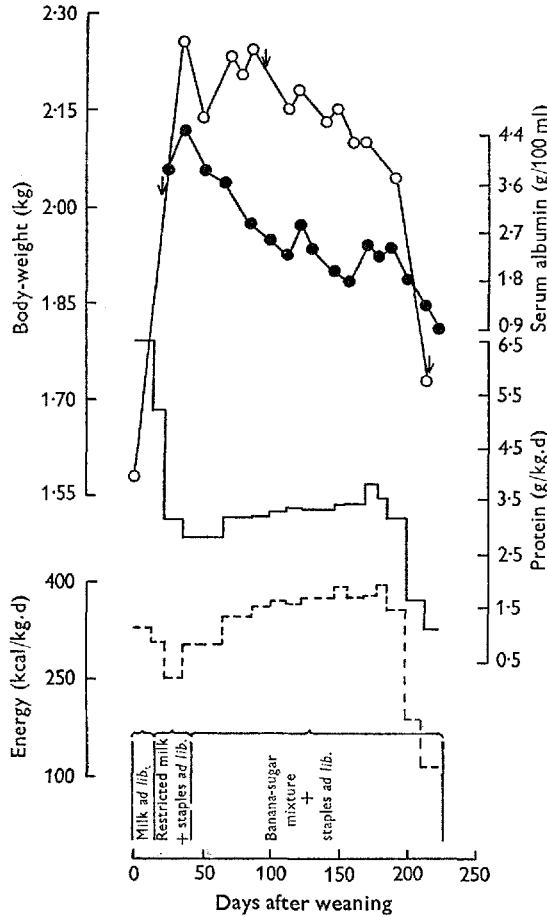


Fig. 5. The dietary regimen and changes in protein and energy intake, body-weight and serum albumin concentration in baboon B 8 given diets of low-protein staples supplemented with sucrose from the onset of protein deprivation. ○, body-weight; ●, serum albumin; —, protein intake; ---, energy intake; ↓, d of biopsy.

three animals the second biopsy liver samples taken only 42–53 d after introducing the banana–sucrose mixture were pale in appearance and microscopy and chemical analysis revealed excessive fat in the hepatocytes.

In B 6 the general clinical status also deteriorated rapidly. Changes in skin and hair were noted from day 81 and oedema was present from day 122. Unexpectedly the animal did not recover from a fourth biopsy performed on day 144 and therefore an extreme kwashiorkor-like state was not able to develop.

B 7 also died unexpectedly, but at an earlier stage, on day 83 when he was under sedation for routine blood sampling. The sudden deaths of B 6 and B 7 indicated that their fatty livers might be making them less tolerant to Sernylan, although in the normal baboon the tolerance to this anaesthetic is in fact very great (Howard & Gresham, 1966). In B 7 malnutrition had not been prolonged and therefore the animal did not show any clinical signs of abnormality other than body wasting, hypoalbuminaemia and a fatty liver.

Deterioration in the clinical state of B 8 followed approximately the same time pattern as in B 6. There was a marked drop in appetite from day 198 and once again the sudden fall in total energy intake led to the decline of the baboon into a kwashiorkor-like state. There were small ulcers over the tongue and entire inside surface of the mouth; the skin lesions on the buttocks and tail became infected with β haemolytic streptococci. It is possible that these infections were related to the loss of appetite. A third biopsy was performed on day 223 but the animal did not recover.

Vitamin intake

Whenever children or animals are eating a narrow range of foodstuffs in limited quantities, there is always a possibility of associated vitamin deficiencies. In this investigation it was particularly important to consider whether or not any of the clinical abnormalities, in particular the skin lesions, were likely to have been due to vitamin rather than just protein and energy deficiencies. The role of vitamin deficiencies in the development of skin lesions in baboons has been extensively studied by Foy, Kondi & Mbaya (1964). Since the object of this experiment was to reproduce the dietary stresses of the Ugandan child rather than to study simple primary protein malnutrition, no separate vitamin additions were given except for vitamin D; this was because the young animals were caged separately in a room out of direct sunlight. The diets were supplemented with crushed Dumocalcin tablets (Dumex Ltd, Copenhagen) to provide 2.5 μ g cholecalciferol/kg body-weight daily.

The intakes of vitamin A, thiamin, riboflavin, nicotinamide and ascorbic acid are given in Table 1. The units chosen are those recommended by the Panel on Recommended Allowances of Nutrients (1969). Riboflavin and nicotinamide are expressed/resting Mcal of energy expenditure per d which reflects the metabolic body size or cell mass. Resting metabolic rates are not yet available for baby baboons and a value has been estimated from the formula of Evans & Miller (1968): resting metabolic rate = $70 W^{0.75}$ kcal/d, where W is the body-weight in kg.

There is no factual information on the vitamin requirements of growing baby baboons and therefore the values can only be compared with those recommended for human infants (Panel on Recommended Allowances of Nutrients, 1969). These values are also given in Table 1.

In general, the recommended intakes were maintained throughout the study, although there were possible deficiencies of nicotinamide during the terminal stages in animals living basically on cassava and of riboflavin during periods when energy intake was restricted. However, it can be argued that the animals were no more lacking in these vitamins than they were in protein and energy at these times.

DISCUSSION

The literature reveals that even in primates it has been exceedingly difficult to produce a convincing animal model of kwashiorkor. Follis (1957) observed oedema in only one of his eight experimental animals (*Cercopithecus griseoviridis*) and this was confined to the periorbital region and to around the external genitalia. No skin lesions

Table 1. Dietary schedules and calculated average daily vitamin intakes* in six baby baboons (B 1, B 2, B 4, B 6, B 7 and B 8) given different low-protein diets and in two others (B 3 and B 5) given a more adequate intake

Diet	Baboon no.						Calculated average daily vitamin intakes				
	B 1	B 2	B 3	B 4	B 7	B 8	Vitamin A (μ g retinol/ kg body-wt)	Thiamin (mg/Mcal food)	Riboflavin (mg/resting Mcal)	Nicotinic acid (mg equivalent/ resting Mcal)	Ascorbic acid (mg/kg body-wt)
Milk <i>ad lib.</i> plus staples†	0-13	0-13	0-13	0-13	0-13	0-13	83	0.35	3.1	11	14
Milk gradually restricted											
plus staples† <i>ad lib.</i>	14-56	14-69	14-71	14-25	14-27	14-40	72	0.38	2.1	18	24
Staples† <i>ad lib.</i>	57-182	70-169	72-98	—	—	—	105	0.43	1.7	25	36
Cassava <i>ad lib.</i>	183-197	170-185	99-114	—	—	—	82	0.35	0.6	11	35
Matooke, restricted	198-211	186-262	115-212	—	—	—	84	0.35	0.8	11	18
Cassava, restricted	—	263-286	—	—	—	—	63	0.37	0.3	5	20
Cassava <i>ad lib.</i>	—	—	213-248	—	—	—	—	—	—	—	—
Cassava <i>ad lib.</i> plus banana- sucrose mixture‡	—	—	249-336	—	—	—	76	0.32	0.9	13	28
Staples† <i>ad lib.</i> plus banana- sucrose mixture‡	—	—	—	26-126	28-82	41-221	100	0.32	1.7	25	37
Staples† <i>ad lib.</i>	—	—	—	127-143	—	—	—	—	—	—	—
Milk or egg plus staples† <i>ad lib.</i>	—	—	—	—	—	—	154	0.42	3.9	23	30

Higher protein diets (given to B3 and B5)

Values recommended for human infants||

* All animals received daily a minimum of 33 g paw-paw (*Carica papaya* L.) in addition to the above diets.

† For details see page 232.

‡ For staples used see page 224.

§ Banana and sucrose mashed together in the proportions 180 and 30 respectively (w/w).

|| There is considerable difficulty in defining an adequate level of thiamin intake and values ranging from 0.2 to 0.5 have been reported as satisfactory.

¶ Panel on Recommended Allowances of Nutrients (1969).

were found in any animal and hair changes occurred in just the one oedematous monkey. Deo *et al.* (1965) did report oedema in some of their Rhesus monkeys (*Macaca mulatta*), but again this was restricted to the lower eyelids, although ascites was eventually noticed in three of thirty-two animals. No actual skin lesions occurred. Ordy *et al.* (1966) found no external pathological changes specifically reminiscent of kwashiorkor in Rhesus monkeys experimentally protein-malnourished for 90–120 d. Racela *et al.* (1966) said that, although the hair of a group of their Rhesus monkeys given low-protein diets had become coarse and sparse, only one developed oedema and once more this was only of the eyelids. No mention was made of skin lesions.

Stress factors

We too failed to produce a 'kwashiorkor-like' state just by a diet of low-protein, high-carbohydrate staples. The animals seemed to be precipitated into this condition only after being stressed in some way. In B 1 and B 2 this occurred after a period of acute energy deprivation; in B 8 it was after a voluntary decrease in food intake, possibly due to infection. This experience paralleled findings in Ugandan children, in whom the final hypoalbuminaemic episodes are usually associated with infections (Frood, Whitehead & Coward, 1971; Poskitt, 1971). In B 4 the addition of sucrose to the diet towards the end of the study produced a particularly big fall in serum albumin concentration. Most workers have experienced little difficulty in producing growth failure and hypoalbuminaemia both in primates and other laboratory animals. It might be that these abnormalities represent specific effects of primary protein malnutrition, whereas some of the additional pathological features result, at least in part, from an interaction between protein malnutrition and other dietary deficiencies or environmental factors. The variability in detail of the kwashiorkor syndrome as seen in different countries is also in keeping with this suggestion.

Oedema

Edozien (1968), discussing the oedema which he had succeeded in producing in rats, considered that the earlier attempts had failed because the deficient diets had not been given for long enough. Certainly in the baboon, oedema was only seen after prolonged malnutrition. However, although the first appearance of oedema was apparently associated with the degree of hypoalbuminaemia, the grotesque picture seen in B 2 after electrolyte therapy supports the view that a reduced ability of the kidneys to excrete sodium is an important factor in determining the actual amount of oedema which occurs (Alleyne, 1966).

Most investigators working with primates have observed oedema around the eyes. In the baboon it then spread to the jowls. It is tempting to relate this to the 'moon face' seen in preclinical cases of kwashiorkor. However, in the baboon the reason for the accumulation of fluid in this region is probably the bizarre posture of the severely malnourished animal. The face becomes virtually the lowest part of the anatomy.

Skin lesions

Deo *et al.* (1965), discussing their failure to produce skin lesions in their monkeys, concluded that the only skin change in kwashiorkor that definitely could be attributed to protein malnutrition was an atrophy of the epidermis and that the more dramatic changes, including pigmentary disturbances, were probably related to deficiencies of other nutrients. The role of deficiencies of other nutrients in the development of the skin lesions found in our baboons remains to be investigated. The only vitamin that might have been implicated would seem to be riboflavin and in this context the work of Foy *et al.* (1964) would be of particular relevance. The possibility of essential fatty-acid deficiency should also not be ignored (Naismith, 1964); the total fat content of the diet was low. However, in spite of the thinness of the skin, it is of interest that the incisions made during the biopsy operations appeared to heal well throughout the period of nutritional deprivation. This finding is in agreement with that of Mott, Ashby, Flannery & Ellis (1969), who reported normal peritoneal wound healing in protein-malnourished rats.

Hair

Hair changes also constitute a variable pathological feature in kwashiorkor. In Uganda the usual picture is of pale, sparse hair and it was important that this abnormality was reproduced. The gross hair changes took a long time to develop and their appearance probably depended on the chronicity of the malnutrition.

Fatty liver

The absence of marked fatty infiltration into the livers of those baboons given just the high-starch staples was unexpected, but the dramatic effect of supplementation with moderate amounts of sucrose was even more surprising. Sucrose possibly had only a secondary role in the development of the fatty liver, perhaps through the fructose part of the molecule passing more readily into the glycerol bound as triglyceride (Macdonald, 1965) or through the greater synthesis of fat in the liver induced by simple sugars compared with starch (Naismith & Khan, 1970). This would place an additional burden on the already depleted metabolic systems, centred around the β -lipoprotein required to remove fat from the liver (Flores, Sierralta & Monckeborg, 1970; Coward & Whitehead, 1972). Not only did the addition of sucrose seem to potentiate the development of a fatty liver, it was also associated with a more rapid fall in serum albumin concentration, and other pathological signs of kwashiorkor appeared more quickly too. No explanation for this latter effect can be given. The phenomenon clearly merits further investigation.

Mental apathy

Perhaps the most depressing feature of human kwashiorkor is the severe mental apathy which affects almost all the children. It is unwise to draw too close a parallel between baboons and humans, especially in terms of mental attitudes. However, the animals did become progressively quieter as the malnutrition proceeded. Eventually they went into a recluse existence at the rear of the cage, although severe anorexia

did not present the same problem as it had done in the pig (Grimble & Whitehead, 1969) and in the rat (Grimble *et al.* 1969), except in the terminal stages. The body tremors are difficult to interpret. An abnormality of this kind, also believed to be of neurological origin, was reported in the malnourished dog (Platt, 1968). A Parkinsonian-like tremor has been described in children in South Africa (Khan, 1954) and this abnormality is also seen in Uganda, although it is believed to be confined to the recovery phase. This effect in the baboons needs to be studied in greater detail; the tremors could have been due just to generalized muscular weakness, although a neurological cause can not be ruled out.

Body wasting

This investigation may be considered partly successful in that it has resulted in animals showing stunting of growth, loss of weight and muscle, hypoalbuminaemia, oedema, skin and hair changes and a fatty liver. However, the final appearance of the animals resembled marasmic kwashiorkor rather than the more classical type of kwashiorkor. During the development of the latter syndrome there is pronounced failure of growth but actual weight loss and muscle wasting are confined to the terminal stages (unpublished results), whereas the baboons lost weight throughout most of the period of malnutrition. It is necessary to carry out further modifications to the experimental design; it is clear that many factors have to be considered before a really adequate representation of human kwashiorkor is achieved.

REFERENCES

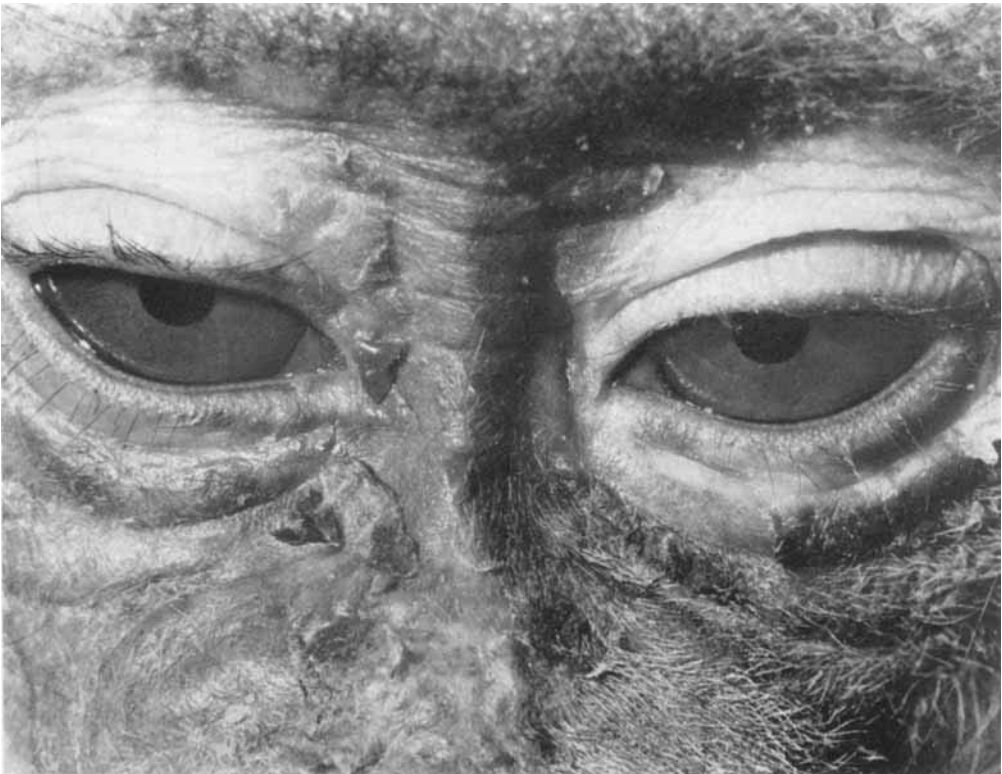- Alleyne, G. A. O. (1966). *W. Indian med. J.* **15**, 150.
 Coward, D. G., Sawyer, M. B. & Whitehead, R. G. (1971). *Am. J. clin. Nutr.* **24**, 940.
 Coward, W. A. & Whitehead, R. G. (1972). *Br. J. Nutr.* **27**, 383.
 Dean, R. F. A. & Jelliffe, D. B. (1960). *Courr. Cent. int. Enf.* **10**, 429.
 Deo, M. G., Sood, S. K. & Ramalingaswami, V. (1965). *Archs Path.* **80**, 14.
 Edozien, J. C. (1968). *Nature, Lond.* **220**, 917.
 Evans, E. & Miller, D. S. (1968). *Proc. Nutr. Soc.* **27**, 121.
 Flores, H., Sierralta, W. & Monckeberg, F. (1970). *J. Nutr.* **100**, 375.
 Follis, R. H. Jr (1957). *Proc. Soc. exp. Biol. Med.* **96**, 523.
 Foy H., Kondi, A. & Mbaya, V. (1964). *Br. J. Nutr.* **18**, 307.
 Frood, J. D. L., Whitehead, R. G. & Coward, W. A. (1971). *Lancet* *ii*, 1047.
 Grimble, R. F., Sawyer, M. B. & Whitehead, R. G. (1969). *Br. J. Nutr.* **23**, 879.
 Grimble, R. F. & Whitehead, R. G. (1969). *Br. J. Nutr.* **23**, 791.
 Hoffbauer, F. W., Zaki, F. G. & Hitchcock, C. R. (1965). In *The Baboon in Medical Research* p. 515 [H. Vagtborg, editor]. Austin: University of Texas Press.
 Howard, A. N. & Gresham, G. A. (1966). In *Some Recent Developments in Comparative Medicine* p. 75 [R. N. T. W. Fiennes, editor]. London and New York: Academic Press.
 Jelliffe, D. B. (1966). *Monograph Ser. WHO* no. 53, p. 35.
 Khan, E. (1954). *Archs Dis. Childh.* **29**, 256.
 Macdonald, I. (1965). *Clin. Sci.* **29**, 193.
 Mott, T. J., Ashby, E. C., Flannery, B. P. & Ellis, H. (1969). *Br. J. Nutr.* **23**, 497.
 Naismith, D. N. (1964). *Proc. Nutr. Soc.* **23**, viii.
 Naismith, D. J. & Kahn, N. A. (1970). *Proc. Nutr. Soc.* **29**, 64A.
 Ordy, J. M., Samorajski, T., Zimmerman, R. R. & Rady, P. M. (1966). *Am. J. Path.* **48**, 769.
 Panel on Recommended Allowances of Nutrients (1969). *Rep. publ. Hlth med. Subj., Lond.* no. 120.
 Platt, B. S. (1962). *Spec. Rep. Ser. med. Res. Coun.* no. 302. London: HM Stationery Office.
 Platt, B. S. (1968). In *Calorie Deficiencies and Protein Deficiencies* p. 237 [R. A. McCance and E. M. Widdowson, editors]. London: J. and A. Churchill.
 Poskitt, E. M. E. (1971). *Lancet* *ii*, 68.



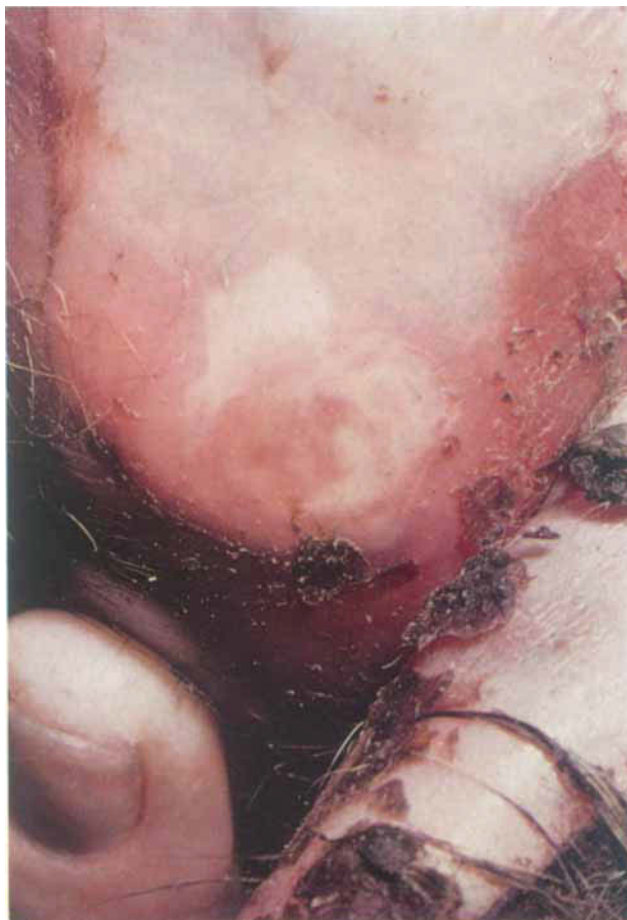(a)




(b)



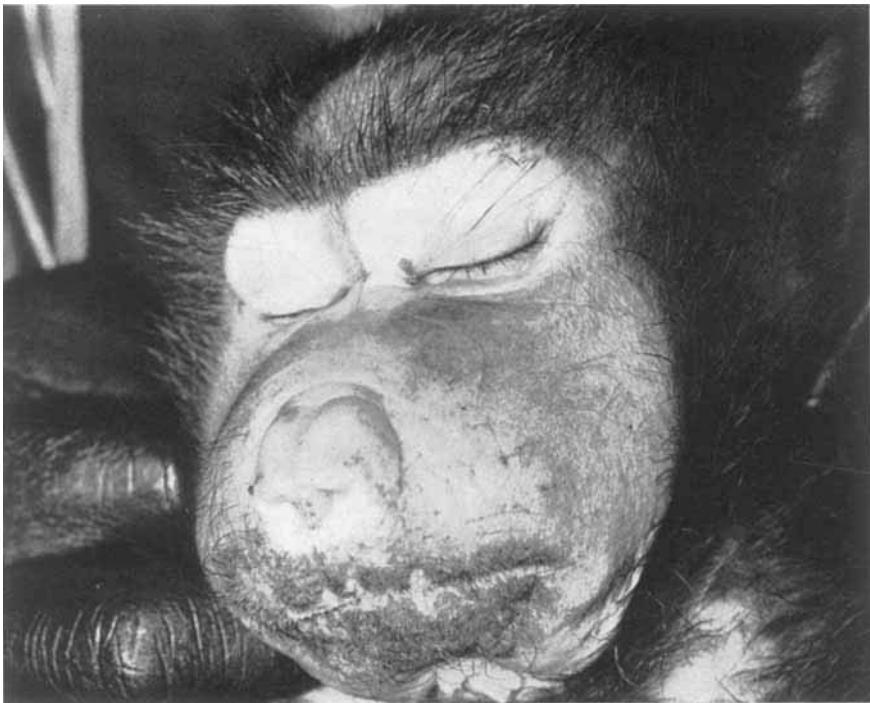
(c)



D. G. COWARD AND R. G. WHITEHEAD



(a)



(b)

D. G. COWARD AND R. G. WHITEHEAD

- Racela, A. S. Jr, Grady, H. J., Higginson, J. & Svoboda, D. J. (1966). *Am. J. Path.* **49**, 419.
Vice, T. E. & Rodriguez, A. R. (1965). In *The Baboon in Medical Research* p. 125 [H. Vagtborg, editor].
Austin: University of Texas Press.
Whitehead, R. G. & Coward, D. G. (1969). *Nutritio Dieta* **13**, 74.

EXPLANATION OF PLATES

PLATE 1

Effect of protein malnourishment on young baboons. (a) General appearance of a normal young baboon (B 3). (b) General appearance of young baboon (B 1) given low-protein diets for 197 d. There is oedema of the jowls and hyperpigmented skin lesions are present all over the face; the hair is depigmented. The animal is generally apathetic. (c) Face of baboon (B 1) showing extensive skin peeling.

PLATE 2

The buttocks and tail of baboon B 1. All developmental stages in the skin lesions can be seen – the general redness of the intact skin in the affected areas, the initially clear scaly skin, the hyperpigmented dead tissue and the pale area underneath the peeled skin. One of the pressure sores is also visible.

PLATE 3

The effect of electrolyte therapy on protein-malnourished baboon (B 2). (a) facial oedema before treatment, mainly periorbital; (b) terminal gross oedema of the whole face.