

# In Situ Cranioplasty for Hyperostosing Meningiomas of the Cranial Vault

Orin Bloch, Michael W. McDermott

**ABSTRACT: Objective:** Hyperostosis of the bone overlying meningiomas has been reported in up to 50% of cases. The skull becomes infiltrated by meningotheial tumor cells, necessitating removal of the hypertrophied bone to achieve a complete tumor resection. Unfortunately, aesthetic reconstruction of large bony defects can pose a significant challenge intra-operatively. Custom cranioplasty implants are very expensive and can only be fabricated after the bony defect exists, requiring a second surgery for implantation. Although numerous composite materials exist to repair the defects at the time of tumor resection, the challenge is to create an implant that fits appropriately without shifting and approximates the natural curvature of the skull. We have developed a technique for an “*in situ* cranioplasty” using a composite construct with strength in compression and tension. **Technique:** After the skull is reshaped by shaving down part of the hyperostotic bone, titanium mesh is molded to the surface of the skull and screwed into the surrounding normal bone. The bone flap is then removed by drilling a trough at the outer margin of the tumor-involved skull and removing a ring of normal surrounding bone. The central portion of tumor involved skull is then craniectomized. The mesh can be reapplied and the full thickness of the central bone can be reconstructed with polymethylmethacrylate, yielding a solid construct perfectly matched to the patient’s natural head shape. **Conclusion:** This novel technique yields a sturdy, aesthetic, and cost-effective result which can be used to address any cranial vault defect at the time of tumor resection.

**RÉSUMÉ: Cranioplastie in situ dans le traitement des méningiomes avec hyperostose de la voûte crânienne. Objectif :** Une hyperostose de l’os susjacent a été rapportée dans près de 50% des cas de méningiome. Le crâne est infiltré par des cellules méningothéliales tumorales ce qui requiert une ablation de l’os hypertrophié pour assurer une résection complète de la tumeur. Malheureusement, une reconstruction esthétique peut constituer un défi de taille lors de la chirurgie lorsque la résection osseuse est importante. Les implants faits sur mesure sont très coûteux et ne peuvent être fabriqués qu’après la chirurgie, ce qui nécessite une seconde intervention. Bien qu’il existe plusieurs composites qui peuvent être utilisés au moment de la résection tumorale, c’est un défi de créer un implant bien adapté et stable, dont la courbure s’apparente à celle du crâne. Nous avons développé une technique de “cranioplastie in situ” utilisant un montage de composite avec propriétés en tension et en résistance. **Technique :** Après que le crâne ait été remodelé par rasage d’une partie de l’hyperostose, un treillis de titane est moulé à la surface du crâne et vissé dans l’os normal adjacent. Le lambeau osseux est ensuite réséqué après avoir foré une gouttière au bord externe de l’os infiltré par la tumeur, en s’assurant d’enlever un anneau osseux normal à la périphérie. La portion centrale de l’os infiltré par la tumeur est ensuite réséquée. Le treillis peut alors être réappliqué et l’os central peut être reconstruit dans sa pleine épaisseur au moyen de polyméthylméthacrylate, produisant ainsi un montage solide qui est parfaitement apparié à la forme naturelle de la tête du patient. **Conclusion :** Cette technique nouvelle donne un résultat solide, esthétique et rentable qui peut être utilisée pour traiter toute brèche à la voûte crânienne lors d’une résection tumorale.

Can. J. Neurol. Sci. 2011; 38: 59-64

Meningiomas involving the cranial vault often present with fullness under the scalp from remodeling of bone. Regardless of the size of the intracranial tumor or the degree of dural involvement, bony infiltration and hyperostosis of adjacent bone is quite common. Brissaud and Lerebaoullet first described the association of hyperostosis and meningiomas in 1903.<sup>1</sup> Since their original description, many authors have reported on the incidence and pathophysiology of tumor-related hyperostosis. Cushing and Eisenhardt reported hyperostosis in 25% of their meningioma patients, and other authors have reported rates as high as 49%.<sup>2-4</sup> Histopathology of hyperostotic bone demonstrates infiltration of meningotheial tumor cells within Haversian canals.<sup>5,6</sup> Complete tumor resection therefore necessitates the removal of involved bone to prevent recurrence. In his classification for meningioma resection, Simpson demonstrated that a total resection, including all dural and bony involvement, was necessary to achieve a low recurrence rate of

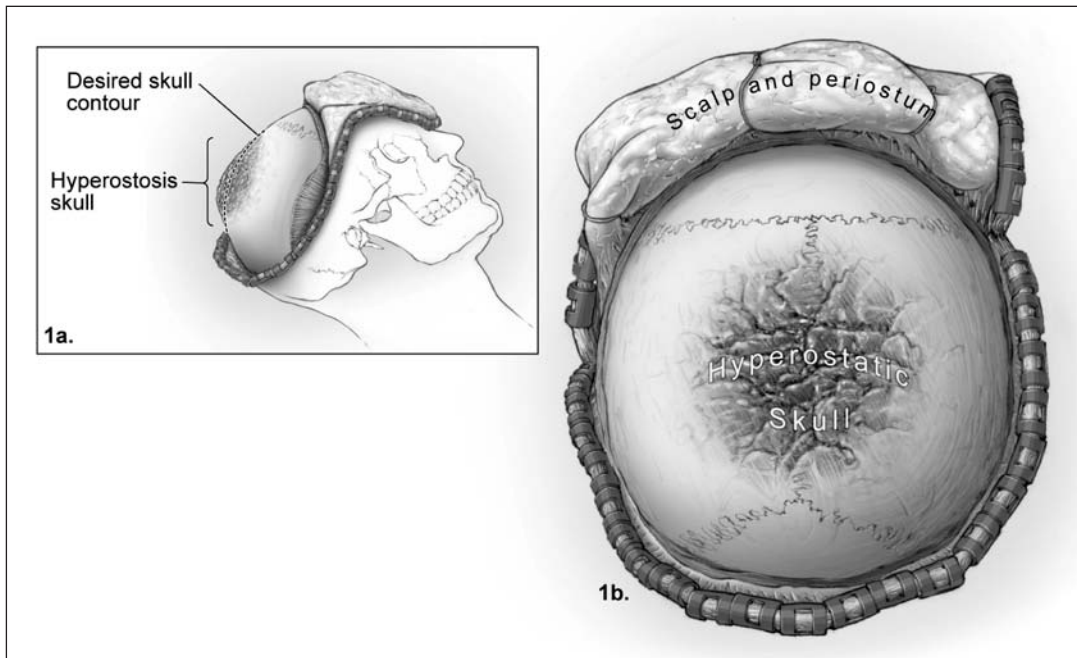
< 9% (Simpson grade I).<sup>7</sup> This has since been confirmed by other authors.<sup>8-10</sup>

Unfortunately, the removal of large areas of hyperostotic bone poses a significant challenge to surgeons when attempting an appropriate cosmetic repair. Creation of an aesthetically pleasing cranioplasty that approximates the natural curvature of the skull can be difficult. The contour of a typical cranioplasty is often disappointing when viewed on post-operative CT scans

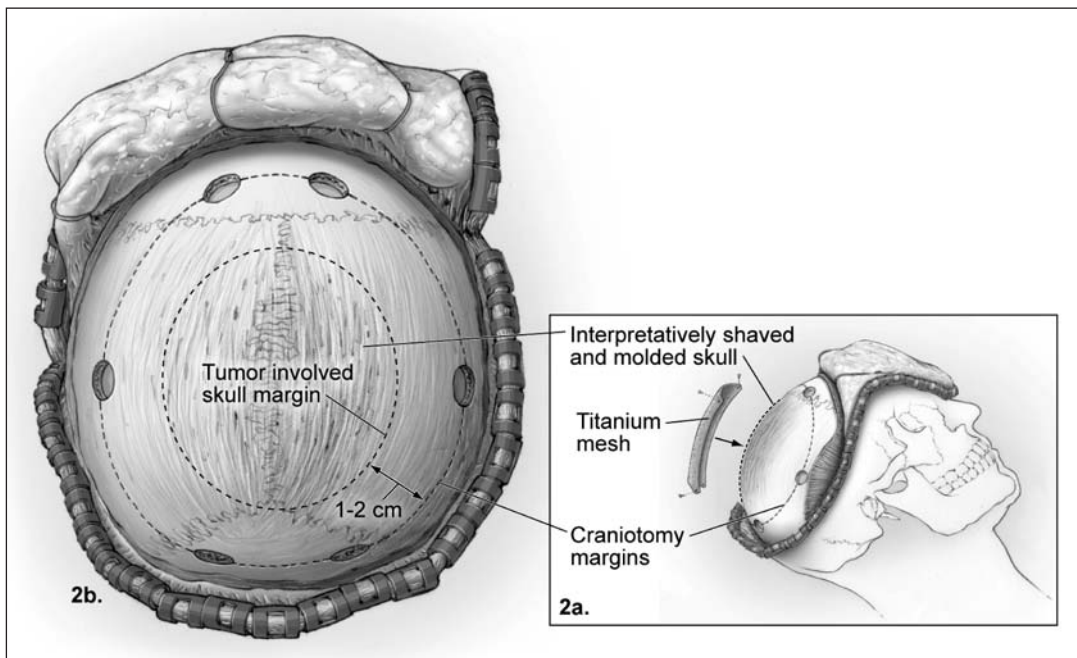
From the Department of Neurological Surgery, University of California, San Francisco California, USA.

RECEIVED JULY 14, 2010. FINAL REVISIONS SUBMITTED AUGUST 23, 2010.

Correspondence to: Michael W. McDermott, 505 Parnassus Avenue, Box 0112, San Francisco, California, 94143-0112, USA.



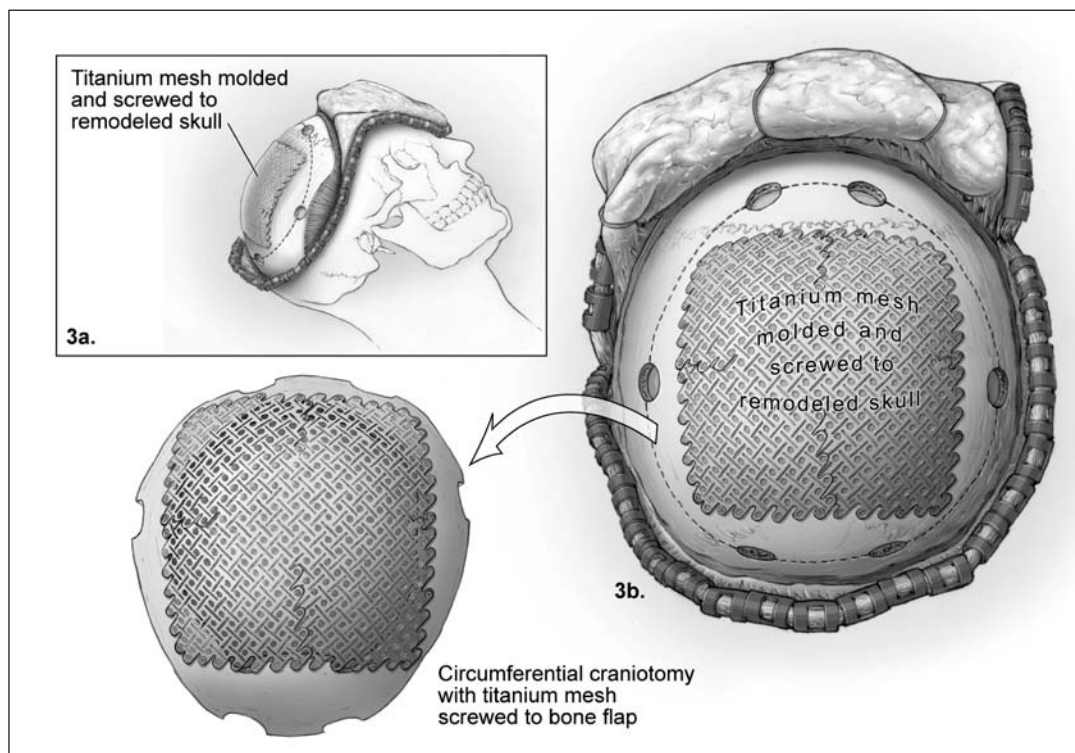
**Figure 1:** Exposure of the tumor-infiltrated bone. The scalp flap and periosteum are turned back to reveal the hyperostotic skull viewed sagittally (a) and axially (b). The natural curvature of the skull can be imagined from multiple angles to determine the degree of hyperostotic skull to be shaved.



**Figure 2:** Remodeling of the hyperostosis in situ. Exophytic bone is shaved down to recreate a natural curvature to the skull. The boundaries of abnormal bone are identified with image guidance and a circular craniotomy is planned 1-2cm beyond the abnormal margin. Titanium mesh is then molded to cover the abnormal bone to be craniectomized.

and the cranioplasty often appears “flatter” than imagined intraoperatively. At present, custom polymer or titanium implants cannot be modeled pre-operatively without a cranial defect. Additionally, it is often difficult to assess the degree of involved bone prior to exposure. Therefore “*in situ* cranioplasty” using composite materials is often necessary at the time of surgery. Numerous techniques for polymer cranioplasty have been reported in the literature. The challenge is often creating an implant that fits appropriately without the risk of sinking or rotating and approximates the natural shape of the skull. Here we

Intraoperatively, the shaved hyperostotic skull can be viewed from multiple angles to ensure the best cosmetic result. Once the surgeon is satisfied with the remodeled skull, image guidance is used to mark out the boundaries of the abnormal bone and underlying tumor, as well as important structures such as the sagittal sinus. Titanium mesh is then molded to the curvature of the skull and secured beyond the abnormal bone to normal skull that will be elevated as a ring craniotomy. The titanium mesh is removed from the craniotomy flap taking care to mark the screw sites and orientation of the mesh. A circular craniotomy is



**Figure 3:** Turning of the craniotomy flap. After the screw holes are marked to identify the orientation of the molded titanium mesh (a), the craniotomy flap can be turned and removed. Shown in (b) is the final flap with the titanium mesh reapplied.

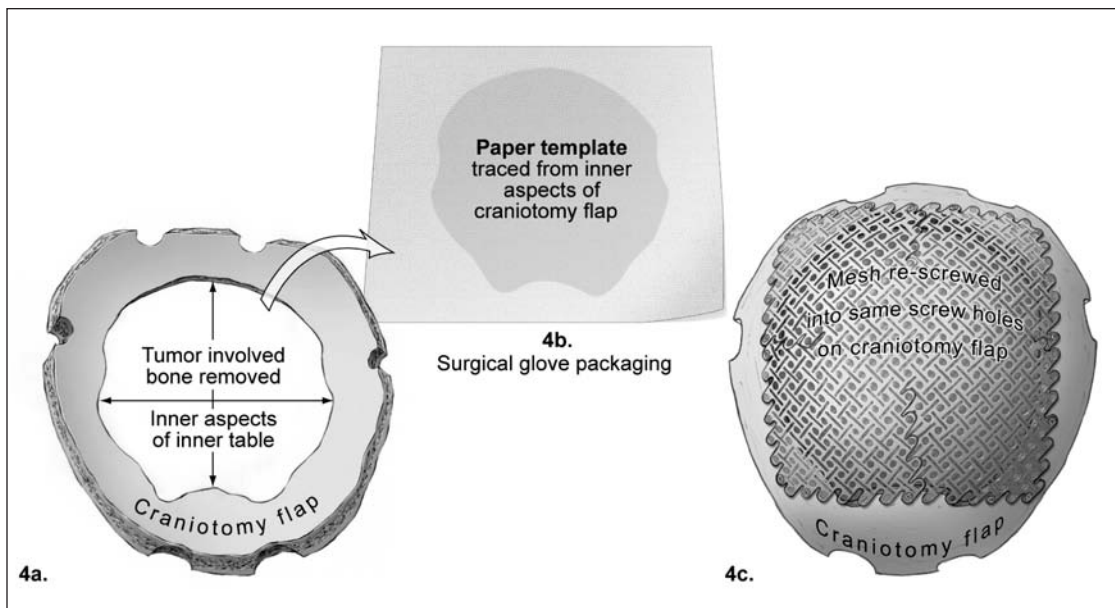
report a technique for “*in situ* cranioplasty” for defects from hyperostosis associated with meningiomas of the cranial vault using a composite implant made of titanium mesh and polymethylmethacrylate (PMMA). The advantage of this technique is that we use the patient’s anatomy in situ to create a perfectly fitting, solid implant that closely approximates the natural contour of the skull for an aesthetic result.

#### SURGICAL TECHNIQUE

At the time of surgery, the scalp and periosteum are turned back to expose the hyperostotic skull (Figure 1). A cutting burr is used to shave down the exophytic hyperostotic bone until the shape approximates the natural curvature of the skull.

planned 1-2cm beyond the margin of the tumor-involved skull to be excised (Figure 2). A trough is created at the margin of the tumor involved skull down to dura. This allows for excision of the tumor involved skull separately and creation of a craniotomy of normal bone beyond this margin. The craniotomy flap is turned and the bone is removed, often in two pieces (Figure 3). The tumor-infiltrated bone in the center of the flap is craniectomized with a burr or rongeur. The mesh is replaced on the bone flap and screwed in place to cover the central defect (Figure 4). The flap can then be stored while the intracranial portion of the tumor is resected.

Once the tumor resection is accomplished, the cranioplasty is completed as a composite structure with polymethylmethacrylate.



**Figure 4:** Removal of the hyperostotic bone. The remaining tumor-infiltrated bone is craniectomized from the center of the flap using a burr or rongeur (a). The defect can then be templated on a sterile piece of paper (b) to mold the polymethylmethacrylate. The mesh is resecured to the flap with screws (c) prior to application of the polymethylmethacrylate.

The polymethylmethacrylate is mixed and allowed to become dry to touch yet still soft. It is rolled out on a moistened plastic surface to create a thick sheet of the appropriate thickness and size to fit the craniectomy defect. This can easily be done using a paper template. The inner edge of the craniectomy defect is marked with ink and a piece of paper (such as the packaging from a surgical glove) is pressed against the margin transferring the ink mark. The paper is then used as a template for the PMMA sheet which is cut to the appropriate size and lifted off the moistened plastic surface. The PMMA is laid onto the mesh from the inner table side up (Figure 5). Gentle pressure is used to push the PMMA into the interstices of the mesh to create a secure composite structure with increased rigidity in tension and compression, a similar concept to concrete reinforced with rebar. The outer edges of the cranioplasty are smoothed with a moist gloved finger before the PMMA hardens. Once the composite has set, the craniotomy flap can be re-inserted into the defect and secured in the standard fashion (Figure 6).

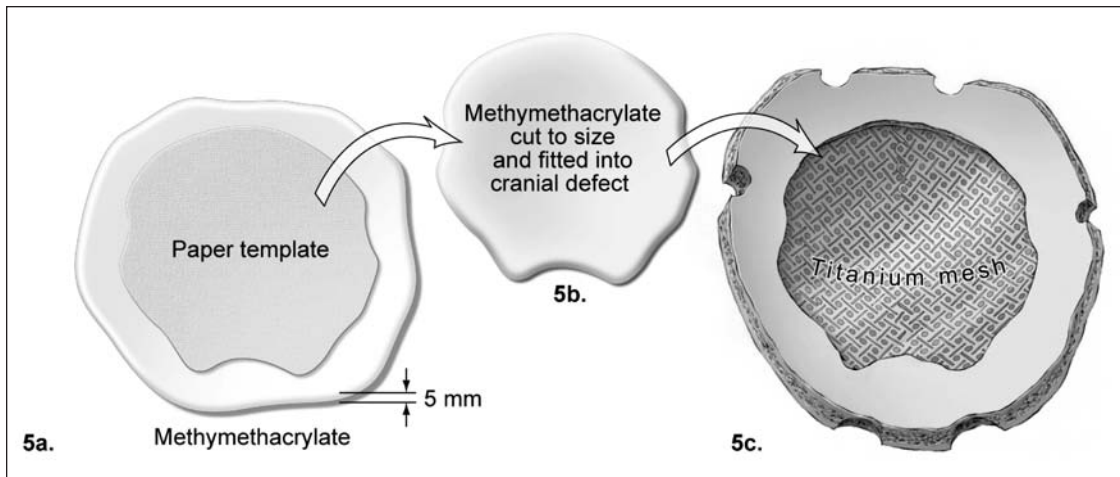
## DISCUSSION

Repair of the cranial defect following craniotomy for tumor is essential for neuroprotection, providing a satisfactory cosmetic result for the patient and potentially avoiding symptoms related to alterations in barometric pressure with large defects ("syndrome of the trephined")<sup>11,12</sup>. Ideally, the defect is repaired with the patient's autologous bone flap, however this is not always possible. When the calvarium is infiltrated with tumor, the involved bone must be removed to achieve a complete resection. This situation is most often encountered with hyperostotic meningiomas. Meningothelial tumor cells infiltrate the Haversian canals within the bone and stimulate osteoblast activity resulting in thickened bone overlying the

primary tumor.<sup>5,6</sup> Bikmaz et al demonstrated histopathologic evidence of bone invasion by tumor in 12 of 13 meningioma patients with sphenoid wing hyperostosis.<sup>13</sup> Additionally, Pieper et al demonstrated evidence of tumor invasion into adjacent bone in 69% of skull base meningioma patients, with evidence of tumor in nearly all patients with clear hyperostosis and in 9 of 24 patients without obvious bony changes.<sup>5</sup> Based on Simpson's original study, which has since been confirmed by other authors, it is clear that this tumor-infiltrated hyperostotic bone must be completely resected to minimize tumor recurrence.<sup>7-10</sup> In addition to harboring a source of tumor cells, the hyperostosis can be quite disfiguring and must be addressed for cosmetic purposes. For these tumors, as well as other rare lesions involving the calvarium such as giant cell tumors, aneurysmal bone cysts, and osteosarcomas reconstruction of the cranial defect is a major portion of the operation.

A number of options exist for the reconstruction of cranial defects when autologous bone replacement is not possible. Prefabricated custom synthetic or metallic implants produce excellent cosmetic results, but they must be generated from a scan after the defect exists, necessitating a second surgery for the cranioplasty.<sup>14,15</sup> In addition, these custom implants are very expensive, with a cost greater than ten times that of dynamic polymer cranioplasties.<sup>15</sup> "In situ cranioplasty" at the time of tumor resection is therefore preferred, but there are multiple challenges to achieving a secure construct with an appropriate cosmetic result. The flap must approximate the natural curvature of the skull and be secured in place firmly without risk of sinking or rotating to maintain a long lasting aesthetic result. Furthermore, most polymers produce an exothermic reaction generating heat while curing, and thermal injuries to the brain from direct application of cranioplasty polymers is a real





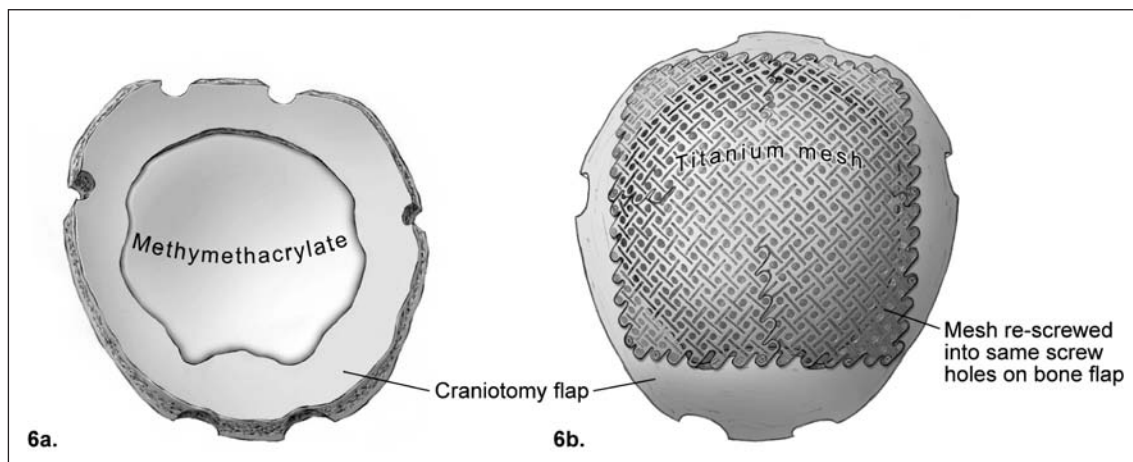
**Figure 5:** Building the composite flap. The paper template is applied to a pressed sheet of polymethylmethacrylate of appropriate thickness (a) and the polymer is cut to the appropriate size to fit in the craniectomized portion of the flap (b). The polymethylmethacrylate is then applied to the inner table surface of the craniotomy flap and pressed into the interstices of the titanium mesh (c).

concern.<sup>16</sup> Although the use of multiple synthetic polymers has been described, PMMA remains the standard given its ease of use, low cost, and biocompatibility. Several different commercial products exist but we prefer the barium impregnated type due to increase ease of use, handling characteristics and the radio-opaque features similar to skull on post-operative CT scans.

#### CONCLUSIONS

Our method for in situ cranioplasty described in this paper utilizes the natural bone contour prior to craniectomy as a template for bending the titanium mesh for the sythetic flap, yielding a highly cosmetic result. Although other authors have

described the use of molded cranioplasties templated from the native bone flap, they utilize the explanted bone flap to press-mold the synthetic flap thereby molding their flap without visualizing the shape relative to the rest of the skull.<sup>17</sup> Furthermore, these flaps are made of polymer only and are affixed within the defect by plating. Since the polymers do not fuse with bone, flaps held in place by only 3 or 4 point fixation may loosen and sink or rotate over time. Some authors have attempted to address this problem by notching the bone edge and/or creating a scaffold with sutures to bolster the cranioplasty flap, but that requires laying the polymer *in situ* over the brain surface with the previously mentioned risk of thermal injury, as



**Figure 6:** Completed composite flap. As demonstrated, the final result is a composite craniotomy flap with polymethylmethacrylate on the inner surface bonded to titanium mesh over the outer table defect molded to recreate the natural curvature of the skull. This flap can be reapplied to the skull defect at the end of the tumor resection and secured with standard titanium plates.

well as the surgical delay while the flap is allowed to set.<sup>18,19</sup> By utilizing a composite flap made of titanium mesh and PMMA, our method produces a more secure final result without the risk or delay of other methods. The mesh is molded *in situ* and affixed solidly at multiple points with overhang onto natural bone circumferentially around the defect to prevent delayed motion. The tumor-infiltrated bone can then be craniectomized and the PMMA molded off the field by the assistant surgeon while the primary surgeon proceeds with the intracranial tumor resection. In this way, our novel method for *in situ* cranioplasty offers a sturdy, aesthetic, and efficient way to address cranial defects during tumor resection.

#### ACKNOWLEDGEMENTS

The authors thank Kenneth Probst for his assistance with the illustrations for this manuscript.

#### REFERENCES

1. Brissaud, Lerebaoullet P. Deux cas d'hémicraniose. *Rev Neurol.* 1903;11:504-37.
2. Cushing H. The cranial hyperostoses produced by meningeal endotheliomas. *Arch Neurol Psychiatry.* 1922;8:139-54.
3. Cushing H, Eisenhardt L. *Meningiomas: their classification, regional behavior, life history and surgical end results.* Springfield: Charles C Thomas; 1938.
4. Sosman M, Putnam T. Roentgenological aspects of brain tumors-meningiomas. *AJR Am J Roentgenol.* 1925;13:1-12.
5. Pieper DR, Al-Mefty O, Hanada Y, Buechner D. Hyperostosis associated with meningioma of the cranial base: secondary changes or tumor invasion. *Neurosurgery.* 1999;44(4):742-6; discussion 6-7.
6. Bonnal J, Thibaut A, Brotchi J, Born J. Invading meningiomas of the sphenoid ridge. *J Neurosurg.* 1980;53(5):587-99.
7. Simpson D. The recurrence of intracranial meningiomas after surgical treatment. *J Neurol Neurosurg Psychiatry.* 1957;20(1): 22-39.
8. Adegbite AB, Khan MI, Paine KW, Tan LK. The recurrence of intracranial meningiomas after surgical treatment. *J Neurosurg.* 1983;58(1):51-6.
9. Mirimanoff RO, Dosoretz DE, Linggood RM, Ojemann RG, Martuza RL. Meningioma: analysis of recurrence and progression following neurosurgical resection. *J Neurosurg.* 1985;62(1):18-24.
10. Stafford SL, Perry A, Suman VJ, et al. Primarily resected meningiomas: outcome and prognostic factors in 581 Mayo Clinic patients, 1978 through 1988. *Mayo Clin Proc.* 1998;73 (10):936-42.
11. Fodstad H, Love JA, Ekstedt J, Friden H, Liliequist B. Effect of cranioplasty on cerebrospinal fluid hydrodynamics in patients with the syndrome of the trephined. *Acta Neurochir (Wien).* 1984;70(1-2):21-30.
12. Stiver SI, Wintermark M, Manley GT. Reversible monoparesis following decompressive hemicraniectomy for traumatic brain injury. *J Neurosurg.* 2008;109(2):245-54.
13. Bikmaz K, Mrak R, Al-Mefty O. Management of bone-invasive, hyperostotic sphenoid wing meningiomas. *J Neurosurg.* 2007; 107(5):905-12.
14. Chiarini L, Figurelli S, Pollastri G, et al. Cranioplasty using acrylic material: a new technical procedure. *J Craniomaxillofac Surg.* 2004;32(1):5-9.
15. Lee SC, Wu CT, Lee ST, Chen PJ. Cranioplasty using polymethyl methacrylate prostheses. *J Clin Neurosci.* 2009;16(1):56-63.
16. Stelnicki EJ, Ousterhout DK. Prevention of thermal tissue injury induced by the application of polymethylmethacrylate to the calvarium. *J Craniofac Surg.* 1996;7(3):192-5.
17. Fathi AR, Marbacher S, Lukes A. Cost-effective patient-specific intraoperative molded cranioplasty. *J Craniofac Surg.* 2008;19 (3):777-81.
18. Gibbons KJ, Hicks WL, Jr., Guterman LR. A technique for rigid fixation of methyl methacrylate cranioplasty: the vault-locking method. *Surg Neurol.* 1999;52(3):310-14; discussion 4-5.
19. Raja AI, Linskey ME. In situ cranioplasty with methylmethacrylate and wire lattice. *Br J Neurosurg.* 2005;19(5):416-9.