



Letter to the Editor: New Observation

The “Drama Mask” Phenomenon in Craniofacial Dystonia

Matthew A. Remz^{1,2} , Jason L. Chan^{1,2} , Alfonso E. Martinez-Nunez^{1,2} and Irene A. Malaty^{1,2}

¹Department of Neurology, University of Florida, Gainesville, Florida, USA and ²Normal Fixel Institute for Neurological Disease, University of Florida, Gainesville, Florida, USA

Keywords: blepharospasm; botulinum toxin; emotion; Meige syndrome; segmental dystonia

Dystonia involves sustained or intermittent muscle contractions that cause abnormal movements or postures and are often exacerbated by voluntary actions.¹ Blepharospasm, a manifestation of dystonia, spreads in about 50% of cases, with oromandibular involvement as the most common area.² In craniofacial dystonia, the involvement of facial musculature can have an outsized impact on social and interpersonal interactions.

A 52-year-old woman presented to our center with a 7-year history of involuntary eyelid closure. Based on her complaint of “heavy” eyelids that would not stay open, she was initially diagnosed with seronegative myasthenia gravis and treated with medications and thymectomy. The lack of improvement led to subspecialty consultation and a diagnosis of blepharospasm. MRI imaging of the brain was unremarkable. Genetic testing was not pursued. She presented to our center to continue therapy with botulinum toxin injections.

At disease onset, she had isolated involuntary eye closure, and her symptoms progressed to involve involuntary contractions of other facial muscles, consistent with craniofacial dystonia. When she chewed food, she had stereotyped eyelid clenching, nose elevation, and lip puckering and elevation (Video 1). In social settings, people would consistently inquire about her reason for disgust, when in fact she was enjoying her food. This caused embarrassment to eat in public. Conversely, when angrily scolding her children, she noticed paradoxical “smiling,” or pulling of the nose upward and angles of the mouth backward, diminishing the conviction and emotion she was trying to convey. These “drama masks” resulted in a frustrating mismatch between her emotional state and outward expression.

A trial of clonazepam had minimal impact. Other medications, including trihexyphenidyl, were not tried because of the focal nature of her symptoms and concerns about systemic side effects. Botulinum toxin injections were progressively tailored (Figure 1) and ultimately alleviated her craniofacial dystonia and the “drama mask” phenomenon (Video 1).

In our case, a patient with chronic blepharospasm experienced new debility as the spread of her dystonia contaminated the execution of nonverbal communication. This case highlights the distinct social and emotional impact of craniofacial dystonia and the importance of finely tailoring treatment to aspects of impact on

the individual. Muscle selection in this individual required watching several home videos and allowing her to chew food and provoke the dystonia in the clinic in order to capture the specific actions.

We present an example wherein craniofacial dystonia produced emotionally incongruent facial expressions and impacted emotional expression. Consequently, this “drama mask” phenomenon interfered with effective communication and was socially disabling. This symptomatology is not captured on common scales that assess focal dystonia, is not well described in the literature, and may be underappreciated. This is compounded by the known non-motor effects of dystonia. Depression and anxiety are highly co-morbid with blepharospasm and even more so with segmental dystonia, with one recent study citing social anxiety in 67% of patients with the latter.³ Recognizing the emotional and social impacts of craniofacial dystonia is critical to effective and comprehensive treatment.

Supplementary material. The supplementary material for this article can be found at <https://doi.org/10.1017/cjn.2025.6>.

Acknowledgments. The authors would like to acknowledge the patient for her cooperation in making this work possible.

Author contributions. MAR: Organization, execution, writing of the first draft, and review and critique. JLC: Organization, writing of the first draft, and review and critique. AEMN: Execution and review and critique. IAM: Conception and review and critique.

Financial disclosures for the previous 12 months. MAR was part of a fellowship program supported by the Blumenthal Movement Disorders Fellowship Fund, Boston Scientific, and Medtronic. He receives no direct remuneration. JLC was supported by a Parkinson’s Foundation Institutional Movement Disorders Fellowship. AEM receives support for his fellowship position from Amneal Pharmaceuticals. He receives no direct remuneration. IAM has participated in research funded by AbbVie, Emalex, Neuroderm, Revance, and Sage and is a consultant for AbbVie. She has received royalties from Robert Rose Publishers.

Funding statement. No specific funding was received for this work.

Competing interests. IAM has participated in research funded by AbbVie and is a consultant for AbbVie.

Corresponding author: Matthew A. Remz; Email: Matthew.Remz@neurology.ufl.edu

Cite this article: Remz MA, Chan JL, Martinez-Nunez AE, and Malaty IA. The “Drama Mask” Phenomenon in Craniofacial Dystonia. *The Canadian Journal of Neurological Sciences*, <https://doi.org/10.1017/cjn.2025.6>

© The Author(s), 2025. Published by Cambridge University Press on behalf of Canadian Neurological Sciences Federation. This is an Open Access article, distributed under the terms of the Creative Commons Attribution licence (<https://creativecommons.org/licenses/by/4.0/>), which permits unrestricted re-use, distribution and reproduction, provided the original article is properly cited.

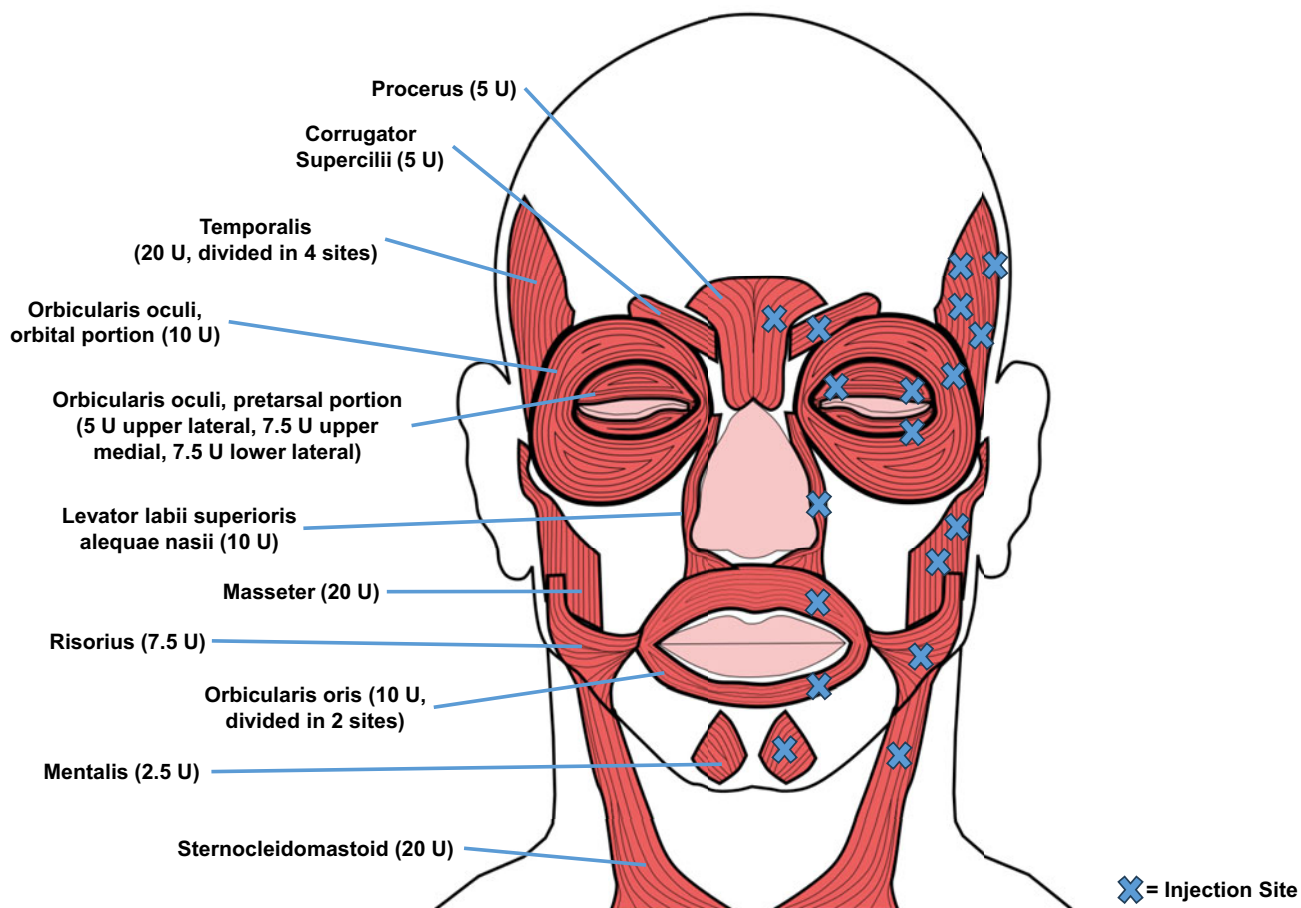


Figure 1. Bilateral, symmetric onabotulinum toxin type A injections into muscles of the face and neck alleviated the patient's craniofacial dystonia. Her optimized injection pattern is displayed on a single side, with each injection site indicated by an X. Units of toxin displayed are for unilateral injections.

References

1. Albanese A, Bhatia K, Bressman SB, et al. Phenomenology and classification of dystonia: a consensus update. *Mov Disord Off J Mov Disord Soc.* 2013;28(7):863–873.
2. Berman BD, Groth CL, Sillau SH, et al. Risk of spread in adult-onset isolated focal dystonia: a prospective international cohort study. *J Neurol Neurosurg Psychiatry.* 2020;91(3):314–320.
3. Junker J, Hall J, Berman BD, et al. Longitudinal predictors of health-related quality of life in isolated dystonia. *J Neurol.* 2024;271(2):852–863.