

Cantrell's Pentalogy in Twins: Prenatal Diagnosis

Renato A. Moreira de Sá,^{1,2} Gustavo P. A. de Souza Filho,^{1,2} Laudelino M. Lopes,¹ Edson C. Faleiro,² and Joffre A. Junior²

¹ Department of Fetal Medicine, CPDT/Laranjeiras Clínica Perinatal, Rio de Janeiro, Brazil

² Department of Fetal Medicine, Maternidade Escola da UFRJ, Rio de Janeiro, Brazil

The combination of an omphalocele, an anterior thoracic wall defect and an anterior diaphragmatic defect constitutes classical Cantrell's pentalogy. We present a case of Cantrell's pentalogy diagnosed prenatally in twins with conventional and three-dimensional sonography.

In 1958, Cantrell et al. described a syndrome consisting of a supraumbilical wall defect, a defect of the lower sternum, a deficiency of the anterior diaphragm, a defect of the diaphragmatic pericardium and various intracardiac defects. The syndrome, Cantrell's pentalogy, is exceedingly rare. Until now, only one case report describes this pathologic entity in twins (Baker et al., 1984).

Case Report

A 22-year-old (gravida 3, para 2) was referred to Maternidade Escola da UFRJ for ultrasound examination at 23 weeks' menstrual age. The clinical history and physical examination were unremarkable. Transabdominal sonography using an SSA-260A ultrasound scanner with a 3.5 MHz convex-array transducer (Toshiba, Japan) revealed a twin pregnancy with both fetuses in cephalic position. Twin A showed the heart extruded through the thoracic cavity and an omphalocele with abdominal visceral eventration (Figure 1). A free communication was present between cavities due to the lack of a diaphragm. A dysraphic spine was present. Twin B exhibited no abdominal wall or thoracic defect. Both fetuses had severe intracardiac defects, however, confirmed by fetal echocardiography. Twin A showed a large ventricular septal defect and mitral valve stenosis. Twin B showed a 'univentricular heart' (a single atrial chamber connected by a single atrioventricular valve to a single ventricle).

The biparietal diameter, femur length and other fetal measurements were normal according to gestational age in both fetuses. We performed a three-dimensional sonographic (Voluson 730, GE, USA) examination at CPDT/Laranjeiras Clínica Perinatal to delineate the defect and confirm the diag-

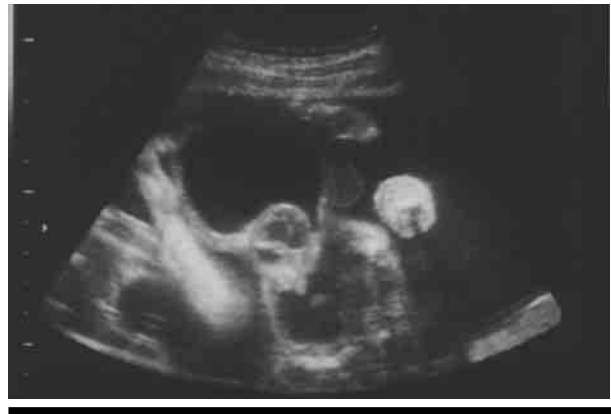

Figure 1

Transversal scan of the fetus demonstrating a ventral wall defect with the heart outside the thorax.

nosis (Figure 2 and 3). The patient was admitted for cesarean section after PROM in the 36th week of pregnancy. A 1610 g live neonate with multiple congenital malformations (supraumbilical abdominal midline defect with extracorporeal herniation of the heart and abdominal organs, defect of the inferior sternum and pericardial and anterior diaphragm defect — Cantrell's pentalogy, dysraphic spine and clubfoot) was delivered and died immediately after birth. The Twin B weighed 2120 g and did not exhibit external malformations. The cardiopathy was confirmed in postnatal echocardiography. After a 10-day hospitalization the baby was discharged. This infant died at the age of 4 months.

Discussion

The prevalence of Cantrell's pentalogy is 5.5 per million live-births (Carmi & Boughman, 1992). The embryology of abdominal wall defects is controversial

Received 2 May, 2006; accepted 25 May, 2006.

Address for correspondence: Renato Augusto Moreira de Sá, CPDT-Laranjeiras Clínica Perinatal, rua das Laranjeiras 445, Laranjeiras, Rio de Janeiro, RJ, Brazil, 22240-002. E-mail: rsa@cpdt.com.br

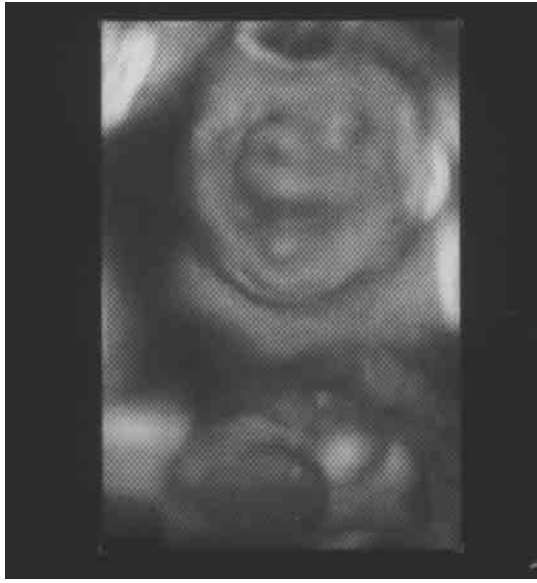

Figure 2
Three-dimensional sonography showing a ventral wall defect with the heart outside the thorax.

(Baker et al., 1984). Normal development of the fetal abdomen depends on the migration of the lateral folds and correct ventral mesodermal differentiation (Bonilla-Musoles et al., 2001). The flat embryo becomes tubular during the fourth week as the result of the circumferential enfolding of the cephalic, caudal, and two lateral abdominal wall folds. If the lateral ectodermal and mesodermal folds fail to fuse along midline, by the end of 4 weeks, an abdominal wall defect develops (Baker et al., 1984). Intracardiac lesions result from faulty mesodermal development. Cantrell's pentalogy results from failure of the cephalic fold to close (Seeds et al., 1984).

Toyama (1972), Spitz et al. (1975), Ghidini et al. (1988) and Denath et al. (1994) reviewed the literature and found that six of 59 confirmed cases exhibited central nervous system malformations. The

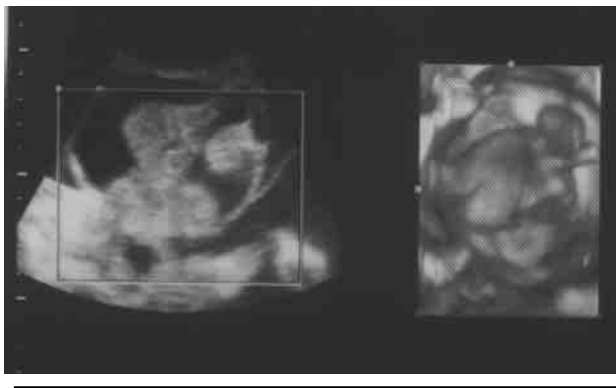


Figure 3
Three-dimensional sonography showing the abdominal wall defect.

differentiation of Cantrell's pentalogy from other abdominal wall defects is extremely important. The differential diagnosis includes isolated thoracic *ectopia cordis*; amniotic band syndrome and body stalk anomaly (Hsieh et al., 1998). Bennett et al. (1991) reported the first case of Cantrell's pentalogy, in the first trimester, using two-dimensional ultrasound and Doppler imaging. Baker et al. (1984) reported the first case in twins. In this instance, identical midline defects occurred in both twins. To our knowledge, no report exists using a three-dimensional system to complement two-dimensional ultrasound (Baker et al., 1984). We agree with Bonilla-Musoles et al. (2001) that the three-dimensional system is a more valuable tool than two-dimensional ultrasound for evaluating fetuses with abdominal wall defects.

In conclusion, Cantrell's pentalogy is a rare entity, and we add our case to the few reported in world literature. The complementary imaging results obtained when two-dimensional and three-dimensional systems are used for the assessment of fetal malformations may allow a more complete and accurate diagnosis (Bonilla-Musoles et al., 2001). We suggest that this combination is a procedure of choice for ultrasound assessment of abdominal wall defects.

References

- Baker, M. E., Rosenberg, E. R., Trofatter, K. F., Imber, M. J., & Bowie, J. D. (1984). The in utero findings in twin pentalogy of Cantrell. *Journal of Ultrasound in Medicine*, 3, 525–527.
- Bennett, T. L., Burlbaw, J., Drake, C. K., & Finley, B. E. (1991). Diagnosis of *ectopia cordis* at 12 weeks gestation using transabdominal ultrasonography with color flow Doppler. *Journal of Ultrasound in Medicine*, 10, 695–696.
- Bonilla-Musoles, F., Machado, L. E., Bailao, L. A., Osborne, N. G., & Raga F. (2001). Abdominal wall defects: Two- versus three-dimensional ultrasonographic diagnosis. *Journal of Ultrasound in Medicine*, 20, 379–389.
- Cantrell, J. R., Haller, J. Á., & Ravith, M. M. (1958). A syndrome of congenital defects involving the abdominal wall, sternum, diaphragm, pericardium, and heart. *Surgery, Gynecology and Obstetrics*, 107, 602–614.
- Carmi, R., & Boughman, J. A. (1992). Pentalogy of Cantrell and associated midline anomalies: A possible ventral midline developmental field. *American Journal of Medical Genetics*, 42, 90–95.
- Denath, F. M., Romano, W., Solcz, M., & Donnelly, D. (1994). Ultrasonographic findings of exencephaly in pentalogy of Cantrell: Case report and review of the literature. *Journal of Clinical Ultrasound*, 22, 351–354.
- Ghidini, A., Sirtori, M., Romero, R., & Hobbins, J. C. (1988). Prenatal diagnosis of pentalogy of Cantrell. *Journal of Ultrasound in Medicine*, 7, 567–572.

- Hsieh, Y. Y., Lee, C. C., Chang, C. C., Tsai, H. D., Hsu, T. Y., & Tsai, C. H. (1998). Prenatal sonographic diagnosis of Cantrell's pentalogy with cystic hygroma in the first trimester. *Journal of Clinical Ultrasound*, 26, 409–412.
- Seeds, J. W., Cefalo, R. C., Lies, S. C., & Koontz, W. L. (1984). Early prenatal sonographic appearance of rare thoraco-abdominal eventration. *Prenatal Diagnosis*, 4, 437–441.
- Spitz, L., Bloom, R., Milner, S., & Levin, S. E. (1975). Combined anterior abdominal wall, sternal, diaphragmatic, pericardial, and intracardiac defects: A report of five cases and their management. *Journal of Pediatric Surgery*, 10, 491–496.
- Toyama, W. M. (1972). Combined congenital defects of the anterior abdominal wall, sternum, diaphragm, pericardium, and heart: A case report and review of the syndrome. *Pediatrics*, 50, 778–792.
-