

# Horseshoe abscess associated with acute carpal tunnel syndrome: somebody wake up the hand surgeon

David A. Simon, BKin, MD\*; Taryn-Lise Taylor, BKin, MSc, MD, CCFP<sup>†</sup>

## ABSTRACT

The horseshoe abscess is a rare variant of flexor tendon sheath infections. It involves the tendon sheaths of the first and fifth digits, which communicate through the deep potential space of the wrist. Neural compression is possible, leading to an acute carpal tunnel syndrome. The approach to such patients should include empirical antibiotic coverage and urgent consultation with a hand surgeon to facilitate operative management.

## RÉSUMÉ

L'abcès en fer à cheval est une variante rare d'infection de la gaine du tendon fléchisseur. Il touche la gaine des tendons des premier et cinquième doigts, qui communiquent par le grand espace potentiel du poignet. Une compression nerveuse est possible, entraînant un syndrome du tunnel carpien aigu. L'approche, avec de tels patients, devrait comprendre une antibiothérapie empirique et une consultation d'urgence auprès d'un chirurgien de la main pour faciliter la gestion opératoire.

**Keywords:** hand infection, horseshoe abscess, infectious tenosynovitis

The hand is the major prehensile organ. It is constantly in use and at risk for injury and infection during everyday activities. Even innocuous trauma may introduce damaging pathogens. An untreated hand infection can lead rapidly to tissue destruction and permanent disability. If a tendon sheath infection is recognized late or is not treated appropriately, skin loss, tendon necrosis, and subsequent osteomyelitis can result. Early diagnosis and timely, effective intervention are

crucial to treatment. The hand's compartmentalized anatomy consists of multiple potential spaces and tissue planes and may contribute to the development of very uncommon infectious presentations such as the horseshoe abscess. This rare infection may generate significant morbidity. Aggressive infectious tenosynovitis and its variants are a true emergency, and in most cases, immediate drainage in the operating room is required. A successfully managed case of a 52-year-old male with a rare horseshoe abscess and subsequent acute carpal tunnel syndrome emphasizes the importance of early recognition and surgical consultation.

## CASE REPORT

A 52-year-old male hobbyist was completing a piece of furniture in his workshop and incurred a self-described "minor scratch" on the volar aspect of the tip of his right thumb while working with a piece of steel wool. There was no puncture wound, bleeding, or sliver of material embedded in the thumb. A few hours later, the patient began experiencing intense pain in the thumb. A rapid progression of erythema, swelling, and pain occurred over the radial aspect of his hand accompanied by lymphangitic streaking along the volar aspect of the right forearm. His past medical history was unremarkable. There were no pets in the home or recent animal exposures.

On presentation to the emergency department, tetanus toxoid was administered because the patient could not recall his last booster. Streptococcal infection was suspected, and the patient was initially

From the \*Faculty of Medicine, Division of Orthopaedic Surgery, University of Ottawa, and †Carleton Sport Medicine Clinic, Ottawa, ON.

**Correspondence to:** Dr. Taryn-Lise Taylor, Carleton Sport Medicine Clinic, 1125 Colonel By Drive, Ottawa, ON K1S 5B6; taryntaylor13@yahoo.

Submitted May 7, 2010; Revised August 20, 2010; Accepted August 22, 2010.

© Canadian Association of Emergency Physicians

CJEM 2012;14(2):124-127

DOI 10.2310/8000.2011.110364

managed with empirical intravenous cefazolin and clindamycin (the patient had a previous documented allergic reaction to penicillin). However, the pain intensified, and the patient developed symptoms of suppurative flexor tenosynovitis in the fifth digit in addition to the thumb. The lymphangitic streaking migrated proximally up his right arm into the axilla and across the lateral aspect of his chest. Massive swelling also developed over the dorsum of his hand and the volar carpus, which induced an acute carpal tunnel syndrome with dense anesthesia and motor deficit. The wrist was postured in slight flexion.

Initial blood work revealed leukocytosis (white blood cell count of  $29.7 \times 10^9/L$ ); the erythrocyte sedimentation rate (ESR) was normal, and the C-reactive protein (CRP) levels were not immediately available. Soft tissue swelling was evident on a radiograph; however, no metallic foreign body or gas was visualized (Figure 1). A magnetic resonance image (MRI), which revealed extensive flexor tenosynovitis, was obtained immediately to rule out necrotizing fasciitis. Surgical consultation was requested while the patient was having the MRI. The patient's condition was progressing rapidly despite intravenous antibiotics. He also developed an acute carpal tunnel syndrome and so was taken urgently to the operating room.

Within 4 hours of initial presentation to the emergency department and within 6 hours of symptom onset, the patient underwent urgent exploration of the flexor tendon sheaths and decompression of the carpal tunnel. Intraoperatively, there was gross pus in the carpal tunnel and in the flexor tendon sheaths of the first and fifth digits, which were all accessed via separate incisions. The flexor tendon sheaths of the

second through fourth digits were normal, thus confirming the diagnosis of the extremely rare horseshoe abscess variant of pyogenic flexor tenosynovitis.

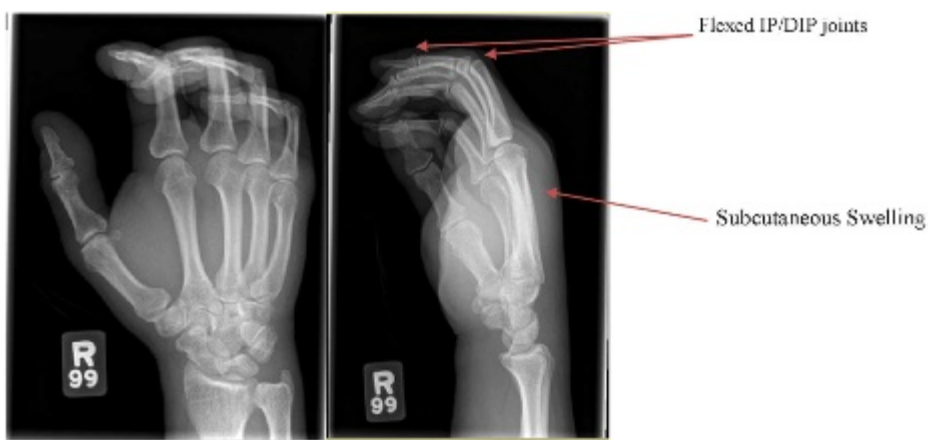The affected flexor tendon sheaths were debrided and irrigated using angiocatheters that were left in situ for further irrigation on the ward. The median nerve appeared hemorrhagic owing to acute compression, so necrotic tissue was debrided and the Guyon canal was also released. The carpal tunnel skin incision could not be closed primarily in the operating room owing to massive edema.

Postoperatively, the erythema and lymphangitic streaking receded rapidly, and the patient experienced significant pain relief. Intraoperative cultures grew group G streptococcus—sensitive to cefazolin, penicillin, and clindamycin. The infectious disease service recommended continuing only the cefazolin while the patient was in hospital. He was ultimately discharged on oral cephalexin. The patient had mild residual parathesias in the distribution of the median nerve of his right hand, but motor function was normal. After a short course of hand therapy, he was able to return to activities of daily living, including his woodworking hobby.

## DISCUSSION

Pyogenic flexor tenosynovitis is a bacterial infection of the flexor tendon sheath. It is a familiar entity to emergency physicians and usually results from small penetrating trauma over the volar proximal interphalangeal or distal interphalangeal joint.

The digital flexor tendon sheath is a double-walled mesothelial structure with a closed space between the visceral layer adherent to the flexor tendon and the



**Figure 1.** Anteroposterior and lateral radiograph views of the hand. Multiple views show prominent soft tissue swelling about the distal forearm and along the dorsal aspect of the hand. No gas is seen within the soft tissues. The underlying bone is also unremarkable. Note that there are flexion deformities noted at the proximal interphalangeal joints, which may be related to the soft tissue swelling. DIP = distal interphalangeal; IP = interphalangeal.

parietal layer. The sheath extends from the proximal end of the A1 pulley (at the level of the metacarpophalangeal joint) to the level of the distal interphalangeal joint. The sheath of the thumb is contiguous with the radial bursa, and the sheath for the small finger is contiguous with the ulnar bursa. The radial and ulnar bursae extend proximally where they may communicate proximal to the carpal tunnel via the Parona space in 50 to 80% of the population<sup>1,2</sup> (Figure 2).

Bacterial spread to adjoining deep spaces and tissues can also occur. Infection of the thumb-flexor sheath can, via contiguous spread through communication of the radial and ulnar bursae, result in infection of the small-finger sheath, and vice versa. This is referred to as the “horseshoe abscess,” as described in the case above. More extensive proximal spread can lead to infection of the Parona space (the quadrilateral potential space at the wrist bordered by the pronator quadratus, digital flexors, flexor pollicis longus, and

flexor carpi ulnaris), potentially resulting in acute median nerve compression.<sup>2,3</sup> This situation is also likely to clinically feature tenderness over the thenar and/or hypothenar eminence, a flexed posture at the wrist, and painful passive extension of uninvolved digits. The epidemiology of this variant has yet to be quantified in the medical literature.<sup>4</sup>

*Staphylococcus aureus* is the most common causative organism. A wider host of organisms should be considered in immunocompromised patients and in those with chronic indolent infections.<sup>2</sup> Several conditions can mimic acute pyogenic flexor tenosynovitis. The differential diagnosis includes herpetic whitlow, felon, septic joint, local abscess, necrotizing fasciitis, and inflammatory diseases such as rheumatoid arthritis and gout.

In 1939, Kanavel described in detail the four signs characteristic of pyogenic flexor tenosynovitis: 1) flexed resting position of the involved digit, 2) tenderness over

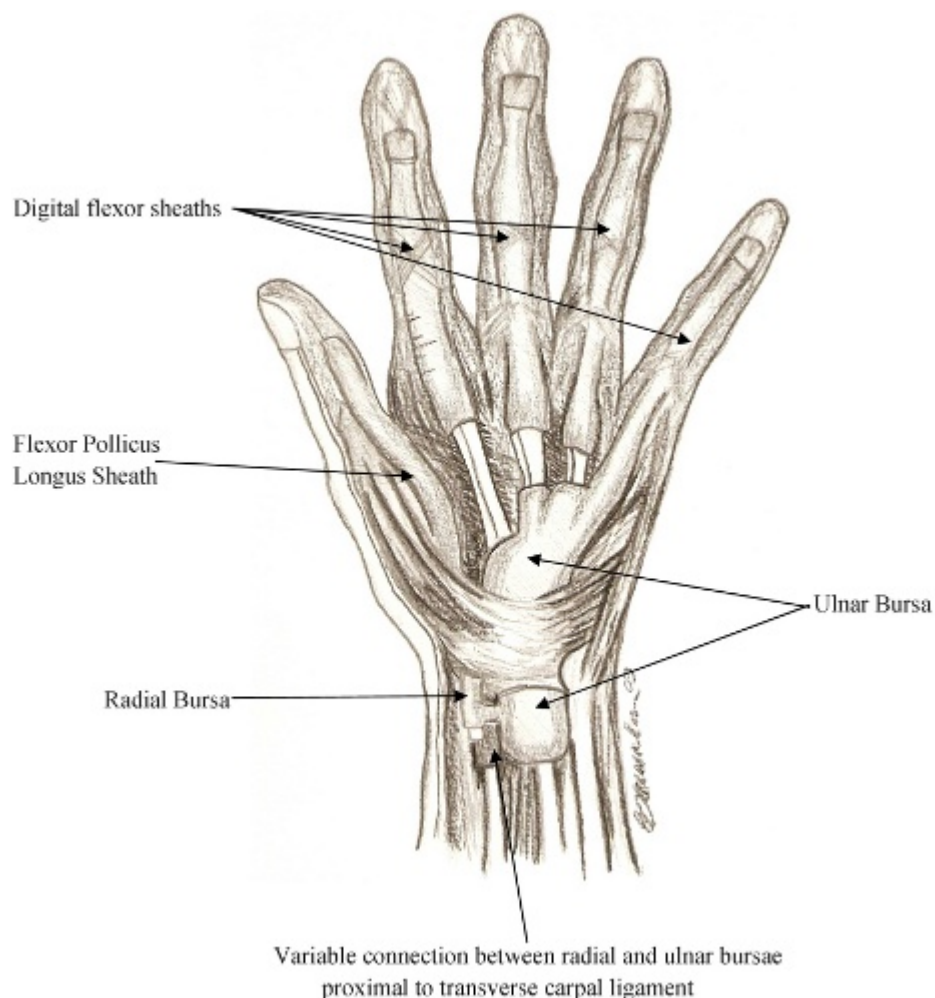


Figure 2. Hand anatomy.

the flexor sheath, 3) fusiform swelling, and 4) severe pain on passive extension.<sup>1,5</sup> All signs may not be present, especially early in the course. Concomitant local or extensive cellulitis is often part of the clinical presentation. Treatment delay can result in tendon vascular compromise and necrosis, eventuating in adhesion, poor tendon gliding, and diminished hand function.

Early infections (within 24 hours) with only partial expression of one or two of Kanavel signs, can be treated with elevation, splinting, and intravenous antibiotics.<sup>1</sup> If improvement is not noted in the first 12 hours, surgical treatment is necessary to avoid destruction of the gliding mechanism and subsequent loss of range of motion. Untreated disease and late diagnosis or presentation can lead to devastating disability in hand function.

Laboratory evaluation may include a complete blood count and differential. The ESR and CRP may be useful in monitoring the response to treatment. Radiographs should be taken initially to evaluate for a retained foreign body or fracture. Radiographic evidence of a septic joint or osteomyelitis will not be present acutely. Flexor tenosynovitis is primarily a clinical diagnosis, and advanced imaging studies generally are unnecessary (including in this case) and should not delay requests for consultation or operative intervention.

Sterile conditions are imperative for attempting tendon sheath aspiration and irrigation, which should ideally be performed by a plastic or orthopedic surgeon. Early involvement of a hand specialist is imperative when there are aggressive features. In this case, both the unusually aggressive presentation and acute neurologic deficit warranted rapid surgical intervention. The preferred surgical techniques, which involve limited incisions and catheter irrigation, have proven effective in the hand literature,<sup>1,2,4</sup> enabling more rapid recovery and rehabilitation.

Outcomes after horseshoe abscess or bursal infections are generally not as favourable as for isolated flexor tenosynovitis. Complications such as tendon

adhesions, flexion contracture of the fingers and wrist, and restricted motion are more likely to occur. Median nerve integrity may be jeopardized, and the neurologic prognosis is directly related to the duration of compression. Additional surgical interventions, such as tenolysis for recalcitrant adhesions, may be necessary if physical therapy does not adequately restore function.

## **CONCLUSION**

The horseshoe abscess is a rare and potentially aggressive variant of suppurative flexor tenosynovitis. It may be associated with neurologic deficits. Empirical antibiotic coverage is appropriate with step-down therapy once the culture and sensitivity results are available. Emergency physicians should not hesitate to involve their surgical colleagues should they encounter this rare presentation of a common problem. Timely surgical intervention is critical for optimizing outcome and for preventing complications following delayed recognition of flexor tenosynovitis.

**Acknowledgment:** The authors wish to thank Lauren Lim Liong Soon for providing the anatomic drawing.

**Competing interests:** None declared.

## **REFERENCES**

1. Hausman MR, Lisser SP. Hand infections. *Orthop Clin North Am* 1992;23:171-85.
2. Siegel DB, Gelberman RH. Infections of the hand. *Orthop Clin North Am* 1988;19:779-89.
3. Abrams RA, Botte MJ. Hand infections: treatment recommendations for specific types. *J Am Acad Orthop Surg* 1996;4: 219-30.
4. Stefanovic MV, Sharpe F. Acute infections in the hand. In: Green DP, editor. *Operative hand surgery*. 5th ed, vol 1. New York: Churchill Livingstone; 2005. p. 55-94.
5. Kanavel AB. *Infections of the hand*. 7th ed. Philadelphia: Lea & Febiger; 1939.