

Main Article

Edward Balai takes responsibility for the integrity of the content of the paper

Cite this article: Balai E, Dronkers EAC, Yaghchi CA, Gujral D, Sandhu G, Iacovidou A. Adjuvant treatments for recurrent respiratory papillomatosis: a descriptive review and proposed management guideline in adults. *J Laryngol Otol* 2024;1–11. <https://doi.org/10.1017/S0022215124001026>

Received: 5 February 2024

Revised: 14 April 2024

Accepted: 25 April 2024

Keywords:



larynx; endoscopy; laser; dysphonia; trachea; papillomatosis

Corresponding author:

Edward Balai;

Email: edward.balai@nhs.net

Adjuvant treatments for recurrent respiratory papillomatosis: a descriptive review and proposed management guideline in adults

Edward Balai¹ , Emilie AC Dronkers² , Chadwan A Yaghchi², Dorothy Gujral³, Guri Sandhu² and Aphrodite Iacovidou²

¹Department of Otolaryngology, Charing Cross Hospital, Imperial College Healthcare NHS Trust, London, UK,

²National Centre for Airway Reconstruction, Charing Cross Hospital, Imperial College Healthcare NHS Trust, London, UK and ³Department of Surgery and Cancer, Charing Cross Hospital, Imperial College Healthcare NHS Trust, London, UK

Abstract

Objective. Recurrent respiratory papillomatosis is a rare disease characterised by growth of papilloma within the respiratory tract. The disease course is variable but can require frequent surgical interventions alongside adjuvant medical treatments. There is no definitive curative treatment or gold-standard guidelines for management. We aimed to evaluate current and potential future adjuvant treatments and propose a management guideline for adult patients. **Methods.** Relevant articles were identified through searching databases, reference lists and grey literature.

Results. Systemic bevacizumab appears to be the most effective adjuvant treatment currently available. However, intralesional cidofovir also achieves a high complete-response rate in adults and the Gardasil vaccine demonstrates preventative and therapeutic value. The INO-3107 DNA vaccine is a promising potential future adjuvant treatment.

Conclusions. This review provides a detailed examination of current and potential future adjuvant treatments. Based on the literature, we have developed a management guideline for adult patients with recurrent respiratory papillomatosis.

Introduction

Recurrent respiratory papillomatosis is a rare chronic disease caused by the human papillomavirus (HPV) that is characterised by the growth of benign papilloma within the respiratory tract. The disease, which is classified as adult onset (adult-onset recurrent respiratory papillomatosis) or juvenile onset (juvenile-onset recurrent respiratory papillomatosis) based on the age at diagnosis, demonstrates a trimodal distribution with peaks at ages 7, 35 and 64 years.¹ Adult-onset recurrent respiratory papillomatosis has a male predilection and typically affects individuals between the second and fourth decades of life, with an incidence rate of 1.8 per 100 000 adults. Juvenile-onset recurrent respiratory papillomatosis is the most common benign laryngeal tumour in children, with an incidence rate of 4.5 per 100 000.²

In adults, recurrent respiratory papillomatosis can manifest with symptoms of hoarseness, dyspnoea, stridor, cough and recurrent respiratory infections. Paediatric presentation varies based on whether the disease affects the supraglottis, glottis or subglottis, with early presentation with dysphonia if the glottis is involved.

Standardised systems of objective scoring of recurrent respiratory papillomatosis, such as the Derkay Severity Score, have been developed that allow for assessment of the disease course over time and evaluation of the response to treatment.³ The Derkay Severity Score combines a subjective clinical assessment with an anatomical assessment of the sites involved and has been shown to positively correlate with voice-related quality of life (QoL) scores on the Voice Handicap Index-10.⁴

The disease course is variable but can require lifelong treatment with multiple surgeries alongside adjuvant medical treatments to achieve control. While an increasing number of adjuvant treatments have become available over the past two decades, there is currently no definitive curative treatment for recurrent respiratory papillomatosis or gold-standard guidelines for the management of this condition.

In this review, we aimed to evaluate current and potential future adjuvant treatment options for the management of recurrent respiratory papillomatosis. We considered the efficacy and potential side effects of each option and propose a management guideline for adult patients with recurrent respiratory papillomatosis based on the current literature. Additionally, we evaluated the approach to surgical management of recurrent respiratory papillomatosis and considered the burden of surgical interventions from both an economic and QoL perspective.

Methods

Electronic database searches of Embase (1974–2023) and Ovid MEDLINE (1946–2023) were systematically performed with the following keywords and Mesh terms: “recurrent respiratory papillomatosis”, “laryngeal papillomatosis”, “juvenile-onset recurrent respiratory papillomatosis”, “adult-onset recurrent respiratory papillomatosis”, “adjuvant treatment”, “adjuvant therapy”, “quality of life” and “economic burden”. The full search can be requested from the corresponding author. The results were screened to identify articles relevant to the creation of the management guideline. Eligibility criteria included articles involving humans, available in the English language, and with the full text available for retrieval.

The database search identified 3352 articles with 1273 screened after removal of duplicates and those marked ineligible by automation tools (Figure 1). After screening, 1171 articles were excluded and 102 were retrieved and assessed for eligibility, with 16 deemed relevant for inclusion in the development of the management guideline. The main details of these articles are shown in Table 1. The reference lists of included articles were then screened for additional sources. Grey literature was searched as well. The data and discussions

were interpreted and synthesised to create a concise review of the surgical management and adjuvant treatments available for recurrent respiratory papillomatosis. Based on the findings of the review, we developed a proposed management guideline for the treatment of adult patients with recurrent respiratory papillomatosis within the United Kingdom National Health Service (NHS) setting.

Results

Pathophysiology

Human papillomavirus infiltrates basal epithelial cells of the squamous epithelium through microtears in the overlying cell layers, activating the epidermal growth factor pathway and suppressing tumour-suppressor proteins.⁵ Specifically, the proteins encoded by the E6 and E7 regions of the HPV viral genome interfere with tumour suppressor proteins p53 and pRB, respectively.⁶ This results in cellular proliferation and epithelial differentiation that culminates in the development of papillomatous lesions that can be microscopic or macroscopic and exophytic. These lesions are typically benign, but depending on the specific subtype of HPV involved, they

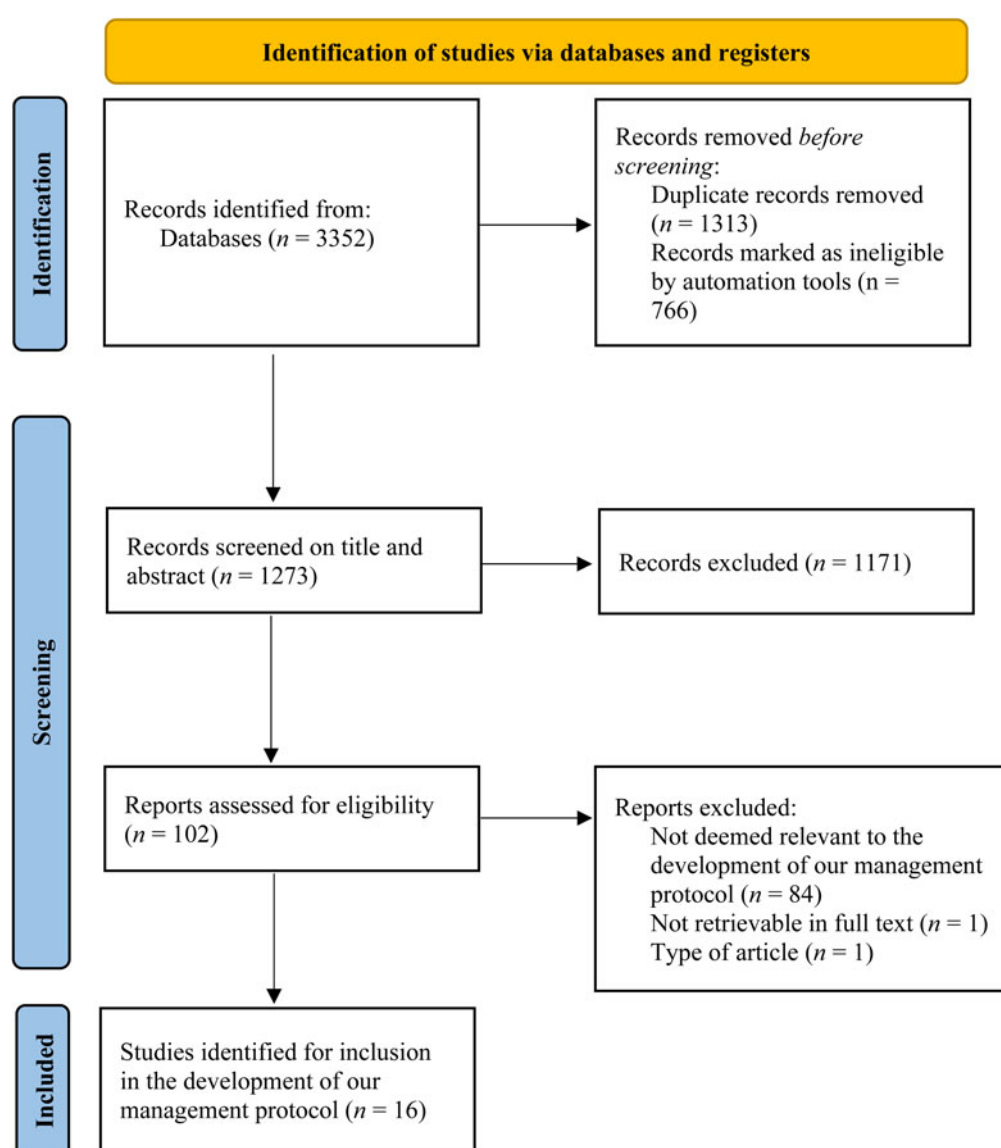


Figure 1. Flow diagram of screened and included studies identified via database search

Table 1. Articles identified in the database search relevant to the development of the management guideline

Author	Year	Study Design	Adjuvant Treatment / Topic	N	Outcome measures	Follow Up/ Study Period
Ablanedo-Terrazas <i>et al.</i> ⁶⁴	2022	Randomised, double-blind, placebo-controlled trial	Intralesional Cidofovir Intralesional Bevacizumab	11 AO-RRP 5 JO-RRP	Derkey severity score Voice Handicap Index	1 year
Armstrong <i>et al.</i> ¹⁸	1999	Prospective, multi-centre, case series	Surgical interventions Adjuvant treatments	399 JO-RRP	Frequency of surgical interventions Disease progression Adjuvant treatments Need for tracheostomy	2 years
Benedict <i>et al.</i> ⁴³	2021	Descriptive review	Management of RRP	N/A	N/A	N/A
Derkey <i>et al.</i> ⁵¹	2013	Cross-sectional study, web-based clinician survey	Intralesional Cidofovir	801 AO-RRP 447 JO-RRP	Indications Administration Associated adverse events	N/A
Derkey <i>et al.</i> ²	2008	Descriptive review	Management of RRP	N/A	N/A	N/A
Fortes <i>et al.</i> ⁵	2017	State-of-the-art review	Management of RRP	N/A	N/A	N/A
Gazia <i>et al.</i> ⁵⁴	2020	Systematic review	Intralesional Cidofovir	185 AO-RRP 85 JO-RRP	Concentration used Number of injections Injection interval Therapeutic response Side effects Progression to dysplasia	N/A
Goon <i>et al.</i> ⁴⁹	2023	Systematic review and meta-analysis	HPV vaccine	101 AO-RRP	Frequency of surgery Rate of recurrence	N/A
Hock <i>et al.</i> ²²	2022	Retrospective, multi-centre, case series	Surgical interventions Adjuvant treatments	44 AO-RRP 68 JO-RRP	Derkey severity score Progression to dysplasia	10 years
Liu <i>et al.</i> ²⁵	2023	Systematic review and meta-analysis	Safety of surgical interventions	576 AO-RRP 419 JO-RRP	Intra-operative complications Post-operative complications	N/A
McMurray <i>et al.</i> ⁵³	2008	Randomised, double-blind, placebo-controlled trial	Intralesional Cidofovir	14 AO-RRP 5 JO-RRP	Derkey severity score Voice Handicap Index Health-Related Quality of Life Frequency of surgical interventions	1 year
Pogoda <i>et al.</i> ⁶³	2022	Systematic review	Intralesional Bevacizumab Systemic Bevacizumab	10 AO-RRP 54 JO-RRP	Treatment dose and interval Frequency of surgical interventions Derkey severity score Complications	N/A
Rosenburg <i>et al.</i> ⁴⁸	2019	Systematic review and meta-analysis	HPV vaccine	133	Frequency of surgical interventions	N/A
Sidell <i>et al.</i> ⁶⁵	2021	Delphi method-based survey	Systemic Bevacizumab	N/A	Patient characteristics Disease characteristics Treating centre characteristics Prior treatment characteristics Prior work-up	N/A
Tjon Pian Gi <i>et al.</i> ⁶¹	2013	Retrospective, multi-centre, cohort study	Intralesional Cidofovir	AO-RRP 517 JO-RRP 118	Nephrotoxic side effects Neutropenic side effects Oncogenic side effects	14 years
Welschmeyer <i>et al.</i> ¹⁰	2021	Systematic review	Epidemiological factors	N/A	Risk factors associated with RRP Patient demographics HPV immunological characteristics Clinical course Psychosocial factors	N/A

can have varying degrees of malignant potential. In recurrent respiratory papillomatosis these papillomata predominantly manifest at the junction between the stratified squamous epithelium in the larynx and the pseudostratified columnar epithelium of the respiratory tract distally.⁵

Human papillomavirus infection is ubiquitous in the population. It is estimated that by the age of 50 years old, 80 per cent of women in the United States have serological evidence of previous infection.⁷ While in the majority of cases the virus is cleared by a host cell-mediated immune response, it is estimated that 5 per cent of the general population has HPV DNA detectable in their larynx suggesting persistent infection.⁸ It is unclear why a small number of these individuals go on to develop recurrent respiratory papillomatosis, but it is thought to be related to an ineffective immune response to the viral proteins. While the mechanism is unknown, there is evidence that the adaptive immune response becomes polarised toward a Th2-like or T-regulatory phenotype in these patients. This results in suppression of Th1 cells that would produce the inflammatory cytokines, such as interleukin-2 and tumour necrosis factor, responsible for clearing viral infections.⁹

Recurrent respiratory papillomatosis is predominantly associated with HPV sub-types 6 and 11, but can also be caused by other strains, including 16, 18, 31 and 33. Traditionally, HPV 11 has been linked to more severe recurrent respiratory papillomatosis disease.¹⁰ However, emerging evidence suggests that age at diagnosis may be a more consistent predictor of disease severity, with the probability of an aggressive disease course being higher in patients diagnosed under five years of age.^{11,12}

Juvenile-onset recurrent respiratory papillomatosis is typically thought to be due to transmission of maternal HPV infection to the child at birth. Trans-placental transmission of HPV has been suggested to occur in 12 per cent of cases,¹³ and the presence of maternal anogenital papilloma increases the risk of developing juvenile-onset recurrent respiratory papillomatosis by 231 times.¹⁴ First-born status, vaginal delivery, and being born to a teenage mother have also been reported to increase the risk of juvenile-onset recurrent respiratory papillomatosis.¹⁵

Adult-onset recurrent respiratory papillomatosis has historically been thought to potentially be a sexually transmitted infection and linked to the practice of oral sex. Studies have found higher sexual partner counts, oral sex prevalence, and increased number of lifetime sexual partners to be associated with adult-onset recurrent respiratory papillomatosis. However, they also reported no significant difference in the number of lifetime oral sex partners when compared to controls, and instances where no prior oral sex or sexual partners were noted.^{12,16} An alternative hypothesis is that adult-onset recurrent respiratory papillomatosis may represent the reactivation of latent infection acquired at the time of birth. However, juvenile-onset recurrent respiratory papillomatosis and adult-onset recurrent respiratory papillomatosis patients have been demonstrated to have different exposures to the proposed birth risk factors¹² as well as no discernible difference in birth history between adult-onset recurrent respiratory papillomatosis patients and healthy controls.¹⁶

Surgical treatment

In adult-onset recurrent respiratory papillomatosis, the clinical course of the disease is highly variable but typically requires frequent surgical interventions. The average rate of surgeries is 4.4 per year and, although spontaneous remission can

occur, chronic disease is the norm.¹⁷ Paediatric patients with juvenile-onset recurrent respiratory papillomatosis typically require an average of 5.1 surgeries per year, with a mean duration of disease of 4.4 years. Remission can occur at any age but is most likely in cases where the disease presents at 6–10 years of age and is confined to the larynx, with younger age of diagnosis (< 5 years old) being associated with more aggressive disease.^{18,19}

Multiple modalities are available to surgically treat recurrent respiratory papillomatosis under general anaesthesia. These include cold steel, microdebrider, coblation, CO₂ laser (10 600 nm), pulsed dye laser (585 nm) and potassium titanyl phosphate (KTP) (532 nm), and blue-light laser (445 nm). There is growing evidence for the use of blue-light laser (445 nm) in an office-based laser treatment setting.^{20,21} In terms of efficacy, a retrospective study of 112 adult-onset recurrent respiratory papillomatosis patients treated with KTP laser, CO₂ laser, or microdebrider found no significant difference in mean surgical intervals among the three treatment groups.²² A further retrospective study of 194 adult-onset recurrent respiratory papillomatosis patients treated with either CO₂ laser or cold steel resection found the method of treatment did not affect the rate of recurrence.²³ The UK recurrent respiratory papillomatosis registry of 1208 procedures performed April 2018 to August 2022 demonstrated that a wide variety of surgical approaches are used across the UK. Analysis from the registry regarding which surgical modalities are most effective in recurrent respiratory papillomatosis has not yet been published, but the most common techniques employed were microdebrider, CO₂ laser, and radiofrequency ablation.²⁴

Repeated surgery at the same anatomic site carries a risk of complications such as mucosal scarring, webbing, impaired vocal cord mobility, and subglottic and glottic stenosis. A recent systematic review and meta-analysis of 20 studies reported a complication rate of 0–44.9 per cent.²⁵ The weighted average complication rate for CO₂ laser treatment was 0.16, for KTP laser was 0.04, and for microdebrider was 0.03.²⁵

Quality of life and economic burden

Recurrent respiratory papillomatosis imposes a substantial QoL burden and economic strain. In the USA, the economic impact linked to non-cervical HPV types 6, 11, 16 and 18 was estimated to be \$418 million annually.²⁶ The annual cost of treating a single case of juvenile-onset recurrent respiratory papillomatosis has been estimated to range from \$58,000 to \$76,115, and for adult-onset recurrent respiratory papillomatosis to range from \$5000 to \$11,000.^{27,28} A UK-based single-centre study reported an annual expenditure of £7677 per adult-onset recurrent respiratory papillomatosis patient.²⁹

Recurrent respiratory papillomatosis can also have a significant effect on a patient's QoL. A recent study by So *et al.* found that 65.7 per cent of patients miss at least five workdays monthly, 79.5 per cent reported social anxiety, and the average lifetime number of surgeries was 20.³⁰ The financial strain on patients is also evident, with over half allocating at least 5 per cent of their annual income towards recurrent respiratory papillomatosis-related medical care. This economic burden on healthcare systems and the considerable effect on patients' QoL emphasizes the pressing need for effective management strategies for recurrent respiratory papillomatosis.

Malignant transformation and surveillance

While recurrent respiratory papillomatosis is clinically a benign disease, the development of dysplasia and transformation to malignancy can occur. The rates of dysplasia reported in the literature are 10–55 per cent in adult-onset recurrent respiratory papillomatosis and 0–10 per cent in juvenile-onset recurrent respiratory papillomatosis.³¹ However, it is unclear if there is a typical progression from dysplasia to invasive malignancy in recurrent respiratory papillomatosis. Factors that are thought to increase the risk for malignant transformation include previous radiotherapy, smoking, older age at diagnosis in adult-onset recurrent respiratory papillomatosis, younger age at diagnosis in juvenile-onset recurrent respiratory papillomatosis, and the HPV subtype.^{31–33}

Human papillomavirus subtypes 11, 16 and 18 are considered higher risk for malignant transformation,³¹ although it has still been reported to occur with HPV 6 infection.³⁴ With this in mind, there is evidence from case reports that the HPV subtypes present in the papilloma of an individual can change during the lifetime of their recurrent respiratory papillomatosis disease. Doyle *et al.* reported a case of juvenile-onset recurrent respiratory papillomatosis where HPV 6 and 11 subtypes were detected initially, but with repeated biopsy over an 8-year period there was subsequent detection of HPV 16.³⁵ Fancello *et al.* reported a case of adult-onset recurrent respiratory papillomatosis where only HPV 6 was detected on biopsy at the three initial surgeries, but upon repeat surgery and biopsy 3 years later both HPV 6 and HPV 18 subtypes were detected.³⁶ This would suggest that repeat biopsies should be performed in patients when there is clinical suspicion of progression or spread of disease, as well as at regular intervals as part of routine surveillance to detect any change in HPV subtype.

While the exact pathogenesis remains unclear, the risk of malignant transformation in laryngeal recurrent respiratory papillomatosis is estimated to be 3–7 per cent in adults and less than 1 per cent in children.³⁷ However, up to 8.9 per cent of patients with recurrent respiratory papillomatosis will have pulmonary involvement, which carries a 32-fold increased lifetime risk of malignant transformation (range 11.7–16 per cent) compared with the overall recurrent respiratory papillomatosis population.³⁸

A clinical algorithm for screening and surveillance of pulmonary involvement in recurrent respiratory papillomatosis, based on known risk factors, was developed by Pai *et al.* and published in 2022.³⁸ The algorithm proposes performing a low-dose computed tomography (CT) thorax scan in all adult-onset recurrent respiratory papillomatosis patients at the time of initial diagnosis. In juvenile-onset recurrent respiratory papillomatosis patients the Pai *et al.*³⁸ algorithm recommends performing low-dose CT at 7 years of age in those with risk factors and at 18 years of age in those without. If no pulmonary nodules or cysts are detected, then the recommendation is for a surveillance low-dose CT thorax scan every five years. If a nodule or cyst is detected then, depending on its size, either close monitoring with interval surveillance low-dose CT or further diagnostic workup is required.

However, the Pai *et al.*³⁸ clinical algorithm does not specifically address management of patients where tracheal or proximal bronchial disease is identified at laryngo-tracheo-bronchoscopy. These patients may not necessarily have appreciable disease on cross-sectional imaging, but the presence of papilloma in these regions is a sign of more aggressive recurrent respiratory papillomatosis disease³⁷ and confers a

higher risk of progression to pulmonary involvement.³⁹ To our knowledge, there is no published recommendation for radiological surveillance in this patient cohort. Within our department, after discussion with specialist colleagues in radiology and respiratory, we have reached a consensus to perform an interval surveillance low-dose CT every two years in these patients.

As HPV infection is also a risk factor for the development of cervical and oropharyngeal malignancy, many patients worry that recurrent respiratory papillomatosis might lead to one of these types of cancer in the future or put their sexual partners at risk. However, the few studies that have addressed concurrent infection in the head and neck and genital tracts suggest that oral oncogenic HPV infection occurs independently of cervical oncogenic HPV infection.⁴⁰

Current adjuvant treatments

While surgical intervention is the mainstay of management for recurrent respiratory papillomatosis, approximately 20 per cent of patients will require adjuvant treatments to achieve disease control.⁴¹ Accepted criteria for considering initiation of adjuvant treatment include disease requiring four or more surgeries per year, rapid regrowth of lesions with airway compromise, or spread of disease to the distal airway.³⁷

The next paragraphs describe the different available adjuvant therapies in detail.

Gardasil vaccine

Gardasil is an HPV vaccine prepared from purified virus-like particles of the major capsid L1 protein that is found on the external surface of the virus.⁴² The initial quadrivalent Gardasil vaccine was approved for use in 2006 against HPV strains 6, 11, 16, and 18. A 9-valent vaccine Gardasil-9 was subsequently approved for use against the additional strains of 31, 33, 45, 52, and 58 in 2014.⁴³

Gardasil vaccination leads to a persistent neutralising antibody response and has been shown to have a profound effect on the prevention of recurrent respiratory papillomatosis in countries where vaccination rates are high, such as in Australia where they demonstrated a significant decrease in the incidence of recurrent respiratory papillomatosis from 0.16 to 0.02 per 100 000 children.⁴⁴ Furthermore, there is increasing evidence that national Gardasil vaccination programs are cost-effective and have a positive effect on public health by reducing the burden of HPV-related diseases, including HPV-associated cancer.^{45–47}

Gardasil vaccination is also thought to have a role as an adjuvant treatment. A 2019 systematic review and meta-analysis of 63 patients from 5 studies found that the mean interval between surgical procedures increased from 7.02 months to 34.45 months.⁴⁸ An updated meta-analysis in 2023 of 101 patients from three studies reported an estimated overall reduction of 0.123 recurrences or surgeries per month following Gardasil vaccination.⁴⁹ These findings suggest that HPV vaccination is effective as both a preventative measure and a therapeutic adjunct that can reduce the frequency of surgical interventions required by recurrent respiratory papillomatosis patients.

The American Academy of Otolaryngology-Head & Neck Surgery released a position statement in 2021 supporting the use of Gardasil-9 vaccination in all recurrent respiratory papillomatosis patients 9–45 years of age.⁵⁰ Its use in patients under

9 or over 45 years of age is considered “off-label” and therefore its use in these patients should be based on a shared-decision-making process. While not contraindicated, there is a lack of evidence regarding the potential benefits of administration of the Gardasil-9 vaccination to patients with recurrent respiratory papillomatosis who have previously received the quadrivalent Gardasil vaccine.⁵¹ However, a large randomized, double-blinded, placebo-controlled trial published in 2015 investigated the effect of administering the Gardasil-9 vaccine to healthy adolescent and adult females who had previously received the quadrivalent Gardasil vaccine.⁵² The study found that administration of the Gardasil-9 vaccine was safe and well tolerated, and led to seroconversion in more than 98 per cent of participants with significant increases in antibody titres to all 9 HPV sub-types. The practice at our centre is to offer Gardasil-9 vaccination to both unvaccinated recurrent respiratory papillomatosis patients and those who have previously received the quadrivalent Gardasil vaccine.

Intralesional Cidofovir

Cidofovir, a cytosine nucleotide analogue, exhibits its antiviral action by incorporating into the DNA chain of viruses and inhibiting the viral DNA polymerization process. Its long intracellular half-life leads to an antiviral effect that can last from several days to weeks. While the FDA approved Cidofovir for the treatment of cytomegalovirus (CMV) retinopathy in acquired immunodeficiency syndrome (AIDS), it has been used off-label intralesionally for recurrent respiratory papillomatosis since 1998.⁵³

Optimal timing and dosing for Cidofovir treatment in recurrent respiratory papillomatosis lacks consensus. A 2013 study of 82 surgeons concluded that standalone indications for use included a requirement for six or more operations/year, increasing frequency of surgery, or extra-laryngeal spread in paediatric patients.⁵⁴ Initiation should be considered in patients who exhibited a combination of factors such as requiring four or more operations per year, persistent disease at the anterior or posterior commissures, and failure to respond to their current surgical regime. While most surgeons reported administering up to five injections to determine efficacy for the patient, some allowed up to 10 injections, and others did not observe a limit. Typical doses used are 20–40 mg (< 4 ml) in adults and 20 mg (< 2 ml) in paediatrics, with scheduled administration every 3–6 weeks. Safe total dosing limits for Cidofovir were deemed to be 3 mg/kg.⁵¹

Regarding efficacy, a Cochrane review in 2012 of 92 publications found insufficient evidence to support the efficacy of intralesional Cidofovir over placebo.⁵⁵ The review included one randomized controlled trial published in 2008 of 15 adults and 4 children.⁵⁶ Although significant improvement in the Derkey Severity Score³ (measure of disease extent) within the Cidofovir and placebo groups was found at 2- and 12-month follow-ups, no significant difference was found between Cidofovir and placebo groups, nor any difference between groups, in the number of procedures performed. However, a more recent literature review conducted in 2020 reported that intralesional Cidofovir achieved a complete response rate in 74 per cent of 185 patients with adult-onset recurrent respiratory papillomatosis and 56.5 per cent of 85 patients with juvenile-onset recurrent respiratory papillomatosis.⁵⁷ The mean concentration used in the studies was 7.5 mg/ml, and the mean number of injections was 6, with 26 days between injections.

With regard to adverse effects, concerns have been raised regarding intralesional Cidofovir administration and the development of vocal fold scarring. While a porcine model showed no effect after a course of four injections of up to 5 mg (10 mg/mL) doses of intralaryngeal Cidofovir to the porcine vocal fold,⁵⁸ a canine model showed dose-dependent irreversible atrophy and scarring of the canine vocal fold after a course of 12 injections of 20 mg (40 mg/mL) or 37.5 mg (75 mg/mL) doses.⁵⁹ Cidofovir is also contraindicated during pregnancy due to potential teratogenicity, and there have been concerns raised about the risk of nephrotoxicity as well as possible carcinogenesis. With regards to nephrotoxic effects, these are known to be dose-dependent and have only been observed with high-dose systemic administration.⁶⁰

The concern regarding carcinogenesis stems from toxicology studies performed in rodents which were terminated early due to the development of mammary adenocarcinoma.⁶¹ However, the total doses delivered were greater than the equivalent human systemic exposure received at the recommended dose for CMV retinopathy, and it should be noted that the development of mammary adenocarcinoma is a frequent occurrence in rodent pharmacological studies. These findings were not replicated in similar primate studies, albeit at intravenous doses equivalent to 0.7 times the human systemic exposure.⁶² Concerns regarding a possible dysplastic effect of the drug were raised in a case, reported by Wemer *et al.* in 2005, of progressive dysplasia seemingly associated with intralesional administration of Cidofovir in a patient with adult-onset recurrent respiratory papillomatosis.⁶³ However, a subsequent international retrospective study of 635 adult-onset recurrent respiratory papillomatosis patients demonstrated no differences in renal dysfunction or the incidence of upper airway and tracheal malignancies between Cidofovir and non-Cidofovir groups.⁶⁴

Intralesional Bevacizumab

Bevacizumab is a human monoclonal antibody that can bind to and inhibit vascular endothelial growth factor expressed on papilloma epithelium. This subsequently inhibits angiogenesis, which is thought to be a crucial factor in determining the rate of papilloma recurrence. Both systemic and intra-lesional administration have been described for the treatment of recurrent respiratory papillomatosis, with the first systemic use reported in 2009.⁶⁵

The efficacy of Bevacizumab as a treatment option was assessed in a recent systematic review published in 2022.⁶⁶ Sixty-four patients were included from 15 case series or case report studies, with 54 of the 64 patients having juvenile-onset recurrent respiratory papillomatosis. When administered intralesionally, Bevacizumab was not found to be as effective as systemic administration, with only 62 per cent (13 out of 21) of patients showing a prolongation in the post-treatment surgical interval (4–12 weeks) compared to the pre-treatment interval (2–6 weeks). The occurrence of side effects was discussed in eight of the reported cases, with no side effects found.

The intra-lesional efficacy of Bevacizumab was further assessed in a randomised, placebo-controlled trial of 16 participants (5 children, 11 adults) comparing Bevacizumab to Cidofovir after cold steel papilloma resection.⁶⁷ Cidofovir exhibited a significant Derkey Severity Score decrease after one year ($p = 0.027$), while Bevacizumab and placebo showed no significant changes. All treatment groups experienced a significant decrease in voice handicap index score ($p < 0.001$), attributed to surgical papilloma resection.

Systemic Bevacizumab

A 2021 Delphi study involving 70 international experts provided consensus statement on systemic Bevacizumab use in recurrent respiratory papillomatosis.⁶⁸ The consensus suggested that age at surgery or at time of diagnosis should not be a deciding factor in the treatment of patients with recurrent respiratory papillomatosis, with both paediatric and adult patients open to consideration. Disease characteristics that were supported by consensus or near-consensus included progressive and/or severe disease burden, disease in locations difficult to treat, need for tracheostomy due to disease burden, and increasing Derkey Severity Score over the preceding year.

Systemic Bevacizumab appears to be more effective than intralesional administration for the treatment of recurrent respiratory papillomatosis.⁶³ Systemic treatment with Bevacizumab led to considerably longer surgical intervals in 95 per cent (41 out of 43 cases) of patients post-treatment (3–17 months) compared to pre-treatment (1–8.6 weeks). In 55 per cent (24 out of 43) of patients, no further surgical interventions were required during follow up. Side effects were observed in 44 per cent (19 out of 43) of patients and included proteinuria, epistaxis, haemoptysis, hypertension, headache, thrombocytopenia, hyperthyroidism and nausea. However, these were all classified as mild and self-limiting.

There is no universally adopted dosing protocol for the use of systemic Bevacizumab as an adjuvant treatment in recurrent respiratory papillomatosis. One suggested regime following standard chemotherapy guidelines is a 10 mg/kg target dose with infusions given initially every 3–4 weeks for 6 cycles, before a maintenance regime of infusions every three months for two years with surveillance laryngo-trachea-bronchoscopies.⁶⁹

Potential future adjuvant treatments

While Cidofovir may block replication of HPV and Bevacizumab may block blood supply to the papilloma, neither result in clearance of the virus. Based on current understanding of antiviral immune responses, the only rational strategy to clear HPV-infected epithelial cells is through activation of the cytotoxic T-lymphocyte arm of the adaptive immune response. Activation of HPV immunity may clear the virus and cure the infection.⁷⁰ Immunotherapies, such as immune checkpoint blockade or engineered therapeutic vaccines, may provide a path toward tolerable and efficacious adjuvant immunotherapy for recurrent respiratory papillomatosis.

DNA vaccines

DNA vaccine technology involves encoding the DNA sequence of a specific monoclonal antibody in a DNA plasmid, which is then delivered directly into cells of the body by electroporation. The host cells then manufacture the monoclonal antibody in vivo and stimulate an immune response.⁷¹ DNA vaccines are a potentially promising novel therapeutic agent for the treatment of recurrent respiratory papillomatosis and there is current clinical-stage research ongoing in this field.

INO-3107 vaccine

The biotechnology company INOVIO published the results of a phase-1 study of their product INO-3106 in 2020⁷² and are currently undergoing phase 1/2 clinical trial for their product

INO-3107.⁷³ These products, which contain DNA immunotherapy designed to elicit targeted T-cell responses against HPV 6 and HPV 11, are delivered by intramuscular injection followed by electroporation. The treatment induces activated CD4 T cells and activates CD8 T cells with lytic potential, and the percentages are similar for HPV 6 and HPV 11. The open-label, multi-centre trial enrolled 32 participants with recurrent respiratory papillomatosis and administered four doses of the INO-3107 vaccine three weeks apart. For inclusion, participants must have required at least two surgical interventions per year for the past year for the removal of HPV 6- or HPV 11-associated papilloma. The primary outcome was the change in median number of surgical interventions in the year prior to Day 0 compared with the year following Day 0. In the reported preliminary results, 26 out of 32 (81.3 per cent) of participants had a significant reduction in the number of surgical interventions required, with a median decrease of three surgical interventions. Ten out of these 26 participants required no surgical intervention during the follow-up period. The vaccine was shown to induce T-cell responses against both HPV 6 and HPV 11. This was still observed at week 52, suggesting a persistent cellular memory response. The INO-3107 vaccine was generally well tolerated, with all patients completing the follow up. The results support further investigation of INO-3107 plus electroporation, with a confirmatory trial currently being planned as part of INOVIO's biological licence application submission to the U.S. Food and Drug Administration.⁷⁴

NIH PRGN-2012 vaccine

The NIH PRGN-2012 vaccine, developed by Precigen, is a subcutaneous injection of gorilla adenovirus encoding HPV DNA designed to elicit immune responses directed against HPV 6 and HPV 11. A preclinical study in 2021 showed that it induces low-risk HPV antigen-specific responses in in-vitro stimulation of peripheral T lymphocytes from patients with recurrent respiratory papillomatosis. In-vivo therapeutic vaccination of mice bearing established HPV 6 E6-expressing tumours resulted in HPV 6 E6-specific CD8 + T-lymphocyte immunity of sufficient magnitude to induce tumour growth delay.⁷⁵ A non-randomised, phase 1/2 safety and tolerability study is in progress and estimated to be completed in 2026.⁷⁶

Pembrolizumab

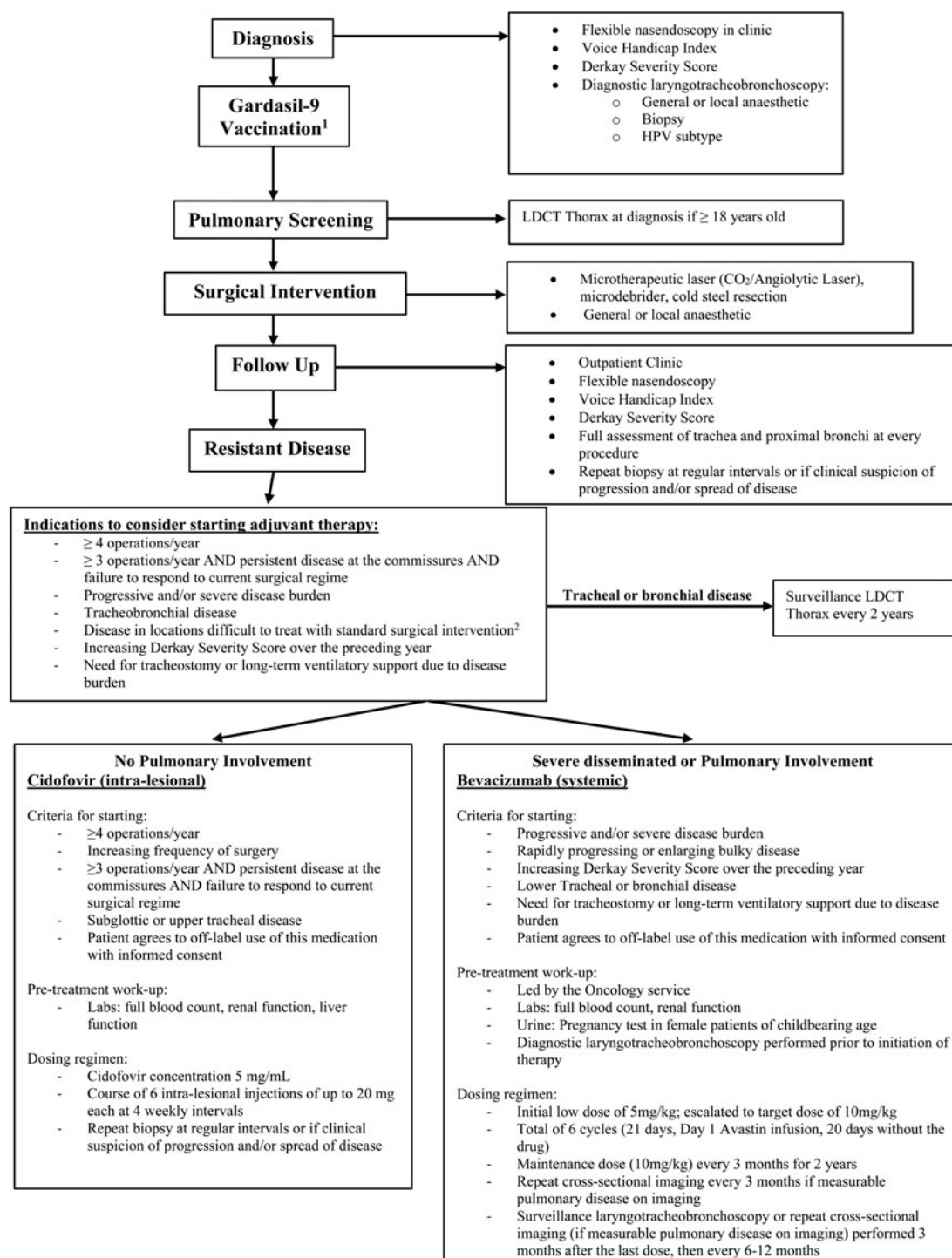
Pembrolizumab is a humanized monoclonal antibody that acts as a PD-1 receptor inhibitor on T cells.⁷⁷ By inhibiting PD-1 receptors, Pembrolizumab leads to activation of T cells and an immune response against potentially abnormal cells, such as tumour cells or the HPV-infected cells in recurrent respiratory papillomatosis. The efficacy and safety of Pembrolizumab monotherapy is currently being investigated in a phase 2 clinical trial of 21 patients (10 juvenile-onset recurrent respiratory papillomatosis, 11 adult-onset recurrent respiratory papillomatosis, 62 per cent trachea-pulmonary involvement).⁷⁸ Preliminary results from the trial found that 57 per cent of patients (7 of 10 juvenile-onset recurrent respiratory papillomatosis, 5 of 11 adult-onset recurrent respiratory papillomatosis) had a partial response. Stable disease was reported in 7 out of 21 patients. No complete responses were observed. Surgical interventions were reduced by a mean of seven operations per year in patients treated with Pembrolizumab for more than 12

months. However, only 62 per cent (13 of 21) patients completed the 24 months of treatment, with reasons for discontinuation including disease progression, treatment-related adverse events, and study withdrawal. Overall, the preliminary results suggest that while Pembrolizumab reduced the need for routine surgical intervention there appears to be variable response in the reduction of tumour burden.

Discussion

Among the available adjuvant treatments, systemic Bevacizumab appears to be the most effective, consistently

resulting in extended surgical intervals post treatment, and notably, a substantial proportion of patients experiencing no further need for surgical interventions.⁶³ In comparison, intralesional Bevacizumab exhibits a less pronounced effect, achieving a smaller increase in surgical intervals in a lower percentage of patients.^{63,64} Systemic Bevacizumab is associated with a risk of side effects that is not seen with intralesional administration. While these tend to be mild or moderate in grade, clinical and biochemical monitoring of patients throughout the treatment course and follow-up period is required to promptly recognise and address any adverse effects.⁶³



¹Three doses of Gardasil-9 vaccine given intramuscularly at 0, 2, & 6 months.

Consider offering Gardasil-9 vaccination even if a patient has previously received the quadrivalent Gardasil vaccination.

²Tracheal, bronchial, pulmonary, persistent disease at the commissures.

Figure 2. Recurrent respiratory papillomatosis adult management guideline; LDCT = low-dose computed tomography; HPV = human papillomavirus.

While evidence supporting a reduction in the frequency of surgical procedures after intralesional Cidofovir is limited, it demonstrates a reasonable complete response rate, particularly in patients with adult-onset recurrent respiratory papillomatosis.⁵⁴ Concerns have been raised regarding possible nephrotoxic and oncogenic effects of Cidofovir, but these risks appear to be associated only with higher-dose systemic administration with no existing evidence that strongly supports an association between intralesional Cidofovir and renal dysfunction or dysplasia.^{57,61}

- Surgical intervention is the mainstay of management for recurrent respiratory papillomatosis, but approximately 20 per cent of patients will require adjuvant medical treatments to achieve disease control
- Systemic Bevacizumab appears to be the most effective adjuvant treatment currently available, consistently resulting in extended surgical intervals post-treatment, and a substantial proportion of patients experiencing no further need for surgical interventions
- While evidence supporting a reduction in the frequency of surgical procedures after intralesional Cidofovir is limited, it demonstrates a reasonable complete response rate when used as an adjuvant treatment, particularly in patients with adult-onset recurrent respiratory papillomatosis
- The Gardasil vaccine demonstrates efficacy as a preventative measure and therapeutic adjunct that can lead to reduced recurrence rates and prolonged surgical intervals
- Based on the current literature, we have developed a management guideline for adult patients with recurrent respiratory papillomatosis that aims to assist with the identification of patients who have resistant disease where adjuvant treatment should be considered and guide their subsequent management with intralesional Cidofovir or systemic Bevacizumab

The Gardasil vaccine has been demonstrated to be valuable as both a preventative measure and therapeutic adjunct that can lead to reduced recurrence rates and prolonged surgical intervals. Widespread vaccination of pre-adolescent children is expected to reduce the incidence of HPV genital warts. This, in turn, will decrease the risk of vertical HPV transmission, ultimately lowering the incidence of juvenile-onset recurrent respiratory papillomatosis and overall recurrent respiratory papillomatosis.

There are several potential future immunotherapy and DNA vaccine-based adjuvant treatments on the horizon. The most promising of these is the INO-3107 DNA vaccine, with phase 2 trials reporting a significant reduction in the average number of surgical interventions for most participants, with some requiring no surgical interventions during the follow-up period, as well as persistent T-cell responses.⁷⁰ Further plans are currently being developed for a confirmatory trial.

The economic burden associated with recurrent respiratory papillomatosis and the financial cost of treatment are considerable. While several adjuvant treatments are available, the financial implications of each for a healthcare system should be taken into consideration. This is particularly important in government-funded healthcare settings such as the National Health Service in the UK, where the cost of treatment can significantly limit access and availability. Whilst administration of the Gardasil-9 vaccine has been reported to cost £259,²⁹ the estimated cost of systemic Bevacizumab is more than £1500 per infusion based on a 70-kg patient at a 10 mg/kg dose.⁸⁰ To commence a patient with recurrent respiratory papillomatosis on systemic Bevacizumab in the NHS, a clinician is required to complete an individual funding request that specifically explains the clinical circumstances that warrant this treatment.

Based on the current literature, we have developed a management guideline for adult patients with recurrent respiratory papillomatosis to be used in our tertiary centre in the UK (Figure 2). The guideline aims to assist with the identification of patients who have resistant disease where adjuvant treatments should be considered. The presence of severe disseminated disease or pulmonary involvement, and thus the risk of malignant transformation, is used to determine whether adjuvant treatment with intralesional Cidofovir or systemic Bevacizumab is likely to be more beneficial for the individual patient. For each of these adjuvant treatments, our guideline details the pre-treatment work-up required, the dosing regime, and the follow-up surveillance required.

Limitations

We recognise that our review has some limitations in that we did not perform a systematic review and meta-analysis. However, lack of uniformity in study designs, small sample sizes, and variations in treatment protocols and outcome measures across different studies lead to inherent heterogeneity of the available data that would have limited the value of doing so. To improve our understanding of the indications and optimal dosing regimens, future prospective studies, including randomised controlled trials, comparing different adjuvant treatments with standardised outcome measures would be invaluable.

Conclusions

Recurrent respiratory papillomatosis is a rare but chronic disease that can require lifelong treatment that has a significant impact on quality of life as well as placing a substantial economic burden on a healthcare system. This review provides a detailed examination of current and potential future adjuvant treatments for recurrent respiratory papillomatosis and proposes a management guideline for adult patients based on the current literature. Further prospective studies and randomised controlled trials are essential to refine treatment and enhance our understanding of optimal dosing regimens for these adjuvant therapies.

Financial support. This research received no specific grant funding from any funding agency, commercial or not-for-profit sectors.

Competing interests. The authors declare none.

References

- 1 San Giorgi MRM, van den Heuvel ER, Tjon REA, Brunings JW, Chirila M, Friedrich G *et al.* Age of onset of recurrent respiratory papillomatosis: a distribution analysis. *Clin Otolaryngol* 2016;**41**:448–53
- 2 Derkay CS, Wiatrak B. Recurrent respiratory papillomatosis: a review. *Laryngoscope* 2008;**118**:1236–47
- 3 Derkay CS, Malis DJ, Zalzal G, Wiatrak BJ, Kashima HK, Coltrera MD. A staging system for assessing severity of disease and response to therapy in recurrent respiratory papillomatosis. *Laryngoscope* 1998;**108**:935–7
- 4 Kupfer RA, Tatar EÇ, Barry JO, Allen CT, Merati AL. Anatomic Derkay score is associated with voice handicap in laryngeal papillomatosis in adults. *Otolaryngol Head Neck Surg* 2016;**154**:689–92
- 5 Fortes HR, von Ranke FM, Escuissato DL, Araujo Neto CA, Zanetti G, Hochegger B *et al.* Recurrent respiratory papillomatosis: a state-of-the-art review. *Respir Med* 2017;**126**:116–21
- 6 Oh ST, Longworth MS, Laimins LA. Roles of the E6 and E7 proteins in the life cycle of low-risk human papillomavirus type 11. *J Virol* 2004;**78**:2620–6
- 7 Syrjänen K, Hakama M, Saarikoski S, Väyrynen M, Yliskoski M, Syrjänen S *et al.* Prevalence, incidence, and estimated life-time risk of cervical

- human papillomavirus infections in a nonselected Finnish female population. *Sex Transm Dis* 1990;**17**:15–19
- 8 Sivasankar M, Erickson E, Rosenblatt M, Branski RC. Hypertonic challenge to porcine vocal folds: effects on epithelial barrier function. *Otolaryngol Head Neck Surg* 2009;**142**:79–84
 - 9 Bonagura VR, Hatam LJ, Rosenthal DW, De Voti JA, Lam F, Steinberg BM *et al.* Recurrent respiratory papillomatosis: a complex defect in immune responsiveness to human papillomavirus-6 and -11. *APMIS* 2010;**118**:455–70
 - 10 Welschmeyer A, Berke GS. An updated review of the epidemiological factors associated with recurrent respiratory papillomatosis. *Laryngoscope Investig Otolaryngol* 2021;**6**:226–33
 - 11 Tjon Pian Gi REA, San Giorgi MRM, Slagter-Menkema L, van Hemel BM, van der Laan BFAM, van den Heuvel ER *et al.* Clinical course of recurrent respiratory papillomatosis: comparison between aggressiveness of human papillomavirus-6 and human papillomavirus-11. *Head Neck* 2015;**37**:1625–32
 - 12 Buchinsky FJ, Valentino WL, Ruszkay N, Powell E, Derkay CS, Seedat RY *et al.* Age at diagnosis, but not HPV type, is strongly associated with clinical course in recurrent respiratory papillomatosis. *PLoS One* 2019;**14**:e0216697
 - 13 Rombaldi RL, Serafini EP, Mandelli J, Zimmermann E, Losquiavo KP. Transplacental transmission of human papillomavirus. *Virol J* 2008;**5**:106
 - 14 Silverberg MJ, Thorsen P, Lindeberg H, Grant LA, Shah KV. Condyloma in pregnancy is strongly predictive of juvenile-onset recurrent respiratory papillomatosis. *Obstet Gynecol* 2003;**101**:645–52
 - 15 Kashima HK, Shah F, Lyles A, Glackin R, Muhammad N, Turner L *et al.* A comparison of risk factors in juvenile-onset and adult-onset recurrent respiratory papillomatosis. *Laryngoscope* 1992;**102**:9–13
 - 16 Ruiz R, Achlatis S, Verma A, Born H, Kapadia F, Fang Y *et al.* Risk factors for adult-onset recurrent respiratory papillomatosis. *Laryngoscope* 2014;**124**:2338–44
 - 17 Rasmussen ER, Schnack DT, Jørkov AS, Raja AA, Olsen CH, Homøe P. Long-term follow-up and outcome in patients with recurrent respiratory laryngeal papillomatosis. *Dan Med J* 2017;**64**:A5424
 - 18 Armstrong LR, Derkay CS, Reeves WC. Initial results from the national registry for juvenile-onset recurrent respiratory papillomatosis. RRP task force. *Arch Otolaryngol Head Neck Surg* 1999;**125**:743–8
 - 19 Reeves WC, Ruparelia SS, Swanson KI, Derkay CS, Marcus A, Unger ER. National registry for juvenile-onset recurrent respiratory papillomatosis. *Arch Otolaryngol Head Neck Surg* 2003;**129**:976–82
 - 20 Hess MM, Fleischer S, Ernstberger M. New 445 nm blue laser for laryngeal surgery combines photoangiolytic and cutting properties. *Eur Arch Otorhinolaryngol* 2018;**275**:1557–67
 - 21 Hamdan AL, Ghanem A. Un-sedated office-based application of blue laser in vocal fold lesions. *J Voice* 2023;**37**:785–9
 - 22 Hock K, Kennedy A, Howell R, Friedman A, de Alarcon A, Khosla S. Surgery and adjuvant therapy improve Derkay scores in adult and pediatric respiratory papillomatosis. *Laryngoscope* 2022;**132**:2420–6
 - 23 Preuss SF, Klusmann JP, Jungelhulsing M, Eckel HE, Guntinas-Lichius O, Damm M. Long-term results of surgical treatment for recurrent respiratory papillomatosis. *Acta Otolaryngol* 2007;**127**:1196–201
 - 24 Northern Medical Physics and Clinical Engineering. Airway Intervention Registry: Recurrent Respiratory Papillomatosis (AIR: RRP). In: <https://rrp.org.uk/results/> [3 December 2023]
 - 25 Liu S, Wang J, Shao J. Safety of different surgical modalities for recurrent respiratory papillomatosis resection: a systematic review and meta-analysis. *Clin Otolaryngol* 2023;**48**:403–13
 - 26 Hu D, Goldie S. The economic burden of noncervical human papilloma-virus disease in the United States. *Am J Obstet Gynecol* 2008;**198**:500.e1–7
 - 27 Bishai D, Kashima H, Shah K. The cost of juvenile-onset recurrent respiratory papillomatosis. *Arch Otolaryngol Head Neck Surg* 2000;**126**:935–9
 - 28 Tam S, Wu CF, Peng HL, Dahlstrom KR, Sturgis EM, Lairson DR. Cost of treating recurrent respiratory papillomavirus in commercially insured and Medicaid patients. *Laryngoscope* 2020;**130**:1186–94
 - 29 Harrison A, Montgomery J, Macgregor FB. Economic impact of recurrent respiratory papillomas in a UK adult population. *J Laryngol Otol* 2016;**130**:645–9
 - 30 So RJ, McClellan K, Best SR. Recurrent respiratory papillomatosis: quality of life data from an international patient registry. *Laryngoscope* 2023;**133**:1919–26
 - 31 Karatayli-Ozgursoy S, Bishop JA, Hillel A, Akst L, Best SRA. Risk factors for dysplasia in recurrent respiratory papillomatosis in an adult and pediatric population. *Ann Otol Rhinol Laryngol* 2016;**125**:235–41
 - 32 Majoros M, Devine KD, Parkhill EM. Malignant transformation of benign laryngeal papillomas in children after radiation therapy. *Surg Clin North Am* 1963;**43**:1049–61
 - 33 Donne AJ, Hampson L, Homer JJ, Hampson IN. The role of HPV type in recurrent respiratory papillomatosis. *Int J Pediatr Otorhinolaryngol* 2010;**74**:7–14
 - 34 Zarod AP, Rutherford JD, Corbitt G. Malignant progression of laryngeal papilloma associated with human papilloma virus type 6 (HPV-6) DNA. *J Clin Pathol* 1988;**41**:280–3
 - 35 Doyle DJ, Henderson LA, LeJeune FE Jr, Miller RH. Changes in human papillomavirus typing of recurrent respiratory papillomatosis progressing to malignant neoplasm. *Arch Otolaryngol Head Neck Surg* 1994;**120**:1273–6
 - 36 Fancello V, Melis A, Piana AF, Castiglia P, Cossu A, Sotgiu G *et al.* HPV Type 6 and 18 coinfection in a case of adult-onset laryngeal papillomatosis: immunization with Gardasil. *Case Rep Otolaryngol* 2015;**2015**:916023
 - 37 Alanazi A, Karas AF, Husain IA. Recurrent respiratory papillomatosis: an update. *Int J Head Neck Surg* 2022;**13**:1
 - 38 Pai SI, Wasserman I, Ji YD, Gilman M, Hung YP, Faquin WC *et al.* Pulmonary manifestations of chronic HPV infection in patients with recurrent respiratory papillomatosis. *Lancet Respir Med* 2022;**10**:997–1008
 - 39 Yang Q, Li Y, Ma L, Xiao Y, Wang H, Ding Y *et al.* Long-term outcomes of juvenile onset recurrent respiratory papillomatosis with pulmonary involvement. *Laryngoscope* 2021;**131**:EE2277–83
 - 40 Wierzbicka M, Klusmann JP, San Giorgi MR, Wuerdemann N, Dikkers FG. Oral and laryngeal HPV infection: incidence, prevalence and risk factors, with special regard to concurrent infection in head, neck and genitals. *Vaccine* 2021;**39**:2344–50
 - 41 Schraff S, Derkay CS, Burke BL, Lawson LB. American Society of Pediatric Otolaryngology members' experience with recurrent respiratory papillomatosis and the use of adjuvant therapy. *Arch Otolaryngol Head Neck Surg* 2004;**130**:1039–42
 - 42 Harper DM, DeMars LR. HPV vaccines – a review of the first decade. *Gynecol Oncol* 2017;**146**:196–204
 - 43 Benedict JJ, Derkay CS. Recurrent respiratory papillomatosis: a 2020 perspective. *Laryngoscope Investig Otolaryngol* 2021;**6**:340–45
 - 44 Novakovic D, Cheng ATL, Zurynski Y, Booy R, Walker PJ, Berkowitz R *et al.* A prospective study of the incidence of juvenile-onset recurrent respiratory papillomatosis after implementation of a national HPV vaccination program. *J Infect Dis* 2018;**217**:208–12
 - 45 Patel C, Brotherton JML, Pillsbury A, Jayasinghe S, Donovan B, Macartney K *et al.* The impact of 10 years of human papillomavirus (HPV) vaccination in Australia: what additional disease burden will a nonavalent vaccine prevent? *Euro Surveill* 2018;**23**:1700737
 - 46 Diakite I, Nguyen S, Sabale U, Paveleyev A, Saxena K, Tajik AA *et al.* Public health impact and cost-effectiveness of switching from bivalent to nonavalent vaccine for human papillomavirus in Norway: incorporating the full health impact of all HPV-related diseases. *J Med Econ* 2023;**26**:1085–98
 - 47 Owusu-Eduesei K, Palmer C, Ovcinnikova O, Favato G, Daniels V. Assessing the health and economic outcomes of a 9-valent HPV vaccination program in the United Kingdom. *J Health Econ Outcomes Res* 2022;**9**:140–50
 - 48 Rosenberg T, Philipsen BB, Mehlum CS, Dyrvig AK, Wehberg S, Chirilă M *et al.* Therapeutic use of the human papillomavirus vaccine on recurrent respiratory papillomatosis: a systematic review and meta-analysis. *J Infect Dis* 2019;**219**:1016–25
 - 49 Goon P, Sauzet O, Schuermann M, Oppel F, Shao SY, Scholtz LU *et al.* Recurrent respiratory papillomatosis (RRP) – meta-analyses on the use of the HPV vaccine as adjuvant therapy. *NPJ Vaccines* 2023;**8**:49
 - 50 American Academy of Otolaryngology-Head and Neck Surgery. Position Statement: Recurrent Respiratory Papillomatosis and Gardasil Vaccination. In: <https://www.entnet.org/resource/position-statement-recurrent-respiratory-papillomatosis-and-gardasil-vaccination/> [14 April 2024]
 - 51 Centers for Disease Control and Prevention. Supplemental information and guidance for vaccination providers regarding use of 9-valent HPV. In: <https://www.cdc.gov/hpv/downloads/9vhpv-guidance.pdf> [14 April 2024]
 - 52 Garland SM, Cheung TH, McNeill S, Petersen LK, Romaguera J, Vazquez-Narvaez J *et al.* Safety and immunogenicity of a 9-valent HPV vaccine in females 12–26 years of age who previously received the quadri-valent HPV vaccine. *Vaccine* 2015;**33**:6855–64
 - 53 Tjon Pian Gi REA, Dietz A, Djukic V, Eckel HE, Friedrich G, Golusinski W *et al.* Treatment of recurrent respiratory papillomatosis and adverse

- reactions following off-label use of cidofovir (Vistide®). *Eur Arch Otorhinolaryngol* 2011;**269**:361–2
- 54 Derkay CS, Volsky PG, Rosen CA, Pransky SM, McMurray JS, Chadha NK *et al.* Current use of intralesional cidofovir for recurrent respiratory papillomatosis. *Laryngoscope* 2013;**123**:705–12
 - 55 Chadha NK, James A. Adjuvant antiviral therapy for recurrent respiratory papillomatosis. *Cochrane Database Syst Rev* 2012;(12):CD005053
 - 56 McMurray JS, Connor N, Ford CN. Cidofovir efficacy in recurrent respiratory papillomatosis: a randomized, double-blind, placebo-controlled study. *Ann Otol Rhinol Laryngol* 2008;**117**:477–83
 - 57 Gazia F, Galletti B, Freni F, Bruno R, Sireci F, Galletti C *et al.* Use of intralesional cidofovir in the recurrent respiratory papillomatosis: a review of the literature. *Eur Rev Med Pharmacol Sci* 2020;**24**:956–62
 - 58 Connor MP, Brown A, Palazzolo M, Kunkel J, Eller R *et al.* Effect of vocal fold injection of cidofovir and bevacizumab in a porcine model. *JAMA Otolaryngol Head Neck Surg* 2014;**140**:155–9
 - 59 Chhetri DK, Jahan-Parwar B, Hart SD, Bhuta SM, Berke GS, Shapiro NL. Local and systemic effects of intralaryngeal injection of cidofovir in a canine model. *Laryngoscope* 2003;**113**:1922–6
 - 60 Lalezari JP, Stagg RJ, Kuppermann BD, Holland GN, Kramer F, Ives DV *et al.* Intravenous cidofovir for peripheral cytomegalovirus retinitis in patients with AIDS. A randomized, controlled trial. *Ann Intern Med* 1997;**126**:257–63
 - 61 Broekema FI, Dikkers FG. Side-effects of cidofovir in the treatment of recurrent respiratory papillomatosis. *Eur Arch Otorhinolaryngol* 2008;**265**:871–9
 - 62 Derkay C, Multi-disciplinary Task Force on Recurrent Respiratory Papillomas. Cidofovir for recurrent respiratory papillomatosis (RRP): a re-assessment of risks. *Int J Pediatr Otorhinolaryngol* 2005;**69**:1465–7
 - 63 Wemer RD, Lee JH, Hoffman HT, Robinson RA, Smith RJH. Case of progressive dysplasia concomitant with intralesional cidofovir administration for recurrent respiratory papillomatosis. *Ann Otol Rhinol Laryngol* 2005;**114**:836–9
 - 64 Tjon Pian Gi REA, Ilmarinen T, van den Heuvel ER, Aaltonen LM, Andersen J, Brunings JW *et al.* Safety of intralesional cidofovir in patients with recurrent respiratory papillomatosis: an international retrospective study on 635 RRP patients. *Eur Arch Otorhinolaryngol* 2013;**270**:1679–87
 - 65 Nagel S, Busch C, Blankenburg T, Schütte W. Treatment of respiratory papillomatosis – a case report on systemic treatment with bevacizumab [in German]. *Pneumologie* 2009;**63**:387–9
 - 66 Pogoda L, Ziyilan F, Smeeing DPJ, Dikkers FG, Rinkel RNPM. Bevacizumab as treatment option for recurrent respiratory papillomatosis: a systematic review. *Eur Arch Otorhinolaryngol* 2022;**279**:4229–40
 - 67 Ablanedo-Terrazas Y, Estrada-Camacho O, Alvarado-de la Barrera C, Ramírez-García A, Tona-Acedo G, Bross-Soriano D *et al.* Efficacy of cidofovir versus bevacizumab in recurrent respiratory papillomatosis: a randomized, double-blind, placebo-controlled pilot study. *Acta Otorrinolaringol Esp (Engl Ed)* 2021;**73**:82–8
 - 68 Sidell DR, Balakrishnan K, Best SR, Zur K, Buckingham J, De Alarcon A *et al.* Systemic bevacizumab for treatment of respiratory papillomatosis: international consensus statement. *Laryngoscope* 2021;**131**:E1941–9
 - 69 Fernandez-Bussy S, Labarca G, Vial MR, Soto R, Mehta HJ, Jantz M *et al.* Recurrent respiratory papillomatosis and bevacizumab treatment. *Am J Respir Crit Care Med* 2018;**197**:539–41
 - 70 Bai K, Allen C. How enhancing immunity to low-risk HPV could cure recurrent respiratory papillomatosis. *Laryngoscope* 2021;**131**:2041–7
 - 71 Sardesai NY, Weiner DB. Electroporation delivery of DNA vaccines: prospects for success. *Curr Opin Immunol* 2011;**23**:421–9
 - 72 Aggarwal C, Cohen RB, Morrow MP, Kraynyak KA, Sylvester AJ, Cheung J *et al.* Immune therapy targeting E6/E7 oncogenes of human papilloma-virus type 6 (HPV-6) reduces or eliminates the need for surgical intervention in the treatment of HPV-6 associated recurrent respiratory papillomatosis. *Vaccines (Basel)* 2020;**8**:56
 - 73 Mau T, Amin MR, Belafsky PC, Best SR, Friedman AD, Klein AM *et al.* Interim results of a phase 1/2 open-label study of INO-3107 for HPV-6 and/or HPV-11-associated recurrent respiratory papillomatosis. *Laryngoscope* 2023;**133**:3087–93
 - 74 INOVIO Pharmaceuticals News Release, January 03 2024: INOVIO Plans to Submit a BLA for INO-3107 as a Potential Treatment for RRP in Second Half of 2024 Under Accelerated Approval Program. In: <https://ir.inovio.com/news-releases/news-releases-details/2024/INOVIO-Plans-to-Submit-a-BLA-for-INO-3107-as-a-Potential-Treatment-for-RRP-in-Second-Half-of-2024-Under-Accelerated-Approval-Program/default.aspx#:~:text=%22Our%20plan%20is%20to%20complete,INO%2D3107%20in%202025.%22> [24 January 2024]
 - 75 Lee MY, Metenou S, Brough DE, Sabzevari H, Bai K, Jochems C *et al.* Preclinical study of a novel therapeutic vaccine for recurrent respiratory papillomatosis. *NPJ Vaccines* 2021;**6**:86
 - 76 National Library of Medicine, Clinical Trials database. In: <https://www.clinicaltrials.gov/study/NCT04724980> [24 January 2024]
 - 77 Kwok G, Yau TCC, Chiu JW, Tse E, Kwong YL. Pembrolizumab (Keytruda). *Hum Vaccin Immunother* 2016;**12**:2777–89
 - 78 Pai SI, Friedman AD, Franco R, Muniappan A, Park JC, Campbell NP *et al.* A phase II study of pembrolizumab for HPV-associated papilloma patients with laryngeal, tracheal, and/or pulmonary involvement. *J Clin Oncol* 2019;**37**:2502 [abstract: 2019 ASCO Annual Meeting]
 - 79 Wangu Z, Hsu KK. Impact of HPV vaccination on anogenital warts and respiratory papillomatosis. *Hum Vaccin Immunother* 2016;**12**:1357–62
 - 80 Bevacizumab (Monograph). <https://www.nice.org.uk/guidance/ta214/chapter/2-The-technology> [3 December 2023]