



## Letter to the Editor: New Observation

# Anti-amphiphysin-positive Progressive Encephalomyelitis with Rigidity and Myoclonus

Yuki Fujii<sup>1</sup>, Yuki Murata<sup>2</sup>, Keiichi Hokkoku<sup>1</sup> , Takashi Chiba<sup>1</sup>, Yuichi Hamada<sup>1,3</sup> , Ayumi Uchibori<sup>4</sup>, Atsuro Chiba<sup>4</sup>, Shunsuke Kobayashi<sup>1</sup> and Masahiro Sonoo<sup>1</sup>

<sup>1</sup>Department of Neurology, Teikyo University School of Medicine, Tokyo, Japan, <sup>2</sup>Department of General Medicine, Itabashi Chuo Medical Center, Japan, <sup>3</sup>Department of Neurology, Sumitomo Hospital, Osaka, Japan and <sup>4</sup>Department of Neurology, Kyorin University School of Medicine, Tokyo, Japan

**Keywords:** Stiff-person spectrum disorders; Progressive encephalomyelitis with rigidity and myoclonus; Anti-amphiphysin antibodies; Somatosensory evoked potentials

Progressive encephalomyelitis with rigidity and myoclonus (PERM) is a variant of stiff-person syndrome (SPS), characterized by muscle stiffness, myoclonus, dysautonomia, cognitive abnormalities, and brainstem dysfunction.<sup>1</sup> Because clinical conditions of PERM and SPS are continuous and overlapping, they are collectively called stiff-person spectrum disorders (SPSD). Auto-antibodies associated with SPS and PERM also overlap, but the prevalence of associated antibodies differs; specifically, anti-glutamic acid decarboxylase antibodies (anti-GAD) are most common in SPS, and anti-glycine- $\alpha$ 1 receptor antibodies (anti-GlyR) are most common in PERM.<sup>1</sup> Anti-amphiphysin antibodies are a marker of paraneoplastic SPS,<sup>2</sup> but their association with PERM is rare; the clinical picture of anti-amphiphysin-positive PERM has not been well established.<sup>3–5</sup>

Diagnosis of PERM is often challenging because it is rare and shows unusual clinical symptoms, often lacking objective findings in conventional laboratory tests and imaging studies. Additionally, a recent study has disputed the reliability of commercial immunoblots commonly used for anti-amphiphysin antibodies.<sup>6</sup> Thus, clinical tests objectively capture the pathophysiology of PERM are important for the diagnosis.

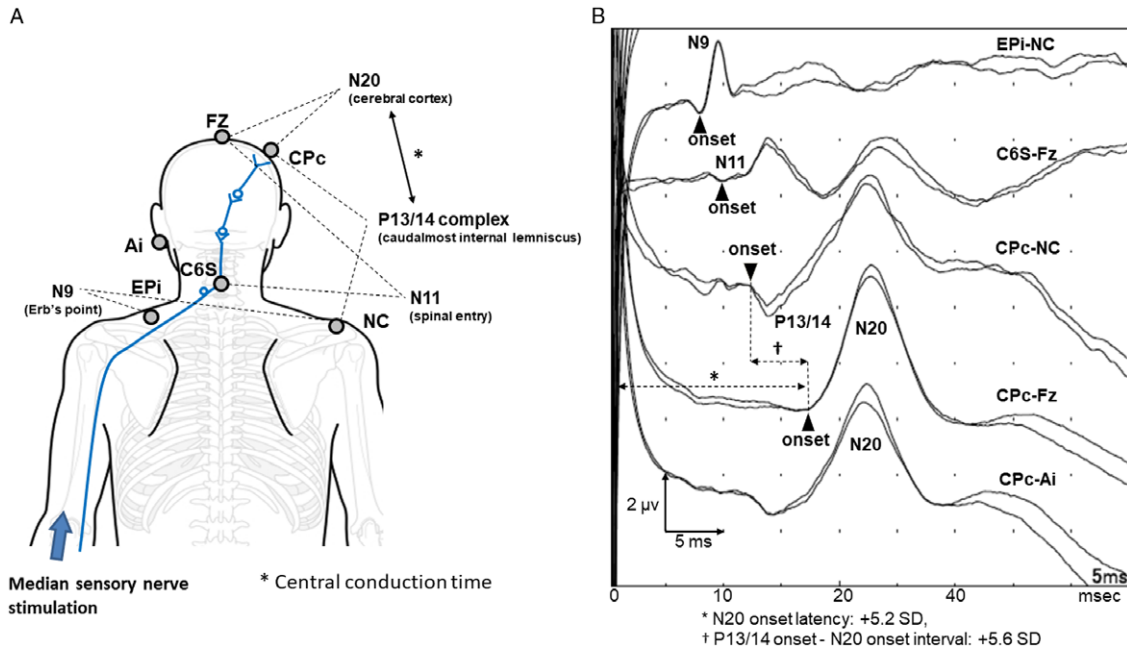
Here, we report a case of anti-amphiphysin-positive PERM in which anti-amphiphysin antibodies were detected by immunohistochemistry in addition to commercial immunoblot, the gold-standard diagnostic testing approach. We discuss the utility of somatosensory evoked potentials (SEPs) in detecting central nervous system involvements in PERM.

A 48-year-old Japanese woman started to suffer from numbness in her right hand. A month later, she developed occasional jerky movement of the lower limbs. Over the following weeks, her daily activity was progressively affected by painful spasms and stiffness in the four limbs. She eventually became unable to stand and was brought to our hospital. She had a history of lumbar spinal stenosis. She was confused and agitated on arrival, and her speech was delusional. However, her speech exhibited no components of dysarthria or aphasia, with normal object naming and fluent output without paraphasia. She exhibited spontaneous and intermittent

myoclonic jerks in the four limbs, easily provoked by stimulations, such as sounds and touches (Supplementary Material 1). Mild stiffness was observed equally in the four limbs and truncal muscles. Tendon reflexes were normal in the upper limbs, but patellar and Achilles tendon reflexes were diminished. Babinski's sign was bilaterally positive. She had dysesthesia in the distal extremities, hyperhidrosis, urinary retention, and constipation. Serum anti-amphiphysin antibodies were strongly positive, and other onconeural antibodies (GAD65, CV2, Ma1, PNMA2 [Ma2/Ta], Hu, Ri, Yo, recoverin, SOX1, titin, zic4, and Tr [DNER]) were negative by commercial immunoblot assays (PNS blot by Ravo Diagnostika, Freiburg, Germany, and EUROLINE PNS 12 Ag by Euroimmun, Lübeck, Germany). By immunohistochemistry on rat cerebellum using the avidin-biotin technique, anti-amphiphysin antibodies were confirmed, and other antibodies against cell surface antigens (NMDAR, AMPAR, GABA<sub>A</sub>R, GABA<sub>B</sub>R, mGluR1, mGluR2, mGluR5, DPPX, and IgLON5) were negative. Anti-GlyR antibodies were negative by cell-based assay, and anti-GAD65 antibodies were also negative with ELISA. Cerebrospinal fluid showed mild pleocytosis (30/ $\mu$ L). Magnetic resonance imaging (MRI) of the brain and spinal cord showed no abnormalities. There was no evidence of malignancy in a positron emission tomography/computed tomography scan of the whole body or breast ultrasound with biopsy on a suspicious hypoechoic area. We diagnosed PERM based on the clinical symptoms and considered that her condition was associated with anti-amphiphysin antibodies. Two courses of intravenous methylprednisolone (1,000 mg/day for three days) dramatically improved her mental state, limb stiffness, involuntary movements, and autonomic dysfunctions, but mild dysesthesia in the extremities persisted. An oral steroid (prednisolone 60 mg/day) was initiated after the second course and then carefully tapered. She was discharged from hospital on the 61st day. One year later, the dysesthesia worsened, and paroxysmal myoclonic jerks relapsed. MRI of the brain and spinal cord and nerve conduction studies showed no significant abnormalities (Supplementary material 2). Further assessment with SEPs revealed delayed conduction in the brain (Figure 1). Again,

**Corresponding author:** Dr. Keiichi Hokkoku, Department of Neurology, Teikyo University School of Medicine, Kaga 2-11-1, Itabashi-ku, Tokyo 1738605, Japan. Email: [k1-hokkoku@hotmail.co.jp](mailto:k1-hokkoku@hotmail.co.jp)

**Cite this article:** Fujii Y, Murata Y, Hokkoku K, Chiba T, Hamada Y, Uchibori A, Chiba A, Kobayashi S, and Sonoo M. (2023) Anti-amphiphysin-positive Progressive Encephalomyelitis with Rigidity and Myoclonus. *The Canadian Journal of Neurological Sciences* 50: 781–783, <https://doi.org/10.1017/cjn.2022.293>



**Figure 1:** (A) Electrode placement and evoked potentials of SEPs with median nerve stimulation. Median nerve somatosensory-evoked potentials are evaluated by the standard references established by our previous study.<sup>8</sup> N9 potential, N11 potential, P13/14 complex, and N20 potential are generated at the Erb's point, spinal entry, caudalmost part of the internal lemniscus, and the cerebral cortex, respectively. Electrode placements are as follows: the Erb's point ipsilateral to the stimulation (EPI), the spinous process of the sixth cervical vertebra (C6S), Fz, the ipsilateral ear (Ai), contralateral centroparietal electrode (CPc), and a non-cephalic reference (NC) over the contralateral shoulder. (B) Right median nerve SEP recordings of the present patient. The latency of N20 onset is significantly delayed (+5.2 SD), suggesting disturbed sensory conduction: 17.4 ms, +5.2 SD (upper limit: 16.2 ms). The prolonged interval between P13/14 complex onset and N20 onset (central conduction time) represents a conduction delay in the caudalmost internal lemniscus to the cerebral cortex compatible with a brainstem lesion: 5.2 ms, +5.6 SD (upper limit: 4.5 ms). Giant SEPs, commonly seen in cortical myoclonus, are not present in CPc-Fz and CPc-Ai leads. The abnormalities are judged regarding the institutional normative values, which are body height adjusted, and expressed by the unit of standard deviations (SD).<sup>8</sup>

**Table 1:** Four cases of anti-amphiphysin-positive PERM have been reported. These cases share core features of PERM, such as muscle stiffness and painful myoclonus, and show neurological symptoms suggesting brainstem and spinal cord involvements, which are also documented in PERM with anti-GlyR or anti-GAD antibodies

	Dropcho	Ishii et al.	Cantinaux et al.	Present case
Age, sex	67, M	37, F	72, F	48, F
Muscle stiffness	(+)	(+)	(+)	(+)
Painful myoclonus and spasms	(+)	(+)	(+)	(+)
Neuropsychological symptoms	Confusion	(-)	Altered consciousness	Delirium
Pyramidal sign	(-)	(-)	(+)	(+)
Sensory symptoms	Numbness in both feet	(-)	(-)	Dysesthesia in the distal four limbs
Autonomic symptoms	(-)	Hyperhidrosis	(-)	Hyperhidrosis, constipation
Other findings	Respiratory failure, weakness, and hyperreflexia in the left arm, sensorimotor neuropathy	Left abducens nerve palsy	(-)	Hyperekplexia, mild limb weakness
Tumor	Small cell lung carcinoma	Breast cancer	Clear cell renal cell carcinoma	Not detected
Treatment / outcome	IVIg, oral PSL chemotherapy / improved but relapsed	mPSL pulse, oral PSL, PE / improved	IVIg, oral PSL / improved but no complete remission	mPSL pulse, oral PSL / improved but relapsed, no complete remission
Method for detection of anti-amphiphysin antibodies	ICC, WB	WB	ND	IHC, immunodot

ICC: immunocytochemistry, IHC: immunohistochemistry, IVIG: intravenous immunoglobulin, mPSL: methylprednisolone, ND: not described, PE: plasma exchange, PSL: prednisolone, WB: Western blot.

we treated her with high-dose methylprednisolone, which immediately partially improved the symptoms. The second work-up for malignancy still showed negative results.

Four cases of anti-amphiphysin-positive PERM have thus far been reported, including the present case (Table 1).<sup>3-5</sup> The cases showed core clinical signs of PERM and varying degrees of brainstem and spinal cord symptoms. While immunotherapy was effective in all cases, relapse occurred in two of four. These findings suggest that the clinical features of anti-amphiphysin-positive PERM are not distinct from PERM with anti-GlyR or anti-GAD antibodies.<sup>1</sup> However, the type of auto-antibodies appears to be important in its association with malignancy. In all reported anti-amphiphysin-positive PERM cases except our case, cancer developed within two years from the onset.<sup>3-5</sup> SPSD associated with anti-amphiphysin is also at high risk (up to 90%) for malignancy, mostly breast cancer and small cell lung cancer, in contrast to SPSD with other antibodies (<20%).<sup>1,2</sup> Hence, although our patient has not developed malignancy after a one-year follow-up, a careful follow-up should still be needed considering the association with anti-amphiphysin antibodies.

Two commercial immunoblot assays with band intensity stratification (Ravo Diagnostika and EUROLINE) are available for detecting anti-amphiphysin antibodies. While these immunoblot assays are quick and easy to perform, their specificity has been questioned. Dechelotte et al. found that only one out of 10 cases with anti-amphiphysin positive results using commercial immunoblot assays was confirmed positive by indirect immunofluorescence on rat brain slices or Western blot, suggesting a high number of false positives when commercial immunoblot assays are used as standalone tests.<sup>6</sup> In our case, the two commercial immunoblots were both strongly positive, and the results were confirmed by an immunohistochemical method. Although further studies are needed, band intensity stratification of immunoblot may be useful.

Patients with PERM sometimes present with sensory disturbances.<sup>1</sup> Several autopsy studies of PERM have documented sensory system involvements: demyelination in the internal lemniscus of the brainstem and the dorsal column of the spinal cord.<sup>7</sup> We demonstrated delayed conduction in the medial lemniscus at the brainstem by SEPs for the first time in PERM. SEPs have been applied to various neurological diseases.<sup>8</sup> Although prolonged central conduction is not a disease-specific finding,

SEPs are potentially useful in identifying CNS lesions in PERM, particularly in the absence of neuroimaging findings.

**Supplementary Material.** To view supplementary material for this article, please visit <https://doi.org/10.1017/cjn.2022.293>.

**Acknowledgements.** The authors would like to thank Dr Takahiro Iizuka and Dr Hideto Nakajima for their advice on antibody serum tests.

**Disclosures.** The authors report no conflicts of interest pertaining to the content of this article. This research did not receive any specific grant from funding agencies in the public, commercial, or not-for-profit sectors.

**Statement of Authorship.** YF, TC, and SK were engaged in treating the patient. YM, KH, and SK were involved in the manuscript's conceptualization, literature review, and writing. YH and MS performed electrophysiological assessments. AU and CA performed serological assessments.

**Statement of Informed Consent.** Informed consent was obtained from the patient for this case report.

## References

- Carvajal-González A, Leite MI, Waters P, et al. Glycine receptor antibodies in PERM and related syndromes: characteristics, clinical features and outcomes. *Brain*. 2014;137:2178–92. DOI [10.1093/brain/awu142](https://doi.org/10.1093/brain/awu142).
- Murinson BB, Guarnaccia JB. Stiff-person syndrome with amphiphysin antibodies: distinctive features of a rare disease. *Neurology*. 2008;71:1955–8. DOI [10.1212/WNL.0b013e3181bd6a72](https://doi.org/10.1212/WNL.0b013e3181bd6a72).
- Dropcho E. Anointimphysin antibodies with small-cell lung carcinoma and paraneoplastic encephalomyelitis. *Ann Neurol*. 1996;39:659–67.
- Ishii A, Hayashi A, Ohkoshi N, Matsuno S, Shoji S. Progressive encephalomyelitis with rigidity associated with anti-amphiphysin antibodies. *J Neurol Neurosurg Psychiatry*. 2004;75:661–2.
- Cantiniaux S, Azulay JP, Boucraut J, Pouget J, Attarian S. Le syndrome de l'homme raide: formes cliniques, traitement et profil évolutif. *Rev Neurol (Paris)*. 2006;162:832–9. DOI [10.1016/s0035-3787\(06\)75086-x](https://doi.org/10.1016/s0035-3787(06)75086-x).
- Déchelotte B, Muñoz-Castrillo S, Joubert B, et al. Diagnostic yield of commercial immunodots to diagnose paraneoplastic neurologic syndromes. *Neurol Neuroimmunol Neuroinflamm*. 2020;7:e701. DOI [10.1212/NXI.0000000000000701](https://doi.org/10.1212/NXI.0000000000000701).
- Howell DA, Lees AJ, Toghil PJ. Spinal internuncial neurones in progressive encephalomyelitis with rigidity. *J Neurol Neurosurg Psychiatry*. 1979;42:773–85. DOI [10.1136/jnnp.42.9.773](https://doi.org/10.1136/jnnp.42.9.773).
- Sonoo M, Kobayashi M, Genba-shimizu K, Mannen T, Shimizu T. Detailed analysis of the latencies of median nerve somatosensory evoked potential components, 1: selection of the best standard parameters and the establishment of normal values. *Electroencephalogr Clin Neurophysiol*. 1996;100:319–31.