

Amygdala volume in schizophrenia: post-mortem study and review of magnetic resonance imaging findings

STEVEN A. CHANCE, MARGARET M. ESIRI and TIMOTHY J. CROW

Background Claims that schizophrenia is a disease of the limbic system have been strengthened by meta-analyses of magnetic resonance imaging (MRI) studies finding reduced hippocampus and amygdala volumes. Some post-mortem studies do not find these abnormalities.

Aims To assess the volume of the amygdala in a series of brains post-mortem.

Method Amygdala volume was estimated using point-counting in both hemispheres of the brains of 10 male and 8 female patients with schizophrenia, and a comparison group of 9 males and 9 females.

Results No significant reduction of amygdala volume was found.

Conclusions Significant volume reduction of the amygdala is not a consistent feature of schizophrenia; findings from early MRI studies using coarse delineation methods may introduce bias to subsequent meta-analyses.

Declaration of interest This work was supported by the Medical Research Council and the SANE Trust.

The limbic system has been suggested to be a possible focus of pathological change in schizophrenia (Torrey & Peterson, 1974; Bogerts, 1997). It is plausible that symptoms of schizophrenia such as inappropriate or flattened affect might relate to a change in the structure of the amygdala and its connections (Benes & Berretta, 2000). Stimulating or damaging the amygdala can induce a range of symptoms (Torrey & Peterson, 1974), and schizophrenia-like psychoses have been associated with epileptic foci in the temporal lobe (Slater & Beard, 1963). There is disagreement between magnetic resonance imaging (MRI) studies and a smaller number of studies in which amygdala volume has been assessed in post-mortem material. A consensus from MRI studies suggests a 5–10% reduction of the amygdala in schizophrenia. However, post-mortem planimetry studies are equivocal. This study aimed to clarify whether the MRI interpretation of amygdala reduction in schizophrenia is apparent in post-mortem tissue, using unbiased methods of estimating volume.

METHOD

Sample

Formalin-fixed brain tissue was used post-mortem from subjects who were selected on the basis of the assessment of clinical notes by a consultant psychiatrist (T.J.C. or Dr S. J. Cooper, Belfast). The DSM-IV (American Psychiatric Association, 1994) criteria for schizophrenia and schizoaffective disorder were used in the selection of cases of schizophrenia. Comparison group brains were collected prospectively from individuals who had died without a history of neuropsychiatric disorder, and whose next of kin had given consent for their tissues to be used in medical research. Pathological assessment of tissue samples was carried out by a consultant neuropathologist (M.M.E. or Dr B. McDonald,

Oxford), and cases with significant neurological disorders, such as Alzheimer's disease, were excluded using the criteria of the Consortium to Establish a Registry for Alzheimer's Disease (Mirra *et al*, 1991).

Subsequent to sectioning and staining, the series consisted of 36 cases, comprising 10 men and 8 women with schizophrenia, and a comparison group of 9 men and 9 women.

The degree of neuroleptic medication received during life was assessed from case notes, and categorised as 'little', 'average' or 'much'. This was based on a clinician's (T.J.C. or S.A.C.) judgement on the basis of the available clinical records, the variability of information available precluding a more quantitative estimation. A three-section categorisation of causes of death indicates that 14 subjects died of cardiac causes, 9 of respiratory causes and 12 of 'other' causes. Of these, 22 deaths were prolonged and 13 were sudden. One subject died of uncertain causes. Other demographic details and potentially confounding variables, including age of symptom onset, duration of illness, age at death, post-mortem interval and fixation time, were noted for statistical analysis (Table 1).

Tissue preparation

Following removal of the leptomeninges and brain-stem, and bisection of the brain, the temporal lobes were removed from the rest of the hemispheres at the posterior end of the sylvian fissure. The temporal lobe was cut into slices 5 mm thick along its antero-posterior axis. Embedding the slices in paraffin resulted in blocks of tissue approximately 3 mm thick owing to shrinkage. Blocks containing the amygdala were exhaustively sectioned from a position posterior to, and random with respect to, the posterior border of the amygdala. For a structure with a regular shape such as the amygdala, a sample of approximately 10 sections should be adequate for the estimation of volume (Gundersen & Jensen, 1987). Selecting sections 25 μ m thick with an interslice distance of 650 μ m provided about 8–12 sections per amygdala. The sections were counterstained with Luxol fast blue, a myelin stain useful for picking out fibre tracts, and cresyl violet, which stains Nissl's substance in cell bodies (Fig. 1) (reagents obtained from Raymond A. Lamb Ltd, Eastbourne, UK).

Measurement

A Cavalieri estimate of volume for each amygdala was obtained by stereological

Table 1 Demographic variables and details of the brain collection for the amygdala study

Variable	Men		Women	
	Comparison group (n=9)	Schizophrenia group (n=10)	Comparison group (n=9)	Schizophrenia group (n=8)
Age at onset (years)				
Mean	NA	28.5	NA	34.4 ¹
s.d. (range)		7.7 (21–42)		11.3 (17–47)
Duration of illness (years)				
Mean	NA	26.5	NA	40.3 ¹
s.d. (range)		14.3 (1–44)		13 (26–64)
Age at death (years)				
Mean	68.9	55.0	70.8	75.8
s.d. (range)	11.0 (40–80)	13.2 (29–69)	14.3 (48–90)	13.8 (48–91)
Post-mortem interval (hours)				
Mean	42.9	42.0 ¹	46.7	39.8
s.d. (range)	31.8 (10–98)	34.0 (6–113)	26.4 (19–104)	39.2 (10–128)
Fixation period (months)				
Mean	25.3	46.3	28.0	67.6
s.d. (range)	15.9 (1–53)	22.4 (20–91)	17.7 (3–61)	13.6 (44–85)
Brain volume (cm ³)				
Mean	1144	1191	982	893
s.d. (range)	115 (995–1290)	104 (994–1378)	144 (846–1296)	144 (641–1087)

1. No accurate information for one case.
NA, not applicable.

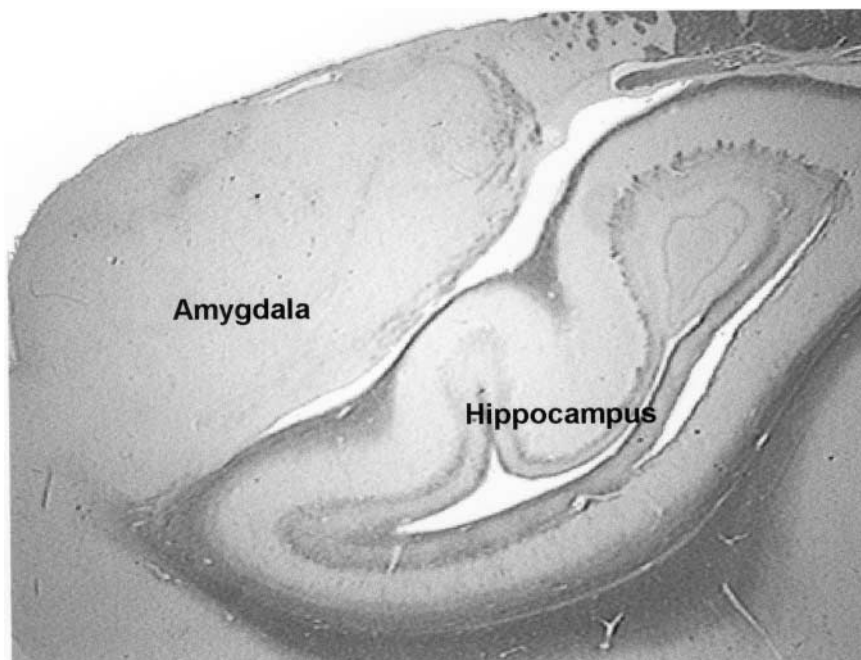


Fig. 1 Cross-section of the amygdala and hippocampus. Staining with Luxol fast blue and cresyl violet results in dark staining of areas containing predominantly white matter fibre tracts and lighter staining of nuclei-containing cell bodies. The amygdala lies superior to and overlaps the hippocampus.

point-counting within the bounds of the amygdala on all sections in which it appeared. A 4-mm² point density grid printed on acetate was laid over each

cross-section and viewed under a dissecting microscope $\times 7$ magnification (Fig. 2). Each point represented a volume of 10.8 mm³ (4 mm \times 4 mm \times 0.675 mm). Three

placements of the grid, each time in a random orientation, were used to obtain a mean count for each section. The total count was multiplied by the volume represented by each point for an estimate of total volume. The most anterior section containing the hippocampus and the most anterior section containing the temporal horn were also noted. This enabled a calculation to be made of the percentage of amygdala volume overlapping with each of those structures along the axis of the temporal lobe.

All measures were performed by the same researcher (S.A.C.) who was blind to the diagnosis and gender of the cases. Left, right and mean amygdala volumes were obtained.

Pilot study

A pilot study was used to determine the grid size of points and the number of counts per section required for a satisfactory estimate of amygdala volume. Point counts were made for each of three different grid sizes, varying the number of recounts. Trial grid sizes had interpoint distances of 2 mm, 3 mm and 4 mm, respectively. The 4-mm² grid yielded a total point count of up to about 75 points per amygdala. Three counts

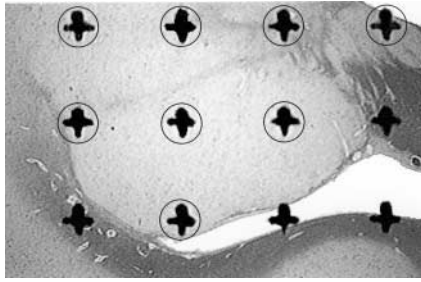


Fig. 2 The black crosses of the acetate counting grid appear large when superimposed over a section under a $\times 7$ magnification. Points falling within the structure of interest such as the amygdala grey matter (circled) are counted.

of this grid gave a coefficient of error of 0.04, which was deemed satisfactory.

Reliability

The volume was estimated twice for 10 randomly selected amygdalas to test intra-rater reliability. This provided an intraclass correlation coefficient of 0.94, suggesting that the reliability of this measure was satisfactory.

Statistics

Statistical analyses were carried out using the software *Statistical Package for the Social Sciences*, version 9.0 (SPSS, 1998). Unfortunately, for some amygdalas, insufficient tissue was available to provide a systematically random sample of total volume. This was due to an idiosyncratic tissue response to embedding procedures in some tissue blocks which resulted in

unsatisfactory sections in a few amygdalas and prohibited their inclusion. Consequently, three cases provided volumetric data only for the right side and four cases only for the left side. Since a repeated-measures analysis of variance (ANOVA) would exclude all seven cases with one side missing, an alternative univariate ANOVA was used to test the mean of both sides for each case, replaced by the value for just one side in cases that did not have both. This approach was used to test for the between-subject effects of diagnosis and gender. A repeated-measures ANOVA was still applied to test the within-subject effects of side using those cases that had data for both sides. In addition, an asymmetry statistic was calculated for these cases: $(R-L)/(R+L) \times 100$, where R and L are the values for the right and left sides respectively.

The influence of potentially confounding variables – age at death, post-mortem interval and fixation time – for all cases were examined as variables in separate ANOVAs of groups selected by gender and/or diagnosis. Lifetime medication of the patients with schizophrenia was examined as a factor in ANOVA of the measured variables. Clinical information was felt to be unsatisfactory for correlating symptoms or sub-syndromes with data. All variables, including covariates, fitted with a normal distribution as tested by a Kolmogorov–Smirnov goodness-of-fit test (Zar, 1984) for each gender and diagnosis group. Homogeneity of variance of the measured variables between groups was accepted after testing with a Box's M test (Glantz & Slinker, 2000) before each ANOVA.

RESULTS

The measurements obtained are summarised in Table 2 and Fig. 3.

Accuracy

The observed coefficients of error for the estimates of volume were less than or equal to 0.1 for both left and right amygdalas in each diagnosis \times gender subgroup, indicating that their means offer a satisfactory estimate of the true population means.

Results of analysis of variance

A univariate ANOVA of mean amygdala volume found no significant difference between schizophrenia cases and controls ($F=0.5$, d.f. 1,30, $P=0.47$), no difference between genders ($F=0.1$, d.f. 1,30, $P=0.73$) and no interaction between diagnosis and gender. Analysis of covariance (ANCOVA) included fixation time, which was not a significant covariate, and age, which showed a significant negative relationship with volume ($F=5.4$, d.f. 1,30, $P=0.03$). Inclusion of brain volume in a secondary ANCOVA revealed that it was a significant covariate ($F=10.8$, d.f. 1,29, $P<0.01$) which had a positive relationship with amygdala volume, and resulted in a reduced P value in the effect of age ($F=0.9$, d.f. 1,29, $P=0.37$), suggesting a relationship with age described below. When controlling for brain volume all other results remained, including the lack of difference between patients and controls, and between the genders.

A repeated-measures ANOVA revealed no significant volume asymmetry of the

Table 2 Amygdala measurements in the post-mortem study group. Values are actual measured values uncorrected for tissue shrinkage

Variable	Men		Women	
	Comparison group mean (s.d.)	Schizophrenia group mean (s.d.)	Comparison group mean (s.d.)	Schizophrenia group mean (s.d.)
Amygdala volume (mm ³)				
Left	686.5 (165.2) $n=8$	714.8 (91.9) $n=9$	628.5 (219.3) $n=9$	586.6 (138.4) $n=7$
Right	607.8 (82.9) $n=8$	721.2 (114.0) $n=9$	596.0 (186.5) $n=9$	545.1 (161.1) $n=6$
Mean amygdala volume (mm ³)	643.4 (107.5) $n=9$	720.9 (92.7) $n=10$	612.3 (182.3) $n=9$	604.9 (155.0) $n=8$
Amygdala symmetry ($(R-L)/(R+L) \times 100$)	-4.5 (11.4) $n=7$	-1.1 (6.5) $n=8$	-2.2 (14.5) $n=9$	-3.3 (7.8) $n=5$
Percentage of mean amygdala volume overlapping with hippocampus (%)	56.9 (12.5) $n=9$	60.7 (17.6) $n=10$	56.0 (18.7) $n=9$	65.6 (16.5) $n=8$
Percentage of mean amygdala volume overlapping with temporal horn (%)	79.6 (11.2) $n=9$	83.8 (13.4) $n=10$	71.7 (12.9) $n=9$	84.2 (12.0) $n=8$

R, L are values for right and left sides, respectively.

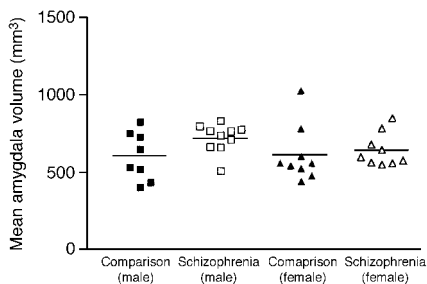


Fig. 3 No difference in amygdala volume was found between the study groups.

amygdala and no difference in amygdala symmetry between groups. An ANCOVA found that age and fixation time were not significant covariates (although there was an interaction between fixation time and side: left amygdala smaller with longer fixation time, $F=8.8$, d.f. 1,22, $P<0.01$). Brain volume also had no effect on amygdala asymmetry.

The percentage of mean amygdala volume overlapping with the hippocampus, along the temporal lobe axis, was 56% (s.d. 15) in control brains and 63% (s.d. 17) in schizophrenia. The volume overlap with the temporal horn of the ventricles was 76% (s.d. 12) in controls and 84% (s.d. 12) in schizophrenia. No significant correlations were found between amygdala volumes and temporal horn volumes.

Artefacts and covariates

As shown in Table 1, the women ($F=7.0$, d.f. 1,32, $P=0.01$), particularly those with schizophrenia ($F=3.7$, d.f. 1,32, $P=0.06$), were older at death than the men. Consequently, age at death was included as a covariate in all tests of the measured variables. As expected, the total brain volumes were larger in the men than in the women in this series. Amygdala volume was positively correlated with brain volume, which was included as a covariate in secondary ANOVAs of the measured variables to observe the effect of controlling for brain size that might mask changes in the amygdala.

Post-mortem factors

Post-mortem interval did not differ between groups and therefore was not included as a covariate. Fixation time was similarly examined and differed between groups selected by diagnosis ($F=25.4$, d.f. 1,32, $P<0.01$) and gender ($F=4.0$, d.f. 1,32, $P=$

0.06). Consequently, although the distortion due to fixation stabilises after approximately 3 weeks (Quester & Schroder, 1997) and all of the brains studied should therefore have reached a stable state prior to examination, fixation time was included as a covariate in the analysis of amygdala volume.

Clinical factors

Within the group of patients with schizophrenia, age of illness onset and neuroleptic medication were found to have no influence on the mean amygdala volume or the asymmetry of amygdala volumes. The mean level of medication within the schizophrenia group corresponded to a rating of 'average' or 'much'.

DISCUSSION

In a review of MRI studies McCarley *et al* (1999) reported that 77% of 30 studies showed a reduction in volume in at least one of the hippocampus, parahippocampal gyrus or amygdala. By meta-analysis Lawrie & Abukmeil (1998) found a median volume reduction of approximately 6% over ten studies measuring the combined amygdala and hippocampus, and about 10% from six studies measuring the amygdala separately. A meta-analysis by Nelson *et al* (1998) found a reduction of about 8% from MRI studies measuring the amygdala and hippocampus and about 5% from five studies measuring the amygdala separately. They suggested that inclusion of the amygdala significantly increased the size of the reduction. The most recent meta-analysis, by Wright *et al* (2000), found that the amygdala was 94% of its normal size relative to cerebral volume differences in schizophrenia.

In contrast, the post-mortem study by Heckers *et al* (1990) found no difference in the volume of the amygdala in 20 patients (see Table 4). Similarly, Pakkenberg's post-mortem planimetry study (Pakkenberg, 1990) found no difference in volume of the basolateral nucleus, which constitutes a large percentage of the amygdala (the cortico-basolateral nuclei constitute 75% according to Eccles, 1989). These differ from the original finding of reduced amygdala volume in post-mortem material (Bogerts *et al*, 1985).

Contrary to what might be expected if schizophrenia is a disorder of the limbic system, no volumetric reduction in the amygdala was found in this set of

brains. If sustained, this conclusion suggests that the structural changes that have been established in post-mortem studies (Brown *et al*, 1986; Altshuler *et al*, 1990), including those of the parahippocampal gyrus in brains from this collection (McDonald *et al*, 2000), do not extend equally to other parts of the limbic system such as the amygdala and, as previously indicated, may not substantively involve the fornix (Chance *et al*, 1999).

MRI limitations

Although consistent with other post-mortem findings (Heckers *et al*, 1990; Pakkenberg, 1990) the absence of a reduction of amygdala size apparently runs counter to the weight of published neuroimaging research. Recent MRI reviews and meta-analyses include studies from the early 1990s, since which time imaging technology has improved. The most obvious limitations of older studies is low scan resolution. Several studies provide only one or two slices through the amygdala (Table 3). Such limited sampling exacerbates the problem of delineating the amygdala, separating it from the hippocampus and the temporal horn of the ventricle. Several authors concluded that the delineation of the amygdala was unreliable and excluded it from their analysis (Flaum *et al*, 1995), or excluded the region of overlap with the hippocampus (Breier *et al*, 1992). Many studies (e.g. DeLisi *et al*, 1991) simply included it with the hippocampus. Some studies (e.g. Bogerts *et al*, 1990, 1993; Seidman *et al*, 1999) that divided a segmentation including both amygdala and hippocampus into a posterior portion and an anterior portion (deemed to represent the amygdala) found a volume reduction only when the posterior portion was included.

Table 3 surveys the MRI studies from the period 1988–2000 that have measured the volume of the amygdala in schizophrenia. Studies that provided only one or two slices through the amygdala have been noted. The outcome of the study is reported for the measurement deemed to be closest to an amygdala volume. In some cases this is the anterior part of a hippocampus–amygdala complex. In studies in which the amygdala was defined as a separate entity, the landmark used for the posterior boundary is important. An interslice spacing has been reported for studies that measured more than one slice through the

Table 3 Studies of the amygdala identified by Nelson *et al* (1998), Lawrie & Abukmeil (1998) and a Medline search of articles since 1998. The later studies have better scan resolution and assess more than two slices through the amygdala. No slice thickness is given for studies that measure only one slice. For studies with more than two slices through the amygdala, the boundary used to divide the amygdala portion of a segmentation from the hippocampal portion is given. If a subdivision was measured, the findings refer only to the anterior, amygdaloid portion

Study	Number of slices	Interslice spacing (mm)		Arbitrary boundary	Significant volume reduction?
		> 3 mm	≤ 3 mm		
Kelsoe <i>et al</i> (1988)	2	10			No
Suddath <i>et al</i> (1989)	1				Yes
Barta <i>et al</i> (1990)	2		3		Yes
Bogerts <i>et al</i> (1990)	>2	3.1		Mamillary bodies	No
Dauphinais <i>et al</i> (1990)	2	10			Yes
Suddath <i>et al</i> (1990)	1				No
Blackwood <i>et al</i> (1991)	>2	8		Undefined	No
DeLisi <i>et al</i> (1991)	>2	7		Combined measure	No
Breier <i>et al</i> (1992)	>2		3	Overlap excluded	Yes
Hoff <i>et al</i> (1992)	>2	7		Pons	No
Shenton <i>et al</i> (1992)	>2		1.5	Mamillary bodies	Yes
Swayze <i>et al</i> (1992)	2	10			No
Bogerts <i>et al</i> (1993)	>2	3.1		Mamillary bodies	No
Marsh <i>et al</i> (1994)	1				Yes
Rossi <i>et al</i> (1994)	2	6			Yes
Becker <i>et al</i> (1996)	>2	4		Mamillary bodies	No
Pearlson <i>et al</i> (1997)	2		3		Yes
Hirayasu <i>et al</i> (1998)	>2		1.5	Mamillary bodies	No
Giedd <i>et al</i> (1999)	>2		2	Tracing	No
Sanderson <i>et al</i> (1999)	>2		1.9	Combined measure	Yes
Seidman <i>et al</i> (1999)	>2		3	10/24 of AC-PC distance (automated)	No
Altshuler <i>et al</i> (2000)	>2		1.4	Tracing	No
Niemann <i>et al</i> (2000)	>2		2.2	Tracing	No
Staal <i>et al</i> (2000)	>2		1.6	Optic tract	No

AC, anterior commissure; PC, posterior commissure.

Table 4 Post-mortem studies of the amygdala in schizophrenia

Study	Structure	Volume (cm ³)		Significant difference? ¹
		Control mean (s.d.)	Schizophrenia mean (s.d.)	
Bogerts <i>et al</i> (1985)	Amygdala	1.62 (0.78) n=8	1.27 (0.78) n=9	P=0.048
Heckers <i>et al</i> (1990)	Amygdala	1.20 (0.14) n=20	1.29 (0.22) n=20	NS
Pakkenberg (1990)	Basolateral amygdala	0.19 ² n=5	0.19 ² n=5	NS

1. NS denotes 'not significant' where a P value was not given in the paper.
 2. Approximate values derived from scatter plot (also appear to be uncorrected for tissue shrinkage).

amygdala. The interslice spacing is composed of both slice thickness and, when present, interslice gap, and is split into categories of less than or greater than

3 mm, since a distance greater than 3 mm has been reported to reduce significantly the accuracy of MRI measurements (Luft *et al*, 1996).

Limitations of meta-analysis

Although apparently consistent evidence of amygdala volume reduction emerges from compilations of studies, such meta-analyses conceal a potential source of bias. In most studies a landmark external to the temporal lobe was used either to mark the division into anterior and posterior portions, or to begin segmentation of the amygdala. Few MRI studies that provide more than two slices through the amygdala delineate it without the use of an external landmark (Fig. 4). The landmarks include the mamillary bodies (Bogerts *et al*, 1990, 1993; Shenton *et al*, 1992; Rossi *et al*, 1994; Becker *et al*, 1996; Hirayasu *et al*, 1998), the optic tract (Staal *et al*, 2000), the pons (Hoff *et al*, 1992), and the anterior and posterior commissures (Seidman *et al*,

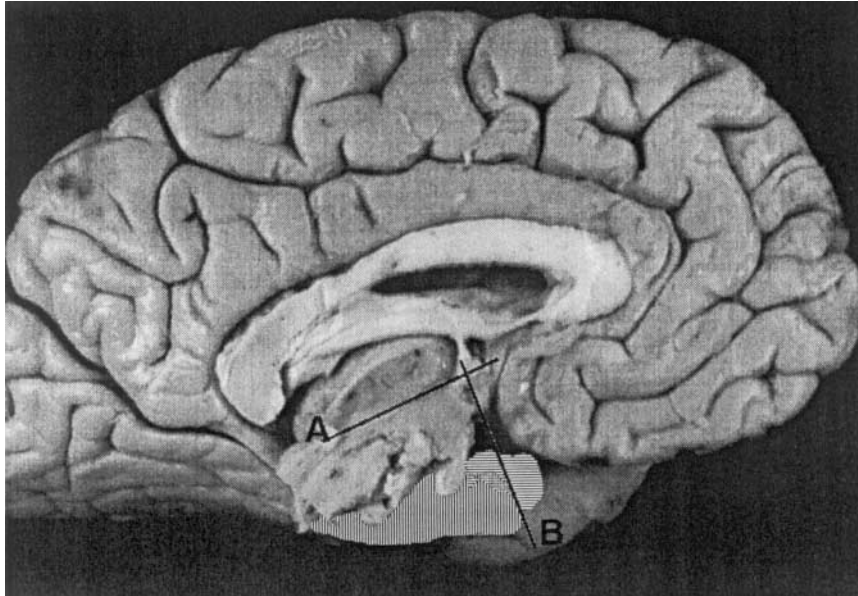


Fig. 4 The mamillary body can be used to delineate the boundary between hippocampus and amygdala. The approximate positions of the amygdala (horizontal stripes) and hippocampus (vertical stripes) are shown. The line B runs through the mamillary body orthogonal to the line (A) between the anterior and posterior commissures.

1999). However, the temporal lobes have been reported to be preferentially shortened in schizophrenia (Bartzokis *et al*, 1996). For example, in the present series of brains, measurement from the pole to the posterior sylvian fissure (Highley *et al*, 1998), and to the ventricular trigone (further details available from the author upon request), have found shorter temporal lobes despite controlling for brain size. In this situation, landmarks that lie outside the temporal lobe in cases of schizophrenia will be further forwards relative to structures within the temporal lobe. Consequently, the use of external landmarks in MRI studies could constitute one systematic source of error, yielding smaller estimates of amygdala volume such as are identified in the meta-analyses.

Furthermore, this study found that at least half of the volume of the amygdala overlaps the hippocampus along the axis of the temporal lobe. This emphasises the necessity of clearly differentiating the two structures to obtain accurate volumes. Although the mean amygdala volume was not changed in this study, the percentage of its volume overlapped by the neighbouring hippocampus and temporal horn was slightly more in the brains from subjects who had schizophrenia. The greater surface of amygdala bordered by the high contrast of an enlarged temporal horn in schizophrenia could lead to a more

conservative segmentation of the amygdala on MRI scans.

Hemisphere and gender

No significant asymmetry of amygdala volume was found in these brains – a finding similar to that of Heckers *et al* (1990). No difference of asymmetry was noted between patients with schizophrenia and comparison subjects. In contrast to the finding of Fukuzako *et al* (1997), who showed that a relatively larger right hippocampus was correlated with later age of illness onset, no correlation between amygdala asymmetry and age of onset was found. This was accompanied by an absence of significant difference between the genders, similar to the findings of Bryant *et al* (1999), although the mean amygdala volume in the women seemed to be a little less than that in the men (see Table 2) – presumably associated with the normal human sexual dimorphism of total brain size.

Interpreting normal volume

The negative findings of this study (particularly in relation to imaging studies) raise the possibility of a type II error (i.e. a failure to identify a difference between groups because of small sample size). A power analysis using the *Statmate* program, version 1.01 (GraphPad Software, San

Diego, USA) indicates that this study had about 15% power to detect a change of 5–7% of amygdala volume, as suggested by MRI meta-analyses. This rises to about 30% power to detect a change of 10% volume, and 80% power to detect a change of 20% ($\text{power} = 1 - p$ (type II error)); the model was a two-samples *t*-test with $\alpha = 0.05$). The observed coefficients of error, which take into account sample size to determine how good an estimate of the true population mean is provided by the sample mean, were all satisfactory, at less than or equal to 0.1.

The absence of a gross volumetric reduction in this study does not discount a cytoarchitectural or neurochemical disturbance. Increased dopamine innervations on the left (Reynolds, 1983) and reduced binding of γ -aminobutyric acid (Simpson *et al*, 1989) in the amygdala in schizophrenia, have been interpreted as a loss of inhibition which might induce positive symptoms (Reynolds, 1995). Such changes may reflect a change in connectivity, for example of the dopaminergic afferent fibres, rather than an alteration in gross volume.

The study was limited by the use of elderly, medicated subjects, and Bogerts *et al* (1991) have suggested that age-related brain atrophy may obscure reductions in limbic structures. In our study the negative association of age with volume could act to reduce any apparent diminution in volume in the subjects with schizophrenia, since the control subjects were on average 5 years older (means: controls 69 years, patients 64 years). However, age was controlled for as a covariate in the analyses of volume. The use of MRI can avoid these complications.

Magnetic resonance imaging is most appropriate for assessment of macroscopic measurements, while post-mortem examination is still the only option at a microscopic scale. Currently, the amygdala stands at the limit of structures that can be satisfactorily determined using MRI. Recent and improving methods of assessment, which make use of visual tracing of the amygdala–hippocampus boundary, using the alveus and local anatomical features rather than other external landmarks, should provide a more reliable source of measurements (Kates *et al*, 1997; Niemann *et al*, 2000; Pruessner *et al*, 2000). Further studies are required to clarify which, if any, components of the limbic system are affected in schizophrenia. The current study supports the conclusion that volume reductions of the amygdala in schizophrenia are not large,

and that small reductions reported in MRI may be due to coarse delineation methods that could introduce bias to subsequent meta-analyses.

ACKNOWLEDGEMENTS

The authors thank Dr B. McDonald, Dr S. J. Cooper, Mrs H. Roberts and Mrs A. Halsey.

REFERENCES

- Altshuler, L. L., Casanova, M. F., Goldberg, T. E., et al (1990)** The hippocampus and parahippocampus in schizophrenia, suicide, and control brains. *Archives of General Psychiatry*, **47**, 1029–1034.
- , **Bartzokis, G., Grieder, T., et al (2000)** An MRI study of temporal lobe structures in men with bipolar disorder or schizophrenia. *Biological Psychiatry*, **48**, 147–162.
- American Psychiatric Association (1994)** *Diagnostic and Statistical Manual of Mental Disorders* (4th edn) (DSM-IV). Washington, DC: APA.
- Barta, P. E., Pearlson, G. D., Powers, R. E., et al (1990)** Auditory hallucinations and smaller superior temporal gyral volume in schizophrenia. *American Journal of Psychiatry*, **147**, 1457–1462.
- Bartzokis, G., Nuechterlein, K. H., Marder, S. R., et al (1996)** Age at illness onset and left temporal lobe length in males with schizophrenia. *Psychiatry Research*, **67**, 189–201.
- Becker, T., Elmer, K., Schneider, F., et al (1996)** Confirmation of reduced temporal limbic structure volume on magnetic resonance imaging in male patients with schizophrenia. *Psychiatry Research*, **67**, 135–143.
- Benes, F. M. & Berretta, S. (2000)** Amygdalo-entorhinal inputs to the hippocampal formation in relation to schizophrenia. *Annals of the New York Academy of Sciences*, **911**, 293–304.
- Blackwood, D. H., Young, A. H., McQueen, J. K., et al (1991)** Magnetic resonance imaging in schizophrenia: altered brain morphology associated with P300 abnormalities and eye tracking dysfunction. *Biological Psychiatry*, **30**, 753–769.
- Bogerts, B. (1997)** The temporolimbic system theory of positive schizophrenic symptoms. *Schizophrenia Bulletin*, **23**, 423–435.
- , **Meertz, E., Schonfeldt Bausch, R., et al (1985)** Basal ganglia and limbic system pathology in schizophrenia. A morphometric study of brain volume and shrinkage. *Archives of General Psychiatry*, **42**, 784–791.
- , **Ashtari, M., Degreaf, G., et al (1990)** Reduced temporal limbic structure volumes on magnetic resonance images in first episode schizophrenia. *Psychiatry Research*, **35**, 1–13.
- , **Falkai, P. & Greve, B. (1991)** Evidence of reduced temporolimbic structure volumes in schizophrenia (letter; comment). *Archives of General Psychiatry*, **48**, 956–958.
- , **Lieberman, J. A., Ashtari, M., et al (1993)** Hippocampus–amygdala volumes and psychopathology in chronic schizophrenia. *Biological Psychiatry*, **33**, 236–246.
- Breier, A., Buchanan, R. W., Elkashef, A., et al (1992)** Brain morphology and schizophrenia. A magnetic resonance imaging study of limbic, prefrontal cortex,

CLINICAL IMPLICATIONS

- The volume of the amygdala is unchanged in schizophrenia.
- Schizophrenia does not affect all components of the limbic system equally.
- Structural change elsewhere in the temporal lobes may introduce bias in magnetic resonance imaging studies.

LIMITATIONS

- Although satisfactory for a post-mortem study, the sample size does not exclude small differences of amygdala volume in schizophrenia.
- There may be alterations in other morphological aspects of the amygdala such as cellular composition.
- Age-related brain changes may obscure size reductions in limbic structures.

STEVEN A. CHANCE, DPhil, MARGARET M. ESIRI, FRCPath, TIMOTHY J. CROW, FRCPsych, University of Oxford, UK

Correspondence: Steven A. Chance, Schizophrenia Research Group, Radcliffe Infirmary, Woodstock Road, Oxford OX2 6HE, UK. Tel: 01865 228424; fax: 01865 228496; e-mail: steven.chance@clneuro.ox.ac.uk

(First received 14 May 2001, final revision 24 September 2001, accepted 27 September 2001)

and caudate structures. *Archives of General Psychiatry*, **49**, 921–926.

Brown, R., Colter, N., Corsellis, J. A., et al (1986) Postmortem evidence of structural brain changes in schizophrenia. Differences in brain weight, temporal horn area, and parahippocampal gyrus compared with affective disorder. *Archives of General Psychiatry*, **43**, 36–42.

Bryant, N. L., Buchanan, R. W., Vladar, K., et al (1999) Gender differences in temporal lobe structures of patients with schizophrenia: a volumetric MRI study. *American Journal of Psychiatry*, **156**, 603–609.

Chance, S. A., Highley, J. R., Esiri, M. M., et al (1999) Fiber content of the fornix in schizophrenia: lack of evidence for a primary limbic encephalopathy. *American Journal of Psychiatry*, **156**, 1720–1724.

Dauphinais, L. D., DeLisi, L. E., Crow, T. J., et al (1990) Reduction in temporal lobe size in siblings with schizophrenia: a magnetic resonance imaging study. *Psychiatry Research*, **35**, 137–147.

DeLisi, L. E., Hoff, A. L., Schwartz, J. E., et al (1991) Brain morphology in first-episode schizophrenic-like psychotic patients: a quantitative magnetic resonance imaging study. *Biological Psychiatry*, **29**, 159–175.

Eccles, J. C. (1989) *Evolution of The Brain: Creation of The Self*, p. 105. London: Routledge.

Flaum, M., Swayze, V. W., O'Leary, D. S., et al (1995) Effects of diagnosis, laterality, and gender on brain morphology in schizophrenia. *American Journal of Psychiatry*, **152**, 704–714.

Fukuzako, H., Yamada, K., Kodama, S., et al (1997) Hippocampal volume asymmetry and age at illness onset

in males with schizophrenia. *European Archives of Psychiatry and Clinical Neurosciences*, **247**, 248–251.

Giedd, J. N., Jeffries, N. O., Blumenthal, J., et al (1999) Childhood-onset schizophrenia: progressive brain changes during adolescence. *Biological Psychiatry*, **46**, 892–898.

Glantz, S. A. & Slinker, B. K. (2000) *Primer of Applied Regression and Analysis of Variance* (2nd edn). New York: McGraw-Hill.

Gundersen, H. J. & Jensen, E. B. (1987) The efficiency of systematic sampling in stereology and its prediction. *Journal of Microscopy*, **147**, 229–263.

Heckers, S., Heinsen, H., Heinsen, Y. C., et al (1990) Limbic structures and lateral ventricle in schizophrenia. A quantitative postmortem study. *Archives of General Psychiatry*, **47**, 1016–1022.

Highley, J. R., Esiri, M. M., McDonald, B., et al (1998) Temporal-lobe length is reduced, and gyral folding is increased in schizophrenia: a post-mortem study. *Schizophrenia Research*, **34**, 1–12.

Hirayasu, Y., Shenton, M. E., Salisbury, D. F., et al (1998) Lower left temporal lobe MRI volumes in patients with first-episode schizophrenia compared with psychotic patients with first-episode affective disorder and normal subjects. *American Journal of Psychiatry*, **155**, 1384–1391.

Hoff, A. L., Riordan, H., O'Donnell, D., et al (1992) Anomalous lateral sulcus asymmetry and cognitive function in first-episode schizophrenia. *Schizophrenia Bulletin*, **18**, 257–272.

Kates, W. R., Abrams, M. T., Kaufmann, W. E., et al (1997) Reliability and validity of MRI measurement of

the amygdala and hippocampus in children with fragile X syndrome. *Psychiatry Research*, **75**, 31–48.

Kelsoe, J. R., Cadet, J. L., Pickar, D., et al (1988)

Quantitative neuroanatomy in schizophrenia. A controlled magnetic resonance imaging study. *Archives of General Psychiatry*, **45**, 533–541.

Lawrie, S. M. & Abukmeil, S. S. (1998)

Brain abnormality in schizophrenia. A systematic and quantitative review of volumetric magnetic resonance imaging studies. *British Journal of Psychiatry*, **172**, 110–120.

Luft, A. R., Skalej, M., Welte, D., et al (1996)

Reliability and exactness of MRI-based volumetry: a phantom study. *Journal of Magnetic Resonance Imaging*, **6**, 700–704.

Marsh, L., Suddath, R., Higgins, N., et al (1994)

Medial temporal lobe structures in schizophrenia: relationship of size to duration of illness. *Schizophrenia Research*, **11**, 225–238.

McCarley, R. W., Wible, C. G., Frumin, M., et al (1999)

MRI anatomy of schizophrenia. *Biological Psychiatry*, **45**, 1099–1119.

McDonald, B., Highley, J. R., Walker, M. A., et al (2000)

Anomalous asymmetry of fusiform and parahippocampal gyrus gray matter in schizophrenia: a postmortem study. *American Journal of Psychiatry*, **157**, 40–47.

Mirra, S. S., Heyman, A., McKeel, D., et al (1991)

The consortium to establish a registry for Alzheimer's disease (CERAD). Part II: Standardization of the neuropathologic assessment of Alzheimer's disease. *Neurology*, **41**, 479–486.

Nelson, M. D., Saykin, A. J., Flashman, L. A., et al (1998)

Hippocampal volume reduction in schizophrenia as assessed by magnetic resonance imaging: a meta-analytic study. *Archives of General Psychiatry*, **55**, 433–440.

Niemann, K., Hammers, A., Coenen, V. A., et al (2000)

Evidence of a smaller left hippocampus and left

temporal horn in both patients with first episode schizophrenia and normal control subjects. *Psychiatry Research: Neuroimaging*, **99**, 93–110.

Pakkenberg, B. (1990)

Pronounced reduction of total neuron number in mediodorsal thalamic nucleus and nucleus accumbens in schizophrenics. *Archives of General Psychiatry*, **47**, 1023–1028.

Pearlson, G. D., Barta, P. E. & Powers, R. E. (1997)

Medial and superior temporal gyral volumes and cerebral asymmetry in schizophrenia versus bipolar disorder. *Biological Psychiatry*, **41**, 1–14.

Pruessner, J. C., Li, L. M., Serles, W., et al (2000)

Volumetry of hippocampus and amygdala with high-resolution MRI and three-dimensional analysis software: minimizing the discrepancies between laboratories. *Cerebral Cortex*, **10**, 433–442.

Quester, R. & Schroder, R. (1997)

The shrinkage of the human brain stem during formalin fixation and embedding in paraffin. *Journal of Neuroscience Methods*, **75**, 81–89.

Reynolds, G. P. (1983)

Increased concentrations and lateral asymmetry of amygdala dopamine in schizophrenia. *Nature*, **305**, 527–529.

— (1995) Neurotransmitter systems in schizophrenia.

International Review of Neurobiology, **38**, 305–309.

Rossi, A., Stratta, P., Mancini, F., et al (1994)

Magnetic resonance imaging findings of amygdala–anterior hippocampus shrinkage in male patients with schizophrenia. *Psychiatry Research*, **52**, 43–53.

Sanderson, T. L., Best, J. J., Doody, G. A., et al (1999)

Neuroanatomy of comorbid schizophrenia and learning disability: a controlled study. *Lancet*, **354**, 1867–1871.

Seidman, L. J., Faraone, S. V., Goldstein, J. M., et al (1999)

Thalamic and amygdala–hippocampal volume reductions in first-degree relatives of patients with schizophrenia: an MRI-based morphometric analysis. *Biological Psychiatry*, **46**, 941–954.

Shenton, M. E., Kikinis, R., Jolesz, F. A., et al (1992)

Abnormalities of the left temporal lobe and thought disorder in schizophrenia. A quantitative magnetic resonance imaging study. *New England Journal of Medicine*, **327**, 604–612.

Simpson, M. D., Slater, P., Deakin, J. F., et al (1989)

Reduced GABA uptake sites in the temporal lobe in schizophrenia. *Neuroscience Letters*, **107**, 211–215.

Slater, E. & Beard, A. W. (1963)

The schizophrenia-like psychoses of epilepsy. I. Psychiatric aspects. *British Journal of Psychiatry*, **109**, 95–150.

SPSS (1998) *SPSS for Windows Base System User's Manual. Release 9.0.* Chicago, IL: SPSS Inc.

Staal, W. G., Hulshoff Pol, H. E., Schnack, H. G., et al (2000)

Structural brain abnormalities in patients with schizophrenia and their healthy siblings. *American Journal of Psychiatry*, **157**, 416–421.

Suddath, R. L., Casanova, M. F., Goldberg, T. E., et al (1989)

Temporal lobe pathology in schizophrenia: a quantitative magnetic resonance imaging study. *American Journal of Psychiatry*, **146**, 464–472.

—, Christison, G. W., Torrey, E. F., et al (1990)

Anatomical abnormalities in the brains of monozygotic twins discordant for schizophrenia. *New England Journal of Medicine*, **322**, 789–794.

Swayze, V. W., Andreason, N. C., Alliger, R. J., et al (1992)

Subcortical and temporal structures in affective disorder and schizophrenia: a magnetic resonance imaging study. *Biological Psychiatry*, **31**, 221–240.

Torrey, E. & Peterson, M. (1974)

Schizophrenia and the limbic system. *Lancet*, *ii*, 942–946.

Wright, I. C., Rabe Hesketh, S., Woodruff, P. W., et al (2000)

Meta-analysis of regional brain volumes in schizophrenia. *American Journal of Psychiatry*, **157**, 16–25.

Zar, J. H. (1984) *Biostatistical Analysis* (2nd edn).

Englewood Cliffs, NJ: Prentice-Hall.