


Emma Richards , Jameel Muzaffar, Raghu Kumar, Peter Monksfield and Richard Irving

ENT Department, Queen Elizabeth Hospital Birmingham, University Hospital Birmingham NHS Foundation Trust, Birmingham, UK

Main Article

Emma Richards takes responsibility for the integrity of the content of the paper

Cite this article: Richards E, Muzaffar J, Kumar R, Monksfield P, Irving R. Lateral skull-base osteoradionecrosis: a 15-year series of 20 consecutive cases and a suggested management protocol. *J Laryngol Otol* 2024; 1–5. <https://doi.org/10.1017/S002221512400077X>

Received: 4 February 2024

Revised: 3 March 2024

Accepted: 9 April 2024

Keywords:

head and neck neoplasms; temporal bone; radiology; radiotherapy; osteoradionecrosis

Corresponding author:

Emma Richards;

Email: emma.richards13@nhs.net

Abstract

Background. Temporal bone osteoradionecrosis is a rare but significant complication of radiation for head and neck malignancies. Various management techniques have been described, but no clear protocol exists.

Methods. A retrospective case review of patients with temporal bone osteoradionecrosis managed over 15 years was carried out to highlight multidisciplinary team (MDT) management. The review findings were compared with the published literature and a protocol was derived for the management of future cases.

Results. A total of 20 patients were included. The sites of osteoradionecrosis included the external auditory canal, the middle ear and the lateral skull base, presenting with features including recalcitrant pain, infection, neuropathies and intracranial sepsis. Treatments included hyperbaric oxygen, antibiotics, debridement and, in advanced cases, lateral temporal bone resection with vascularised tissue transfer. Post-operative and long-term outcomes were discussed.

Conclusion. Early temporal bone osteoradionecrosis may be managed conservatively. Refractory osteoradionecrosis can be life-threatening because of intracranial complications and sepsis. Such cases need an MDT approach with radical skull-base surgery for removal of necrotic foci and reconstruction using vascularised tissue transfer.

Introduction

Radiation therapy, as either primary or adjuvant therapy, is a major treatment modality for head and neck cancers.¹ Although radiation has proved to be effective for the management of cancer, it is well recognised that adjacent healthy tissues are also affected by immediate and delayed side effects.² With the increased survival of patients treated for a head and neck malignancy there has been an increase in the incidence of post-radiation sequelae.^{3,4} These include otitis media, sensorineural hearing loss, local tissue breakdown and osteoradionecrosis.^{4–6}

Osteoradionecrosis, first described in 1926 by Ewing,⁷ involves avascular necrosis due to degeneration of the blood vessels following exposure to high-dose radiation.⁷ This ischaemic bone is particularly susceptible to injury and infection.^{5,7} Osteoradionecrosis of the temporal bone is a rare but potentially devastating complication of head and neck radiotherapy.^{1,8} Although rarer than osteoradionecrosis of the mandible,^{6,9} it is an important topic of discussion because of the complexity of treating this region.¹

Osteoradionecrosis of the temporal bone may be limited to the tympanic bone or extend diffusely to involve the lateral skull base.¹⁰ The temporal bone is thought to be particularly susceptible because of its superficial location, limited blood supply and anatomical communication with the flora of the upper aerodigestive tract via the Eustachian tube.^{1,10} Within this, the tympanic part is most commonly affected¹¹ because of its particularly perilous blood supply and resident flora.⁵ In addition, its compact bone is less resistant to irradiation than callous bone. This tolerance is further reduced when the bone is infected or affected by neoplasm.^{10,12}

Risk factors for the development of osteoradionecrosis include age, diabetes, continued tobacco use and immunosuppression.^{5,13,14} When disease is localised, patients often present with mild symptoms, particularly otalgia and otorrhoea.^{9,10,15} On examination there is often bony sequestrum within the external auditory canal (EAC).¹⁰ Patients with localised disease are managed conservatively.^{5,6,9,14–16} Diffuse disease, however, is potentially life-threatening.^{5,14} Affected patients may develop facial nerve paralysis and intracranial complications including meningitis, cerebrospinal fluid (CSF) leak, brain abscesses and sigmoid sinus thrombosis.^{5,11} Despite the potential severity of this disease process, there remains a lack of evidence for best management.^{14,15,17} Medical therapy is symptomatic and helps to limit spread, but surgery to remove sequestrum is often indicated and various methods have been described.¹⁴

Table 1. The original cancer diagnoses

Initial diagnosis	Cases (n (%))
Squamous cell carcinoma, ear	5 (24)
Nasopharyngeal cancer	2 (9)
Parotid cancer	2 (9)
Recurrent jugulotympanic paraganglioma	2 (9)
Osteosarcoma, ear	2 (9)
Chondrosarcoma, temporomandibular joint	2 (9)
Submandibular gland cancer	1 (5)
Squamous cell carcinoma maxilla	1 (5)
Malignant melanoma, eyelid	1 (5)
Rhabdomyosarcoma, ear	1 (5)
Medulloblastoma, cerebellum	1 (5)

Materials and methods

Our aim was to produce a surgical protocol for advanced cases of osteoradionecrosis of the lateral skull base based on over a decade of experience at our tertiary centre in the UK. Advanced cases were defined as those with symptoms and disease progression necessitating surgical management. These patients had pain and discharge that could not be adequately managed with medical therapy. Patients presenting with osteoradionecrosis of the temporal bone between January 2006 and December 2021 and requiring surgery involving flap reconstruction following treatment with either primary or adjuvant radiotherapy for head and neck malignancies were included in the study. There were no exclusion criteria.

A retrospective case review was conducted from electronic records. Information including the original cancer type, location and management with primary or adjuvant radiotherapy was collected. The dates and type of radiotherapy administered were recorded where known. Any medical therapy, including hyperbaric oxygen therapy, was also noted, along with details of pre-operative facial nerve function. Multidisciplinary team (MDT) recommendations were reviewed, and surgical notes and post-operative results recorded. Long-term outcomes were also assessed. Subsequently a protocol was developed by the skull-base MDT for the management of future cases.

This retrospective case note review did not require formal ethics committee review after completing the National Decision Tool developed by the Medical Research Council Regulatory Support Centre in partnership with the Health Research Authority.

Results and analysis

We identified 20 patients with osteoradionecrosis of the temporal bone who met the inclusion criteria and were managed surgically by our MDT between January 2006 and December 2021. The patients included 12 males and 8 females, with a mean age of 66 years (range, 24–82 years).

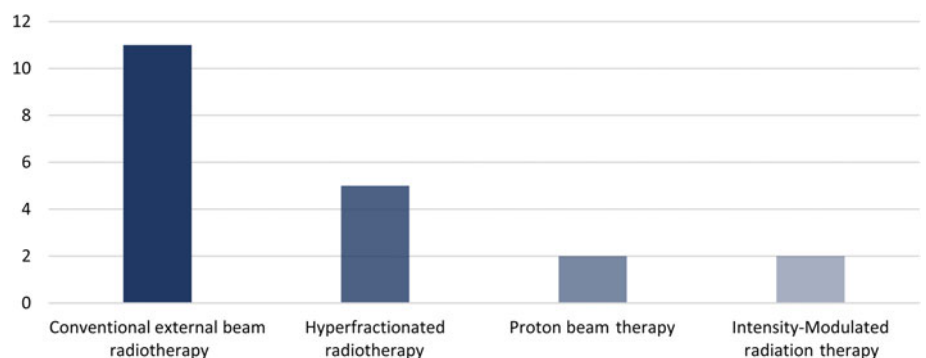
The original cancer diagnoses were variable (Table 1). The most common malignancy was squamous cell carcinoma of the ear (5 cases), followed by the nasopharyngeal carcinoma (2 cases), cancer of the parotid gland (2 cases), recurrent jugulotympanic paraganglioma (2 cases), osteosarcoma of the ear (2 cases) and chondrosarcoma of the temporomandibular joint (2 cases). Other treated malignancies included malignant melanoma of the eyelid and rhabdomyosarcoma of the ear.

Of our 20 cases, 14 (70 per cent) were treated with primary radiotherapy and 6 (30 per cent) with adjuvant radiotherapy. Eleven patients (55 per cent) received conventional external beam radiotherapy, 5 (25 per cent) received hyper-fractionated radiotherapy, 2 (10 per cent) received proton beam therapy and 2 (10 per cent) received intensity-modulated radiation therapy (Figure 1). The radiation dose ranged between 45 and 60 Gy. The mean onset of osteoradionecrosis following radiation was 2.8 years, but onset varied widely between 1.2 and 15 years.

The most common symptoms at diagnosis of osteoradionecrosis were otalgia and otorrhoea. Patients also presented with sequestrum, cholesteatoma, cranial neuropathy and intracranial sepsis. Of our patients, 16 (80 per cent) were cancer-free, 2 (10 per cent) had radio-recurrent cancer as well as osteoradionecrosis and 2 (10 per cent) were palliative (Figure 2). The mean time in progression with medical therapy, including hyperbaric oxygen, to curative surgery was 21 months (range, 11–38 months).

As per our inclusion criteria, all 20 patients underwent surgery requiring repair of defect for their advanced osteoradionecrosis. Overall, 70 per cent of patients (14 of 20) had small defects that were managed using a temporalis muscle rotational flap, 20 per cent (4 of 20) had moderate defects repaired using gracilis, serratus anterior or latissimus dorsi flap and the final 10 per cent (2 of 20) had large defects managed with anterolateral thigh and/or vastus lateralis chimeric flaps. A 100 per cent successful flap take-up rate was achieved.

There were no major operative complications and no surgery-related mortality in our population group. A 40 per cent morbidity rate was reported, with causes recorded as pain, trismus, cranial neuropathy, wound sepsis, rehabilitation time, physiotherapy and prolonged hospitalisation. It is not possible to distinguish this morbidity from morbidity that would have been present without operative management.

**Figure 1.** Type of radiation received.

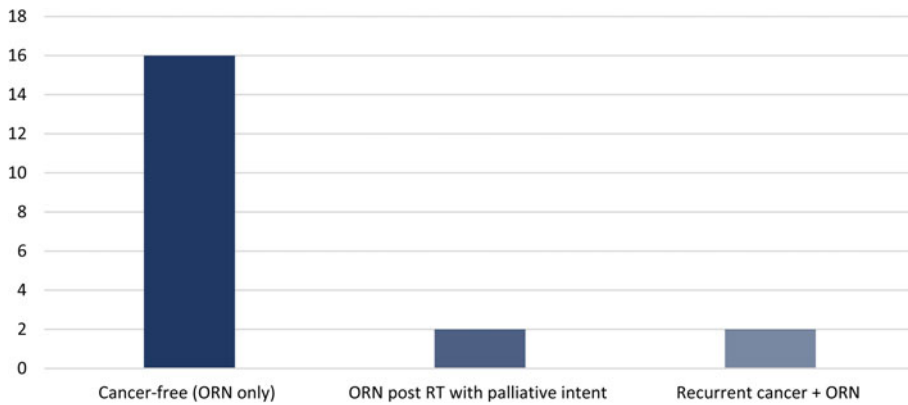


Figure 2. Cancer status of patients presenting with osteoradionecrosis. ORN = osteoradionecrosis; RT = radiotherapy.

Average follow up was for a period of 23 months (range, 5–84 months). Ten patients (50 per cent) were disease-free with no recurrence of osteoradionecrosis. Two patients (10 per cent) were treated with palliative intent because of recurrence of their original pathology (jugulotympanic paraganglioma and medulloblastoma). Eight patients (40 per cent) died during the follow-up period, with a mean time of death post-surgery of 15 months (range, 5–32 months). Of these, three patients died as a result of disease recurrence whilst five died as a result of unrelated causes.

From our findings a management algorithm was designed by the MDT as shown in Figure 3 and this algorithm has now been incorporated into our skull-base MDT.

Discussion

With the increasing survival of patients following treatment including radiotherapy for head and neck malignancies,^{3,4} the incidence of osteoradionecrosis of the temporal bone is set to increase. The hypoxic, hypovascular and hypocellular environment induced by radiotherapy leads to impaired collagen synthesis and cell production, with resultant tissue breakdown and increased prevalence of chronic infection in the ischaemic bone.^{5,7,18}

Whilst some risk factors, such as diabetes mellitus, may be modifiable,¹⁴ many, such as patient age, are not. Ramsden *et al.*¹⁰ noted that the development of osteoradionecrosis was more frequently seen when the temporal bone was in close proximity to the focus of radiation.¹⁰ The superficial location of the temporal bone and thin overlying soft tissue make this region particularly susceptible,¹⁰ and unfortunately when treating malignancies in this region, especially of the ear, this focus cannot be changed.¹ Rudge¹ found that the extent of necrosis was proportional to the dose of radiation

administered.¹ However, this was not supported by Pathek and Bryce⁵ or Sharon *et al.*¹¹ In our study, patients were found on average to have received 45–60 Gy.

It has been recognised that there is a latency period between radiotherapy and the development of osteoradionecrosis.^{1,5,10} Pathek and Bryce⁵ reported an average latency of 8 years (range, 6–11 years) from radiation to the development of diffuse osteoradionecrosis,⁵ whilst Lovin *et al.*¹⁶ reported a mean time of 10 years.¹⁶ Our mean time to development of osteoradionecrosis post-radiation was shorter, at 2.8 years, but ranged from 1.2 to 15 years, again showing a wide variation. Currently there does not seem to be a relationship between the latency period and the severity of osteoradionecrosis.¹⁰

Consistent with our results, Yuhan *et al.*¹⁵ showed that otalgia and otorrhoea are the most common initial symptoms.¹⁵ The most commonly used classification for osteoradionecrosis is by Ramsden *et al.*¹⁰ and divides cases into localised, where bone erosion is limited to the EAC, and diffuse, where it affects more of the ear and mastoid.^{10,19}

As reflected in our protocol (Figure 3), it is widely established that limited disease associated with minimal symptoms should be managed conservatively with regular aural toilet and antibiotic therapy.^{10,14} This is particularly as the goal of treatment for localised disease is directed at symptom control¹⁶ rather than complete removal or resolution of the necrotic bone.¹⁵

The algorithm proposed by Sharon *et al.*¹¹ also recommended initial conservative management, with culture-directed topical antibiotics, topical antiseptics, periodic clinic debridement and pain management,¹¹ as did Kammeijer *et al.*¹⁹ Yuhan *et al.*¹⁵ performed a systematic review on the management of osteoradionecrosis of the temporal bone and found that 89 per cent of all cases treated conservatively had adequately resolved presenting symptoms at last follow up.¹⁵

Pathak and Bryce⁵ found that being over 60 years of age was an indicator of those who failed under conservative management within 2 years⁵ and these cases may therefore need closer monitoring and aural toileting. These patients are more likely to progress to stage 2 management (Figure 3), which we propose necessitates local debridement in the form of canalplasty, meatoplasty or mastoidectomy and consideration of hyperbaric oxygen therapy.

The systemic review performed by Yuhan *et al.*¹⁵ found that 21.5 per cent of cases received conservative management and 60.9 per cent underwent surgical management.¹⁵ Hyperbaric oxygen was used in conjunction with surgical treatment in 11.3 per cent of cases.¹⁵ Kammeijer *et al.*¹⁹ outlined their guidelines to reflect the localised and diffuse osteoradionecrosis described by Ramsden *et al.*¹⁰ They suggest that when those

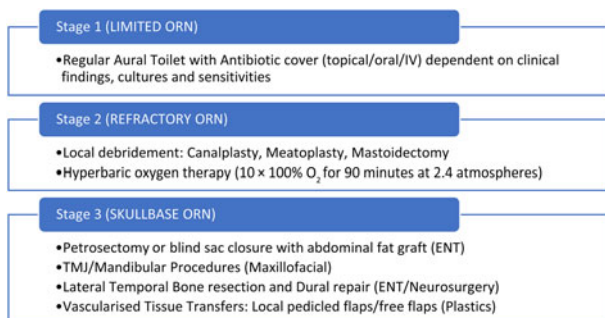


Figure 3. Management algorithm devised by the multidisciplinary team. ORN = osteoradionecrosis; IV = intravenous; TMJ = temporomandibular joint

with localised osteoradionecrosis are not symptomatically controlled, they should be managed as per diffuse A osteoradionecrosis, defined as computed tomography evidence supporting diffuse disease associated with little pain and infection, and intact functional hearing.¹⁹ They also suggest sequestrectomy in these cases.¹⁹

Hyperbaric oxygen therapy aims to increase tissue oxygenation, which in turn promotes neovascularisation and wound healing.¹⁸ Sharon *et al.*¹¹ recommended other therapies in the form of intravenous (IV) antibiotics and hyperbaric oxygen in patients who developed increasing pain, progressive infection and cranial neuropathies despite conservative management.¹¹ Our algorithm includes IV antibiotics as an option in stage 1, dependent on clinical findings. There is some evidence from small randomised controlled trials to support hyperbaric oxygen therapy in late radiation-induced tissue injury.²⁰ Reported clinical outcomes have been variable, with Sharon *et al.*¹¹ finding that of their six patients who received hyperbaric oxygen therapy, no patients achieved resolution of the necrotic bone. It was, however, felt to aid post-operative healing in one patient.¹¹

It should be noted that although hyperbaric oxygen is often incorporated into treatment algorithms for osteoradionecrosis, evaluation of its benefit is currently limited by small patient cohorts, concurrent surgical management and varied treatment protocols.¹⁴ The use of hyperbaric oxygen is affected by geographical limitations with only eight chambers across England.²¹ It is also a significant undertaking for patients both physically and mentally, with the most common protocol involving 40 treatments,²² each typically lasting 90 minutes.²³ We propose a more manageable 10 treatments. The risks of treatment include temporary visual problems, Eustachian tube dysfunction and seizures.²⁴

Whilst conservative management has been shown to be appropriate for patients with limited disease, it may not be sufficient, and refractory disease may arise. Sharon *et al.*¹¹ found that 18 out of 33 patients in their study went on to require surgical management because of intractable pain, persistent infection or the development of cholesteatoma.¹¹ Our study showed a mean time between medical therapy and surgery with curative intent of 21 months.

Kammerijer *et al.*¹⁹ reserved subtotal petrosectomy for those with diffuse B disease, who they define as those in whom there is severe pain and infection and/or no functional hearing because of the risk–benefit balance of the more extensive surgery.¹⁹ Yuhan *et al.*¹⁵ found that less than 60 per cent of mastoidectomies led to complete resolution, but over 90 per cent of lateral temporal bone resections resolved.¹⁵ Sharon *et al.*¹¹ specified that the aim of surgery was to gain symptom control rather than complete removal of necrotic bone.^{5,11} This view was justified in that it has been shown that there are increased risks of operating in radiated temporal bone, including higher than expected rates of facial nerve dehiscence, oval window and lateral canal fistulae, dural exposure, CSF leak and lateral canal procedures.²⁰ These risks are thought to occur because of the poor blood supply to the EAC, which is then further decreased by surgery.⁵ However, it should be noted that our algorithm differs in its consideration and recommendation of reconstruction in appropriate cases.

As in our advanced cases, the symptom severity and potentially life-threatening nature of diffuse disease makes more aggressive management necessary.^{3,5,10} Flexibility from local flaps or free flaps is needed to reconstruct defects of the lateral temporal bone. With advancing techniques in reconstruction, cosmesis is now of increasing focus rather than simply

covering the resultant defect,³ and this is reflected in stage 3 of our algorithm. However, significant complications continue to be reported in those undergoing such surgery, including persistently discharging fistulae.¹¹

Free flaps can provide much better functional and aesthetic results compared with local and regional flaps.²⁵ However, there are a number of considerations when selecting an appropriate flap. These include the size and location of the defect, the blood supply of both the flap and the recipient site, and, importantly, the aim of the reconstruction in terms of aesthetic and functional outcomes.²⁵

The anterolateral thigh chimeric flap, which relies on the descending branch of the lateral circumflex femoral artery, has been described for use in the reconstruction of large soft tissue defects in this region and to correct facial palsy.²⁵ This flap is easily obtained and offers sufficient muscle bulk to fill large defects. There is also access to redundant motor nerves such as a branch of the motor nerve to the vastus lateralis which is suitable for grafting.²⁶ It is also possible to alter the thickness of the subcutaneous fat in the anterolateral region to achieve appropriate flap thickness at the reconstruction site.²⁷ This mitigates the complications of fat liquefaction and seroma associated with fat transfer and dermal grafts.²⁵ Lóderer *et al.*²⁵ reported that there was minimal morbidity at the donor site.²⁵ This single-stage approach is generally associated with fewer complications and better neural regeneration than a multistep approach.²⁵ Direct nerve anastomosis or cable grafting is the preferred reconstruction technique, yielding the best functional outcomes in patients undergoing facial nerve sacrifice.²⁵

Our surgically treated patients in this report obtained good symptomatic relief and long-term control of osteoradionecrosis. However, our findings are based on a small cohort with heterogeneity in presentation, making it difficult to draw overall conclusions. To the best of our knowledge, no multicentre study has yet been performed, and given the rarity of this presentation it is unlikely that this will be undertaken in the near future. In addition, consideration of the interpretation of outcomes is needed. Consensus is required on what constitutes successful treatment, be it complete eradication of exposed bone, resolution of symptoms or reduction of symptoms to acceptable levels.¹¹

- Osteoradionecrosis is a serious potential complication of radiation for head and neck cancer
- The temporal bone is particularly at risk because of its location, blood supply and connection to the upper aerodigestive tract
- Presentation of osteoradionecrosis can be with otalgia, otorrhoea, facial palsy, cerebrospinal fluid leak and meningitis
- Management of osteoradionecrosis is difficult, but local management with regular aural toilet and antibiotics can help with early disease
- In the most severe cases of osteoradionecrosis, resection and flap reconstruction may be required to restore vascularity and function

Osteoradionecrosis is a rare and difficult clinical entity requiring co-ordinated MDT input. The key guiding principle is to restore vascularity to the dying bone and facial nerve. Outcomes are promising, with 50 per cent of cases now disease-free. We advocate the protocol described here as part of a multidisciplinary approach to this complex condition. Larger multicentre studies may provide a better understanding of the optimum treatment strategy in any individual patient.

Competing interests. None declared

References

- 1 Rudge FW. Osteoradionecrosis of the temporal bone: treatment with hyperbaric oxygen therapy. *Mil Med* 1993;**158**:196–8
- 2 Barnett GC, West CM, Dunning AM, Elliott RM, Coles CE, Pharoah PD *et al*. Normal tissue reactions to radiotherapy: towards tailoring treatment dose by genotype. *Nat Rev Cancer* 2009;**9**(2):134–42
- 3 Kadakia S, Badhey A, Inman J, Mourad M, Ducic Y. Surgical management of temporal bone osteoradionecrosis: single surgeon experience of 47 cases. *Am J Otolaryngol* 2017;**38**:688–91
- 4 Funk GF, Karnell LH, Christensen AJ. Long-term health-related quality of life in survivors of head and neck cancer. *Arch Otolaryngol Head Neck Surg* 2012;**138**(2):123–33
- 5 Pathak I, Bryce G. Temporal bone necrosis: diagnosis, classification, and management. *Otolaryngol Head Neck Surg* 2000;**123**:252–7
- 6 Brook I. Late side effects of radiation treatment for head and neck cancer. *Radiat Oncol J* 2020;**38**(2):84–92
- 7 Ewing J. Radiation osteitis. *Acta Radiol* 1926;**6**:399–412
- 8 Schuknecht HF, Karmody CS. Radionecrosis of the temporal bone. *Laryngoscope* 1966;**76**:1416–28
- 9 Guida RA, Finn DG, Buchalter IH, Brookler KH, Kimmelman CP. Radiation injury to the temporal bone. *Am J Otol* 1990;**11**(1):6–11
- 10 Ramsden RT, Bulman CH, Lorigan B. Osteoradionecrosis of the temporal bone. *J Laryngol Otol* 1975;**89**:941–55
- 11 Sharon JD, Khwaja SS, Drescher A, Gay H, Chole R. Osteoradionecrosis of the temporal bone: a case series. *Otol Neurotol* 2014;**35**:1207–17
- 12 Lederman M. Radiation therapy in cancer of the larynx. *JAMA* 1972;**221**:1253–4
- 13 Sathasivam HP, Davies GR, Boyd NM. Predictive factors for osteoradionecrosis of the jaws: a retrospective study. *Head Neck* 2018;**40**:46–54
- 14 Herr MW, Vincent AG, Skotnicki MA, Ducic Y, Manolidis S. Radiation necrosis of the lateral skull base and temporal bone. *Semin Plast Surg* 2020;**34**(4):265–71
- 15 Yuhan BT, Nguyen BK, Svider PF, Raza SN, Hotaling J, Chan E *et al*. Osteoradionecrosis of the temporal bone: an evidence-based approach. *Otol Neurotol* 2018;**39**:1172–83
- 16 Lovin BD, Hernandez M, Elms H, Choi JS, Lindquist NR, Moreno AC *et al*. Temporal bone osteoradionecrosis: an 18-year, single-institution experience. *Laryngoscope* 2021;**131**:2578–85
- 17 Phillips DJ, Njoku IU, Brown KD, Selesnick SH. Radiation-induced necrosis of the temporal bone: diagnosis and management. *Otol Neurotol* 2015;**36**:1374–7
- 18 Hao SP, Chen HC, Wei F-C, Chen C, Yeh AR, Su J. Systematic management of osteoradionecrosis in the head and neck. *Laryngoscope* 1999;**109**:1327–8
- 19 Kammeijer Q, Van Spronsen E, Mirck PG, Dreschler WA. Treatment outcomes of temporal bone osteoradionecrosis. *Otolaryngol Head Neck Surg* 2015;**152**:718–23
- 20 Bennett M, Kaylie D, Warren F, Jackson CG. Chronic ear surgery in irradiated temporal bones. *Laryngoscope* 2007;**117**:1240–4
- 21 NHS England. Hyperbaric oxygen therapy services (all ages). In: <https://www.england.nhs.uk/wp-content/uploads/2018/11/1766-HBOT-Service-Specification.pdf> [28 November 2023]
- 22 Forner LE, Dieleman FJ, Shaw RJ, Kanatas A, Butterworth CJ, Kjeller G *et al*. Hyperbaric oxygen treatment of mandibular osteoradionecrosis: combined data from the two randomized clinical trials DAHANCA-21 and NWHHT2009-1. *Radiother Oncol* 2022;**166**:137–44
- 23 Bedfordshire and Hertfordshire Priorities Forum Statement. Hyperbaric oxygen in the prevention and treatment of osteo-radionecrosis. In: https://www.enhertscg.nhs.uk/sites/default/files/documents/Mar2015/guidance_07-hyperbaric-O2-for-osteoradionecrosis-updated-sept13.pdf [28 November 2023]
- 24 Shaw RJ, Butterworth CJ, Silcocks P, Tesfaye BT, Bickerstaff M, Jackson R *et al*. HOPON (hyperbaric oxygen for the prevention of osteoradionecrosis): a randomized controlled trial of hyperbaric oxygen to prevent osteoradionecrosis of the irradiated mandible after dentoalveolar surgery. *Int J Radiat Oncol Biol Phys* 2019;**104**(3):530–9
- 25 Lóderer Z, Vereb T, Paczona R, Janovszky Á, Piffkó J. An anterolateral thigh chimeric flap for dynamic facial and esthetic reconstruction after oncological surgery in the maxillofacial region: a case report. *Head Face Med* 2018;**14**:1–6
- 26 Revenaugh PC, Knott PD, Scharpf J, Fritz MA. Simultaneous anterolateral thigh flap and temporalis tendon transfer to optimize facial form and function after radical parotidectomy. *Arch Facial Plast Surg* 2012;**14**:104–9
- 27 Ren Z, Wu H, Wang K, Zhang S, Tan HY, Gong Z. Anterolateral thigh myocutaneous flaps as the preferred flaps for reconstruction of oral and maxillofacial defects. *J Craniomaxillofac Surg* 2014;**42**:1583–9