

LETTER TO THE EDITOR**To The Editor****Crohn-related Chronic Relapsing Inflammatory Optic Neuropathy**

Keywords: Crohn colitis, chronic relapsing inflammatory optic neuropathy, inflammatory bowel disease

We describe a patient with hitherto unreported Crohn-related chronic relapsing inflammatory optic neuropathy (CRION). This 37-year-old woman had at age 24 her first attack of right optic neuritis associated with ocular inflammation. Symptoms had included retro-orbital and temporal pain, right eye blurred vision, pain with eye movement and impaired colour vision. Visual acuities were 20/200 on the right and 20/25 on the left. There was right panuveitis with optic disc edema, and left anterior and intermediate uveitis. Magnetic resonance imaging (MRI) scan showed thickening and enhancement of the optic chiasm, optic nerves and optic tracts (Figure 1). High-dose intravenous corticosteroids for 3 days improved right eye visual acuity to 20/25 and left to 20/20. Over the next 4 months, there were 4 attacks of bilateral asymmetrical visual loss, ocular inflammation and optic neuritis, each attack treated with high-dose intravenous corticosteroids and tapering prednisone. After the last attack, visual acuities were finger counting on the right and 20/70 on the left. There was a right relative afferent pupillary defect (RAPD) and a right eye inferior altitudinal visual field defect. She was maintained on azathioprine for 7 months when a relapse of right optic neuritis occurred. She was then switched to cyclophosphamide 50 mg daily. One year later, visual acuities were 20/20 on the right and 20/25 on the left. In 5 years, there was no relapse of optic neuritis. Because she was stable, and to avoid cumulative toxicity, the cyclophosphamide was discontinued. Mild flares of vitritis and uveitis were treated with topical corticosteroids. Within 2 months of discontinuing cyclophosphamide, she developed arthritis, nausea, abdominal pain and diarrhoea. Crohn colitis was demonstrated by colonoscopy and colonoscopic biopsies. She was prescribed a tapering course of prednisone and then begun on maintenance azathioprine 2.5 mg per kg daily. Follow-up colonoscopy 12 weeks later confirmed deep endoscopic remission with no subsequent flares of colitis. At age 33, there was an attack of left optic neuritis. Despite prednisone 80 mg, a large part of the left eye visual field was lost. At age 35, corticosteroids and azathioprine were tapered off after 5 years of treatment and she was maintained on mycophenolate mofetil 1500 mg daily. Within a year, there was a relapse of left optic neuritis resulting in no light perception in the left eye despite high-dose intravenous corticosteroids and plasma exchange. The mycophenolate was increased to 3000 mg daily. After six months of treatment, there was a single episode of left retro-orbital and temple pain with eye movement but without right eye visual loss. The latest examination showed right eye visual acuity of 20/25 and no light perception in the left eye. Colour vision was normal in the right eye. There was a left RAPD and left greater than right optic disc pallor. The rest of the neurological examination was normal. Automated perimetric visual field testing showed in the

right eye nerve fibre bundle defects in the form of superior and inferior arcuate scotomas. Optical coherence tomography (OCT) showed marked bilateral retinal nerve fibre layer loss.

Haematology, chemistry, renal, liver, immunology, autoimmune and infectious diseases laboratory tests were all normal. Specifically, the following were normal or negative: cell-based neuromyelitis optica (NMO) and myelin oligodendrocyte glycoprotein (MOG) antibody assays, complete blood count, calcium, creatine kinase, angiotensin-converting enzyme, complement C3 and C4, cryoglobulins, rheumatoid factor, antinuclear antibody by immunofluorescence, anti-double-stranded DNA, extractable nuclear antigen antibodies-2, extractable nuclear antigen antibodies-4, antineutrophil cytoplasmic antibodies, antiphospholipid antibodies, anticardiolipin antibodies, cyclic citrullinated peptide antibodies, human leukocyte antigen B*51 (B5), syphilis screen, Lyme serology, Bartonella henselae serology, herpes simplex IgG antibodies, Epstein-Barr viral capsid antigen IgG antibodies, cytomegalovirus antigenemia assay. Initial cerebrospinal fluid (CSF) had shown protein of 1.06 g/L and 57×10^6 lymphocytes/L. CSF studies were otherwise normal or negative: glucose; cryptococcal antigen; viral PCRs (herpes simplex virus, varicella zoster virus, cytomegalovirus, Epstein-Barr virus); CSF varicella zoster virus IgM; mycobacterial PCR; bacterial, acid-fast bacterial, and fungal cultures; venereal disease research laboratory test; Lyme disease serology; IgG index; oligoclonal band assay; cytology; flow cytometry. Chest radiograph, computed tomography (CT) scan of the thorax, abdomen and pelvis, radiograph of the sacroiliac joints and electrocardiogram were normal/negative. On MRI scan of the brain, there was a 6 mm cystic lesion in the pituitary gland but no endocrine dysfunction was identified clinically or by testing. There were no abnormalities of the optic nerves or brain on repeat MRI scan, MRI scan of the spinal cord or positron emission tomography scan.

Ocular complications have been described in inflammatory bowel disease (IBD)¹⁻⁴ and reportedly occur in 4% to 6% of IBD patients.¹ Ocular manifestations of IBD are not necessarily associated with a distinct pattern of intestinal disease activity, duration or phenotype.⁴ Neurological manifestations, including optic neuritis, are an occasional feature of IBD. They may precede or follow the onset of IBD or may occur during an IBD exacerbation.^{4,7} Optic neuritis in IBD can occur without associated signs of ocular inflammation such as uveitis or retinitis.⁴ Optic nerve involvement in patients with IBD may be due to inflammation, ischemia due to inflammation or hypercoagulability, intracranial hypertension or anti-tumour necrosis factor (anti-TNF) drugs.⁴ Optic neuritis in IBD may be unilateral, simultaneously bilateral or recurrent (sequentially ipsilateral or contralateral). The basis for stating that "recurrences of retrobulbar neuritis are not uncommon" is not supported by details or numbers in reports.⁴ Furthermore, no recurrences were reported in a more recent review.⁸

Our patient fulfills the criteria for CRION: optic neuritis and at least one relapse; objective evidence for loss of visual function; NMO IgG seronegativity; contrast enhancement of the acutely inflamed optic nerves; response to immunosuppressive treatment and relapse on withdrawal or dose reduction of immunosuppressive treatment.⁹ Her clinical picture is consistent with the features

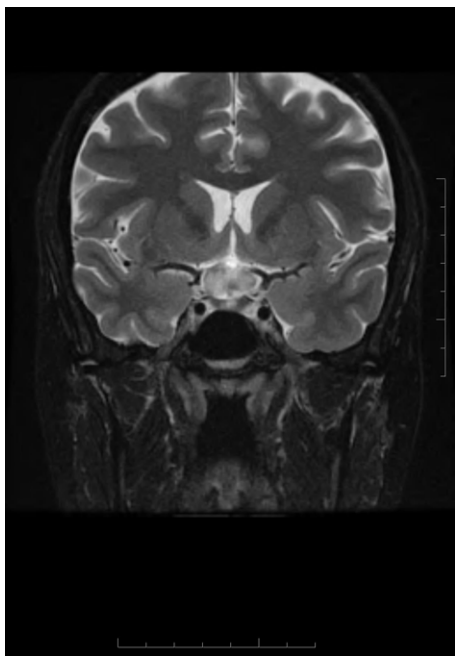


Figure 1: Coronal T2W MRI with gadolinium showing enhancement of the optic chiasm.

of CRION.¹⁰ NMO and MOG antibody positivity have been found in patients previously diagnosed with CRION^{11,12} but not in our patient. Clinically and by laboratory investigations and imaging, we ruled out those alternative diagnoses for optic neuropathies listed by Petzold and Plant.⁸ CRION likely harbours a heterogeneous group of autoimmune disorders with a common clinical optic neuritis phenotype. The discovery of other autoantibodies to account for CRION can be anticipated. Our patient's case, and research in this area, underline the importance of assessing apparent CRION for possible associations and alternative diagnoses. We are not aware of other reports of CRION in the setting of IBD. In addition to such recognised ocular involvement as uveitis, retinitis and optic neuritis in patients with IBD, CRION should now also be considered as a possible extraintestinal manifestation, either at presentation or later in the course of the disease.

DISCLOSURES

Dr. Levin has consulted for Aerie, Eyevensys, Genentech, Prilenia, Quark, Roche, and Santen. All other authors have no disclosures to declare.

STATEMENT OF AUTHORSHIP

Conception and design (FT; AS), data collection (RB; AS), manuscript preparation (FT; AB; IB), critical appraisal (AB; IB; LAL), review of the manuscript (FT).

Felix Tyndel

*Department of Medicine (Neurology), University of Toronto,
Toronto, Ontario, Canada*

Arun Sundaram

*Department of Medicine (Neurology), University of Toronto,
Toronto, Ontario, Canada*

Razmik Bebedjian

*Department of Medicine (Neurology), University of Ottawa,
Ottawa, Ontario, Canada*

Ian Bookman

*Department of Medicine (Gastroenterology), University of
Toronto, Toronto, Ontario, Canada*

Arthur Bookman

*Department of Medicine (Rheumatology), University of Toronto,
Toronto, Ontario, Canada*

Leonard A. Levin

*Departments of Ophthalmology & Visual Sciences and
Neurology & Neurosurgery, McGill University, Montreal,
Quebec, Canada*

Correspondence to: Felix Tyndel, Department of Medicine (Neurology), University of Toronto, Toronto, Ontario, Canada. Email: f.tyndel@utoronto.ca

REFERENCES

- Greenstein AJ, Janowitz HD, Sachar DB. The extra-intestinal complications of Crohn's disease and ulcerative colitis: a study of 700 patients. *Medicine*. 1976;55:401–12.
- Hopkins OJ, Horan E, Burton IL, et al. Ocular disorders in a series of 332 patients with Crohn's disease. *Br J Ophthalmol*. 1974;58:732–7.
- Felekis T, Katsanos K, Kitsanou K, et al. Spectrum and frequency of ophthalmologic manifestations in patients with inflammatory bowel disease: a prospective single-center study. *Inflamm Bowel Dis*. 2009;15:29–34.
- Katsanos A, Asproudis I, Katsanos KH, et al. Orbital and optic nerve complications of inflammatory bowel disease. *J Crohn's Colitis*. 2013;7:683–93.
- Lossos A, River Y, Eliakim A, et al. Neurologic aspects of inflammatory bowel disease. *Neurology*. 1995;45:416–21.
- Petzold A, Wong S, Plant GT. Autoimmunity in visual loss. *Handb Clin Neurol*. 2016;133:352–76.
- McClelland C, Zaveri M, Walsh R, et al. Optic perineuritis as the presenting feature of Crohn's disease. *J Neuro-Ophthalmol*. 2012;32:345–7.
- Alexandre B, Vandermeeren Y, Dewit O, et al. Optic neuritis associated or not with TNF antagonists in patients with inflammatory bowel disease. *J Crohn's Colitis*. 2016;10:541–8.
- Petzold A, Plant GT. Chronic relapsing inflammatory optic neuropathy: a systematic review of 122 cases reported. *J Neurol*. 2014;261:17–26.
- Bennett JL. Optic neuritis. *Continuum*. 2019;25:1238–42.
- Petzold A, Woodhall M, Khaleeli Z, et al. Aquaporin-4 and myelin oligodendrocyte glycoprotein antibodies in immune-mediated optic neuritis at long-term follow-up. *J Neurol Neurosurg Psychiatry*. 2019;90:1021–6.
- Liu H, Zhou H, Wang J, et al. Antibodies to myelin oligodendrocyte glycoprotein in chronic relapsing inflammatory optic neuropathy. *Br J Ophthalmol*. 2019;103:1423–8.